

## Review Article



# Acute Pulmonary Embolism: Focus on the Clinical Picture

Doralisa Morrone , MD, PhD<sup>1</sup>, and Vincenzo Morrone , MD<sup>2</sup>

<sup>1</sup>Department of Surgery, Medical, Molecular and Critical Area Pathology, University of Pisa, Italy

<sup>2</sup>Department of Cardiology, SS. Annunziata Hospital, Taranto, Italy



**Received:** Oct 12, 2017

**Revised:** Mar 27, 2018

**Accepted:** Apr 11, 2018

### Correspondence to

Doralisa Morrone, MD, PhD

Department of Surgery, Medical, Molecular and Critical Area Pathology, University of Pisa, via Paradisa, 2, Pisa 56124, Italy.  
E-mail: doralisa.morrone@unipi.it

Copyright © 2018. The Korean Society of Cardiology

This is an Open Access article distributed under the terms of the Creative Commons Attribution Non-Commercial License (<https://creativecommons.org/licenses/by-nc/4.0>) which permits unrestricted noncommercial use, distribution, and reproduction in any medium, provided the original work is properly cited.

### ORCID iDs

Doralisa Morrone

<https://orcid.org/0000-0002-9667-6931>

Vincenzo Morrone

<https://orcid.org/0000-0002-7485-2041>

### Conflict of Interest

The authors have no financial conflicts of interest.

### Author Contributions

Investigation: Morrone D, Morrone V; Writing - original draft: Morrone D, Morrone V; Writing - review & editing: Morrone D, Morrone V.

## ABSTRACT

Acute pulmonary embolism (APE) is characterized by numerous clinical manifestations which are the result of a complex interplay between different organs; the symptoms are therefore various and part of a complex clinical picture. For this reason, it may not be easy to make an immediate diagnosis. This is a comprehensive review of the literature on all the various clinical pictures in order to help physicians to promptly recognize this clinical condition, remembering that our leading role as cardiologists depends on and is influenced by our knowledge and working methods.

**Keywords:** Pulmonary embolism; Sudden cardiac death; Syncope; Deep vein thrombosis

## INTRODUCTION

Acute pulmonary embolism (APE) is the most serious clinical presentation of venous thrombo-embolism (VTE) with fatal pulmonary embolism (PE) being a common cause of sudden death (SD), usually resulting from a complication of deep venous thrombosis (DVT).

In the United States PE affects about 500,000 to 600,000 people per year, with 200,000 to 300,000 deaths per year.<sup>1)</sup> PE is the third most frequent cardiovascular disease after acute myocardial infarction (AMI) and stroke, with an annual incidence of 1–2 per 1,000 people (100–200 per 100,000 inhabitants).<sup>2)3)</sup>

In 2001, the number of VTE-related deaths was estimated at 543,454 per annum across Europe, more than double comparing with the number of combined deaths due to acquired immune deficiency syndrome (AIDS) (5,860), breast cancer (86,831), prostate cancer (63,636), and road accidents (53,599).<sup>4-6)</sup> The correct annual number of VTE events is hard to obtain due to the difficult diagnosis based mostly on the following factors: 1) VTE is often clinically silent with the first sign of the disease being sudden fatal death (30–50% of cases)<sup>7)</sup>; 2) clinical presentation mimics the characteristics of several other conditions, resulting in mistaken diagnoses<sup>8)</sup>; 3) PE detection during autopsy is very difficult and requires close inspection of the pulmonary vascular tree in order to uncover small acute emboli or the residua of chronic thrombo-emboli<sup>9)</sup>; and 4) sensitivity and specificity of diagnostic tests for the disease remain weak.<sup>10)</sup>

PE risk factors include obesity, immobilization, cigarette use, cancer, surgery, trauma, pregnancy, oral contraceptives or hormone replacement therapies, and a prior history of PE or a known hyper-coagulable disorder. However 30% of patients with PE have no detectable provoking factors and, as shown in the Emergency Medicine Pulmonary Embolism in the Real World Registry (EMPEROR), International Cooperative Pulmonary Embolism Registry (ICOPER), and Registro Informatizado de Enfermedad TromboEmbólica (RIETE) registries, the mean age of PE patients ranges from 56 to 66 years, with older people and females having mild prevalence.<sup>11-14</sup> Clinical presentation of PE varies from an asymptomatic small pulmonary embolus with low mortality to a massive PE resulting in failure of the right ventricular (RV) with shock, and/or death.<sup>15</sup>

Many fatal pulmonary emboli remain unrecognized due to the lack of routine postmortem examinations leading to an underestimation of their incidence.<sup>16-19</sup> Prompt diagnosis of this potentially deadly disease is of utmost importance, therefore knowledge of the salient features associated with PE may enable physicians to make the diagnosis facilitating the following appropriate treatment strategy.

## SYMPTOMS AND SIGNS OF PE

Pain can be related to local disturbances in pulmonary circulation, pleural involvement or impairment of coronary circulation. Central PE may produce typical angina also due to RV ischemia; while pleuritic chest pain can be the consequence of pleural irritation due to pulmonary infarction secondary to small distal pulmonary artery (PA) embolization.<sup>20-22</sup> Dyspnea has a multi-factorial origin, resulting from bronchospasm or vasospasm, disturbances in pulmonary circulation, immobility or diminished respiratory excursion of the diaphragm, atelectasia and/or pulmonary infarction, anoxia, or impairment of cardiac function. In patients with pre-existing heart failure or pulmonary disease, deteriorating dyspnea may be the only symptom indicative of PE. Anoxia is manifested clinically by cyanosis. Hyperbilirubinemia may occur when hepatic congestion co-exists. Dyspnea, chest pain, and cough are the most frequent symptoms of PE, while fever, tachycardia, abnormal pulmonary signs, and peripheral vascular collapse are the most common physical findings. Cyanosis, hemoptysis, syncope, and the various manifestations of acute cor pulmonale are less commonly observed.

## CLINICAL PICTURES

PE is a prevalent and potentially life-threatening cardiovascular condition that may be difficult to diagnose due to a wide spectrum and often nonspecific manifestations (**Table 1**). Diagnosis of PE may therefore involve multiple specialties, including emergency medicine, cardiology, internal medicine, obstetrics and gynaecology, surgical services, and sometimes urgent interventional radiology. A number of medical centers across the United States, including Massachusetts General Hospital and Brigham and Women's Hospital, have already founded multidisciplinary PE response teams in order to improve diagnosis and access to advanced therapies. Given this premise the purpose of this review was to focus on syndromes more than individual symptoms in patients in which APE can be suspected in order to develop a more comprehensive view of PE patients.

Table 1. Clinical presentation of PE

Symptoms	Stein (1981/1991)	Goldhaber (1999)	Kucher (ICOPER 2006), Massive PE	Kucher, Non-massive PE	Torbicki (ICOPER 2003), Right heart thrombus	Torbicki (ICOPER 2003), Right heart thrombus negative	RIETE registry (2006)	EMPEROR registry (2011)
Dyspnea	73%	82%	81%	82%	83%	88%	32%	50%
Tachipnea	66%	60%						
Tachicardia	30%	40%						
Chest pain	70%	49%	40%	50%	46%	47%		54% (39% pleuritic and 15% substernal)
Pulmonary infarction							50%	
Upper abdominal pain								11%
Syncope	13%	14%	39%	12%	24%	16%		6%
Cough	37%	20%	9%	21%				23%
Respiratory distress								16%
Hemoptysis	13%	7%	2%	7%				8%
Circulatory collapse (yes/no)					14%	5%	18%	
Fever (>37.8°C)	7%	9%						10%
DVT	11%	54%	32%	50%	40%	53%		24%
ECG/BBDX		16%			27%	13%		
ECG/AF		14%			12%	12%		
Chest radiograph								
Cardiac enlargement		36%						12%
Effusion		30%						16%
Elevated hemidiaphragm		26%						3%
PA enlargement		25%						
Atelectasis		24%						17%
Infiltrate		23%						14%
RV hypokinesis echocardiogram		40%	62%	39%	64%	40%		
Right heart thrombus echocardiogram		4%	10%	4%				
Pulmonary angiography		34%						
Filling defects >50% total vasculature								
Mortality (30 days)					21%	11%		
Mortality (3 months)		17% 58% U 15% St	52%	15%	29%	16%		

This table highlights symptoms prevalence according each registry.

AF = atrial fibrillation; BBDX = Blocco di Branca Destra; DVT = deep venous thrombosis; ECG = electrocardiogram; EMPEROR = Emergency Medicine Pulmonary Embolism in the Real World Registry; ICOPER = International Cooperative Pulmonary Embolism Registry; PA = pulmonary artery; PE = pulmonary embolism; RIETE = Registro Informatizado de Enfermedad TromboEmbólica; St = stable patients; U = Unstable patients.

### Clinical pictures of APE:

1. SD (sudden cardiac arrest; SCA)
2. Similar to acute respiratory distress syndrome (ARDS)
3. Typical respiratory failure (hypoxia and hypocapnia)
4. Asthmatic crisis-like syndrome
5. Fever syndrome with or without pseudopneumonia (with or without pleural effusion)
6. Acute right heart failure/shock/hypotension (often with epigastric pain)
7. Left heart failure (with pulmonary congestion)
8. Chest pain similar to pleuritic syndrome with or without haemoptysis (with or without effusion)
9. Similar to acute coronary syndrome (ACS) (with or without chest pain)

10. PE with paradoxical embolism (with corresponding clinical picture due to embolization site and resulting in: AMI, stroke, flank pain [due to acute splenic infarction or acute renal infarction], acute abdomen, and upper or lower extremity embolism. In all these paradoxical embolism conditions, the main symptom may be systemic or not)
11. Syncope
12. Complete atrioventricular (AV) block with idioventricular rhythm
13. Persistent or paroxysmal atrial fibrillation (AF), atrial flutter, atrial tachycardia, paroxysmal supraventricular tachycardia (PSVT)
14. DVT and silent PE
15. Platypnea-orthodeoxia
16. Abdominal pain without abdomen acute
17. Delirium

### SD

SD is defined as unexpected natural death from a cardiac cause (coronary disease, hypertrophic cardiomyopathy, valvular disease, no structural abnormalities)<sup>23)</sup> or non-cardiac cause (respiratory, cerebral, drug overdose, exsanguination, metabolic, sepsis, near drowning hypothermia trauma)<sup>24)</sup> that occurs within a short time interval (generally within 1 hour of onset of symptoms) in patients with no prior potentially-fatal condition.<sup>25-27)</sup> Most victims (>90%) have underlying cardiac abnormality.<sup>28)</sup> The most frequent cause of SD is coronary disease (80% of cases) with the risk of sudden cardiac death (SCD) being higher in men than in women and it increases with age due to the higher prevalence of coronary artery disease (CAD) in older individuals. Only a small percentage of patients show no structural abnormalities.<sup>29)30)</sup> The incidence of SD in the United States is 1 person per 1,000/year with SD being the initial clinical manifestation in 25–30% of patients with PE, and it accounts for approximately 1.3% of the total deaths in western countries.<sup>31)32)</sup> Seventy-five percent of SD cases include overweight/obese patients with 31% of these patients having history of psychiatric disorders in pharmacological treatment, supporting the recently-reported association between mental disorders and PE risk.<sup>33-35)</sup> The percentage of clinically unsuspected PE causing in-hospital SD has been reported to be as high as 50% to 80%.<sup>36)37)</sup> SD due to PE can occur in the presence of ACS, developing ventricular arrhythmia, or during non-shockable rhythm. Recently, Bougouin et al.<sup>35)</sup> showed in a large population-based registry that PE-related SCA is not rare, accounting for 3% of all SCA patients admitted in hospital alive. Moreover, this study highlighted that PE-related SCA should be suspected in cases of non-shockable rhythm, in women, and in those with prior thrombo-embolism.<sup>38)</sup> The cause of cardiac arrest is not easily recognized, especially when the initial rhythm is different from ventricular fibrillation; in the majority of cases, the mechanism of cardiac arrest in massive PE is pulseless electrical activity (PEA) (a syndrome characterized by the absence of a palpable pulse in an unconscious patient with organized electrical activity).

### Similar to ARDS

Non-cardiogenic pulmonary edema or ARDS occurs in a wide variety of clinical settings, such as hypovolemic shock, major trauma, and septicemia; it was described as a complication of classic PE by Windebank and Moran in 1973, although in this instance no pulmonary capillary wedge pressures were obtained. In 1982, Adrian et al. documented PE in patients with pulmonary edema while performing right heart catheterisation that showed normal post-capillary pressure, therefore excluding left ventricular (LV) failure as a cause of the pulmonary edema; moreover, the finding of pulmonary edema confined to unobstructed portions of the pulmonary capillary bed confirmed the diagnosis.

It has been proposed that the release of vasoactive substances from clots may lead directly to increased capillary permeability or to venous constriction and increased capillary hydrostatic pressure; in addition, it is possible that fibrin micro-emboli may injure pulmonary capillaries. All these possibilities may, of course, produce edema downstream of the obstruction. Another mechanism proposed has been a mal-distribution of blood flow causing some areas of a lung to be over-perfused, resulting in interstitial and alveolar edema.<sup>39)</sup>

### **Typical respiratory failure (hypoxia and hypocapnia)**

In blood gas analysis, hypoxemia is considered a typical finding of APE, but up to 40% of these patients have normal arterial oxygen saturation and 20% have a normal alveolar-arterial oxygen gradient.<sup>40)41)</sup> However, when hypoxemia is present during PE dyspnea is the first symptom of respiratory failure as a consequence of hemodynamic disturbances. Hemodynamic disturbance includes low cardiac output resulting in desaturation of the mixed venous blood flow that together with areas of reduced flow (due to obstructed vessels) and areas in which flow is increased lead to ventilation-perfusion mismatch. In about one-third of patients' severe hypoxemia can be detected when right-to-left shunt (through a patent foramen oval [PFO]) is present. This is caused by an inverted pressure gradient between the right atrium and left atrium; in these clinical pictures hypocapnia is also often present. The chest X-ray is frequently abnormal, and although findings are usually non-specific in PE, they are useful for excluding other causes of dyspnea or chest pain.

The classic presentation of APE may be difficult or impossible to recognize in critically ill patients with respiratory failure. Symptoms are difficult to obtain and assess in patients who are intubated and receiving therapy with mechanical ventilation. In patients previously diagnosed with chronic obstructive pulmonary disease (COPD), the usual clinical manifestations of pulmonary emboli (symptoms, signs, chest X-ray film, electrocardiogram (ECG), and changes in arterial blood gas levels) are frequently already present due to the severe underlying pulmonary disease, and any superimposed manifestations of pulmonary emboli may not be evident. In this group, the ventilation/perfusion lung scan correlated poorly with pulmonary angiographic results and during examination at autopsy, the scan was generally insufficient to rule in or rule out pulmonary emboli. Currently, pulmonary angiography remains the only reliable technique to confirm or exclude PE.<sup>42)</sup>

### **Asthmatic crisis (bronchial asthma-like symptoms induced by PE)**

PE is known to induce symptoms such as bronchial asthma therefore diagnosis of PE may be difficult if a previous history of asthma is present.<sup>43)69)</sup> However the mechanism behind bronchoconstriction in PE is not fully understood. It has been suggested that pharmacologically-active substances may be released at thrombo-embolic sites, leading to the excitation of specific chemoreflexes. Such agents include acetylcholine, histamine, serotonin, and the plasma kinins, all of which have bronchoconstrictor properties,<sup>11)12)</sup> suggesting that bronchoconstriction occurring with pulmonary emboli may be related to the presence of a substance whose activity or release is blocked by heparin, as evidence of bronchoconstriction in selected patients appears to represent an objective and sensitive, although nonspecific, index of PE.<sup>44-46)</sup> As discussed above, there is a broad differential diagnosis for chronic asthma. In adults, acute severe asthma is almost invariably associated with a diagnosis of chronic asthma. However, in PE, the onset of symptoms (principally breathlessness) varies from very acute (minutes) with a clear precipitant to more sluggish (days) with no clear trigger. Signs consistent with acute severe asthma include difficulty completing sentences, tachycardia, tachypnoea, and a widespread polyphonic wheeze with

oxygenation often preserved, however older patients or those with more chronic disease baseline blood gas may be abnormal and this should always be considered. In order to make a differential diagnosis, routine investigations should include appropriate blood tests, 12-lead ECG, and chest X-ray to assess the presence and/or absence of an additional acute pathology (e.g. lobar pneumonia, pneumothorax) moreover an echocardiography could be performed in order to assess RV shape and function.<sup>47)</sup>

### **Fever syndrome with or without pseudopneumonia (with or without pleural effusion)**

PE may be accompanied by fever and show evidence of pulmonary infiltrates at X-ray; in this case differential diagnosis from other diseases such as pneumonia is mandatory. The clinical features of pneumonia and PE are very different. PE has a more sudden onset, and the dyspnea is more prominent than cough and sputum. In addition, dyspnea-related PE has no radiological features and is not responsive to antibiotics with fever being a later phenomenon of the disease. Pneumonia, on the other hand, has a progressive onset with a more prominent cough, sputum, and fever that appears earlier. Usually chest pain is present in PE. Attention should be paid to young patients without obvious features of PE, and differentiation between pneumonia and PE should be carefully conducted in order to ensure timely diagnosis and appropriate treatment.<sup>48)</sup>

### **Acute right heart failure/shock/hypotension (often with epigastric pain)**

Right heart function and a hemodynamic picture play a key role in PE patient classification. The presence of hypotension is the most significant predictor of poor outcome, and defines patients with massive PE or high-risk PE. Normotensive patients with evidence of RV dysfunction, assessed by echocardiography, define the sub-massive category and are patients at intermediate risk of poor outcome.<sup>49)</sup> Shock or hypotension are present in 5–10% of PE patients with patients with myocardial injury or shock index (heart rate/systolic blood pressure [mmHg]) is  $>1$  having the worst prognosis in which a rapid diagnosis and treatment are mandatory.<sup>50)51)</sup> A physical examination of these patients is extremely important: the jugular venous pulse is often elevated with a prominent V wave, a parasternal RV heave may be palpable. On auscultation, a tricuspidal murmur with increased S2, and a right-sided S4 (in up to 25% of patients) may be present. In patients with RV failure, the ECG may show sinus tachycardia, signs of RV strain, re-polarization abnormalities, or ischemia including a complete or incomplete right bundle branch block with a right axis deviation ( $>90^\circ$ ) or S1Q3T3 pattern; other ECG features could be Qr in lead V1, ST elevation in V1, or pre-cordial T-wave inversions. T-wave inversions in the pre-cordial leads seems to correlate with both the severity of the PE and the presence of RV dysfunction with normalization being a sign of favorable outcome. Increased mortality has been shown in patients with AF, a low QRS voltage and premature ventricular contractions all reflecting the degree of RV failure and hemodynamic compromise.<sup>52)53)</sup>

The hemodynamic response to an APE depends on many factors, such as physiologic reaction to the vasoreactive substances released, the cardiopulmonary status of the patient at baseline and the size of the embolus and degree of pulmonary vasculature obstruction.<sup>54)</sup> A pulmonary vascular obstruction of  $>30\%$  has been shown to correlate with the presence of RV dysfunction on echocardiographic examination.<sup>55)</sup>

Signs of RV dysfunction with dilation on the transthoracic echocardiogram (TTE) include: 1) a ratio of RV to LV end-diastolic diameter  $>1$  in the apical four chamber view, or 2) an RV end diastolic diameter  $>30$  mm and/or loss of inspiratory collapse of the inferior vena cava.



In contrast to the global hypokinesis seen in PAH patients with RV failure, PE patients may exhibit sparing of the RV apex with hypokinesis of the RV free wall and base; a finding termed the “McConnell sign.” The McConnell sign has been shown to have a specificity of 94% and sensitivity of 77% for diagnosing PE<sup>56)</sup> echocardiographic examination can help in suggesting the presence of preexisting cardiopulmonary disease, such as chronic PAH.<sup>57)</sup>

### **Left heart failure with possible pulmonary congestion**

Cariogenic pulmonary edema in PE patients may be due to<sup>78)</sup>: 1) Occlusion of PA branch causing increased flow in the other branches causing high lung capillary pressure; and 2) compression of LV by dilated RV

Although the first scenario can be promptly diagnosed, PE in patients with pulmonary edema due to compression of LV by dilated RV can be difficult. In fact, this category of patients has a complicated clinical picture that may be impossible to solve on the basis of clinical presentation alone and without the help of technology such as echocardiography; in general, they have long standing dyspnea, bilateral pulmonary congestion at the physical examination with a dilated RV at echocardiographic examination, leading to left ventricle compression.<sup>58)59)</sup>

### **Chest pain similar to pleuritic syndrome with or without hemoptysis (with or without effusion)**

Chest pain pleuritic syndrome describes a scenario involving pulmonary infiltration and chest pain, where pain is correlated to breathing and to position; this clinical presentation is evidence of pulmonary infarction.<sup>60)61)</sup> with small distal emboli creating areas of alveolar hemorrhage, without hemodynamic relevance, resulting in hemoptysis, pleuritis, and pleural effusion which is usually mild.<sup>61)</sup>

### **Similar to ACS (with or without chest pain)**

#### *Similar to left main disease*

In some cases, a massive PE may mimic ACS, with chest pain, hypotension, tachycardia, hypoxia; ECG with ST elevation in leads augmented vector right (aVR) and V1 with ST depression in I, augmented vector left (aVL), and V4–6 with coronary angiography revealing non-obstructive coronary arteries.<sup>62)</sup> The “neglected” lead aVR overlooks the LV cavity and gives specific information regarding the RV infundibulum and basal interventricular septum. Therefore, in massive APE the ST elevations in lead aVR is frequently seen, and is associated with an overall worse prognosis. Possible reasons for the finding of ST elevations in aVR and V1 and diffuse ST depressions in the lateral leads in massive APE may be related to diffuse subendocardial ischemia, due to poor LV inflow and subsequent poor coronary blood flow as well as acute RV overload and possible RV infarct. Recognizing this pattern is extremely important in patients with acute massive PE, due to the need for prompt diagnosis and following appropriate therapy.<sup>63)64)</sup>

#### *Similar to anterior interventricular coronary disease*

##### 1) Pseudo-anterior-non-ST-segment elevation myocardial infarction (STEMI)

In patients with severe APE, a negative T wave was often observed in precordial leads (leads V1–4). However, this finding is also found in ACS due to left anterior descending CAD. Prompt differentiation between the 2 diseases is crucial for the selection of appropriate treatment. In patients with APE and ACS who have negative T wave in leads V1–4, peak negative T wave in leads V1–2 simply but accurately differentiates APE from ACS. In APE, anterior negative T is the consequence of an enlargement of the RV and may also be a sign of

RV ischemia given the fact that leads V1 and V2 face the anterior region of the RV. In addition, negative T waves in leads III are very common given the fact that lead III faces the inferior region of the RV.<sup>65)</sup> Negative T waves are also found on ECG at presentation in an appreciable number of patients with left main disease that have similar ECG findings, however in this category of patients, negative T waves are more broadly distributed around lead aVR in the limb leads and the precordial leads, with the exception of lead V1.<sup>66)</sup>

## 2) Pseudo antero-septal STEMI

ECG abnormalities are seen in 70–80% of patients with APE. Many cases of APE with ST elevation V1–V3/V4 have been described in literature.<sup>67)68)</sup> It is quite challenging to differentiate APE from anterior STEMI mainly due to fatal outcomes if STEMI is not diagnosed. However, when clinical presentation is more suggestive of APE, and ECG features are not classic for STEMI (e.g. absence of reciprocal ST deviation), prompt referral to pulmonary angiography computed tomography (CT) and timely delivery of good resolution images should be performed to expedite diagnosis in this specific instance; in this case a bedside echocardiogram looking for regional wall-motion abnormalities and evidence of RV dilation may also be useful.<sup>70)</sup> However when the clinical picture is not so clear, It become very difficult to differentiate APE with ST elevation from anterior STEMI. Several mechanisms for the development of ST-segment elevation in APE have been proposed: the development of RV transmural ischemia and infarction; with RV dilation and failure, in this picture RV is unable to generate enough systolic pressure to overcome the acute increase in after-load, leading to increased RV oxygen demand and a significant reduction of pulmonary perfusion. This, together with leftward shift of the interventricular septum, will reduce the LV preload; and the subsequent cardiac output and coronary flow; in addition hypoxia can cause severe RV transmural ischemia leading to ST-segment elevation in leads V1–V3/V4.<sup>71-73)</sup> Numerous studies of submassive and massive PE with these clinical features and no occlusive CAD have been reported.<sup>74)75)</sup> Another explanation for ST-segment elevation in leads V1–V3/V4 in APE is paradoxical coronary embolism through an atrial septal defect or PFO (which has a prevalence of 25–35% in autopsy series) in the setting of a sudden rise of right heart pressure, creating a right-to-left shunt.<sup>76-78)</sup> This suggests that initial presentation with STEMI may mask a concomitant APE and prompt recognition and treatment of both pathologies is of great importance; in fact patients with paradoxical coronary embolism may not have underlying atherosclerosis, and thrombus aspiration may be the treatment of choice.

## **PE with paradoxical embolism (clinical picture depending on site of embolization)**

PE with paradoxical embolism refers to the clinical phenomenon of thromboembolism originating in the venous vasculature and travelling through an intracardiac or pulmonary shunt into the systemic circulation.

Pulmonary hypertension and massive or sub-massive PE are the high-risk factors for paradoxical peripheral arterial embolism. PFO is the most common intracardiac shunt. The prevalence of a PFO appears to decrease with increasing age, with an incidence of 34% during the first 3 decades, 25% during the third to seventh decade, and <20% among octogenarians.<sup>79)</sup> Under physiological conditions, a pressure gradient is maintained between the left and the right atrium which results in passive closure of the PFO. In the case of increased right atrial pressure exceeding left atrial pressure, as observed at the end of Valsalva maneuvers (such as coughing, sneezing, squatting, defecation, and micturition), a transient right to left shunt may occur which may lead to presence of thrombi into the systemic circulation. A permanent increase in right-sided cardiac pressure, as observed after



PE or other causes of pulmonary arterial hypertension, may result in a significant or possibly permanent right to left inter-atrial shunt, increasing the risk of paradoxical embolism.

Additional anatomical variations are also associated with PFO:

- The Eustakian valve is an embryonic remnant of the right valve of the sinus venosus that in utero directs oxygenated venous blood from the inferior vena cava to the foramen ovale. The Eustakian valve gradually disappears after delivery in the majority of individuals, however residual prominent may direct venous blood to the fossa ovalis and cause significant right to left shunt in some individuals. PFO and residual prominent Eustakian valve are found to coexist (approximately 70% of cases), especially in patients with paradoxical embolism.<sup>80)</sup>
- The Chiari network, observed in 2–4% of the general population, is another embryonic remnant of the right valve of the sinus venosus (in the right atrium) that results from incomplete re-absorption during embryonic heart development. It is frequently associated with PFO, right to left shunt, or an atrial septal aneurysm (ASA), all of which facilitate paradoxical embolism.

All intracardiac communication, including ventricular septal defects, have a certain risk for paradoxical embolism. By contrast patients with pulmonary arteriovenous malformations have a permanent right to left shunt, permitting the passage of thrombi or septic emboli into the systemic circulation.<sup>81)</sup>

The clinical picture resulting from intracardiac communication depends on the embolisation site, and can be associated with the following:

- AMI (STEMI): Paradoxical embolism through a PFO is the most likely cause of AMI, occurring in approximately 5/1,000 patients. While this is quite a low rate, the incidence is still high enough to warrant clinical attention especially in younger patients or in the case of RV infarction.<sup>82-84)</sup>
- Stroke: Cerebro-vascular accidents constitute the most frequent relevant clinical manifestations of presumed paradoxical embolism. The cause of stroke remains unidentified by routine diagnostic testing in about 40% of patients, known as the so-called cryptogenic stroke.<sup>85)</sup> PFO is increased more than 2-fold among patients with cryptogenic stroke compared with patients with conventional causes of stroke.
- Flank pain (due to acute renal infarction, flank pain with hematuria)<sup>86)</sup>
- Acute mesenteric ischemia (acute abdomen)<sup>87)</sup>
- Lower extremity embolism: cold and pulseless extremities secondary to peripheral arterial occlusion.<sup>88)</sup> Surgical thromboembolectomy efficiently reduces mortality rate compared to conservative management with thrombolysis or anticoagulation. Pulmonary hypertension and massive or sub-massive PE are the high-risk factors for paradoxical peripheral arterial embolism. For secondary prevention of paradoxical peripheral arterial embolism, combined medical therapy can result in a significant reduction of the risk of recurrent embolic events or death.<sup>89)90)</sup>

These cases demonstrate the high index of possible paradoxical emboli due to concurrent arterial and venous embolism. A correct and prompt diagnosis is extremely important and the use of echocardiographic examinations and more sensitive trans-esophageal echocardiography and transcranial doppler (TCD) sonography have a key role<sup>91)</sup> in the detection of a right to left shunt regardless of its location.

### Syncope

Syncope is defined as a transient loss of consciousness attributable to global cerebral hypoperfusion, further characterized by rapid onset, brevity, and spontaneous recovery. It is a common reason for arrival at the emergency department (ED), accounting for approximately 1% of attendances. In the United States, 30–40% of such patients are subsequently admitted for further investigation. The prevalence of PE among patients hospitalized for syncope is not well-documented however recent studies by Duplyakov et al.<sup>66)</sup> and the German register, Management Strategy and Prognosis of Pulmonary Embolism Registry (MAPPET) showed that the rate of syncope in patients with high-risk PE was 29.9% and 35% respectively.

Three possible mechanisms of syncope in patients with PE have been proposed:

- Syncope may be caused by thrombosis of more than 50% of the lung arterial system, which leads to a significant decrease of cardiac output, followed by arterial hypotension and reduction of cerebral blood flow.
- A second mechanism causing syncope may be the activation of the vasovagal reflex. In 1867, von Bezold proposed the theory of cardiac depressor reflex, which was later completed by Jarisch. The essential point of the Bezold-Jarisch reflex is an activation of mechanoreceptors located in the left ventricle. In acute pulmonary thrombo-embolism, when an embolus lodges in a large branch of the PA, it may trigger a hyper-adrenergic state, resulting in an increase in the LV contractility with restriction of the diastolic filling. This could stimulate the ventricular mechanoreceptors (type C afferent fibers) involved in the Bezold-Jarisch reflex and lead to an increase in the efferent vagal response, causing a decrease in heart rate, a delay in AV conduction and a decrease in sympathetic tonus, resulting in peripheral vasodilation, and finally syncope.
- A third possible explanation is heart arrhythmias and conduction disturbances due to RV overload.

A history of syncope in patients with suspected PE should be considered as a possible criterion for the high risk of fatal complications during an in-hospital period.

### Complete AV block with idioventricular rhythm

Complete AV block with idioventricular rhythm can be the initial manifestation of an APE sometimes together with syncope.

In the presence of syncope during pulmonary thromboembolism due to massive embolism and Bezold-Jarisch reflex (as previously mentioned), various degrees of AV block may occur. However, complete AV block is possible in the presence of preexisting complete left bundle-branch block. In fact, in this subset of patients, complete AV-block is known to be due to the development of acute right bundle-branch block, resulting in syncope. The development of right bundle-branch block is linked to its anatomic position; in fact, the right branch of the His bundle is particularly exposed due to its superficial sub-endocardial trajectory on the RV face of the septum, and it is therefore very sensitive to a sudden distension of the right cavities.

### Persistent or paroxysm AF, atrial flutter, atrial tachycardia, PSVT

PE is often under-diagnosed for a long time because of its atypical symptoms, and the diagnosis is made only when the clinical picture is complicated by the onset of an arrhythmia that forces the patient to go to hospital. In this case the physician finds himself faced with an

arrhythmia that is the consequence of another problem that may be unrecognized,<sup>92)</sup> which is the case with AF, atrial flutter, atrial tachycardia, and PSVT.

### **DVT and silent PE**

In PE patients, clinical signs and symptoms suggesting thrombophlebitis are present in 32% of cases. However, DVT is present in 79% of cases, and if it is not present, it could mean that it has already embolized. In most patients with DVT, the clots are localized proximally with 40–50% of cases having a more complex clinical picture in which PE is present, but very often silent. Silent PE is frequent in the post-surgery phase, above all in patients without prophylaxis. APE develops 3–7 days after DVT and in 10% of cases can be fatal within 1 hour of the onset of symptoms.<sup>93)</sup>

### **Platypnea-orthodeoxia**

Platypnea-orthodeoxia is a syndrome of dyspnea and hypoxia in an upright posture (desaturation  $SO_2$ ), relieved by recumbence. Platypnea-orthodeoxia is also associated with PFOs with and without PE and with or without paradoxical embolism. Two conditions must coexist to cause this syndrome: an anatomical component in the form of an interatrial communication, and a functional component that produces a deformity in the atrial septum resulting in a redirection of shunt flow with the assumption of an upright posture. The former may be an atrial septal defect, a PFO, or a fenestrated ASA. The latter may be cardiac, such as pericardial effusion or constrictive pericarditis; pulmonary, such as emphysema, arteriovenous malformation, pneumonectomy, or amiodarone toxicity; abdominal, such as cirrhosis or ileus; or vascular, such as aortic aneurysm or elongation. Platypnea-orthodeoxia could be explained on the basis of positional modification of abnormal shunting. The upright position could stretch the interatrial communication (a PFO, atrial septal defect or a fenestrated ASA) allowing more streaming of venous blood from the inferior vena cava through the defect, whether or not a persistent Eustachian valve coexists. In the case of a PFO, the occurrence of PE creates higher left atrial pressure that may be one of the elements to explain the shunt and the platypnea orthodeoxia.<sup>94)</sup>

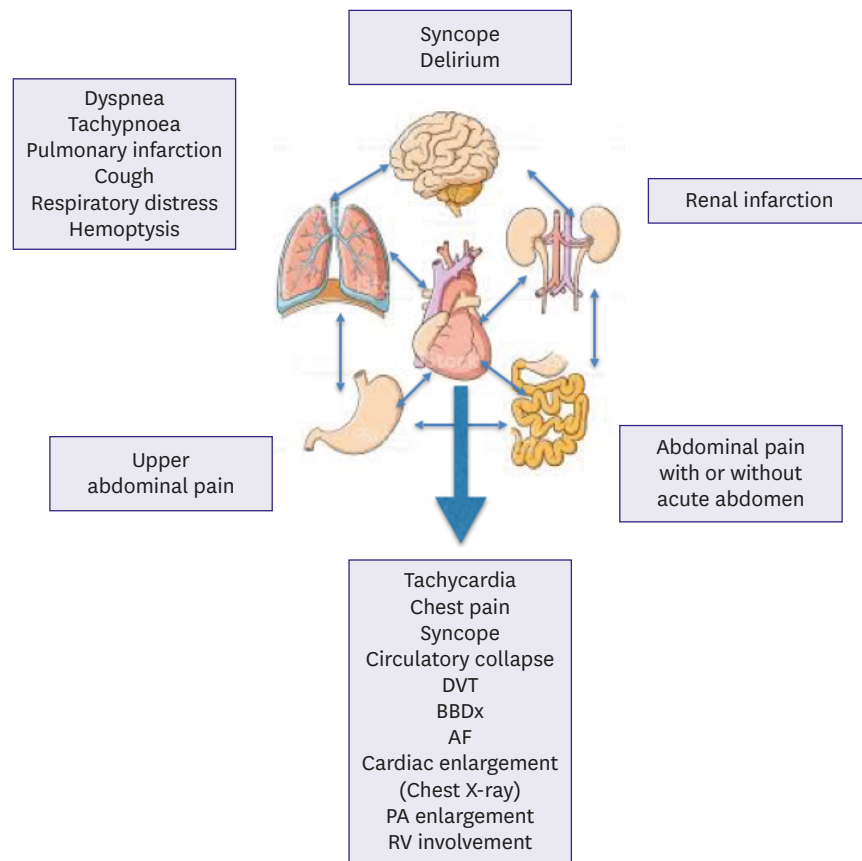
### **Abdominal pain without acute abdomen**

It is well known that a number of patients affected by hemodynamic stable PE are admitted to the ED presenting chest pain without further symptoms of PE, but in a few cases, the presenting symptoms are even more unusual: in fact, 2 cases of PE in young men evaluated in the ED for acute pain in the upper abdomen and showing basal pulmonary abnormalities consistent with PE<sup>92)</sup> have been described in literature.

### **Delirium**

Delirium, an acute confusional state, is a common, complex medical disorder associated with substantial morbidity and mortality among patients of 65 years and older. This potentially reversible cognitive disturbance is increasingly recognized as a sign of serious underlying illness. Hypoxia is a well-known precipitating factor for delirium and that PE is a common cause of hypoxia.

Therefore delirium may complicate PE in patients with other evidence of the disease. Delirium in the elderly should be regarded as an atypical presentation of PE related to the hypoxemia picture, acute ventricular impairment, hypotension, and/or paradoxical embolism that could explain this “lung-brain connection,” but the full mechanisms remain unknown.<sup>93)95)</sup>



**Figure 1.** Apparatus involvement in PE.

PE may present under several clinical pictures. Careful patient evaluation is the key role in order to do not miss the diagnosis.

AF = atrial fibrillation; BBDx = Blocco di Branca Destra; DVT = deep venous thrombosis; PA = pulmonary artery; PE = pulmonary embolism; RV = right ventricular.

## CONCLUSION

APE can be a complex interplay between several different symptoms due to the involvement of different apparatus (**Figure 1**) that can lead to a potentially life-threatening cardiovascular condition that may be difficult to diagnose; multiple team approach could be necessary to improve patient evaluation and help clinical decision-making in order to provide the best possible care; working in this direction should be our future goal.

## REFERENCES

1. Marshall PS, Mathews KS, Siegel MD. Diagnosis and management of life-threatening pulmonary embolism. *J Intensive Care Med* 2011;26:275-94.  
[CROSSREF](#)
2. Heit JA. The epidemiology of venous thromboembolism in the community. *Arterioscler Thromb Vasc Biol* 2008;28:370-2.  
[PUBMED](#) | [CROSSREF](#)
3. Cohen AT, Agnelli G, Anderson FA, et al. Venous thromboembolism (VTE) in Europe. The number of VTE events and associated morbidity and mortality. *Thromb Haemost* 2007;98:756-64.  
[PUBMED](#) | [CROSSREF](#)

4. Eurostat: Eurostat statistics on health and safety 2001 [Internet]. Luxembourg: Eurostat; 2001. Available from: [http://ec.europa.eu/eurostat/search?p\\_auth=2D3nmKEv&p\\_p\\_id=estatsearchportlet\\_WAR\\_estatsearchportlet&p\\_p\\_lifecycle=1&p\\_p\\_state=maximized&p\\_p\\_mode=view&\\_estatsearchportlet\\_WAR\\_estatsearchportlet\\_action=search&text=PULMONARY+EMBOLISM](http://ec.europa.eu/eurostat/search?p_auth=2D3nmKEv&p_p_id=estatsearchportlet_WAR_estatsearchportlet&p_p_lifecycle=1&p_p_state=maximized&p_p_mode=view&_estatsearchportlet_WAR_estatsearchportlet_action=search&text=PULMONARY+EMBOLISM).
5. Klok FA, van Kralingen KW, van Dijk AP, et al. Quality of life in long-term survivors of acute pulmonary embolism. *Chest* 2010;138:1432-40.  
[PUBMED](#) | [CROSSREF](#)
6. Fanikos J, Piazza G, Zayaruzny M, Goldhaber SZ. Long-term complications of medical patients with hospital-acquired venous thromboembolism. *Thromb Haemost* 2009;102:688-93.  
[PUBMED](#) | [CROSSREF](#)
7. Stein PD, Henry JW. Prevalence of acute pulmonary embolism among patients in a general hospital and at autopsy. *Chest* 1995;108:978-81.  
[PUBMED](#) | [CROSSREF](#)
8. Heit JA, Silverstein MD, Mohr DN, Petterson TM, O'Fallon WM, Melton LJ 3rd. Predictors of survival after deep vein thrombosis and pulmonary embolism: a population-based, cohort study. *Arch Intern Med* 1999;159:445-53.  
[PUBMED](#) | [CROSSREF](#)
9. Pichereau C, Maury E, Monnier-Cholley L, et al. Post-mortem CT scan with contrast injection and chest compression to diagnose pulmonary embolism. *Intensive Care Med* 2015;41:167-8.  
[PUBMED](#) | [CROSSREF](#)
10. Opinions regarding the diagnosis and management of venous thromboembolic disease. ACCP Consensus Committee on Pulmonary Embolism. American College of Chest Physicians. *Chest* 1998;113:499-504.  
[PUBMED](#) | [CROSSREF](#)
11. Laporte S, Mismetti P, Décousus H, et al. Clinical predictors for fatal pulmonary embolism in 15,520 patients with venous thromboembolism: findings from the Registro Informatizado de la Enfermedad TromboEmbolica venosa (RIETE) Registry. *Circulation* 2008;117:1711-6.  
[PUBMED](#) | [CROSSREF](#)
12. Tzoran I, Brenner B, Papadakis M, Di Micco P, Monreal M. VTE registry: what can be learned from RIETE? *Rambam Maimonides Med J* 2014;5:e0037.  
[PUBMED](#)
13. Goldhaber SZ, Visani L, De Rosa M. Acute pulmonary embolism: clinical outcomes in the International Cooperative Pulmonary Embolism Registry (ICOPER). *Lancet* 1999;353:1386-9.  
[PUBMED](#) | [CROSSREF](#)
14. Heit JA, Silverstein MD, Mohr DN, Petterson TM, O'Fallon WM, Melton LJ 3rd. Risk factors for deep vein thrombosis and pulmonary embolism: a population-based case-control study. *Arch Intern Med* 2000;160:809-15.  
[PUBMED](#) | [CROSSREF](#)
15. Pineda LA, Hathwar VS, Grant BJ. Clinical suspicion of fatal pulmonary embolism. *Chest* 2001;120:791-5.  
[PUBMED](#) | [CROSSREF](#)
16. Babak S, Sriram KB. Misinterpreting risk and test results delays diagnosis in a patient with pulmonary embolism. *BMJ Case Rep* 2014;2014:bcr2014204172.  
[PUBMED](#) | [CROSSREF](#)
17. Cohen AT, Edmondson RA, Phillips MJ, et al. The changing pattern of venous thromboembolic disease. *Haemostasis* 1996;26:65-71.  
[PUBMED](#)
18. Sandler DA, Martin JF. Autopsy proven pulmonary embolism in hospital patients: are we detecting enough deep vein thrombosis? *J R Soc Med* 1989;82:203-5.  
[PUBMED](#) | [CROSSREF](#)
19. Pollack CV, Schreiber D, Goldhaber SZ, et al. Clinical characteristics, management, and outcomes of patients diagnosed with acute pulmonary embolism in the emergency department: initial report of EMPEROR (Multicenter Emergency Medicine Pulmonary Embolism in the Real World Registry). *J Am Coll Cardiol* 2011;57:700-6.  
[PUBMED](#) | [CROSSREF](#)
20. Stein PD, Henry JW. Clinical characteristics of patients with acute pulmonary embolism stratified according to their presenting syndromes. *Chest* 1997;112:974-9.  
[PUBMED](#) | [CROSSREF](#)
21. Thames MD, Alpert JS, Dalen JE. Syncope in patients with pulmonary embolism. *JAMA* 1977;238:2509-11.  
[PUBMED](#) | [CROSSREF](#)
22. Islam M, Filopei J, Frank M, et al. Pulmonary infarction secondary to pulmonary embolism: an evolving paradigm. *Respirology*. 2018 [Epub ahead of print].  
[PUBMED](#) | [CROSSREF](#)

23. Jaff MR, McMurtry MS, Archer SL, et al. Management of massive and submassive pulmonary embolism, iliofemoral deep vein thrombosis, and chronic thromboembolic pulmonary hypertension: a scientific statement from the American Heart Association. *Circulation* 2011;123:1788-830.  
[PUBMED](#) | [CROSSREF](#)
24. Adabag AS, Luepker RV, Roger VL, Gersh BJ. Sudden cardiac death: epidemiology and risk factors. *Nat Rev Cardiol* 2010;7:216-25.  
[PUBMED](#) | [CROSSREF](#)
25. Zipes DP, Wellens HJ. Sudden cardiac death. *Circulation* 1998;98:2334-51.  
[PUBMED](#) | [CROSSREF](#)
26. Knight B. *Forensic pathology*. 2nd ed. London: Edward Arnold; 1996.
27. Chugh SS. Sudden cardiac death with apparently normal heart: clinical implications of progress in pathophysiology. *Card Electrophysiol Rev* 2001;5:394-402.  
[CROSSREF](#)
28. Eckart RE, Shry EA, Burke AP, et al. Sudden death in young adults: an autopsy-based series of a population undergoing active surveillance. *J Am Coll Cardiol* 2011;58:1254-61.  
[PUBMED](#) | [CROSSREF](#)
29. Lucena J, Rico A, Vázquez R, et al. Pulmonary embolism and sudden-unexpected death: prospective study on 2477 forensic autopsies performed at the Institute of Legal Medicine in Seville. *J Forensic Leg Med* 2009;16:196-201.  
[PUBMED](#)
30. Kırkcıyan I, Meron G, Behringer W, et al. Accuracy and impact of presumed cause in patients with cardiac arrest. *Circulation* 1998;98:766-71.  
[PUBMED](#) | [CROSSREF](#)
31. Beckman MG, Hooper WC, Critchley SE, Ortel TL. Venous thromboembolism: a public health concern. *Am J Prev Med* 2010;38:S495-501.  
[PUBMED](#) | [CROSSREF](#)
32. Heit JA. The epidemiology of venous thromboembolism in the community: implications for prevention and management. *J Thromb Thrombolysis* 2006;21:23-9.  
[PUBMED](#) | [CROSSREF](#)
33. Patriquin L, Khorasani R, Polak JF. Correlation of diagnostic imaging and subsequent autopsy findings in patients with pulmonary embolism. *AJR Am J Roentgenol* 1998;171:347-9.  
[PUBMED](#) | [CROSSREF](#)
34. Bharadwaj RS, Slade TB. Diagnosis of pulmonary thromboembolism in psychiatric patients. *Prim Care Companion CNS Disord* 2011;13:PCC.10101076.  
[PUBMED](#) | [CROSSREF](#)
35. Bougouin W, Marijon E, Planquette B, et al. Factors associated with pulmonary embolism-related sudden cardiac arrest. *Circulation* 2016;134:2125-7.  
[PUBMED](#) | [CROSSREF](#)
36. Roger VL, Go AS, Lloyd-Jones DM, et al. Heart disease and stroke statistics--2012 update: a report from the American Heart Association. *Circulation* 2012;125:e2-220.  
[PUBMED](#) | [CROSSREF](#)
37. Rodger MA, Carrier M, Jones GN, et al. Diagnostic value of arterial blood gas measurement in suspected pulmonary embolism. *Am J Respir Crit Care Med* 2000;162:2105-8.  
[PUBMED](#) | [CROSSREF](#)
38. Stein PD, Goldhaber SZ, Henry JW, Miller AC. Arterial blood gas analysis in the assessment of suspected acute pulmonary embolism. *Chest* 1996;109:78-81.  
[PUBMED](#) | [CROSSREF](#)
39. Geibel A, Zehender M, Kasper W, et al. Prognostic value of the ECG on admission in patients with acute major pulmonary embolism. *Eur Respir J* 2005;25:843-8.  
[PUBMED](#) | [CROSSREF](#)
40. Page IH. Serotonin (5-hydroxytryptamine); the last four years. *Physiol Rev* 1958;38:277-335.  
[PUBMED](#) | [CROSSREF](#)
41. Lewis GP. Active polypeptides derived from plasma proteins. *Physiol Rev* 1960;40:647-76.  
[PUBMED](#) | [CROSSREF](#)
42. Boyer NH, Curry JJ. Bronchospasm associated with pulmonary embolism. *Arch Intern Med (Chic)* 1944;73:403-9.  
[CROSSREF](#)
43. Xu K, Tang X, Song Y, Chen Z. The diagnostic dilemma between pulmonary embolism with positive chest imaging and pneumonia: a case report and literature review. *J Transl Med Epidemiol* 2015;3:1039.



44. Karabulut N, Kiroğlu Y. Relationship of parenchymal and pleural abnormalities with acute pulmonary embolism: CT findings in patients with and without embolism. *Diagn Interv Radiol* 2008;14:189-96.  
[PUBMED](#)
45. Duru S, Keleşoğlu A, Ardiç S. Clinical update on pulmonary embolism. *Arch Med Sci* 2014;10:557-65.  
[PUBMED](#) | [CROSSREF](#)
46. Konstantinides S. Pulmonary embolism: impact of right ventricular dysfunction. *Curr Opin Cardiol* 2005;20:496-501.  
[PUBMED](#) | [CROSSREF](#)
47. Fonarow GC, Abraham WT, Albert NM, et al. Factors identified as precipitating hospital admissions for heart failure and clinical outcomes: findings from OPTIMIZE-HF. *Arch Intern Med* 2008;168:847-54.  
[PUBMED](#) | [CROSSREF](#)
48. McMichael J. Pulmonary heart disease acute and chronic. *Br Heart J* 1948;10:80-7.
49. McIntyre KM, Sasahara AA. The hemodynamic response to pulmonary embolism in patients without prior cardiopulmonary disease. *Am J Cardiol* 1971;28:288-94.  
[CROSSREF](#)
50. Wolfe MW, Lee RT, Feldstein ML. Prognostic significance of right ventricular hypokinesis and perfusion lung scan defects in pulmonary embolism. *Am Heart J* 1994;127:1371-5.  
[PUBMED](#) | [CROSSREF](#)
51. McConnell MV, Solomon SD, Rayan ME, et al. Regional right ventricular dysfunction detected by echocardiography in acute pulmonary embolism. *Am J Cardiol* 1996;78:469-73.  
[PUBMED](#) | [CROSSREF](#)
52. Wood KE. Major pulmonary embolism: review of a pathophysiologic approach to the golden hour of hemodynamically significant pulmonary embolism. *Chest* 2002;121:877-905.  
[PUBMED](#) | [CROSSREF](#)
53. Luisada AA, Cardi L. Acute pulmonary edema; pathology, physiology and clinical management. *Circulation* 1956;13:113-35.  
[PUBMED](#) | [CROSSREF](#)
54. Harjola VP, Mebazaa A, Čelutkienė J, et al. Contemporary management of acute right ventricular failure: a statement from the Heart Failure Association and the Working Group on Pulmonary Circulation and Right Ventricular Function of the European Society of Cardiology. *Eur J Heart Fail* 2016;18:226-41.  
[PUBMED](#) | [CROSSREF](#)
55. Wolff L. Pulmonary embolism. *Circulation* 1952;6:768-76.  
[PUBMED](#) | [CROSSREF](#)
56. ESC Committee for Practice guidelines (CPG), Konstantinides SV, Torbicki A, et al. 2014 ESC Guidelines on the diagnosis and management of acute pulmonary embolism: the Task Force for the Diagnosis and Management of Acute Pulmonary Embolism of the European Society of Cardiology (ESC). *Eur Heart J* 2014;35:3033-73.  
[PUBMED](#) | [CROSSREF](#)
57. Amini R, Jyothidasan A, Poommipanit P, Kapoor D. EKG findings mimicking left main coronary disease in a patient with acute massive pulmonary embolism. *J Am Coll Cardiol* 2014;63 suppl:A699.  
[CROSSREF](#)
58. Manne JR. Acute ST segment elevation in a patient with massive pulmonary embolism mimicking acute left main coronary artery obstruction. *J Am Coll Cardiol* 2016;67:1118.
59. Ciliberti P, Rapezzi C, Villani C, Boriani G. Massive pulmonary embolism with acute coronary syndrome-like electrocardiogram mimicking acute left main coronary artery obstruction. *J Emerg Med* 2012;43:e255-8.  
[PUBMED](#)
60. Kosuge M, Ebina T, Hibi K, et al. Simple electrocardiographic criteria for discriminating between acute pulmonary embolism and acute coronary syndrome. *J Am Coll Cardiol* 2016;67:528.  
[CROSSREF](#)
61. Kosuge M, Ebina T, Hibi K, et al. Differences in negative T waves among acute coronary syndrome, acute pulmonary embolism, and Takotsubo cardiomyopathy. *Eur Heart J Acute Cardiovasc Care* 2012;1:349-57.  
[PUBMED](#) | [CROSSREF](#)
62. Yaméogo NV, Mbaye A, Kagambèga LJ, et al. Pulmonary embolism mimicking acute anterior myocardial infarction: diagnostic trap. *Ann Cardiol Angeiol (Paris)* 2011;60:169-72.  
[PUBMED](#) | [CROSSREF](#)
63. Falterman TJ, Martinez JA, Daberkow D, Weiss LD. Pulmonary embolism with ST segment elevation in leads V1 to V4: case report and review of the literature regarding electrocardiographic changes in acute pulmonary embolism. *J Emerg Med* 2001;21:255-61.  
[PUBMED](#) | [CROSSREF](#)

64. Omar HR. ST-segment elevation in V1-V4 in acute pulmonary embolism: a case presentation and review of literature. *Eur Heart J Acute Cardiovasc Care* 2016;5:579-86.  
[PUBMED](#) | [CROSSREF](#)
65. Mittal SR, Maheshwari M. Electrocardiographic changes in submassive pulmonary embolism. *Indian Heart J* 2005;57:80-1.  
[PUBMED](#)
66. Duplyakov D, Kurakina E, Pavlova T, et al. Value of syncope in patients with high-to-intermediate risk pulmonary artery embolism. *Eur Heart J Acute Cardiovasc Care* 2015;4:353-8.  
[PUBMED](#) | [CROSSREF](#)
67. Jenab Y, Lotfi-Tokaldany M, Alemzadeh-Ansari MJ, et al. Correlates of syncope in patients with acute pulmonary thromboembolism. *Clin Appl Thromb Hemost* 2015;21:772-6.  
[PUBMED](#) | [CROSSREF](#)
68. Yamaki T, Nozaki M, Sakurai H, et al. Presence of lower limb deep venous thrombosis and prognosis in patients with symptomatic pulmonary embolism: preliminary report. *Eur J Vasc Endovasc Surg* 2009;37:225-31.  
[PUBMED](#) | [CROSSREF](#)
69. Jiménez D, Aujesky D, Díaz G, et al. Prognostic significance of deep vein thrombosis in patients presenting with acute symptomatic pulmonary embolism. *Am J Respir Crit Care Med* 2010;181:983-91.  
[PUBMED](#) | [CROSSREF](#)
70. Lin JF, Li YC, Yang PL. A case of massive pulmonary embolism with ST elevation in leads V1-4. *Circ J* 2009;73:1157-9.  
[PUBMED](#) | [CROSSREF](#)
71. Mittal SR, Arora H. Pulmonary embolism with isolated right ventricular infarction. *Indian Heart J* 2001;53:218-20.  
[PUBMED](#)
72. Mittal SR, Jain S, Maheshwari S. Pulmonary embolism with isolated right ventricular infarction. *Indian Heart J* 1996;48:704-6.  
[PUBMED](#)
73. Jerjes Sánchez C, Gutiérrez-Fajardo P, Ramírez-Rivera A, et al. Acute infarct of the right ventricle secondary to a massive pulmonary thromboembolism. *Arch Inst Cardiol Mex* 1995;65:65-73.  
[PUBMED](#)
74. Olivares-Reyes A, Chan S, Lazar EJ, Bandlamudi K, Narla V, Ong K. Atrial septal aneurysm: a new classification in two hundred five adults. *J Am Soc Echocardiogr* 1997;10:644-56.  
[CROSSREF](#)
75. Kleber FX, Hauschild T, Schulz A. Paradoxical embolic myocardial infarction. *J Am Coll Cardiol* 2014;64:TCT-163.
76. Wąsek WC, Samul W, Ryczek R, Skrobowski A. Unique case of ST-segment-elevation myocardial infarction related to paradoxical embolization and simultaneous pulmonary embolization: clinical considerations on indications for patent foramen ovale closure in no-guidelines land. *Circulation* 2015;131:1214-23.  
[PUBMED](#) | [CROSSREF](#)
77. Yildiz A, Bostan C, Akin F, Arat Ozkan A, Gurmen T. Concurrent pulmonary embolism and acute coronary syndrome with dynamic electrocardiographic changes. *Am J Emerg Med* 2012;30:637.e1-637.e4.
78. Windecker S, Stortecky S, Meier B. Paradoxical embolism. *J Am Coll Cardiol* 2014;64:403-15.  
[PUBMED](#) | [CROSSREF](#)
79. Carey HB, Boltax R, Dickey KW, Finkelstein FO. Bilateral renal infarction secondary to paradoxical embolism. *Am J Kidney Dis* 1999;34:752-5.  
[PUBMED](#) | [CROSSREF](#)
80. Vicente DC, Kazmers A. Acute mesenteric ischemia. *Curr Opin Cardiol* 1999;14:453-8.  
[PUBMED](#) | [CROSSREF](#)
81. Loscalzo J. Paradoxical embolism: clinical presentation, diagnostic strategies, and therapeutic options. *Am Heart J* 1986;112:141-5.  
[PUBMED](#) | [CROSSREF](#)
82. Wei F, Zhang Y, Tian H, Zhang J, Ma Q. Pulmonary hypertension and massive or sub-massive pulmonary embolism are the high risk factors for paradoxical peripheral arterial embolism. *J Am Coll Cardiol* 2016;68:C154.  
[CROSSREF](#)
83. Akrawinthewong K, Damrongwatanasuk R, Abuzahra M. Acute limb ischemia and silent pulmonary emboli as a key to identify thrombus-in-transit through patent foramen ovale. *J Am Coll Cardiol* 2016;67:1194.

84. Konstantinides S, Geibel A, Kasper W, Olschewski M, Blümel L, Just H. Patent foramen ovale is an important predictor of adverse outcome in patients with major pulmonary embolism. *Circulation* 1998;97:1946-51.  
[PUBMED](#) | [CROSSREF](#)
85. Di Tullio M, Sacco RL, Venketasubramanian N, Sherman D, Mohr JP, Homma S. Comparison of diagnostic techniques for the detection of a patent foramen ovale in stroke patients. *Stroke* 1993;24:1020-4.  
[PUBMED](#) | [CROSSREF](#)
86. Pinto FJ. When and how to diagnose patent foramen ovale. *Heart* 2005;91:438-40.  
[PUBMED](#) | [CROSSREF](#)
87. Prandoni P, Lensing AW, Prins MH, et al. Prevalence of pulmonary embolism among patients hospitalized for syncope. *N Engl J Med* 2016;375:1524-31.  
[PUBMED](#)
88. Kearon C. Natural history of venous thromboembolism. *Circulation* 2003;107:122-30.  
[PUBMED](#)
89. Varkul M, Robinson T, Ng E, Hyland R. Orthodeoxia and platypnea secondary to a patent foramen ovale despite normal right-sided cardiac pressures. *Can Respir J* 2001;8:105-7.  
[PUBMED](#) | [CROSSREF](#)
90. Sentjens RE, Houtman S, Meijerink MR, Konings TC. Emboli on the move. *J Crit Care* 2010;14:399-401.
91. Giorgi-Pierfranceschi M, Cattabiani C, Mumoli N, Dentali F. Abdominal pain as pulmonary embolism presentation, usefulness of bedside ultrasound: a report of two cases. *Blood Coagul Fibrinolysis* 2017;28:107-111.  
[PUBMED](#)
92. Inouye SK. Delirium in older persons. *N Engl J Med* 2006;354:1157-65.  
[PUBMED](#) | [CROSSREF](#)
93. Laack TA, Goyal DG. Pulmonary embolism: an unsuspected killer. *Emerg Med Clin North Am* 2004;22:961-83.  
[PUBMED](#) | [CROSSREF](#)
94. Søgaard KK, Schmidt M, Pedersen L, Horváth-Puhó E, Sørensen HT. 30-year mortality after venous thromboembolism: a population-based cohort study. *Circulation* 2014;130:829-36.  
[PUBMED](#) | [CROSSREF](#)
95. Carrascosa MF, Batán AM, Novo MF. Delirium and pulmonary embolism in the elderly. *Mayo Clin Proc* 2009;84:91-2.  
[PUBMED](#) | [CROSSREF](#)