

Ragged cuticles and erythematous hands and feet in a pediatric patient with chronic diarrhea



Andraia R. Li, BS,^a Kimberly B. Hashemi, MD,^a Katherine Silver, MD,^b and Lara Wine Lee, MD, PhD^{a,c}
Charleston, South Carolina

Key words: autoimmune skin disease; collagenous colitis; connective tissue disease; erythromelalgia; juvenile dermatomyositis; nailfold changes.

INTRODUCTION

Erythromelalgia (EM) is a chronic syndrome characterized by the triad of erythema, warmth, and severe, recurrent pain in the distal extremities.¹ EM affects 1.3 per 100,000 persons each year and is exceedingly rare in children and adolescents.² Common triggers include increased environmental temperatures and exertion. Primary EM is idiopathic or inherited, but secondary EM is associated with numerous comorbid conditions, including autoimmune and myeloproliferative disorders.¹ Here, we describe a case of EM where examination of abnormal nailfold changes raised suspicion for underlying autoimmune disease and led to the diagnosis of juvenile amyopathic dermatomyositis (ADM) with collagenous colitis.

CASE DESCRIPTION

A 15-year old boy presented for evaluation of new-onset burning and tingling accompanied by transient erythema of his hands and feet provoked by exercise (Fig 1) and relieved with rest. His findings were consistent with EM. He was previously evaluated by gastroenterology for a 1-year history of diarrhea with an unremarkable workup. He denied rashes elsewhere, joint pain, muscle weakness, fatigue, and sun sensitivity. A full-body skin examination identified periungual erythema, ragged cuticles, erythema over the metacarpophalangeal joints, livedo pattern over his dorsal hands, and abnormal nailfold changes on dermatoscopy (Figs 2 and 3). His strength examination was normal. These findings raised suspicion that his EM was secondary to an

Abbreviations used:

ADM:	amyopathic dermatomyositis
DM:	dermatomyositis
EM:	erythromelalgia
IBD:	inflammatory bowel disease
IDA:	iron deficiency anemia
NFC:	nailfold capillaroscopy

underlying connective tissue disorder, specifically dermatomyositis (DM). Laboratory workup revealed a positive antinuclear antibody >1:2560 with both homogeneous and speckled patterns present and a positive SSA of 1.2 (normal value, ≤ 0.9 AU). His creatine kinase (normal range, 30-260 U/L) and aldolase (normal value, <14.5 U/L) were within normal limits. The patient was referred to rheumatology for a multidisciplinary approach as he now had swelling of multiple metacarpophalangeal joints and proximal interphalangeal joints with a limited ability to make a tightly closed fist. Myositis panel (MyoMarker 3 Plus Profile, Mayo Clinic Laboratories) revealed a positive TIF-1- γ and weakly positive Mi-2, ku, and PM/Scl, consistent with the diagnosis of juvenile DM, again considered amyopathic given his normal strength and creatine kinase.

Review of the workup previously done for the patient's chronic diarrhea identified iron deficiency anemia (IDA) and a slightly elevated fecal calprotectin. Given his ongoing diarrhea and new diagnosis of ADM, which is associated with an increased risk of concomitant autoimmune disease, suspicion for inflammatory bowel disease (IBD) was much

From the Department of Dermatology and Dermatologic Surgery,^a and the Department of Medicine^b and Department of Pediatrics, Medical University of South Carolina.^c

Funding sources: None.

IRB approval status: Not applicable.

This has case been presented at the Congress of Clinical Dermatology meeting June 2021.

Correspondence to: Lara Wine Lee, MD, PhD, 135 Rutledge Avenue, Charleston, SC 29425. E-mail: winelee@muscu.edu.

JAAD Case Reports 2022;22:18-20.

2352-5126

© 2022 Published by Elsevier on behalf of the American Academy of Dermatology, Inc. This is an open access article under the CC BY-NC-ND license (<http://creativecommons.org/licenses/by-nc-nd/4.0/>).

<https://doi.org/10.1016/j.jidcr.2021.12.031>

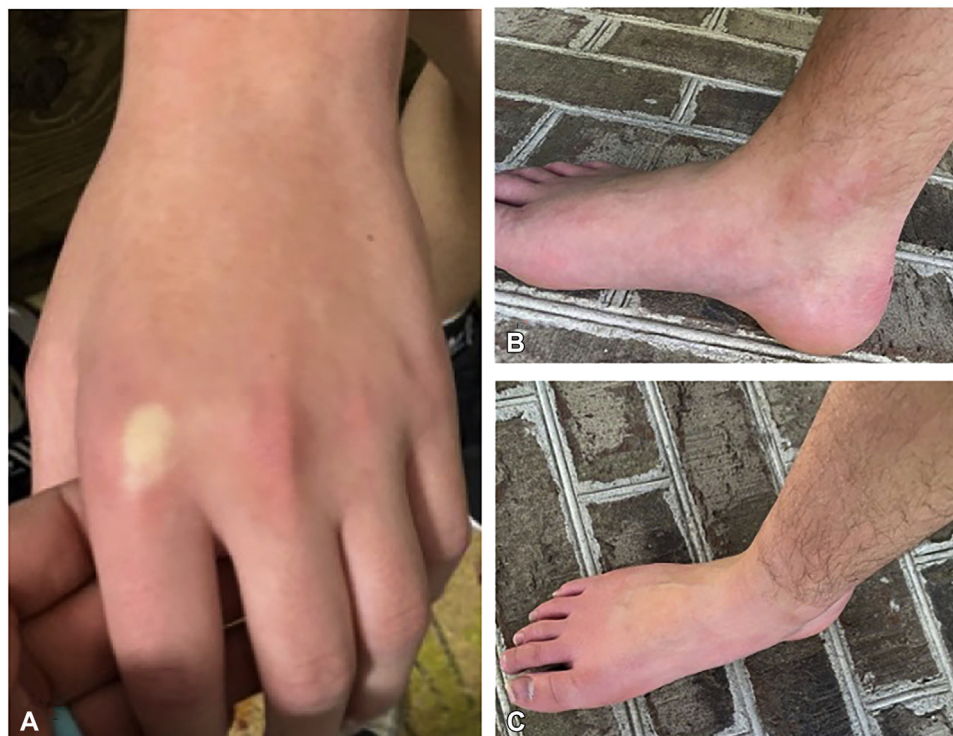

Fig 1. Blanching erythema overlying the dorsal surface of the hands and feet. Given the transient nature of EM, we did not have an opportunity to observe the changes. Clinical images courtesy of family, representative of the patient's less progressive erythromelalgia episodes.

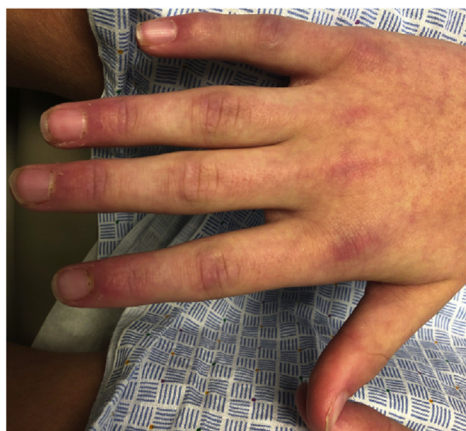

Fig 2. Notable periungual erythema, ragged cuticles, and livedo pattern on the dorsal hand with erythema overlying the metacarpophalangeal joints and swelling of the proximal interphalangeal joints.

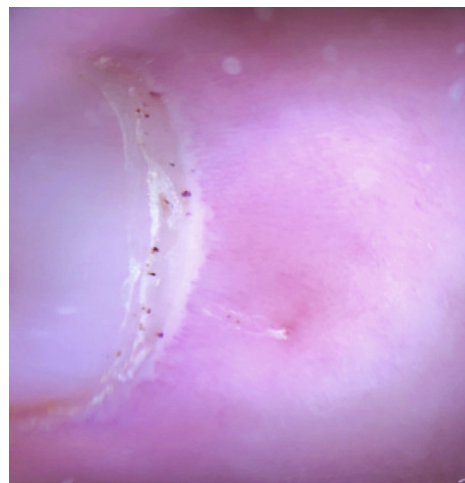


Fig 3. Dermatoscopy showing abnormal nailfold changes with microhemorrhages and hemosiderin deposits.

higher. The IBD panel (IBD sgi Diagnostic, Prometheus), a test that identifies seromarkers commonly found in IBD, was suggestive of Crohn's disease. Colonoscopy showed minimal inflammation, and colonic biopsies were consistent with collagenous colitis. Biopsies of the terminal ileum showed a focal area of ileitis, but the remainder of the ileal biopsies were unremarkable, and thus the patient was thought not to have Crohn's disease. The

patient was treated with adalimumab with the goal of using one agent to target his inflammatory arthritis, ADM, and collagenous colitis. His diarrhea and cutaneous manifestations of ADM resolved, and his EM and arthritis improved with treatment.

In summary, the patient presented with EM and chronic diarrhea. Subtle findings limited to his hands, notably on bedside nailfold capillaroscopy

(NFC), raised suspicion for an underlying autoimmune disease, prompting further workup and ultimately a diagnosis of EM, inflammatory arthritis, and collagenous colitis, all occurring in the setting of juvenile ADM.

DISCUSSION

Juvenile ADM, EM, and collagenous colitis are rare diseases in pediatric patients, the latter two exceedingly so, with coexistence previously unreported. EM is a clinical syndrome characterized by redness, pain, and warmth of distal extremities that primarily affects the hands and feet.¹ The onset of EM may be acute or gradual, with symptoms remaining mild for months to years.¹ Secondary EM is associated with myeloproliferative disorders but may also signal an underlying autoimmune disease, including DM.^{1,3} Juvenile ADM, in which children present with the cutaneous manifestations of DM without muscle involvement, is estimated to occur in 5% to 20% of cases of juvenile DM.⁴ Although ADM is associated with an increased prevalence of interstitial lung disease than classic DM in adults, there is less evidence of this relationship in children.⁴ Anti-TIF-1- γ is the most commonly occurring autoantibody in juvenile DM and is associated with severe cutaneous disease and photosensitivity.⁵ Preliminary data suggest that adults with DM may be at an increased risk for microscopic colitis, but it is unknown if this relationship holds true in children.⁶ As a subset of microscopic colitis, collagenous colitis is a chronic inflammatory condition characterized by thickened subepithelial deposition of collagen on histopathology.⁷ The most common presentations of collagenous colitis in children include chronic diarrhea and recurrent abdominal pain, with IDA observed in approximately 90% of cases.⁷ There are reported cases of IBD preceding the development of collagenous colitis, with some experts suggesting that microscopic colitis may be part of the IBD continuum.⁸

The rarity and nonspecific presentation of these immune-mediated pathologies may make the initial diagnosis difficult. NFC is a noninvasive technique used to visualize nailfold capillaries. The presence of capillary abnormalities on NFC is highly specific for autoimmune diseases.⁹ Pathologic capillaroscopic patterns were observed in up to 90% of cases of systemic sclerosis.⁹ The benefit of NFC is that it is an inexpensive point-of-care assessment that can be performed using a variety of devices.¹⁰ For example, ophthalmoscopes and dermatoscopes are affordable and accessible but only confer a 10 \times to 40 \times magnification.¹⁰ Videocapillaroscopes are significantly more expensive, but provide excellent

resolution with a magnification of 200 \times to 600 \times .¹⁰ Nonetheless, all of these modalities allow for the assessment of gross nailfold changes.

Although the absence of pathologic features does not rule out autoimmune disease, the presence of capillary abnormalities increases the suspicion for a concomitant pathology. In our case, the presence of abnormal nailfold changes suggested that an additional autoimmune component may be responsible for this patient's cutaneous manifestations. This, in the setting of chronic diarrhea, IDA, and elevated fecal calprotectin, led to further IBD testing and ultimately to the diagnosis of collagenous colitis. Thus, diminutive nailfold changes on capillaroscopy may aid in the diagnosis of autoimmune diseases, especially in patients with nonspecific or mild symptoms, and may lead to an earlier referral, diagnosis, and treatment of this population.

Conflicts of interest

None disclosed.

REFERENCES

- Cohen JS. Erythromelalgia: new theories and new therapies. *J Am Acad Dermatol*. 2000;43(5):841-847. <https://doi.org/10.1067/mjd.2000.109301>
- Reed KB, Davis MD. Incidence of erythromelalgia: a population-based study in Olmsted County, Minnesota. *J Eur Acad Dermatol Venereol*. 2009;23(1):13-15. <https://doi.org/10.1111/j.1468-3083.2008.02938.x>
- Grinnell M, Keyes E, Wat M, et al. Erythromelalgia associated with dermatomyositis: a case series. *JAAD Case Rep*. 2021;16:37-40. <https://doi.org/10.1016/j.jidcr.2021.07.035>
- Javadi Parvaneh V, Yasaei M, Rahmani K, Nilipour Y. Juvenile clinically amyopathic dermatomyositis: a case report and review of literature. *Iran J Child Neurol*. 2019;13(3):113-120.
- Pachman LM, Khojah AM. Advances in juvenile dermatomyositis: myositis specific antibodies aid in understanding disease heterogeneity. *J Pediatr*. 2018;195:16-27. <https://doi.org/10.1016/j.jpeds.2017.12.053>
- Pearson DR, Werth VP. Relative risk of microscopic colitis in dermatomyositis. *J Am Acad Dermatol*. 2019;81(5):1188-1190. <https://doi.org/10.1016/j.jaad.2019.03.045>
- Matta J, Alex G, Cameron DJS, Chow CW, Hardikar W, Heine RG. Pediatric collagenous gastritis and colitis: a case series and review of the literature. *J Pediatr Gastroenterol Nutr*. 2018;67(3):328-334. <https://doi.org/10.1097/MPG.0000000000001975>
- Saad RE, Shobar RM, Jakate S, Mutlu EA. Development of collagenous colitis in inflammatory bowel disease: two case reports and a review of the literature. *Gastroenterol Rep (Oxf)*. 2019;7(3):218-222. <https://doi.org/10.1093/gastro/gox026>
- Lambova S, Hermann W, Muller-Ladner U. Nailfold capillaroscopy—its role in diagnosis and differential diagnosis of microvascular damage in systemic sclerosis. *Curr Rheumatol Rev*. 2013;9(4):254-260. <https://doi.org/10.2174/157339710904140417125241>
- Karbalaie A, Emrani Z, Fatemi A, Etehadtavakol M, Erlandsson BE. Practical issues in assessing nailfold capillaroscopic images: a summary. *Clin Rheumatol*. 2019;38(9):2343-2354. <https://doi.org/10.1007/s10067-019-04644-9>