



OPEN ACCESS

CASE REPORT

Spontaneous acalculous gallbladder perforation post-cardiac transplantation

Candice Sagi,¹ Jayshree Lavana,² Robert Franz,³ Ambika Bhasin¹

¹Department of Medical Imaging, The Prince Charles Hospital, Chermide, Queensland, Australia

²Department of Intensive Care, The Prince Charles Hospital, Chermide, Queensland, Australia

³Department of General Surgery, The Prince Charles Hospital, Brisbane, Queensland, Australia

Correspondence to

Dr Candice Sagi,
candice.sagi@health.qld.gov.au

Accepted 28 April 2018

SUMMARY

Spontaneous acalculous gallbladder perforation is a rare radiological and clinical phenomenon with life-threatening consequences. In the setting of recent cardiac transplantation, the condition is increasingly uncommon and difficult to diagnose preoperatively. We describe a case of spontaneous acalculous gallbladder perforation in an intensive care unit (ICU) patient, most likely due to a combination of cardiac transplantation and immunosuppression. There are no such documented cases in the literature with an established preoperative diagnosis, to the best of our knowledge. Abdominal CT and targeted ultrasound proved complimentary in establishing the diagnosis, facilitating successful and timely treatment with urgent cholecystectomy.

BACKGROUND

Spontaneous acalculous gallbladder perforation is a rare but catastrophic phenomenon in critically ill and immunosuppressed patients. Mortality associated with gallbladder perforation is often confounded by delayed diagnosis. Radiology plays a key role in identifying this condition and facilitates timely surgical intervention.

CASE PRESENTATION

A 45-year-old man underwent cardiac transplantation in 2016 for ischaemic cardiomyopathy at a tertiary hospital specialising in cardiothoracic medicine in Brisbane, Australia. Relevant medical history included atrial fibrillation/flutter, hypertension, dyslipidaemia and depression.

A routine cardiac biopsy on day 14 after transplantation had revealed mild rejection while on a standard immunosuppression regimen of tacrolimus, mycophenolate mofetil and prednisolone. Immunosuppressive doses were accordingly adjusted. On day 35, worsening rejection was clinically suspected due to the development of first-degree and second-degree heart block, necessitating treatment with isoprenaline. An empirical pulse treatment with methylprednisolone 1000 mg daily for three doses was also given, and the daily prednisolone dose was increased from 30 mg to 80 mg daily. Tacrolimus was continued at 3 mg twice a day and mycophenolate mofetil at 1500 mg twice a day.

The patient's postoperative ICU course was complicated by recurrent sepsis, dialysis-dependent acute kidney injury (AKI), haemopericardium and peripheral limb ischaemia, necessitating below-knee amputation at day 30.

At day 40 post-transplant, while on the aforementioned immunosuppressive regimen, the patient was investigated for severe upper abdominal pain while weaning from mechanical ventilation in ICU.

INVESTIGATIONS

The patient's haemoglobin had reduced from 101 g/L to 88 g/L. White cell count was elevated to $31 \times 10^9/L$, and platelets reduced to $95 \times 10^9/L$. Bilirubin was elevated to 41 $\mu\text{mol/L}$, with a markedly raised gamma-GT of 1090 U/L, alkaline phosphatase of 512 U/L and moderately raised transaminases.

Non-contrast CT abdomen (in light of AKI) demonstrated hyperdense haemobilia (~75 HU) within the gallbladder lumen and haemoperitoneum within the right paracolic gutter and pelvis. The fundal gallbladder wall could not be discerned (figure 1A–D). Subsequently, abdominal ultrasound confirmed the presence of contiguous haematoma within the gallbladder lumen into the peritoneum, across a defect within the gallbladder fundus (figure 2A–D).

TREATMENT

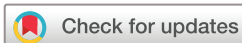Within hours of the investigations, the patient underwent emergency laparoscopic cholecystectomy and abdominal washout. At surgery, the gallbladder was found to be necrotic and perforated, with moderate-volume haemoperitoneum (figure 3A,B).

OUTCOME AND FOLLOW-UP

Towards completion of the surgery, the patient became bradycardic with eventual loss of cardiac output. Resuscitation was successful with chest compressions and an epinephrine infusion. Follow-up ultrasound after 9 days demonstrated no collection or biliary obstruction.

A protracted recovery in intensive care ensued, complicated by an episode of cardiac arrest requiring automated implantable cardioverter-defibrillator (AICD) insertion, fungal infective endocarditis, post-transplant lymphoproliferative disorder and pulmonary embolism. The patient was discharged from ICU after 75 days to inpatient rehabilitation, but required readmission to ICU and the cardiology ward for episodes of sepsis and hypotension. AKI had resolved during admission.

He returned home following physical rehabilitation at 8 months post-transplant, and at the time of this report, the patient continues to live in the community with an ongoing antirejection regimen of



To cite: Sagi C, Lavana J, Franz R, et al. *BMJ Case Rep* Published Online First: [please include Day Month Year]. doi:10.1136/bcr-2017-223195

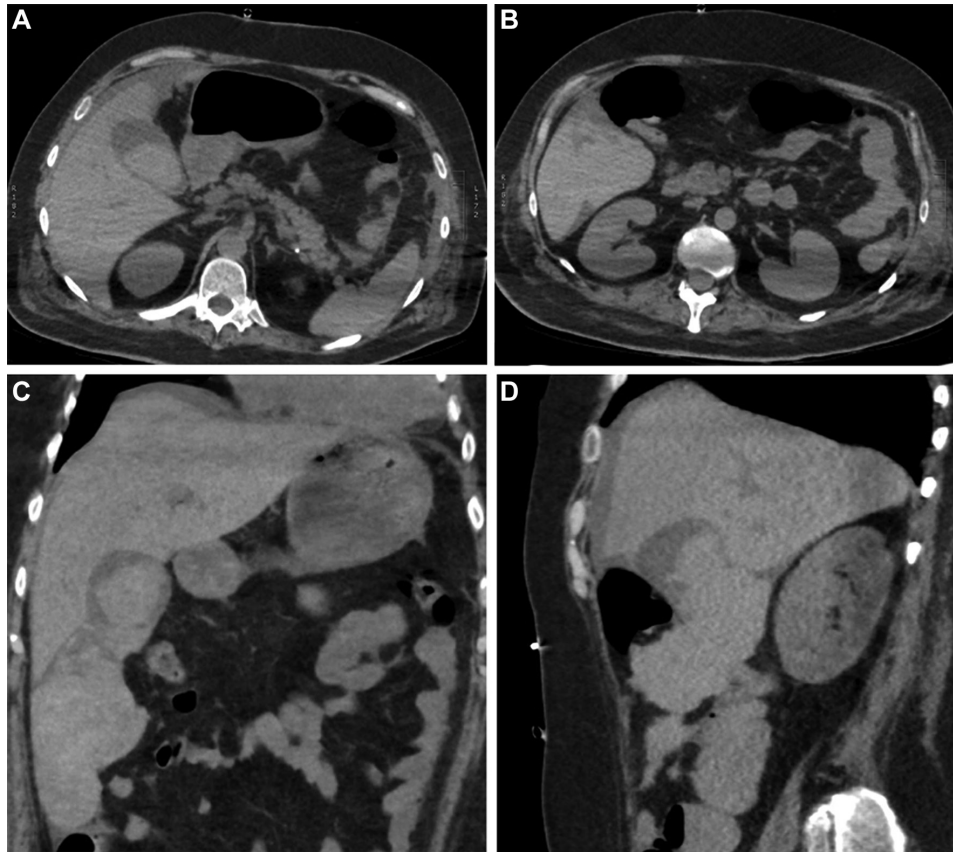


Figure 1 (A–D) Non-contrast helical CT abdomen in a 45-year-old male patient with abdominal pain, day 40 post-cardiac transplantation.

everolimus, tacrolimus and prednisolone. The patient is receiving ongoing physiotherapy and occupational therapy in the community, for consideration of lower limb prostheses. No long-term sequelae of gallbladder perforation have been encountered.

DISCUSSION

In critically ill patients with ICU admissions over 2 days, the documented incidence of acalculous cholecystitis (ACC) is 0.2%–0.4%. Immunosuppression and prolonged ICU

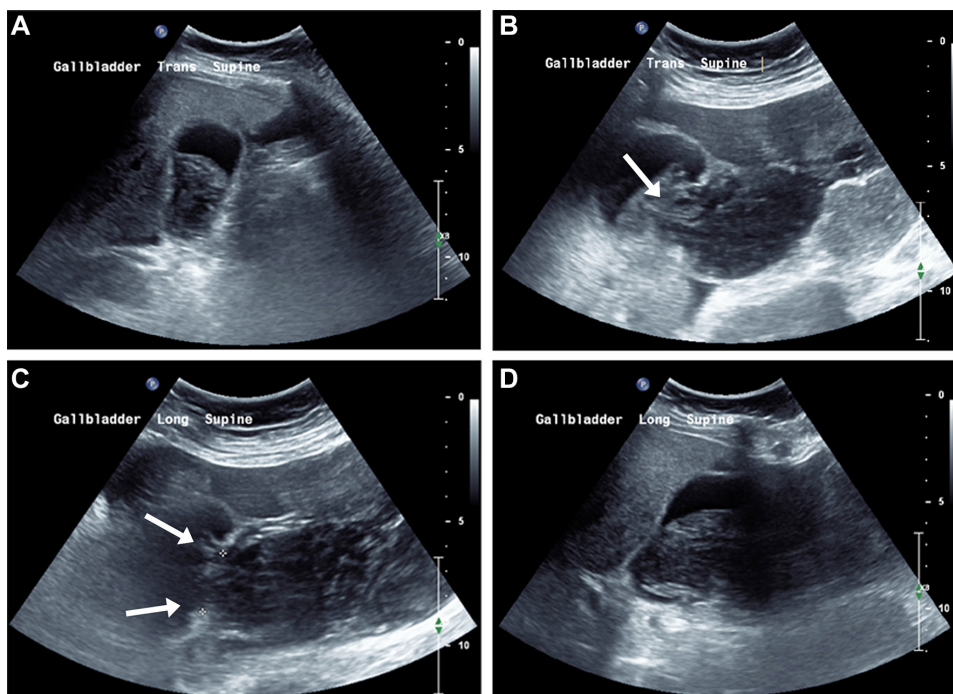


Figure 2 (A–D) Targeted upper abdominal ultrasound demonstrating contiguous haemobilium and haemoperitoneum, across a defect within the gallbladder fundus (arrows).

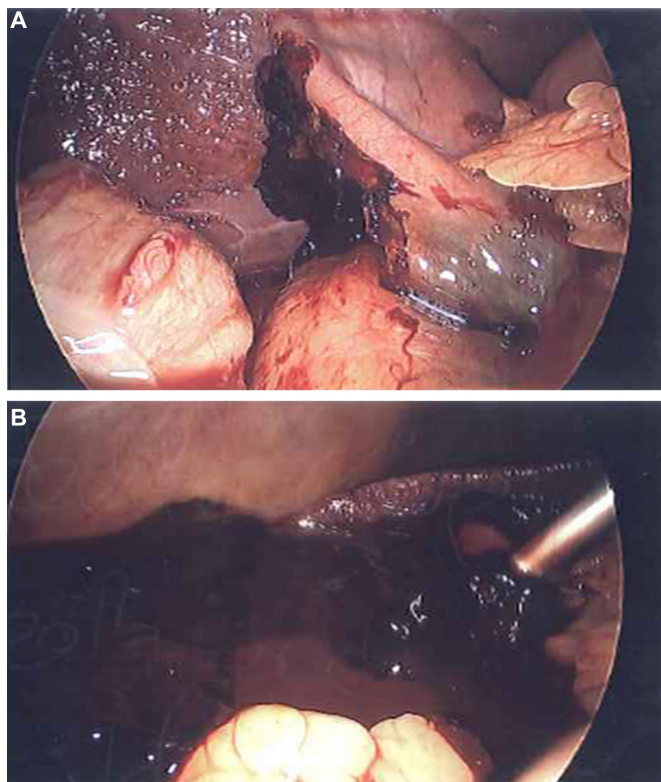


Figure 3 (A–B) Intraoperative photographs demonstrating a necrotic and perforated gallbladder, with moderate-volume haemoperitoneum.

stay further increases the risk and, if untreated, may lead to perforation and fatal outcomes. The mortality rate of ACC is commonly documented at 30%, with a range of 10% with early diagnosis, to 90% with delayed diagnosis.¹ Furthermore, the risk of morbidity and mortality in cardiac transplant patients with acute cholecystitis (calculous and acalculous) has been shown to be elevated, predominantly in the immediate postoperative period.²

Likewise, gallbladder perforation is associated with significant morbidity and mortality, with a median mortality rate of 10% from a previous systematic review.³ Its incidence ranges from 0.8% to 11%.^{4,5} More commonly, gallbladder perforation is seen in the setting of complicated calculous cholecystitis.³ Spontaneous acalculous perforation, on the other hand, is rare.

Cases of gallbladder perforation have been previously documented in the context of steroid therapy,^{5,6} peritoneal dialysis⁷ and diabetic or elderly patients.^{5,8–10} We report a case of spontaneous Niemeier type 1¹¹ perforation in a patient 40 days post-cardiac transplantation. Pancreaticobiliary disease has been reported to occur 17.4 times more frequently in cardiac transplant recipients than the general population.¹² Factors likely contributing to perforation in this patient were (1) surgical vagotomy at the time of transplantation, leading to gallbladder dysmotility and stasis; (2) gallbladder ischaemia due to ischaemic cardiomyopathy, during transplantation, and in the post-transplant period during episodes of rejection; (3) immunosuppression during steroid administration; and (4) prolonged ICU stay complicated by sepsis, AKI and peripheral limb ischaemia requiring below-knee amputation.

In the context of immunosuppression, mechanical ventilation and sedation, the classical signs of ACC—fever, positive Murphy's sign, right hypochondriac tenderness and guarding—were

masked in this patient. The non-specific pattern of hepatic enzyme derangement was likely attributed to the combination of cholestatic disease and polypharmacy, reducing their value in the diagnostic process. Submitting a cardiac transplant patient with multiple comorbidities to abdominal surgery without prior radiology work-up to exclude non-surgical causes was not considered as an option by the surgical team. For this reason, non-contrast CT was implemented as the first-line modality to identify a likely source of sepsis and exclude non-surgical causes of abdominal pain prior to further targeted investigation and exploratory surgery.

Abdominal CT demonstrated hyperdense haemobilia (75 HU) within the gallbladder lumen, and contiguous hyperdense haematoma in the right paracolic gutter, with low-density fluid within the pelvis. This sentinel clot sign¹³ within and adjacent to the gallbladder raised suspicion of gallbladder perforation. Other diagnostic considerations were synchronous haemobilia and haemoperitoneum, secondary to coagulopathy or underlying vascular rupture. No radiodense calcified gallstone was demonstrated.

Targeted upper abdominal ultrasound was organised immediately following the CT scan. This proved pivotal in confirming the diagnosis of acalculous gallbladder perforation, with demonstration of the gallbladder wall defect and traversing haematoma on high-resolution cine view, and longitudinal and transverse images.

Diagnostic imaging provided a roadmap for aiding the surgical team in the decision to pursue operative management in an immunosuppressed, post-cardiac transplant patient, despite the inconclusive clinical picture. Surgical findings concurred with the radiological diagnosis, and the patient was managed successfully with emergency cholecystectomy.

ACC remains a condition commonly dealt with by abdominal surgeons. Where the clinical diagnosis of ACC is clear-cut, ultrasound may be sufficient for confirmation in haemodynamically stable patients.² However, cardiac transplantation and its mandated immunosuppression made the diagnosis of this easily identifiable condition difficult due to the absence of characteristic clinical signs and inconclusive biochemical tests. Radiology provided a crucial role in identifying the development of gallbladder perforation, thus avoiding a fatal outcome in this patient.

Learning points

- ▶ Spontaneous acalculous gallbladder perforation is a rare but catastrophic complication of acalculous cholecystitis (ACC) in critically ill and immunosuppressed post-transplant patients. Mortality associated with gallbladder perforation is often confounded by delayed diagnosis, as characteristic clinical features of ACC may be masked.
- ▶ Abdominal CT and ultrasound are complimentary in identifying spontaneous perforation, resolving diagnostic dilemma and facilitating timely life-saving intervention.
- ▶ On abdominal CT, the presence of hyperdense clotted haemorrhage on either side of the gallbladder (sentinel clot sign) is highly suspicious for gallbladder perforation in the acute abdomen.
- ▶ Targeted abdominal ultrasound may be used for detailed visualisation of the gallbladder wall defect, as well as confirming the presence of haemobilia or haemoperitoneum.

Contributors All authors contributed significantly to the planning, conduct and reporting of the manuscript. CS and AB reported the radiology studies. CS was first author of the manuscript, and reviewed the patient's case notes. AB was the project supervisor, and reviewed and amended the manuscript. JL was responsible for the patient's ICU care, and reviewed and amended the manuscript. RF performed the patient's cholecystectomy, provided the intraoperative images, and reviewed and amended the manuscript.

Funding The Open Access publication fee was subsidised by the Surgical Department at The Prince Charles Hospital.

Competing interests None declared.

Patient consent Obtained.

Provenance and peer review Not commissioned; externally peer reviewed.

Open Access This is an Open Access article distributed in accordance with the Creative Commons Attribution Non Commercial (CC BY-NC 4.0) license, which permits others to distribute, remix, adapt, build upon this work non-commercially, and license their derivative works on different terms, provided the original work is properly cited and the use is non-commercial. See: <http://creativecommons.org/licenses/by-nc/4.0/>

© BMJ Publishing Group Ltd (unless otherwise stated in the text of the article) 2018. All rights reserved. No commercial use is permitted unless otherwise expressly granted.

REFERENCES

- Huffman JL, Schenker S. Acute acalculous cholecystitis: a review. *Clin Gastroenterol Hepatol* 2010;8:15–22.
- Richardson WS, Surowiec WJ, Carter KM, *et al.* Gallstone disease in heart transplant recipients. *Ann Surg* 2003;237:273–6.
- Date RS, Thrumurthy SG, Whiteside S, *et al.* Gallbladder perforation: case series and systematic review. *Int J Surg* 2012;10:63–8.
- Alessiani M, Peloso A, Tramelli P, *et al.* Successful non-operative management of spontaneous type II gallbladder perforation in a patient with Alzheimer's disease. *BMJ Case Rep* 2014;2014:bcr2014204337.
- Derici H, Kara C, Bozdogan AD, *et al.* Diagnosis and treatment of gallbladder perforation. *World J Gastroenterol* 2006;12:7832–6.
- Vijendren A, Cattle K, Obichere M, *et al.* Spontaneous haemorrhagic perforation of gallbladder in acute cholecystitis as a complication of antiplatelet, immunosuppressant and corticosteroid therapy. *BMJ Case Rep* 2012;2012:bcr1220115427.
- Geddes CC, Waterston A, Asari A, *et al.* Perforation of the gall bladder in a patient on continuous ambulatory peritoneal dialysis. *Nephrol Dial Transplant* 1996;11:2493–4.
- Goenka U, Majumder S, Banerjee P, *et al.* Spontaneous perforation of acalculous gall bladder presenting as acute abdomen. *J Emerg Med* 2012;43:637–40.
- Kim HJ, Park SJ, Lee SB, *et al.* A case of spontaneous gallbladder perforation. *Korean J Intern Med* 2004;19:128–31.
- Sheridan D, Qazi A, Lisa S, *et al.* Spontaneous acalculous gallbladder perforation. *BMJ Case Rep* 2014;2014:bcr2014206002.
- Niemeier OW. Acute free perforation of the gall-bladder. *Ann Surg* 1934;99:922–4.
- Vega KJ, Piña I, Krevsky B, *et al.* Heart transplantation is associated with an increased risk for pancreaticobiliary disease. *Ann Intern Med* 1996;124:980–3.
- Orwig D, Federle MP. Localized clotted blood as evidence of visceral trauma on CT: the sentinel clot sign. *AJR Am J Roentgenol* 1989;153:747–9.

Copyright 2018 BMJ Publishing Group. All rights reserved. For permission to reuse any of this content visit <http://group.bmj.com/group/rights-licensing/permissions>.

BMJ Case Report Fellows may re-use this article for personal use and teaching without any further permission.

Become a Fellow of BMJ Case Reports today and you can:

- ▶ Submit as many cases as you like
- ▶ Enjoy fast sympathetic peer review and rapid publication of accepted articles
- ▶ Access all the published articles
- ▶ Re-use any of the published material for personal use and teaching without further permission

For information on Institutional Fellowships contact consortiasales@bmjgroup.com

Visit casereports.bmj.com for more articles like this and to become a Fellow