

Efficacy and safety of TACE combined with tyrosine kinase inhibitors and camrelizumab for unresectable hepatocellular carcinoma: A systematic review and meta-analysis

JIAHUI YU, DUAN YAN, SONG WEI, LINFENG YANG and PENGSHENG YI

Department of Hepato-Biliary-Pancreas II, Affiliated Hospital of North Sichuan Medical College, Nanchong, Sichuan 637000, P.R. China

Received February 21, 2024; Accepted May 10, 2024

DOI: 10.3892/ol.2024.14534

Abstract. Transcatheter arterial chemoembolization (TACE) combined with tyrosine kinase inhibitors (TKIs) and camrelizumab (collectively: T-T-C) is a novel treatment strategy for unresectable hepatocellular carcinoma (HCC). The present systematic review and meta-analysis aimed to evaluate the efficacy and safety of T-T-C compared with TACE combined with TKIs only (T-T) in the treatment of patients with unresectable HCC. A systematic literature search was conducted on T-T and T-T-C using PubMed, Embase and the Cochrane Library. Data regarding the clinical outcome, including overall survival (OS), progression-free survival (PFS), tumor response and adverse events (AEs), were independently extracted and analyzed by two researchers using standardized protocols. In total, 7 cohort studies, including 1,798 patients (T-T-C, 838; T-T, 960), were included in the meta-analysis. The results of the present study demonstrated that the T-T-C group had significantly prolonged OS [hazard ratio (HR), 0.38; 95% confidence interval (CI), 0.29-0.50; $I^2=61.5\%$; $P=0.016$] and PFS (HR, 0.37; 95% CI, 0.30-0.46; $I^2=44.5\%$; $P=0.109$), and showed significantly higher objective response rates [risk ratio (RR), 0.82; 95% CI, 0.69-0.96; $I^2=25.1\%$; $P=0.237$] and slightly higher disease control rates without a significant difference (RR, 0.96; 95% CI, 0.89-1.03; $I^2=0.0\%$; $P=0.969$). In addition, grade 3/4 AEs were more common in the T-T group, including hypertension (RR, 1.15; 95% CI, 0.85-1.56), vomiting or nausea (RR, 0.88; 95% CI, 0.44-1.76) and pain (RR, 0.74; 95% CI, 0.45-1.21); however, these results were not statistically significant. In conclusion, compared with T-T combination therapy, T-T-C demonstrated a notable advantage in terms of OS, PFS, ORR and DCR in patients with unresectable HCC. For manageable

AEs, although the results were not statistically significant, the incidence of AEs in the T-T group was higher than that in the T-T-C group in terms of event probability.

Introduction

Hepatocellular carcinoma (HCC) is the sixth most commonly diagnosed cancer and the third most common cause of cancer-related death worldwide. Furthermore, HCC ranks fifth in the global incidence rate and second in the mortality rate of men; therefore, it attracts attention from individuals worldwide (1). There are numerous causes of liver cancer, and the risk factors vary depending on the geographical location, which include hepatitis B and C virus infections, alcoholic liver disease and aflatoxin intake (2). With the continuous development of medical technology globally, significant progress has been made in the treatment of HCC. Liver resection and radio-frequency ablation can be used to treat early liver cancer (3,4). However, the majority of patients diagnosed with HCC are already at the intermediate or advanced stage of disease. For unresectable liver cancer, there are various palliative treatment methods, which are selected according to the tumor stage and patient liver function and mainly include transcatheter arterial chemoembolization (TACE), targeted therapy and immunotherapy (5,6). Therefore, TACE combined with tyrosine kinase inhibitors (TKIs) and camrelizumab immunotherapy has become the focus of attention for researchers.

The therapeutic effect of TACE on advanced liver cancer is satisfactory, but it can lead to the formation of tumor blood vessels in the long run (7). As anti-angiogenic drugs, TKIs have a highly selective effect on vascular endothelial growth factor receptor-2 (VEGFR-2), which can effectively inhibit tumor angiogenesis and tumor proliferation, so as to accurately compensate for the formation of tumor blood vessels caused by TACE (8). Camrelizumab, the first approved programmed cell death protein-1 (PD-1) inhibitor for advanced liver cancer in China, demonstrated positive efficacy in a multicenter phase II trial (9). TACE has become the first-line treatment for advanced HCC (10), and TKIs, such as apatinib, sorafenib and lenvatinib, can prolong the overall survival of patients with HCC (11). However, exploring novel targeted therapies and immunotherapy drugs and combining these drugs with established treatments has been shown to improve survival rates (12).

Correspondence to: Dr Pengsheng Yi, Department of Hepato-Biliary-Pancreas II, Affiliated Hospital of North Sichuan Medical College, 1 Maoyuan South Road, Nanchong, Sichuan 637000, P.R. China
E-mail: 1931763993@qq.com

Key words: transcatheter arterial chemoembolization, tyrosine kinase inhibitors, camrelizumab, hepatocellular carcinoma, meta-analysis

TKIs, the main representative type of anti-angiogenic drugs, include sorafenib, lenvatinib and apatinib. Lenvatinib was approved as a first-line treatment for HCC in 2018, and a clinical trial has shown that, compared with sorafenib, lenvatinib can effectively improve the overall survival (OS) of patients (13). In addition, apatinib, a novel drug, is more selective than sorafenib in targeting VEGFR-2 (14).

TACE is widely accepted as the standard treatment for mid to late-stage HCC (15-17). TACE can cause necrosis of most tumor cells; however, hypoxia in tumor tissues during this process can lead to an increase in the level of VEGF, which in turn causes tumor angiogenesis and ultimately leads to tumor growth or metastasis (18). Therefore, anti-angiogenic drugs are particularly important in systemic therapy as they can block hypoxia inducible factor-1 α /the VEGF pathway, inhibiting tumor growth or metastasis and improving patient prognosis (18,19). TACE combined with TKIs (anti-angiogenic drugs) is a novel treatment method for patients with HCC. A randomized multicenter prospective trial by Kudo *et al* (20) reported that this combination therapy significantly improved progression-free survival (PFS).

Immune checkpoint inhibitors (ICIs) are the main therapeutic agents for HCC, and PD-1 can be combined with VEGF inhibitors to increase the immune response (21-23). Camrelizumab is a humanized anti-PD-1 monoclonal antibody, and its efficacy in combination with TKIs, such as apatinib, has been confirmed in the RESCUE assay for advanced HCC (9,24). There have been relevant studies on the efficacy of TACE combined apatinib with or without camrelizumab in the treatment of unresectable HCC, and the results showed that the triple therapy with camrelizumab could prolong the overall survival of patients (25,26). As such, the efficacy and safety of a new triple therapy, TACE + TKIs + camrelizumab (T-T-C), have been widely studied. However, in order to provide evidence for clinical decision-making, the present study collected data on T-T-C and TACE + TKIs (T-T) to explore the efficacy and safety of these combined treatment regimens in unresected HCC.

Materials and methods

Search strategy. The analysis was performed in accordance with the Preferred Reporting Items for Systematic Reviews and Meta-Analyses statement (27). The present review is registered on the PROSPERO website (<https://www.crd.york.ac.uk/PROSPERO/>) under registration no. CRD42024501473. The available literature was retrieved through an electronic search of the PubMed (<https://pubmed.ncbi.nlm.nih.gov/>), Embase (<https://www.embase.com/>) and Cochrane Library (<https://www.cochranelibrary.com/>) databases (Table SI). The main key words searched were as follows: 'liver neoplasms', 'carcinoma, hepatocellular', 'hepatic*', 'carcinoma', 'cancer', 'tumor', 'lenvatinib', 'apatinib', 'sorafenib', 'tyrosinekinase inhibitors', 'chemoembolization', 'transcatheter arterial chemoembolization' and 'camrelizumab'. No language restrictions or limitations were imposed on the search strategy.

Inclusion and exclusion criteria. The inclusion criteria were as follows: i) Clinically or pathologically confirmed unresectable HCC with at least one measurable lesion; ii) Barcelona

Clinical Liver Cancer (BCLC) stage B or C (4); iii) an Eastern Cooperative Oncology Group performance score (ECOG PS) of 0 or 1 (28); iv) patients aged >18 years old; v) there was at least one target lesion with a measurable diameter and arterial strengthening according to the modified Response Evaluation Criteria in Tumors (mRECIST) (29); and vi) Child-Pugh class A or B (30).

The exclusion criteria were as follows: i) Presence of other malignant tumors besides HCC; ii) other treatments, such as radiofrequency ablation and anhydrous alcohol injection, were received during treatment; iii) absence of a control group; iv) the study was a systematic review, meta-analysis, letter or conference abstract; v) incomplete data; vi) patients with vital organ dysfunction; and vii) Child-Pugh class C.

Data extraction. After searching for relevant literature in the databases and organizing literature using Endnote X9 (Bld 12062) (Clarivate) software, two researchers extracted and organized the data using Excel version 2016 (Microsoft Corporation). When two researchers extracted data that were different, a third researcher was used to re-extract the problematic data. The following data were extracted from the included literature: i) Name of the main author, year of publication and country of research; ii) sex and age of the patients; iii) research design, treatment plan and number of participants in the experimental and control groups; iv) α -fetoprotein level in the blood, tumor size, Child-Pugh class, BCLC stage and ECOG PS; and v) objective response rate (ORR), disease control rate (DCR), OS and PFS.

Quality assessment. In the present study, the Newcastle-Ottawa Scale (NOS) was used to conduct quality assessment. NOS is a commonly used quality assessment tool for observational studies. Observational studies were evaluated by three modules with a total of eight items. Specifically, the modules included population selection, comparability and exposure/outcome evaluation. NOS uses the semi-quantification principle of the star system to evaluate the quality of the literature. Excepting comparability in which a maximum of 2 stars can be awarded, items can be rated up to 1 star. In the present study, the quality of the included literature was independently evaluated by two researchers, with a maximum possible quality score of 9, in which 1-4 indicated low quality and 5-9 indicated high quality (31).

The certainty of the evidence was also independently evaluated by two authors according to the Grading of Recommendations Assessment, Development, and Evaluation (GRADE) assessment (32). GRADE was used to score each outcome, and the overall quality level of the evidence was divided into high, medium, low and very low. Finally, GRADEpro version GDT software (www.grade.org) was used to summarize the assessment results (Table SII).

Statistical analysis. The main endpoints assessed in the present study were OS and PFS. OS was defined as the time from randomization until death from any cause. PFS was defined as the time from randomization to disease progression or death from any cause. Survival outcomes were reported using hazard ratios (HRs) and 95% confidence intervals (CIs).

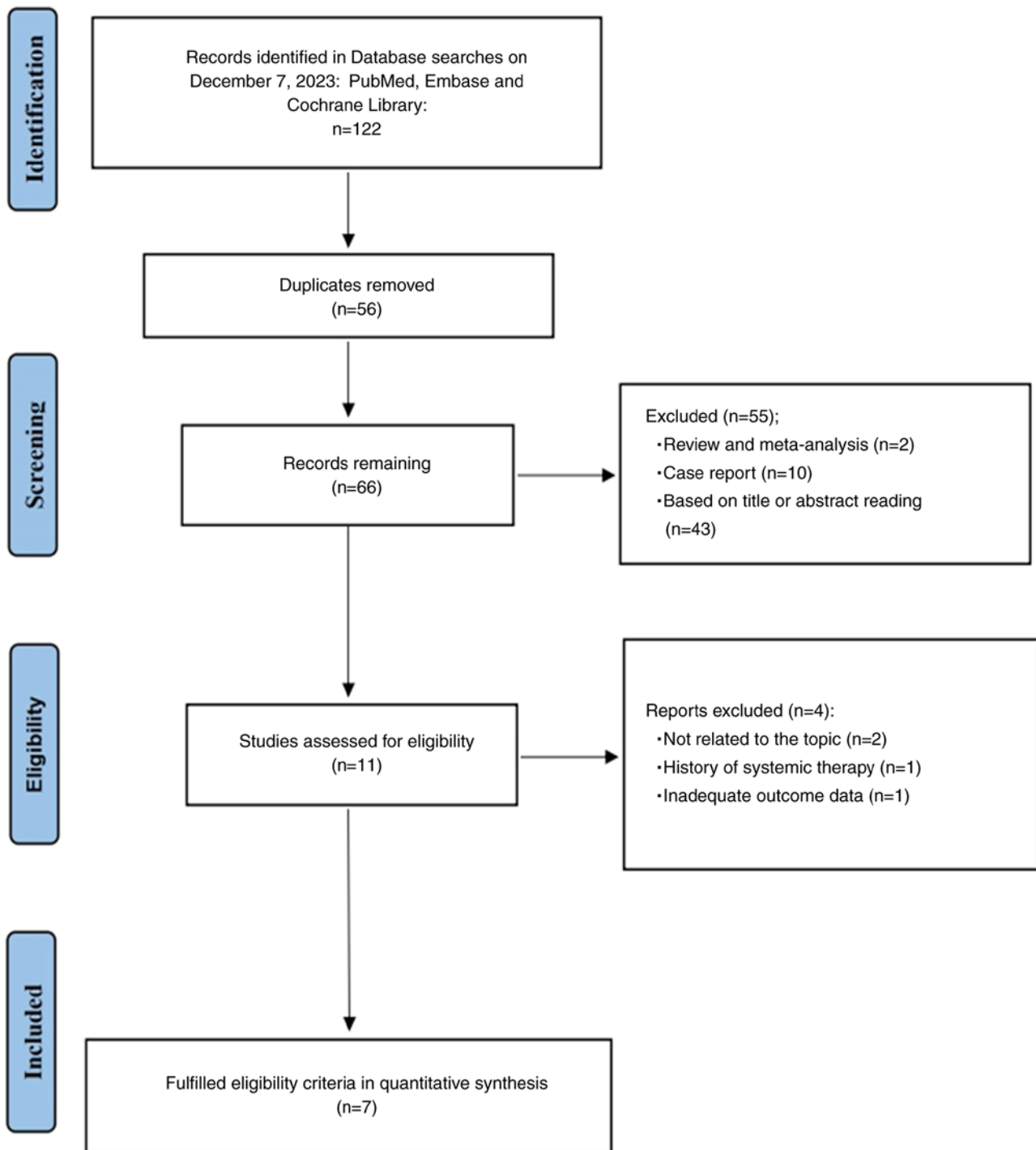


Figure 1. Preferred Reporting Items for Systematic Reviews and Meta-Analyses flow diagram of the process of identifying eligible studies.

The secondary endpoints included ORR and DCR, where ORR was defined as complete and partial remission and DCR was defined as the sum of the complete remission, partial remission and disease stability. ORR and DCR were reported using risk ratios (RRs) and 95% CIs. Tumor response was evaluated according to mRECIST (29).

Q-statistics and I^2 were used to analyze and evaluate heterogeneity, low heterogeneity was indicated when $I^2 < 50\%$ or $P > 0.05$. In the meta-analysis, the random effects model was used. Sensitivity analysis was used to evaluate the stability of the outcomes, and publication bias was evaluated using

Egger's tests. All analyses were conducted using Stata/MP version 17.0 (StataCorp LLC).

Results

Study selection. After searching the primary databases, 122 relevant studies were identified (Fig. 1). The Endnote version X9 software was used to organize the literature, and 56 duplicate studies were both automatically and manually removed. The titles and abstracts of the remaining articles were carefully read and 11 studies were included. The text of

Table I. Demographic characteristics of the included studies.

First author, year	Country	Study design	Treatment strategy	No. of patients	Age, years	Male/female, n	AFP, ng/ml:n	Tumor size, cm	Child-Pugh class A/B, n	BCLC stage B/C, n	ECOG PS 0/1/2/3, n	(Refs.)
Duan <i>et al.</i> , 2023	China	RCS	TACE + A TACE + A + C	477 483	52.9±9.6 ^a 52.6±9.2 ^a	382/95 399/84	≤400/>400:162/345 ≤400/>400:198/285	12.39±4.68 ^a 11.89±5.06 ^a	193/284 193/290	75/402 85/398	256/212/0/0 283/200/0/0	(25)
Liu <i>et al.</i> , 2023	China	RCS	TACE + A TACE + A + C	39 37	<60/≥60:18/21 <60/≥60: 25/12	36/3 32/5	<400/≥400:23/16 <400/≥400:20/17	<5/≥5: 21/18 <5/≥5: 15/22	35/4 32/5	24/15 19/18	24/15/0/0 27/10/0/0	(26)
Pan <i>et al.</i> , 2023	China	RCS	TACE + S TACE + S + C	85 150	63.44±6.099 ^a 61.25±10.576 ^a	68/17 133/17	>400/<400:20/65 >400/<400:42/108	6.989±3.9296 ^a 6.272±3.8188 ^a	63/22 112/38	50/35 94/56	52/23/9/1 94/38/16/2	(33)
Sun <i>et al.</i> , 2022	China	RCS	TACE + L TACE + L + C	52 31	51.77±9.791 ^a 54.84±9.249 ^a	46/6 25/6	>400/≤400:21/31 >400/≤400:12/19	7.65±4.86 ^a 8.31±4.80 ^a	43/9 24/7	17/35 11/20	22/30/0/0 19/12/0/0	(34)
Sun <i>et al.</i> , 2023	China	RCS	TACE + TKIs TACE + TKIs + C	190 70	51.9±10.1 ^a 53.8±10.4 ^a	166/24 58/12	>400/≤400:99/91 >400/≤400:40/30	8.7±4.4 ^a 8.5±4.8 ^a	157/33 57/13	NA NA	81/109/0/0 47/23/0/0	(35)
Xiang <i>et al.</i> , 2023	China	RCS	TACE + L TACE + L + C	49 33	51.7±11.2 ^a 51.0±12.2 ^a	45/4 28/5	<400/≥400:29/20 <400/≥400:14/19	10.6±2.7 ^a 11.8±3.5 ^a	41/8 25/8	22/27 10/23	38/11/0/0 22/11/0/0	(36)
Zhu <i>et al.</i> , 2022	China	RCS	TACE + A TACE + A + C	68 34	<60/≥60: 41/27 <60/≥60: 23/11	58/10 29/5	<200/≥200:35/33 <200/≥200:21/13	<10/≥10: 47/21 <10/≥10: 27/7	56/12 30/4	26/42 13/21	34/34/0/0 19/15/0/0	(37)

^aData are presented as the mean ± SD. RCS, retrospective cohort study; TACE, transcatheter arterial chemoembolization; TKIs, tyrosine kinase inhibitors; A, apatinib; S, sorafenib; L, lenvatinib; C, camrelizumab; AFP, α-fetoprotein; ECOG PS, Eastern Cooperative Oncology Group Performance Status; BCLC, Barcelona Clinic Liver Cancer.

Table II. Assessment of the cohort studies using the Newcastle-Ottawa scale.

First author, year	Selection			Comparability		Exposure/outcome			Total score (out of 9)	(Refs.)
	Representativeness of the cohort ★	Selection of the control cohort ★	Ascertainment of exposure ★	Outcome not present at the start ★	Comparability of cohorts ★★	Assessment of the outcome ★	Length of the follow-up ★	Adequacy of the follow-up ★		
Duan <i>et al</i> , 2023	★	★	★	★	★	★		★	7	(25)
Liu <i>et al</i> , 2023	★	★	★	★	★★	★	★	★	9	(26)
Pan <i>et al</i> , 2023	★	★	★	★	★	★			6	(33)
Sun <i>et al</i> , 2022	★	★	★	★	★★	★	★	★	9	(34)
Sun <i>et al</i> , 2023	★	★	★	★	★★	★		★	8	(35)
Xiang <i>et al</i> , 2023	★	★	★	★	★	★	★	★	8	(36)
Zhu <i>et al</i> , 2022	★	★	★	★	★	★	★	★	8	(37)

Scoring criteria described in (31).

these 11 studies were read in detail and 7 studies were finally included in the meta-analysis (25,26,33-37).

Study characteristics and quality assessment. The meta-analysis included 7 articles, all of which were from China and were retrospective cohort studies. A total of 1,798 patients with HCC were included, of whom 960 were treated with T-T and 830 were treated with T-T-C. Table I summarizes the characteristics of the 7 included studies. The NOS was used to evaluate the quality of the 7 retrospective cohort studies, all of which were considered high quality (Table II).

Clinical outcomes

OS and PFS. Except for the study by Pan *et al* (33), which did not report PFS, all studies reported information regarding OS and PFS. The comprehensive results of the OS meta-analysis showed that, compared with T-T combination therapy, T-T-C combination therapy had significant benefits in terms of the OS rate (HR, 0.38; 95% CI, 0.29-0.50; I²=61.5%; P=0.016; Fig. 2A). Using a random-effects model, I²=61.5% showed slightly high heterogeneity. In terms of the PFS rate, T-T-C combination therapy had significant benefits compared with T-T combination therapy (HR, 0.37; 95% CI, 0.30-0.46; I²=44.5%; P=0.109; Fig. 2B), with low heterogeneity.

Tumor response. Evaluation of the tumor response after treatment based on the ORR and DCR was reported in all 7 studies. A random-effects model was used to merge the RRs for ORR (RR, 0.82; 95% CI, 0.69-0.96; I²=25.1%; P=0.237; Fig. 3A) and DCR (RR, 0.96; 95% CI, 0.89-1.03; I²=0.0%; P=0.969; Fig. 3B). These results indicated that, compared with T-T, T-T-C improved the tumor response in patients with HCC.

AEs. All studies reported AEs. Table III summarizes the seven most common grade 3 AEs. The most common AEs in the T-T-C group were hypertension (8.92%), nausea and vomiting (7.78%) and pain (7.08%). The most common AEs in the T-T group were hypertension (9.42%), pain (9.06%) and nausea and vomiting (7.93%). Compared with the T-T-C treatment group, the T-T treatment group had a significantly increased incidence of diarrhea (RR, 1.97; 95% CI, 0.69-5.61), hand and foot skin reactions (RR, 1.19; 95% CI, 0.82-1.72) and pain (RR, 0.74; 95% CI, 0.45-1.21) (Table III). However, this result was not statistically significant.

Sensitivity analysis and publication bias. A sensitivity analysis of the combined survival outcomes was performed. Omitting 1 study at a time resulted in a consistent OS and PFS without notable fluctuations (Fig. 4). The Egger's test for OS (P=0.303) and PFS (P=0.869) indicated no potential publication bias (Fig. 5).

Discussion

HCC is one of the most common solid malignancies worldwide, accounting for ~90% of primary liver cancer cases, and a large proportion of patients with HCC are diagnosed at an advanced stage (12,38). Significant advances have been made in the treatment of HCC. In the past few years, TACE, a first-line treatment for HCC, has been shown to cause tumor cell ischemia and hypoxia by injecting embolic agents into the artery, leading to tumor destruction. However, TACE can promote the release of VEGF and cause tumor angiogenesis, leading to tumor growth or metastasis (39,40). Therefore, anti-VEGF

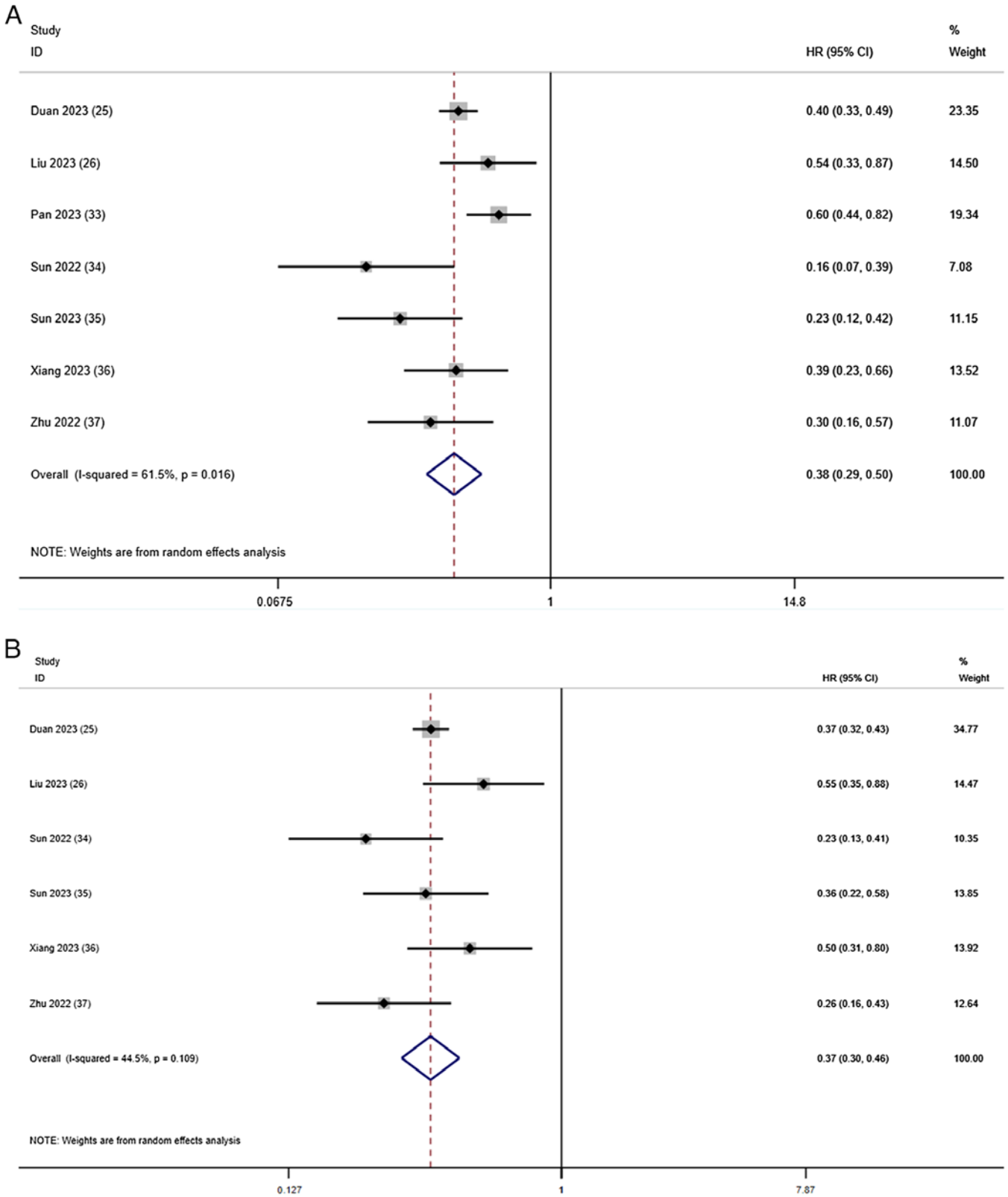


Figure 2. Forest plots for the comparison of (A) OS and (B) PFS. Heterogeneity for OS: χ^2 , 15.59 (P=0.016); I^2 , 61.5%. Test for overall effect of OS: Z, 6.90 (P<0.001). Heterogeneity for PFS: χ^2 , 9.01 (P=0.109); I^2 , 44.5%. Test for overall effect of PFS: Z, 8.91 (P<0.001). CI, confidence interval; HR, hazard ratio; OS, overall survival; PFS, progression-free survival.

treatment can be introduced to inhibit tumor angiogenesis. Bevacizumab was one of the first anti-VEGF drugs approved by the Food and Drug Administration for the treatment of human cancer and can effectively inhibit angiogenesis (41,42). TKIs

can simultaneously target multiple anti-angiogenic receptor sites, thereby blocking the kinase activity of the receptor, thus achieving the effect of inhibiting angiogenesis (43). TKIs (lenvatinib, sorafenib and apatinib) are recommended as the

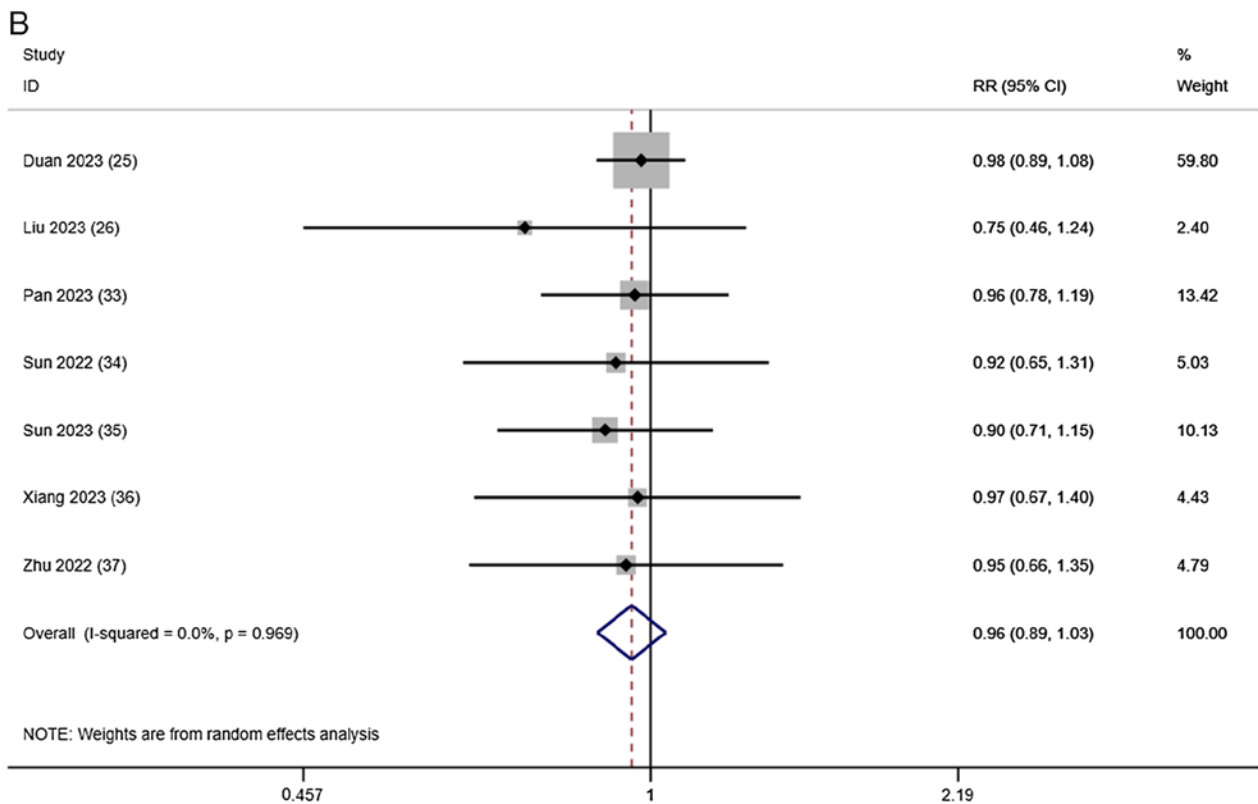
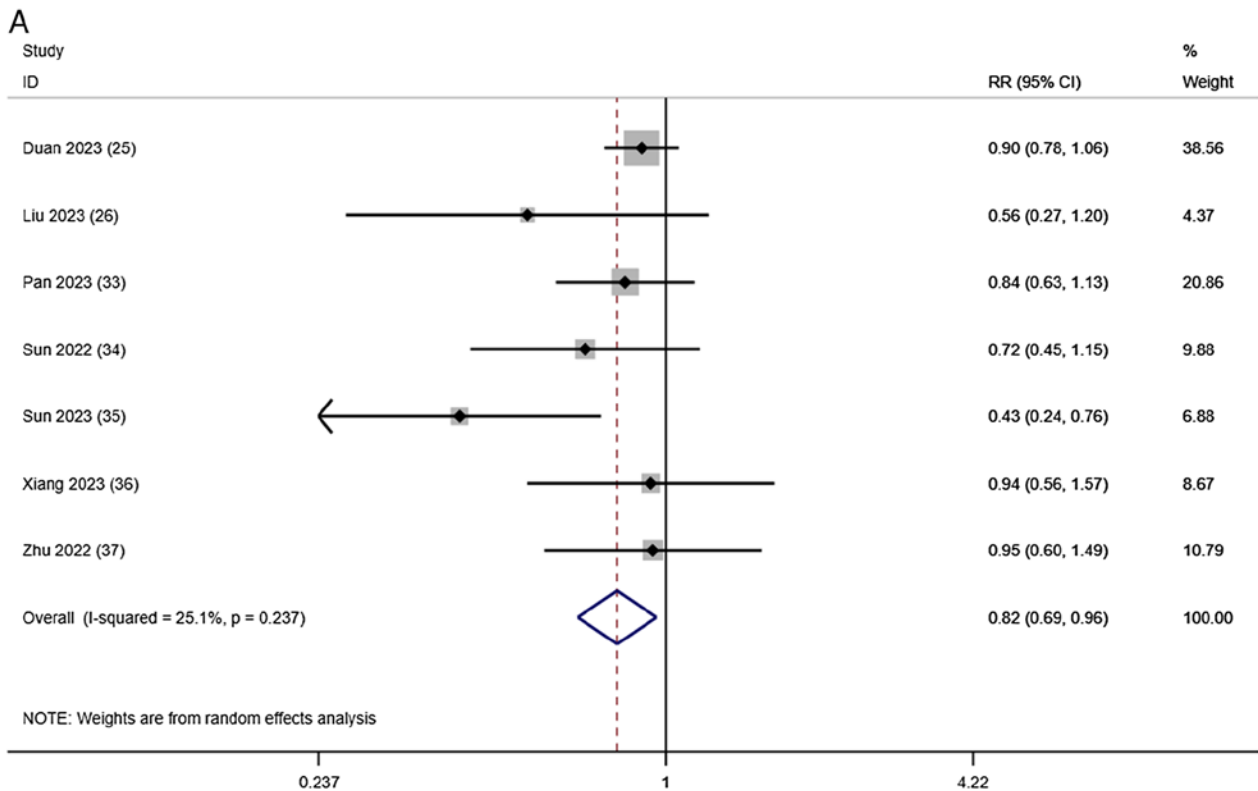


Figure 3. Forest plots for the comparison of the (A) ORR and (B) DCR. Heterogeneity for ORR: χ^2 , 8.01 (P=0.237); I², 25.1%. Test for overall effect of ORR: Z, 2.42 (P=0.016). Heterogeneity for DCR: χ^2 , 1.35 (P=0.969); I², 0.0%. Test for overall effect of DCR: Z, 1.09 (P=0.275). CI, confidence interval; DCR, disease control rate; ORR, objective response rate; RR, risk ratio.

first-line treatment for advanced HCC. A single-arm phase II clinical trial that enrolled patients with advanced HCC who received apatinib demonstrated a total ORR and DCR of 30.4 and 65.2%, respectively, and median OS and PFS times

of 13.8 (95% CI, 5.3-22.3) and 8.7 months (95% CI, 5.9-11.1), respectively, confirming the efficacy of apatinib in patients with advanced HCC (44). In addition, a clinical trial conducted by Kudo *et al* (20) showed that lenvatinib was comparable to

Table III. Summary of the treatment related grade 3/4 adverse events.

Adverse events	No. of studies	Rate of events, %		RR (95% CI)	P-value	I ²
		TACE + TKIs	TACE + TKIs + C			
Hypertension	6	9.42	8.92	1.15 (0.85-1.56)	0.998	0
Pain	5	9.06	7.08	0.74 (0.45-1.21)	0.856	0
Hand-foot skin reaction	5	6.30	5.18	1.19 (0.82-1.72)	0.739	0
Diarrhea	4	3.25	0.88	1.97 (0.69-5.61)	0.988	0
Fatigue	4	3.83	3.43	1.09 (0.46-2.59)	0.606	0
Nausea and vomiting	4	7.93	7.78	0.88 (0.44-1.76)	0.963	0

RR, risk ratio; CI, confidence interval; TACE, transcatheter arterial chemoembolization; TKIs, tyrosine kinase inhibitors; C, camrelizumab.

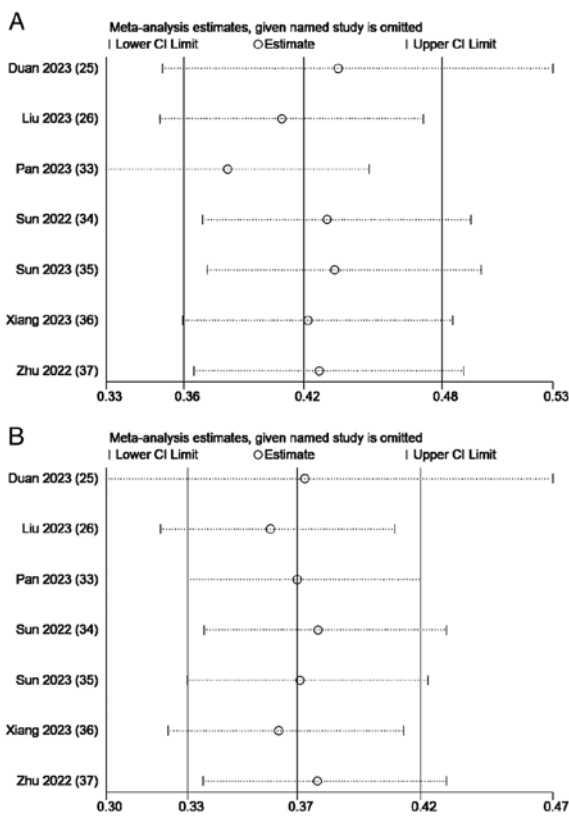


Figure 4. Sensitivity analysis plot based on (A) overall survival and (B) progression-free survival.

sorafenib in terms of OS. In the treatment of HCC, PD-1 inhibitors can restore the ability of the immune system to kill tumor cells by blocking the PD-1/PD-L1 cell signaling pathway (45). Camrelizumab is a humanized PD-1 monoclonal antibody. The RESCUE trial showed that camrelizumab combined with apatinib was effective for treating advanced HCC (24). However, the PD-1 inhibitors nivolumab and pembrolizumab did not significantly improve OS in patients with HCC in a phase III trial of monotherapy (46). Therefore, combination treatment programs have become a research focus. A study analyzing the effects of TACE with or without apatinib in patients with advanced HCC showed median OS and PFS times of 8.5 and 2.5 months, respectively, in the TACE group alone,

whereas the median OS and PFS times in the TACE-apatinib group were 17.0 and 7.0 months, respectively, which suggested that apatinib improved patient outcomes (47). A Phase III randomized clinical trial by Peng *et al* (48), which divided patients with advanced HCC into the lenvatinib + TACE or lenvatinib alone groups, showed that the median OS time was significantly longer in the lenvatinib + TACE group (17.8 vs. 11.5 months; RR, 0.45; $P < 0.001$), and the median PFS time was 10.6 months in the lenvatinib + TACE group and 6.4 months in the lenvatinib alone group (HR, 0.43; $P < 0.001$). Thus, it was concluded that combination therapy has a better therapeutic effect than TACE treatment alone.

Owing to the notable efficacy of combination therapy, many triple therapy trials have also been conducted. A meta-analysis comparing TACE combined with camrelizumab and TACE alone in the treatment of advanced HCC showed an ORR and DCR of 46.13 and 77.19%, respectively. However, the ORR and DCR in the present study were 84 and 96%, respectively, indicating that triple therapy with TKIs could improve the ORR and DCR of patients (49). The results of a retrospective study comparing TACE + sorafenib with or without ICIs suggested that the PFS and OS times were both prolonged in the TACE + sorafenib + ICI group compared with the TACE + sorafenib group (median PFS time: 16.26 vs. 7.30 months, $P < 0.001$; median OS time: 23.3 vs. 13.8 months, $P = 0.012$) (50), which was similar to the results of the present study. A retrospective systematic review showed that T-T-C was beneficial for the treatment of unresectable HCC (51). However, due to the small number of clinical trials, there are no clear clinical trial results for this triple therapy.

In the present meta-analysis, the T-T and T-T-C regimens were compared. The results suggested that T-T-C combination therapy resulted in an improved OS, PFS, ORR and DCR compared with T-T combination therapy. A study by Zou *et al* (52) included 160 patients with advanced liver cancer, all receiving TACE + lenvatinib with or without PD-1 inhibitors, and focused on patient outcomes. The results showed that the triple therapy significantly extended the median OS (23.5 vs. 18.3 months; $P = 0.0002$) and PFS (7.5 vs. 4.3 months; $P < 0.0001$) times compared with the double therapy. In addition, a retrospective study comparing TACE + lenvatinib with or without pembrolizumab showed that the pembrolizumab + lenvatinib + TACE group had significantly prolonged

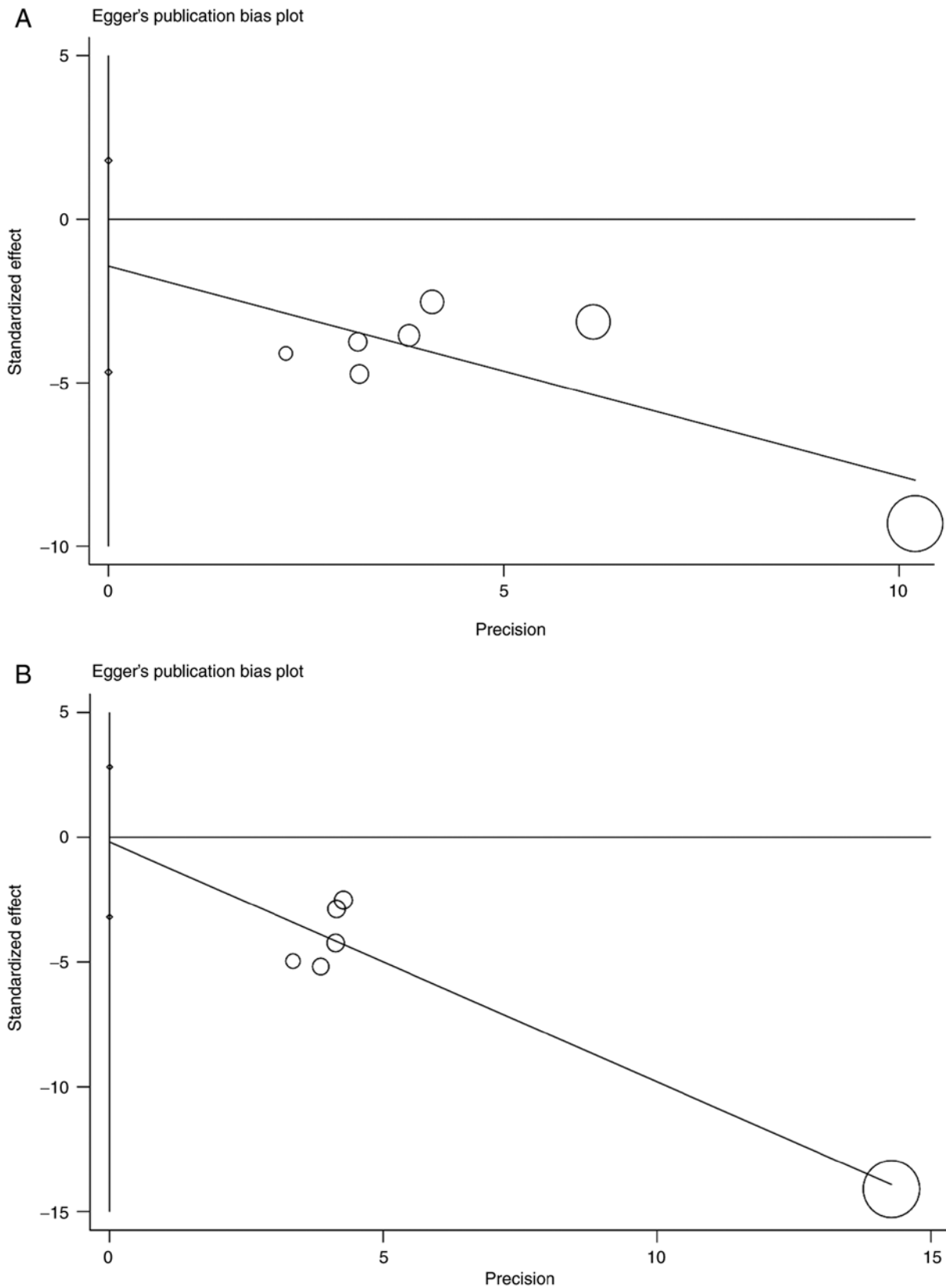


Figure 5. Egger's test for (A) overall survival and (B) progression-free survival.

median OS (18.1 vs. 14.1 months; $P=0.004$) and PFS (9.2 vs. 5.5 months; $P=0.006$) times (53). These results were similar to those of the present meta-analysis. A similar meta-analysis comparing the TACE + TKIs group with the TACE + TKIs + ICI group in the treatment of HCC showed that triple therapy

could effectively improve the ORR of the overall patient population and prolong the median PFS and OS times, but the PFS heterogeneity in the study was high ($I^2=66%$) (54). The source of the heterogeneity was determined through sensitivity analysis and, after excluding an article by Zheng *et al* (50),

the heterogeneity changed to $I^2=0$. The OS heterogeneity was also high in the present meta-analysis ($I^2=61.5\%$; $P=0.016$), and the results remained robust after sensitivity analysis. However, due to the small sample size, meta-regression could not be performed to determine the source of heterogeneity. Therefore, the number of included articles should be increased in further analyses.

Although a relevant study has shown that T-T combination therapy has a positive effect on patients with advanced HCC (55), it is still weaker than triple therapy with T-T-C. The reasons can be summarized as follows: TACE can cause local necrosis of tumors, cause tumor tissues to release antigens, trigger anticancer immune responses, increase the expression of PD-1 and improve tumor recognition ability. Anti-VEGF therapy can be introduced to inhibit tumor angiogenesis, reduce VEGF-mediated immunosuppression in the tumor and its microenvironment, and promote T cell infiltration (56,57). Studies have shown that triple therapy can significantly improve tumor control and patient survival (58-60), and these results were similar to the present results.

Although, as aforementioned, the effect of this triple therapy can be satisfactory, certain patients cannot be treated with TACE, which mainly includes patients in the following categories: i) Patients with decompensated cirrhosis (Child-Pugh B 8 or higher); ii) patients with an extensive tumor with massive replacement of both lobes; iii) patients with severely reduced portal vein flow (such as non-tumoral portal vein occlusion or hepatofugal blood flow); iv) patients with technical contraindications to hepatic intra-arterial treatment (such as untreatable arterio-venous fistula); and v) patients with renal insufficiency (creatinine ≥ 2 mg/dl or creatinine clearance ≤ 30 ml/min) (61). Therefore, before carrying out treatment, the various indicators of the patient must first be evaluated to ensure that the patient meets the treatment requirements.

Regarding AEs, grade 3/4 AEs in the T-T-C and T-T groups were analyzed and consistent results were found for the top four AEs in both groups, which were hypertension, nausea and vomiting, pain, and hand and foot skin reactions. Since TKI and TACE treatment were included in both groups, the primary cause of AEs may be related to TKI and TACE use. These results were consistent with those of previous studies (23,62). In addition, among the six AEs included in the present study, the incidence of each AE was higher in the T-T group than in the T-T-C group, which was inconsistent with the results of a similar meta-analysis (63). Furthermore, Xu *et al* (24) showed that camrelizumab combined with apatinib reduced proteinuria and prolonged vascular normalization. In addition, a study has shown that anti-angiogenic drugs combined with PD-1 can reduce the incidence of AEs (64). Therefore, we concluded that the lower incidence of AEs in the T-T-C group may be due to the effect of camrelizumab alone or camrelizumab combined with TKIs, which can reduce the incidence of related AEs. However, the efficacy of this combination regimen in reducing AEs remains unclear, and further studies are needed to confirm this hypothesis. In summary, under the premise of ensuring patient safety and controlling AEs, the T-T-C triple therapy may have an improved curative effect on patients.

However, the present study had certain limitations. First, the number of articles included was relatively small, the

sample size was small and the included articles were all from China, which lacked representativeness and comprehensiveness. Therefore, more articles should be included in future meta-analyses, particularly those analyzing samples from other countries, to increase the comprehensiveness. Second, all the articles included in the present study were retrospective cohort studies, which may have a certain selection bias and affect the final results. Third, the TKIs selected in all the included articles were different, and different TKIs may bring different curative effects and ultimately lead to different survival rates of patients; however, different TKIs were not analyzed separately due to the small number of available studies. Fourth, among all the included articles, some contained shorter follow-up times, which may have caused some valuable observations to be missed. Finally, the quality of life of the patient can affect the outcome of different treatment modalities; however, relevant data for this could not be found.

In summary, the results of the present systematic review and meta-analysis indicated that, in patients with advanced HCC, T-T-C combination therapy demonstrated a notable advantage in terms of OS, PFS, ORR, DCR and manageable AEs. However, further evidence of this is needed from a larger number of randomized controlled trials.

Acknowledgments

Not applicable.

Funding

The present study was supported by The Bureau of Science and Technology of Nanchong City (grant no. 22SXQT0052).

Availability of data and materials

The data generated in the present study may be requested from the corresponding author.

Authors' contributions

JY, DY, SW, LY and PY contributed to the conception and design of the study. Data collection was performed by JY and DY. Statistical analysis was performed by SW and LY. Interpretation of the data was performed by JY and DY. JY and PY drafted and revised the manuscript. JY and PY confirm the authenticity of all the raw data. All authors read and approved the final version of the manuscript.

Ethics approval and consent to participate

Not applicable.

Patient consent for publication

Not applicable.

Competing interests

The authors declare that they have no competing interests.

References

- Sung H, Ferlay J, Siegel RL, Laversanne M, Soerjomataram I, Jemal A and Bray F: Global cancer statistics 2020: GLOBOCAN estimates of incidence and mortality worldwide for 36 cancers in 185 countries. *CA Cancer J Clin* 71: 209-249, 2021.
- Gordan JD, Kennedy EB, Abou-Alfa GK, Beg MS, Brower ST, Gade TP, Goff L, Gupta S, Guy J, Harris WP, *et al*: Systemic therapy for advanced hepatocellular carcinoma: ASCO Guideline. *J Clin Oncol* 38: 4317-4345, 2020.
- Nault J, Sutter O, Nahon P, Ganne-Carrié N and Sèror O: Percutaneous treatment of hepatocellular carcinoma: State of the art and innovations. *J Hepatol* 68: 783-797, 2018.
- Reig M, Forner A, Rimola J, Ferrer-Fàbrega J, Burrel M, Garcia-Criado A, Kelley RK, Galle PR, Mazzaferro V, Salem R, *et al*: BCLC strategy for prognosis prediction and treatment recommendation: The 2022 update. *J Hepatol* 76: 681-693, 2022.
- Cabibbo G, Enea M, Attanasio M, Bruix J, Craxi A and Cammà C: A meta-analysis of survival rates of untreated patients in randomized clinical trials of hepatocellular carcinoma. *Hepatology* 51: 1274-1283, 2010.
- Yoon SM, Ryoo BY, Lee SJ, Kim JH, Shin JH, An JH, Lee HC and Lim YS: Efficacy and safety of transarterial chemoembolization plus external beam radiotherapy vs sorafenib in hepatocellular carcinoma with macroscopic vascular invasion: A Randomized clinical trial. *JAMA Oncol* 4: 661-669, 2018.
- Wang Q, Xia D, Bai W, Wang E, Sun J, Huang M, Mu W, Yin G, Li H, Zhao H, *et al*: Development of a prognostic score for recommended TACE candidates with hepatocellular carcinoma: A multicentre observational study. *J Hepatol* 70: 893-903, 2019.
- Zhou C, Yao Q, Zhang H, Guo X, Liu J, Shi Q, Huang S and Xiong B: Combining transcatheter arterial embolization with iodized oil containing Apatinib inhibits HCC growth and metastasis. *Sci Rep* 10: 2964, 2020.
- Qin S, Ren Z, Meng Z, Chen Z, Chai X, Xiong J, Bai Y, Yang L, Zhu H, Fang W, *et al*: Camrelizumab in patients with previously treated advanced hepatocellular carcinoma: A multicentre, open-label, parallel-group, randomised, phase 2 trial. *Lancet Oncol* 21: 571-580, 2020.
- Ogasawara S, Ooka Y, Koroki K, Maruta S, Kanzaki H, Kanayama K, Kobayashi K, Kiyono S, Nakamura M, Kanogawa N, *et al*: Switching to systemic therapy after locoregional treatment failure: Definition and best timing. *Clin Mol Hepatol* 26: 155-162, 2020.
- Kudo M, Finn RS, Qin S, Han KH, Ikeda K, Piscaglia F, Baron A, Park JW, Han G, Jassem J, *et al*: Lenvatinib versus sorafenib in first-line treatment of patients with unresectable hepatocellular carcinoma: A randomised phase 3 non-inferiority trial. *Lancet* 391: 1163-1173, 2018.
- Llovet JM and Bruix J: Systematic review of randomized trials for unresectable hepatocellular carcinoma: Chemoembolization improves survival. *Hepatology* 37: 429-442, 2003.
- Kudo M, Cheng AL, Park JW, Park JH, Liang PC, Hidaka H, Izumi N, Heo J, Lee YJ, Sheen IS, *et al*: Orantinib versus placebo combined with transcatheter arterial chemoembolisation in patients with unresectable hepatocellular carcinoma (ORIENTAL): A randomised, double-blind, placebo-controlled, multicentre, phase 3 study. *Lancet Gastroenterol Hepatol* 3: 37-46, 2018.
- Qin S, Li Q, Gu S, Chen X, Lin L, Wang Z, Xu A, Chen X, Zhou C, Ren Z, *et al*: Apatinib as second-line or later therapy in patients with advanced hepatocellular carcinoma (AHELP): A multicentre, double-blind, randomised, placebo-controlled, phase 3 trial. *Lancet Gastroenterol Hepatol* 6: 559-568, 2021.
- Bruix J and Sherman M; American Association for the Study of Liver Diseases: Management of hepatocellular carcinoma: An update. *Hepatology* 53: 1020-1022, 2011.
- Forner A, Reig M and Bruix J: Hepatocellular carcinoma. *Lancet* 391: 1301-1314, 2018.
- European Association for the Study of the Liver. Electronic address: easloffice@easloffice.eu; European Association for the Study of the Liver: EASL Clinical Practice Guidelines: Management of hepatocellular carcinoma. *J Hepatol* 69: 182-236, 2018.
- Kong J, Kong J, Pan B, Ke S, Dong S, Li X, Zhou A, Zheng L and Sun WB: Insufficient radiofrequency ablation promotes angiogenesis of residual hepatocellular carcinoma via HIF-1 α /VEGFA. *PLoS One* 7: e37266, 2012.
- Wang B, Xu H, Gao ZQ, Ning HF, Sun YQ and Cao GW: Increased expression of vascular endothelial growth factor in hepatocellular carcinoma after transcatheter arterial chemoembolization. *Acta Radiol* 49: 523-529, 2008.
- Kudo M, Han G, Finn RS, Poon RT, Blanc JF, Yan L, Yang J, Lu L, Tak WY, Yu X, *et al*: Brivanib as adjuvant therapy to transarterial chemoembolization in patients with hepatocellular carcinoma: A randomized phase III trial. *Hepatology* 60: 1697-1707, 2014.
- El-Khoueiry AB, Sangro B, Yau T, Crocenzi TS, Kudo M, Hsu C, Kim TY, Choo SP, Trojan J, Welling TH Rd, *et al*: Nivolumab in patients with advanced hepatocellular carcinoma (CheckMate 040): An open-label, non-comparative, phase 1/2 dose escalation and expansion trial. *Lancet* 389: 2492-2502, 2017.
- Shigeta K, Matsui A, Kikuchi H, Klein S, Mamessier E, Chen IX, Aoki S, Kitahara S, Inoue K, Shigeta A, *et al*: Regorafenib combined with PD1 blockade increases CD8 T-cell infiltration by inducing CXCL10 expression in hepatocellular carcinoma. *J Immunother Cancer* 8: e001435, 2020.
- Zhu AX, Finn RS, Edeline J, Cattani S, Ogasawara S, Palmer D, Verslype C, Zagonel V, Fartoux L, Vogel A, *et al*: Pembrolizumab in patients with advanced hepatocellular carcinoma previously treated with sorafenib (KEYNOTE-224): A non-randomised, open-label phase 2 trial. *Lancet Oncol* 19: 940-952, 2018.
- Xu J, Shen J, Gu S, Zhang Y, Wu L, Wu J, Shao G, Zhang Y, Xu L, Yin T, *et al*: Camrelizumab in combination with apatinib in patients with advanced hepatocellular carcinoma (RESCUE): A nonrandomized, open-label, phase II trial. *Clin Cancer Res* 27: 1003-1011, 2021.
- Duan X, Li H, Kuang D, Chen P, Zhang K, Li Y, He X, Xing C, Wang H, Liu Y, *et al*: Transcatheter arterial chemoembolization plus apatinib with or without camrelizumab for unresectable hepatocellular carcinoma: A multicenter retrospective cohort study. *Hepatol Int* 17: 915-926, 2023.
- Liu H, Yu Q, Gu T, Qu P, Ma X, Zhou S, Lu T, Pan D and Han Z: Transarterial Chemoembolization plus Apatinib with or without Camrelizumab for the Treatment of Advanced HBV-related Hepatocellular Carcinoma. *J Gastrointest Liver Dis* 32: 182-189, 2023.
- Page MJ, McKenzie JE, Bossuyt PM, Boutron I, Hoffmann TC, Mulrow CD, Shamseer L, Tetzlaff JM, Akl EA, Brennan SE, *et al*: The PRISMA 2020 statement: An updated guideline for reporting systematic reviews. *BMJ* 372: n71, 2021.
- Azam F, Latif MF, Farooq A, Tirmazy SH, Alshahrani S, Bashir S and Bukhari N: Performance status assessment by using ECOG (Eastern Cooperative Oncology Group) score for cancer patients by oncology healthcare professionals. *Case Rep Oncol* 12: 728-736, 2019.
- Lencioni R and Llovet JM: Modified RECIST (mRECIST) assessment for hepatocellular carcinoma. *Semin Liver Dis* 30: 52-60, 2010.
- Lee DH, Son JH and Kim TW: New scoring systems for severity outcome of liver cirrhosis and hepatocellular carcinoma: Current issues concerning the Child-Turcotte-Pugh score and the Model of End-Stage Liver Disease (MELD) score. *Taehan Kan Hakhoe Chi* 9: 167-179, 2003 (In Korean).
- Wells G, Shea B, O'Connell D, Peterson J, Welch V, Losos M and Tugwell P: The Newcastle-Ottawa Scale (NOS) for assessing the quality of nonrandomised studies in meta-analyses, 2021.
- Balshem H, Helfand M, Schünemann HJ, Oxman AD, Kunz R, Brozek J, Vist GE, Falck-Ytter Y, Meerpohl J, Norris S and Guyatt GH: GRADE guidelines: 3. Rating the quality of evidence. *J Clin Epidemiol* 64: 401-406, 2011.
- Pan S, Zheng J and Shi C: Analysis and prediction of the efficacy and influencing factors of camrelizumab combined with TACE and sorafenib in the treatment of advanced hepatocellular carcinoma. *J Cancer Res Clin Oncol* 149: 12479-12487, 2023.
- Sun B, Zhang L, Sun T, Ren Y, Cao Y, Zhang W, Zhu L, Guo Y, Gui Y, Liu F, *et al*: Safety and efficacy of lenvatinib combined with camrelizumab plus transcatheter arterial chemoembolization for unresectable hepatocellular carcinoma: A two-center retrospective study. *Front Oncol* 12: 982948, 2022.
- Sun T, Ren Y, Sun B, Chen L, Zhu L, Zhang L and Zheng C: The Feasibility of TACE Combined with TKIs Plus PD-1 Antibody for Advanced HCC. *J Hepatocell Carcinoma* 10: 447-457, 2023.
- Xiang Z, Li G, Mu L, Wang H, Zhou C, Yan H and Huang M: TACE combined with lenvatinib and camrelizumab for unresectable multiple nodular and large hepatocellular carcinoma (>5 cm). *Technol Cancer Res Treat* 22: 15330338231200320, 2023.
- Zhu D, Ma K, Yang W, Zhou HF, Shi Q, Ren JW, Xie YG, Liu S, Shi HB and Zhou WZ: Transarterial chemoembolization plus apatinib with or without camrelizumab for unresected hepatocellular carcinoma: A two-center propensity score matching study. *Front Oncol* 12: 1057560, 2022.

38. Yang C, Zhang H, Zhang L, Zhu AX, Bernards R, Qin W and Wang C: Evolving therapeutic landscape of advanced hepatocellular carcinoma. *Nat Rev Gastroenterol Hepatol* 20: 203-222, 2023.
39. Esagian SM, Kakos CD, Giorgakis E, Burdine L, Barreto JC and Mavros MN: Adjuvant transarterial chemoembolization following curative-intent hepatectomy versus hepatectomy alone for hepatocellular carcinoma: A systematic review and meta-analysis of Randomized controlled trials. *Cancers (Basel)* 13: 2984, 2021.
40. Rizzo A, Ricci AD and Brandi G: Immune-based combinations for advanced hepatocellular carcinoma: Shaping the direction of first-line therapy. *Future Oncol* 17: 755-757, 2021.
41. Giuliano S and Pagès G: Mechanisms of resistance to anti-angiogenesis therapies. *Biochimie* 95: 1110-1119, 2013.
42. Mukherji SK: Bevacizumab (Avastin). *AJNR Am J Neuroradiol* 31: 235-236, 2010.
43. Mou L, Tian X, Zhong B, Zhan Y, Chen J, Lu Y, Deng J, Deng Y, Wu Z, Li Q, *et al*: Improving outcomes of tyrosine kinase inhibitors in hepatocellular carcinoma: New data and ongoing trials. *Front Oncol* 11: 752725, 2021.
44. Hou Z, Zhu K, Yang X, Chen P, Zhang W, Cui Y, Zhu X, Song T, Li Q, Li H and Zhang T: Apatinib as first-line treatment in patients with advanced hepatocellular carcinoma: A phase II clinical trial. *Ann Transl Med* 8: 1047, 2020.
45. Mazzolini GD and Malvicini M: Immunostimulatory monoclonal antibodies for hepatocellular carcinoma therapy. Trends and perspectives. *Medicina (B Aires)* 78: 29-32, 2018.
46. Finn RS, Ryoo BY, Merle P, Kudo M, Bouattour M, Lim HY, Breder V, Edeline J, Chao Y, Ogasawara S, *et al*: Pembrolizumab as second-line therapy in patients with advanced hepatocellular carcinoma in KEYNOTE-240: A Randomized, double-blind, phase III trial. *J Clin Oncol* 38: 193-202, 2020.
47. Qiu Z, Shen L, Chen S, Qi H, Cao F, Xie L and Fan W: Efficacy of apatinib in transcatheter arterial chemoembolization (TACE) refractory intermediate and advanced-stage hepatocellular carcinoma: A propensity score matching analysis. *Cancer Manag Res* 11: 9321-9330, 2019.
48. Peng Z, Fan W, Zhu B, Wang G, Sun J, Xiao C, Huang F, Tang R, Cheng Y, Huang Z, *et al*: Lenvatinib combined with transarterial chemoembolization as first-line treatment for advanced hepatocellular carcinoma: A phase III, Randomized clinical trial (LAUNCH). *J Clin Oncol* 41: 117-127, 2023.
49. Tashrifwala FAA, Karmani VK, Haider I, Syeda AZ, Noorani A, Mustafa MS, Dave T and Hafeez H: Efficacy of transarterial chemoembolization combined with camrelizumab in the treatment of hepatocellular carcinoma: A systematic review and meta-analysis. *Cureus* 15: e48673, 2023.
50. Zheng L, Fang S, Wu F, Chen W, Chen M, Weng Q, Wu X, Song J, Zhao Z and Ji J: Efficacy and Safety of TACE combined with sorafenib plus immune checkpoint inhibitors for the treatment of intermediate and advanced TACE-Refractory hepatocellular carcinoma: A retrospective study. *Front Mol Biosci* 7: 609322, 2021.
51. Ke Q, Xin F, Fang H, Zeng Y, Wang L and Liu J: The significance of transarterial chemo(embolization) combined with tyrosine kinase inhibitors and immune checkpoint inhibitors for unresectable hepatocellular carcinoma in the Era of systemic therapy: A systematic review. *Front Immunol* 13: 913464, 2022.
52. Zou X, Xu Q, You R and Yin G: Correlation and efficacy of TACE combined with lenvatinib plus PD-1 inhibitor in the treatment of hepatocellular carcinoma with portal vein tumor thrombus based on immunological features. *Cancer Med* 12: 11315-11333, 2023.
53. Chen S, Wu Z, Shi F, Mai Q, Wang L, Wang F, Zhuang W, Chen X, Chen H, Xu B, *et al*: Lenvatinib plus TACE with or without pembrolizumab for the treatment of initially unresectable hepatocellular carcinoma harbouring PD-L1 expression: A retrospective study. *J Cancer Res Clin Oncol* 148: 2115-2125, 2022.
54. Liu J, Wang P, Shang L, Zhang Z, Tian Y, Chen X, Ma Y and Shao H: TACE plus tyrosine kinase inhibitors and immune checkpoint inhibitors versus TACE plus tyrosine kinase inhibitors for the treatment of patients with hepatocellular carcinoma: A meta-analysis and trial sequential analysis. *Hepatol Int* 18: 595-609, 2024.
55. Gong A and Li X: The efficacy and safety of Apatinib combined with TACE in the treatment of hepatocellular carcinoma: A meta-analysis. *World J Surg Oncol* 20: 69, 2022.
56. Khan KA and Kerbel RS: Improving immunotherapy outcomes with anti-angiogenic treatments and vice versa. *Nat Rev Clin Oncol* 15: 310-324, 2018.
57. Wang Q, Gao J, Di W and Wu X: Anti-angiogenesis therapy overcomes the innate resistance to PD-1/PD-L1 blockade in VEGFA-overexpressed mouse tumor models. *Cancer Immunol Immunother* 69: 1781-1799, 2020.
58. Cai M, Huang W, Huang J, Shi W, Guo Y, Liang L, Zhou J, Lin L, Cao B, Chen Y, *et al*: Transarterial chemoembolization combined with lenvatinib Plus PD-1 inhibitor for advanced hepatocellular carcinoma: A retrospective cohort study. *Front Immunol* 13: 848387, 2022.
59. Teng Y, Ding X, Li W, Sun W and Chen J: A retrospective study on therapeutic efficacy of transarterial chemoembolization combined with immune checkpoint inhibitors plus lenvatinib in patients with unresectable hepatocellular carcinoma. *Technol Cancer Res Treat* 21: 15330338221075174, 2022.
60. Wu JY, Yin ZY, Bai YN, Chen YF, Zhou SQ, Wang SJ, Zhou JY, Li YN, Qiu FN, Li B and Yan ML: Lenvatinib Combined with Anti-PD-1 antibodies plus transcatheter arterial chemoembolization for unresectable hepatocellular carcinoma: A Multicenter retrospective study. *J Hepatocell Carcinoma* 8: 1233-1240, 2021.
61. Raoul JL, Sangro B, Forner A, Mazzaferro V, Piscaglia F, Bolondi L and Lencioni R: Evolving strategies for the management of intermediate-stage hepatocellular carcinoma: Available evidence and expert opinion on the use of transarterial chemoembolization. *Cancer Treat Rev* 37: 212-220, 2011.
62. Yang XG, Sun YY, Wang HQ, Li DS, Xu GH and Huang XQ: Efficacy and safety of transarterial chemoembolization combining sorafenib with or without immune checkpoint inhibitors in previously treated patients with advanced hepatocellular carcinoma: A propensity score matching analysis. *Front Oncol* 12: 914385, 2022.
63. Liu J, Wei S, Yang L, Yu J, Yan D and Yi P: Efficacy and safety of transarterial chemoembolization plus lenvatinib with or without programmed death-1 inhibitors in the treatment of unresectable hepatocellular carcinoma: A systematic review and meta-analysis. *J Cancer Res Clin Oncol* 149: 14451-14461, 2023.
64. Zhao S, Ren S, Jiang T, Zhu B, Li X, Zhao C, Jia Y, Shi J, Zhang L, Liu X, *et al*: Low-Dose apatinib optimizes tumor microenvironment and potentiates antitumor effect of PD-1/PD-L1 blockade in lung cancer. *Cancer Immunol Res* 7: 630-643, 2019.

