

CLINICAL VIGNETTE

Hip arthroscopy as a treatment for obturator neuropathy secondary to intra-pelvic ganglion: a case report

Ira Bachar Avnieli¹, Eyal Amar², Ben Efrima³, Yehuda Kollander⁴, Ehud Rath^{2*} and Harrison Volaski⁵

¹Department of Orthopedics, Barzilai Medical Center, 2 Hahistadrout St., Ashkelon 7830604, Israel,

²Minimal Invasive Orthopedics Unit, Tel-Aviv Sourasky Medical Center, 6 Weizman St., Tel-Aviv 6423906, Israel,

³Orthopedics Division, Tel-Aviv Sourasky Medical Center, 6 Weizman St., Tel-Aviv 6423906, Israel,

⁴Orthopedic Oncology Unit, Tel-Aviv Sourasky Medical Center, 6 Weizman St., Tel-Aviv 6423906, Israel and

⁵Sackler School of Medicine

*Correspondence to: E. Rath. E-mail: ehudr@tlvmc.gov.il

Submitted 27 April 2018; revised version accepted 2 July 2018

ABSTRACT

The most common types of cystic lesions around the hip joint are synovial or ganglion cysts. In rare cases, the cysts can compress adjacent structures and cause symptoms to arise. Obturator neuropathy secondary to a hip ganglion cyst is a rare phenomenon, with scarce reports on suggested treatment options. Hip arthroscopy is a potential minimally invasive treatment that has yet to be described in such cases. We present a 52-year-old male suffering from obturator neuropathy caused by an intra-pelvic ganglion cyst arising from the hip joint. Hip arthroscopy was performed for decompression of the cyst and dilation of the stalk opening. Six-month post-operative follow-up showed resolution of symptoms and complete elimination of the cyst on magnetic resonance imaging.

CASE REPORT

A 52-year-old male presented with right groin pain associated with medial thigh pain for the past one and a half years. There was no prior trauma to the hip or pelvic region. His medical history consisted of diabetes mellitus type 2 and leukemia, for which he received bone marrow transplantation 15 years prior to presentation.

On physical examination, he had a noticeable abnormally wide gait pattern—with the right leg in an abducted and externally rotated position. He had local tenderness above the right lower abdomen and thigh adductor muscles. Sensation was reduced on the medial thigh. Hip range of motion was full and without noticeable pain on flexion adduction and abduction.

Magnetic resonance imaging (MRI) examination revealed an intra-pelvic ganglion cyst (17 × 20 mm) medial

to the right ilio-ischial line (Fig. 1A and B). The cyst stalk communicated directly with the medial hip joint (Fig. 1C). Edema and muscle atrophy of the right obturator externus adductor muscles was noted (Fig. 1D and E).

Hip arthroscopy was performed for decompression of the ganglion cyst and dilation of the stalk opening. Antero-lateral viewing portal and a modified anterior working portal were used. The stalk origin was identified at the supero-medial joint capsule. Gentle suction was applied during the process and fluid from the cyst was visualized entering the hip joint, confirming the location of the connecting stalk (Fig. 2A).

After suction decompression of the cyst, the stalk opening was dilated using a 3.5 mm full radius shaver (Smith & Nephew, Andover, MA, USA). A 10 mm round capsular window was created to form an opening that provided a

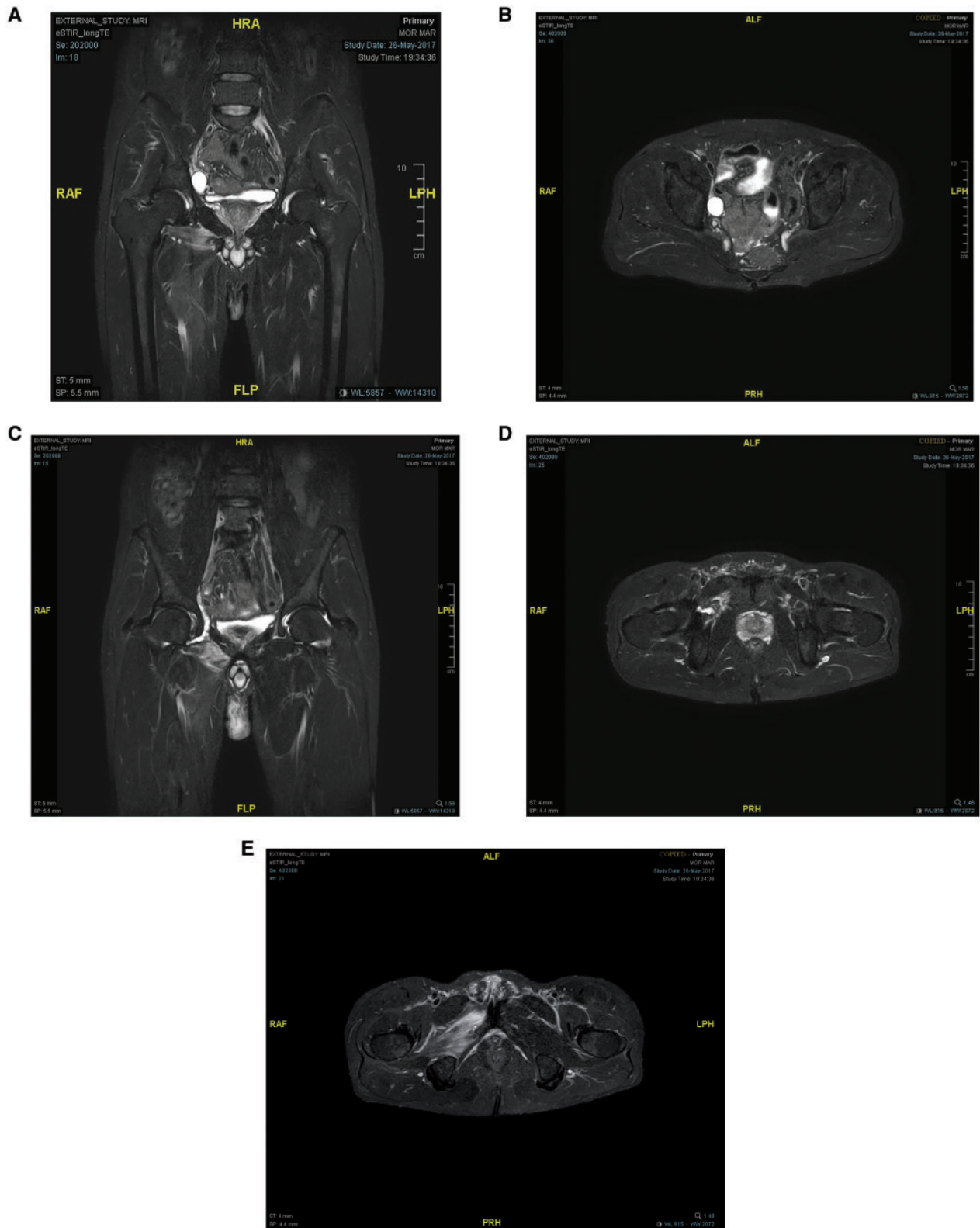


Fig. 1. (A, B) A ganglion cyst medial to the right ilio-ischial line and protruding into the pelvis. Adductor muscle edema is observed in (A). (C) The stalk of the cyst with contiguity to the hip joint. Edema and muscle atrophy involving the right adductor muscles (D) and obturator externus (E).

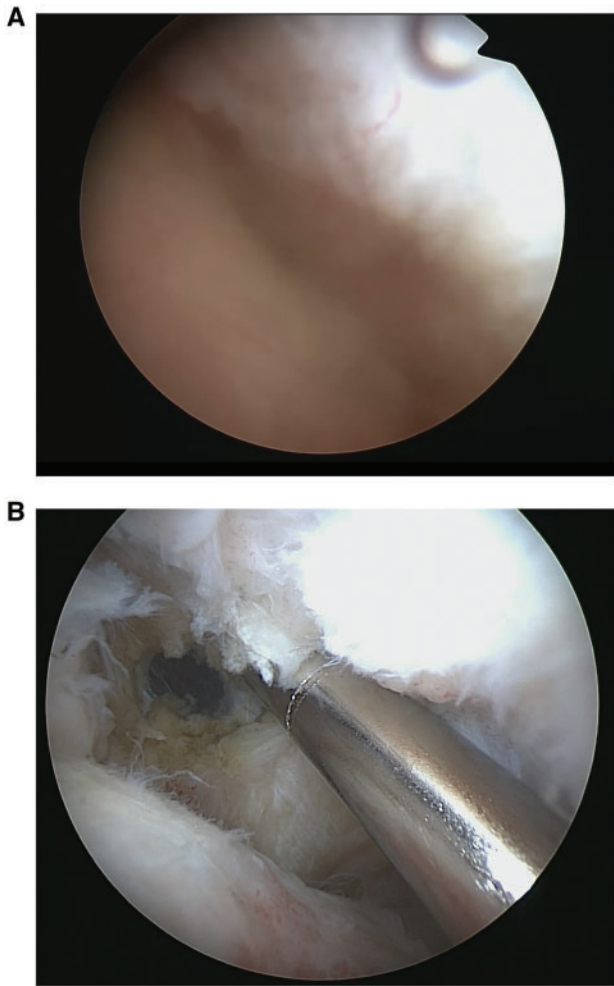


Fig. 2. Fluid from within the ganglion cyst decompressing into the hip joint (A) and the stalk opening eliminated using a shaver after debridement (B).

path of least resistance for synovial fluid drainage to prevent refilling of the ganglion (Fig. 2B).

Three weeks after surgery, the patient was pain free and resumed normal gait pattern. Surgical scars were intact. The adductor muscles were not tender to palpation. Hip range of motion was full and without pain.

At 6 months post-surgery, the patient was pain free. A follow-up MRI 6 months after surgery showed complete elimination of the cyst (Fig. 3A and B).

DISCUSSION

Cystic lesions surrounding and connecting to the hip joint are often fluid-filled, herniated sacs derived from the joint space through a one-way valve mechanism. They can be histologically classified as synovial or ganglion cysts. Ganglion cysts are contained within a capsule consisting of

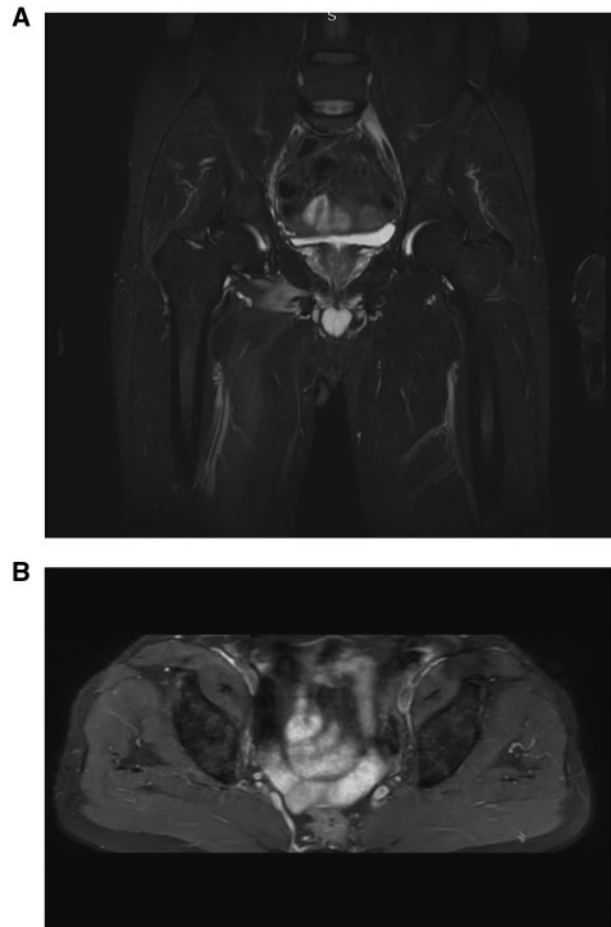

Fig. 3. Updated MRI without evidence of cyst remanence.

connective tissue and fibrocytes. The content is composed of a highly viscous gelatinous fluid, rich in mucopolysaccharides and hyaluronic acid. The pathogenesis of ganglion cysts may be myxomatous degeneration of certain fibrous tissues. Importantly, no lining cells are present [1]. A synovial cyst differs from a ganglion cyst in that it is lined with synovial cells. It appears when chronic inflammation of the hip joint is present, secondary to osteoarthritis, gout, pseudogout, rheumatoid arthritis, infections and post-traumatic degenerative changes [2, 3]. Resultant compression of intra-pelvic structures may occur. These structures include blood vessels, inguinal structures, and nerves.

Our patient presented with the primary complaint of hip and groin pain. His gait pattern, adductor muscle tenderness and reduced sensation of the medial thigh were suggestive of obturator neuropathy. An MRI confirmed the diagnosis of a ganglion cyst. The cyst was visualized to be protruding into the pelvis, compressing the obturator nerve and communicating with the hip joint.

The recommended treatment for ganglion cysts is determined by the location of the cyst and associated symptoms. Common treatment options include observation, aspiration, open excision or arthroscopic excision.

While synovial or ganglion cysts surrounding the hip joint are common, obturator neuropathy caused by intra-pelvic cyst formation is an extremely rare phenomenon [3]. Only four cases of cyst formation with resultant obturator neuropathy have been reported to date. Campeas et al. reported a ganglion cyst arising from the hip joint in a 33-year-old male with medial thigh pain and no palpable mass [7]. His MRI demonstrated a cyst extending through the obturator canal and emerging from the obturator foramen in the proximity of the inferior recess of the left hip joint capsule. The cyst was explored and excised. Yukata et al. reported a 75-year-old woman with osteoarthritis of the hip joint and associated labral cyst compressing the obturator nerve [8]. A sonographic guided aspiration was performed. A synovial cyst compressing the femoral and obturator nerves was described by Stuplich et al. in a 57-year-old osteoarthritic male [9]. The patient underwent hip arthroplasty and the cyst was drained during the operation. However, the authors state the cyst was not removed due to a different surgical approach being required. Kim et al. reported on a 63-year-old male with a para-labral cyst with obturator neuropathy demonstrated by electromyographic studies [10]. In this case, the patient was treated conservatively, with a decrease in symptoms, but not resolution.

Our patient was successfully treated by hip arthroscopy, following the basic principles of one-way valve destruction, decompression of the cyst and shifting the pressure gradient into the hip joint space. The basic principles of arthroscopic treatment of a ganglion cyst can be analogous to the treatment of meniscal cysts of the knee. Ahn et al. described a surgical technique to decompress and destruct the unidirectional valve mechanism caused by the capsular fold within the orifice of the cyst [4]. An excisional debridement of the cyst is not needed unless septa are visualized through the orifice. Disappearance or marked reduction in cyst size was seen in all patients, and 94% improved in clinical scores. Other studies stress the importance of eliminating the one-way valve mechanism as

well [5, 6]. While conceptually similar, hip arthroscopy for the treatment of a ganglion cyst arising from the hip joint has not been reported. Additionally, the destruction of the cyst orifice enables shifting of the pressure gradient between the hip joint space and the cyst cavity. Thus, reducing the recurrence of cyst formation and allowing drainage of the cyst.

CONCLUSION

Hip arthroscopy is a minimally invasive technique that can be safely and effectively used in the treatment of cysts originating from the hip joint with intra-pelvic-related nerve compression syndromes.

CONFLICT OF INTEREST STATEMENT

None declared.

REFERENCES

1. Soren A. Pathogenesis and treatment of ganglion. *Clin Orthop Relat Res* 1966; **48**: 173–9.
2. Treadwell EL. Synovial cysts and ganglia: the value of magnetic resonance imaging. *Semin Arthritis Rheum* 1994; **24**: 61–70.
3. Yukata K. Cystic lesion around the hip joint. *World J Orthop* 2015; **6**: 688.
4. Ahn JH, Lee SH, Yoo JC et al. Arthroscopic treatment of popliteal cysts: clinical and magnetic resonance imaging results. *Arthroscopy* 2010; **26**: 1340–7.
5. Takahashi M, Nagano A. Arthroscopic treatment of popliteal cyst and visualization of its cavity through the posterior portal of the knee. *Arthroscopy* 2005; **21**: 638.e1–4.
6. Sansone V, De Ponti A. Arthroscopic treatment of popliteal cyst and associated intra-articular knee disorders in adults. *Arthroscopy* 1999; **15**: 368–72.
7. Campeas S, Rafii M. Pelvic presentation of a hip joint ganglion: a case report. *Bull Hosp Jt Dis* 2003; **61**: 89–92.
8. Yukata K, Arai K, Yoshizumi Y et al. Obturator neuropathy caused by an acetabular labral cyst: MRI findings. *AJR Am J Roentgenol* 2005; **184**: S112–4.
9. Stuplich M, Hottinger AF, Stoupis C et al. Combined femoral and obturator neuropathy caused by synovial cyst of the hip. *Muscle Nerve* 2005; **32**: 552–4.
10. Kim SH, Seok H, Lee SY, Park SW. Acetabular paralabral cyst as a rare cause of obturator neuropathy: a case report. *Ann Rehabil Med* 2014; **38**: 427–32.