

Temporoparietal Flap for Facial Reconstruction: Donor Site Morbidity

Amin Rahpeyma ^{1,2}, Saeedeh Khajehahmadi ^{2,3*}

1. Oral & Maxillofacial Diseases Research Center, University of Medical Sciences, Mashhad, Iran
2. Department of Oral and Maxillofacial Surgery, School of Dentistry, University of Medical Sciences, Mashhad, Iran
3. Dental Research Center, University of Medical Sciences, Mashhad, Iran

ABSTRACT

Background: Temporoparietal flap (TPF) is recommended when thin delicate tissue for medium sized defect is needed. The most used form of this flap is for auricle reconstruction. In this article usage of this flap for facial reconstruction other than auricle is discussed, emphasizing on donor site morbidity.

Method: In this retrospective study, archived files of the Department of Oral and Maxillofacial Surgery, University of Medical Sciences, Mashhad, Iran were evaluated from 2016-2020. Patients whom TPF was used for facial reconstruction were included. Flap survival was checked and donor site morbidity was evaluated in the form of skin scar and frontal nerve branch injury.

Results: This flap was used in 8 patients for facial reconstruction. All the cases had experienced Alopecia and this was the greatest when the skin of scalp was also included. All of the patients could elevate the eyebrow that means intact frontal branch of facial nerve.

Conclusion: TPF is a versatile flap for facial reconstruction. However, alopecia is high in composite fasciocutaneous form of this flap.

KEYWORDS

Temporoparietal flap; Facial reconstruction; Donor site morbidity

Please cite this paper as:

Rahpeyma A, Khajehahmadi S. Temporoparietal Flap for Facial Reconstruction: Donor Site Morbidity. *World J Plast Surg.* 2024;13(1):87-91.
doi: 10.61186/wjps.13.1.87

INTRODUCTION

Defects in the face come from traumatic, pathologic or congenital events. Based on anatomic location, size and depth of the defect, different flaps have been suggested¹.

Temporoparietal flap (TPF) is recommended when thin delicate tissue for medium sized defect is needed². This flap can be harvested in fascia, fasciocutaneous and osteofascial forms and can be used for reconstruction of frontal, eyebrow, external ear, lateral temporal, infraorbital, upper and lower lips³⁻⁷. (Fig. 1).

The most used form of this flap is for auricle reconstruction⁸. In this article usage of this flap for facial reconstruction other than auricle is discussed emphasizing on donor site morbidity.

*Corresponding Author:

Saeedeh khajehahmadi

Postal Address: Dental Research Center, University of Medical Sciences, Mashhad, Iran

Tel.: +98(51)38829501

Email: khajehahmadis@mums.ac.ir

Received: 15/10/2023

Accepted: 10/01/2024

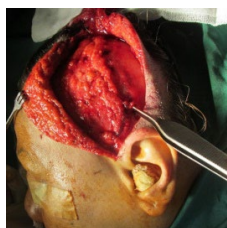


Figure 1a: Types of TPF based on composition a) Fascial

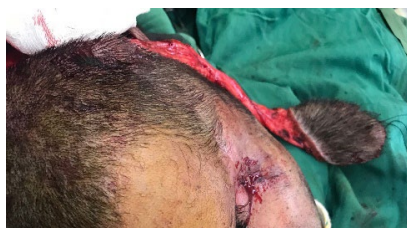

Figure 1b: Types of TPF based on composition b) Fascio-cutaneous

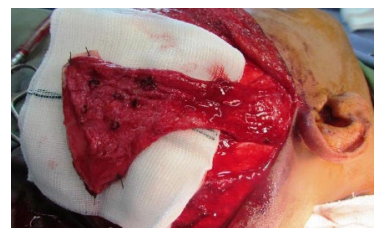

Figure 1c: Types of TPF based on composition c) Osteo-fascia

Table 1: Demographic information's of eight patients with TPF for facial reconstruction

Cases	Age	Sex	Location of defect	Etiology	Type of flap	Donor site morbidity (Alopecia)
1	12	M	Frontal	Trauma	Fascia	+
2	28	M	Frontal	Trauma	Fascia	+
3	18	M	Lateral temporal	Trauma	Fascia	+
4	65	M	Infraorbital	Trauma	Fascia	+
5	72	F	Mandibular angle	Pathology (SCC)	Fascia	+
6	35	M	Upper lip	Trauma	FC	+++
7	28	M	Inferior orbital rim	Pathology (COF)	OF	+
8	48	M	Maxilla	Pathology (SCC)	FC	++

Abbreviations: M: Male; FC: Fascio-cutaneous; F: Female; OF: Osteo-Fascial; SCC: Squamous Cell Carcinoma; COF: Cemento-ossifying fibroma

METHODS

In this retrospective study, archived files of the Department of Oral and Maxillofacial Surgery, University of Medical Sciences, Mashhad, Iran were evaluated from 2016-2020. Patients whom TPF was used for facial reconstruction were included. Flap survival was checked and donor site morbidity was evaluated in the form of skin scar and frontal nerve branch injury.

ETHICAL APPROVAL

All procedures were approved by the institutional Ethics Committee number 940121.

RESULTS

This flap was used in 8 patients for facial reconstruction that shown in Table 1. Patients were trauma cases and the others had defects from pathologic resection.

Schematic Fig. 2 shows the location of defects. Fascia form of flap was the most used form (5/8) (Fig.3).

Donor site morbidity: All the cases had experienced Alopecia and this was the greatest when the skin of

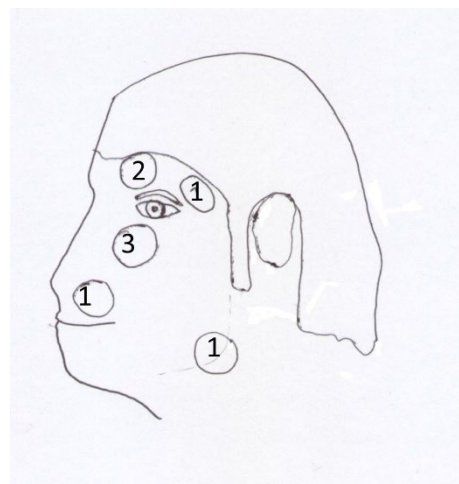


Figure 2: Schematic defect sites. Digit in circles indicates to the number of patients

scalp was also included (Fig. 4). Flap was survived in all cases but flap congestion occurred in a case (Fig. 5). All of the patients could elevate the eyebrow that means intact frontal branch of facial nerve.

DISCUSSION

Different flaps have been introduced for facial reconstruction. One important factor to choose a flap among available ones, is donor site morbidity

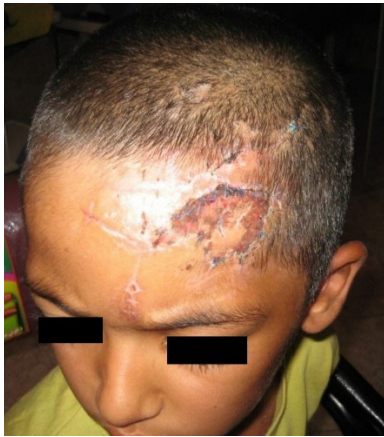

Figure 3a: Temporoparietal fascia with skin graft is used to cover traumatic avulsion in frontal region

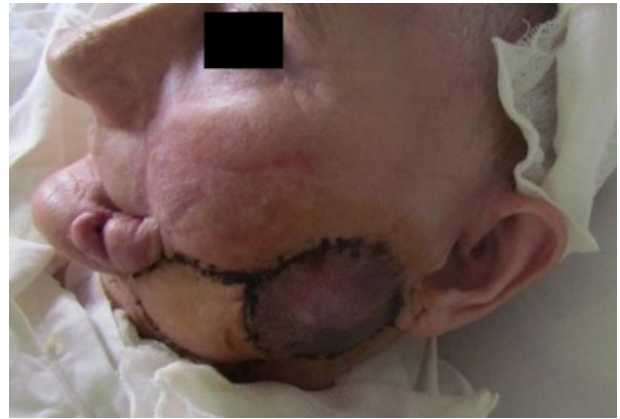

Figure 5: Flap congestion

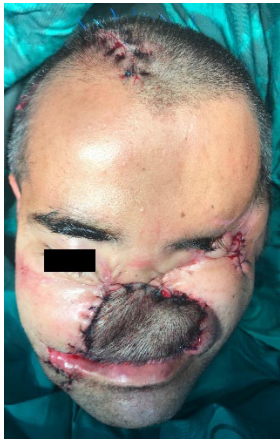

Figure 3b: Upper lip reconstruction

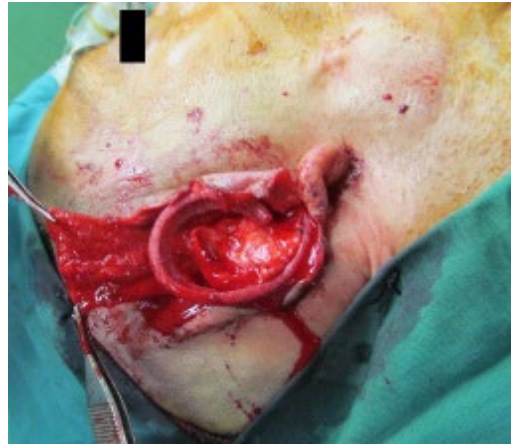


Figure 6: Temporoparietal fascia flap for auricle reconstruction

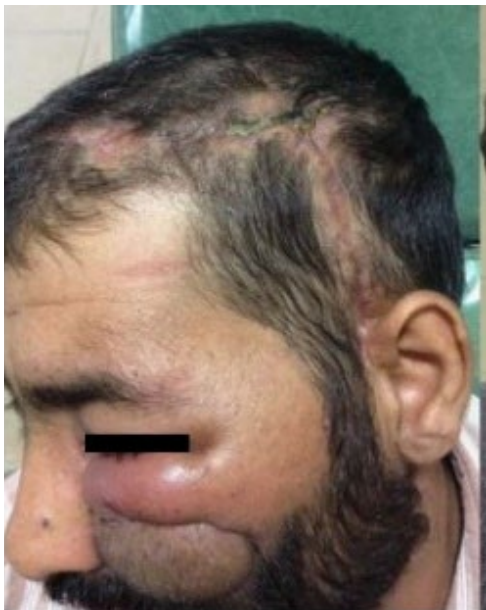

Figure 4: Alopecia around skin incision and harvested skin site. Hair bearing temporoparietal composite flap was used for infraorbital reconstruction

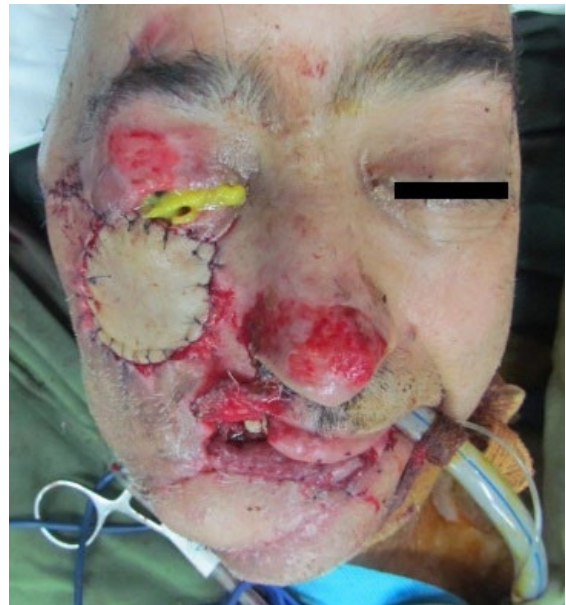

Figure 7: Infraorbital reconstruction with non-hair bearing temporoparietal composite flap

^{2,9}. The most prevalent form of temporoparietal flap is fascia form that is used for auricle reconstruction (Fig. 6). This form has the lowest complication rate with alopecia as the most frequent and damage to the frontal branch of facial, nerve as the most important complication ¹⁰.

Alopecia is due to subfollicular plane of dissection and damage to hair follicles or electrocautery damage during hemostasis ¹¹.

In composite TPF, where the scalp skin is also included, severity of complications also increased. Width of the harvested skin should be around 2cm to allow primary closure by aid of local flaps, however flap closure under tension leads to edge necrosis and wound dehiscence ¹². Secondary wound healing leads to ugly scar in visible region.

Good blood supply of TPF come from delicate surgical technique that preserve superficial temporal artery and veins. Clip ligation of these vessels during onco-surgery and prior radiotherapy of the face endangers flap blood supply. Broad pedicle is also recommended to prevent flap congestion ¹³.

Pivot point of this pedicled flap is at the junction of auricle with scalp. This flap can reach to all area of the face. Bipedicled variant is recommended for lip reconstruction, however with frustrating waiting time for pedicle division ¹⁴.

Composite TPF is almost used in male patients for reconstruction of hair bearing area of the face such as eyebrows, mustache and beards ¹⁵. In bald male patient it also can be used for non-hair bearing areas (Fig. 7).

CONCLUSION

TPF is a versatile flap for facial reconstruction. However, alopecia is high especially in composite fasciocutaneous form of this flap.

FUNDING

This study was supported by a grant from the Vice Chancellor of Research of Mashhad University of Medical Sciences. The results presented in this work have been taken from thesis number 940121.

COMPETING INTERESTS

None.

REFERENCES

1. Agbara R, Obiadazie AC, Fomete B, Omeje KU. Orofacial Soft Tissue Reconstruction with Locoregional Flaps in a Health Resource-Depleted Environment: Experiences from Nigeria. *Arch Plast Surg* 2016 May;**43**(3):265-71.
2. Squaquara R, Kim Evans KF, Spanio di Spilimbergo S, Mardini S. Intraoral reconstruction using local and regional flaps. *Semin Plast Surg* 2010 May;**24**(2):198-211.
3. Elbanoby TM, Zidan SM, Elbatawy AM, Aly GM, Sholkamy K. Superficial temporal artery flap for reconstruction of complex facial defects: A new algorithm. *Arch Plast Surg* 2018 Mar;**45**(2):118-27.
4. Kurbonov U, Davlatov A, Janobilova S, Kurbanov Z, Mirshahi M. The Use of Temporoparietal Fascia Flap for Surgical Treatment of Traumatic Auricle Defects. *Plast Reconstr Surg Glob Open* 2018 May;**6**(5):e1741.
5. Winstead JM, Olson GT, Frodel JL. Reconstruction of periparotid defects using temporoparietal fascia flap with layered acellular human dermal allograft. *Craniofac Trauma Reconstr* 2012 Mar;**5**(1):19-24.
6. Movassaghi K, Lewis M, Shahzad F, May JW, Jr. Optimizing the Aesthetic Result of Parotidectomy with a Facelift Incision and Temporoparietal Fascia Flap. *Plast Reconstr Surg Glob Open* 2019 Feb;**7**(2):e2067.
7. Tanaka A, Hatoko M, Kuwahara M, Yurugi S, Iioka H, Niitsuma K. Evaluation of scars after harvest of the temporoparietal fascial flap depending on the design of the skin incision. *Ann Plast Surg* 2002 Apr;**48**(4):376-80.
8. Mokal NJ, Ghalme AN, Kothari DS, Desai M. The use of the temporoparietal fascia flap in various clinical scenarios: A review of 71 cases. *Indian J Plast Surg* 2013 Sep;**46**(3):493-501.
9. Rahpeyma A, Khajehahmadi S. Donor site morbidity in buccinator-based myomucosal flaps: A retrospective study. *Asian J Surg* 2017 May;**40**(3):210-4.
10. Demirdover C, Sahin B, Vayvada H, Oztan HY. The versatile use of temporoparietal fascial flap. *Int J Med Sci* 2011;**8**(5):362-8.
11. Scheithauer MO, Rettinger G. Operative treatment of functional facial skin disorders. *GMS Curr Top Otorhinolaryngol Head Neck Surg* 2005;**4**:Doc18.
12. Pinto FR, de Magalhães RP, Capelli Fde A, Brandão LG, Kanda JL. Pedicled temporoparietal galeal flap for reconstruction of intraoral defects. *Ann Otol Rhinol Laryngol* 2008 Aug;**117**(8):581-6.
13. Cheney ML, Varvares MA, Nadol JB, Jr. The temporoparietal fascial flap in head and neck

- reconstruction. *Arch Otolaryngol Head Neck Surg* 1993 Jun;**119**(6):618-23.
14. Min P, Li J, Brunetti B, et al. Pre-expanded bipediced visor flap: an ideal option for the reconstruction of upper and lower lip defects postburn in Asian males. 2020;**8**:tkaa005.
15. Denadai R, Raposo-Amaral CE, Marques FF, Raposo-Amaral CA. Posttraumatic eyebrow reconstruction with hair-bearing temporoparietal fascia flap. *Einstein (Sao Paulo)* 2015 Jan-Mar;**13**(1):106-9.