

Case Report

Prenatal Diagnosis of Atrioventricular Block and QT Interval Prolongation by Fetal Magnetocardiography in a Fetus with Trisomy 18 and SCN5A R1193Q Variant

Lisheng Lin,^{1,2} Miho Takahashi-Igari,¹ Yoshiaki Kato,¹ Yoshihiro Nozaki,¹ Mana Obata,³ Hiromi Hamada,³ and Hitoshi Horigome^{1,2}

¹Department of Child Health, University of Tsukuba, Tsukuba, Japan

²Department of Pediatric Cardiology, Ibaraki Children's Hospital, Mito, Japan

³Department of Obstetrics and Gynecology, University of Tsukuba, Tsukuba, Japan

Correspondence should be addressed to Lisheng Lin; rin-ham@umin.ac.jp

Received 17 February 2017; Accepted 2 May 2017; Published 30 May 2017

Academic Editor: Seyed Mohsen Dehghani

Copyright © 2017 Lisheng Lin et al. This is an open access article distributed under the Creative Commons Attribution License, which permits unrestricted use, distribution, and reproduction in any medium, provided the original work is properly cited.

We report a case of fetal trisomy 18 with SCN5A R1193Q variant that presented with sinus bradycardia, 2:1 atrioventricular block (AVB), and QT interval prolongation. These complex arrhythmias were diagnosed by fetal magnetocardiography combined with ultrasound findings. Advanced AVB and ventricular arrhythmias were confirmed after birth. Genetic testing of the baby revealed a SCN5A R1193Q variant, which we considered could account for the various arrhythmias in this case.

1. Introduction

Fetuses with trisomy 18 tend to present bradycardia, but further electrophysiological details have not fully been investigated [1, 2]. In the present case, bradycardia and atrioventricular block (AVB) were observed by fetal echocardiography. Further details such as QT interval prolongation and functional AVB due to prolonged ventricular repolarization were accurately diagnosed by fetal magnetocardiography (fMCG). A SCN5A gene variant (R1193Q) was identified after birth, which might have attributed to the complex arrhythmias in this patient.

2. Case Presentation

The mother was referred to our hospital at 20 weeks of gestation due to fetal bradycardia, fetal growth retardation, oligohydramnios, and overlapping fingers detected on fetal ultrasound. The fetus was suspected to have chromosomal abnormality, specifically trisomy 18. The parents chose not to carry out prenatal genetic diagnosis. Ventricular septal defect (VSD) and bradycardia with AVB were diagnosed by fetal

echocardiography. At 28 weeks of gestation, fMCG (MC-6400, Hitachi High-Technologies Corporation) was performed to investigate the details of arrhythmias (Figure 1). Baseline fetal heart rate was around 66 beats per minute (bpm). QT interval was prolonged and 2:1 AVB was suspected to be the so-called functional AVB, which develops due to prominently prolonged ventricular repolarization (QT 0.498 s, QTc 0.522). Torsade de pointes or other ventricular arrhythmias were not detected. At the prenatal visit, parents were informed of the possibilities of (1) the need for urgent pacemaker therapy for bradycardia after birth and (2) the occurrence of lethal arrhythmias in late pregnancy or immediately after birth.

Fetal hydrops or signs of fetal heart failure were not detected before birth. The baby (male) was born at 37 weeks and 1 day of gestation with a birth weight of 1,211 g. The Apgar scores were 8 at 1 minute and 9 at 5 minutes. Characteristic multiple minor anomalies of trisomy 18 included prominent occiput, micrognathia, and short sternum. Chromosome analysis revealed the karyotype 47, XY, +18 (trisomy 18). A large VSD (inlet type, 4 mm) and patent ductus arteriosus were observed by transthoracic echocardiography. The

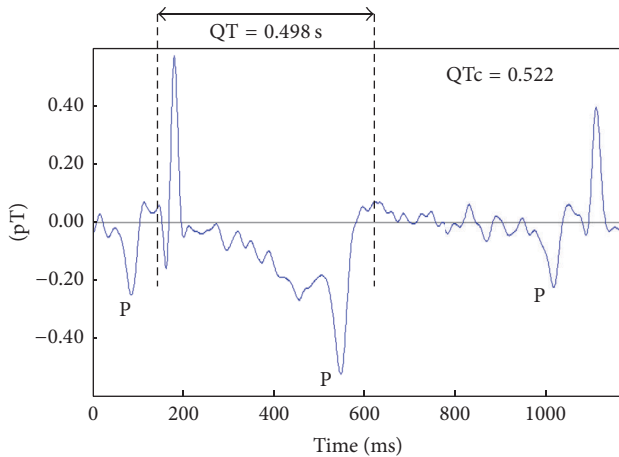


FIGURE 1: fMCG waveform at 30 weeks' gestation. QT interval was extremely prolonged (normal QT interval of the same gestational week: 0.248 ± 0.316 s [6]). P waves showed the same morphology and polarity. They were observed before the QRS complex and also in the posterior half of the T wave without following the QRS complex, which indicates a functional 2:1 AVB related to QT prolongation. pT: piko-Tesla.

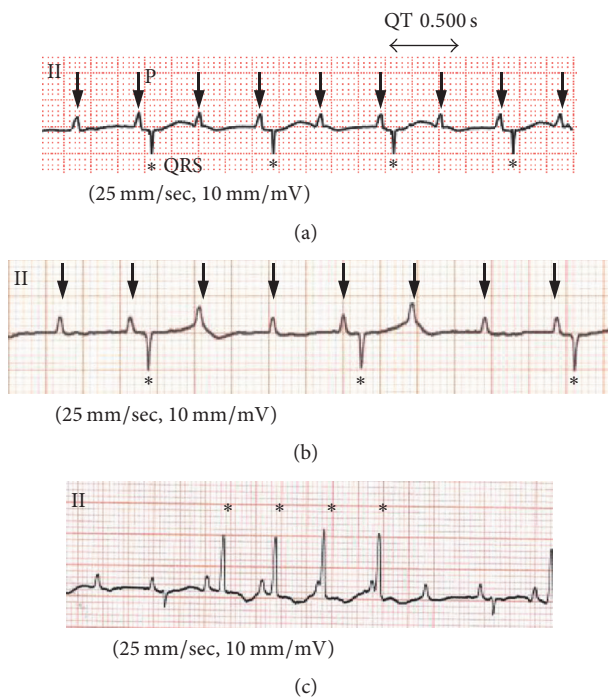


FIGURE 2: Electrocardiograms recorded after birth (arrows: P wave; asterisk: QRS complex). (a) Severe bradycardia (HR 60–70 bpm), 2:1 AVB, and QT interval prolongation. (b) Transient 3:1 AVB. (c) Nonsustained ventricular tachycardia.

baby's resting heart rate was 60–70 bpm. A grade of 2:1 or higher (transiently, 3:1) AVB and QT interval prolongation were recorded on electrocardiogram (ECG) (Figures 2(a) and 2(b)). Nonsustained ventricular tachycardia was also observed (Figure 2(c)). Considering the poor prognosis of trisomy 18, the parents did not consent to aggressive

treatments such as pacemaker implantation for bradycardia nor surgical closure of VSD. The patient died at 85 days postnatally, because of progressive heart failure.

Informed consent was obtained from the parents and genetic analysis of long QT candidate genes was performed (Ion PGM™ system, target exon sequencing, and direct sequencing). A *SCN5A* R1193Q variant was identified, which we considered could account for the various arrhythmias observed in this case [3–5].

3. Discussion

Trisomy 18 syndrome is usually associated with multiorgan complications and has a poor prognosis. Meanwhile, reports of its electrophysiological details are very few, and whether or not trisomy 18 has arrhythmic substrates is still unknown. To the best of our knowledge, this is the first report to describe complex arrhythmias in trisomy 18. On the other hand, *SCN5A* R1193Q (amino acid substitution of glutamine for arginine), which was identified in this case, is a variant that alters the current of cardiac sodium channel [5]. The R1193Q variant in *SCN5A* has been associated with sudden infant death syndrome (SIDS), long QT syndrome (LQTS) type 3, cardiac conduct defect, and Brugada syndrome [3, 4, 7, 8], and we consider it to be partly responsible for the various arrhythmias that were observed in this case. However, there was no previous report of coexistence of *SCN5A* mutation and trisomy 18. We believe that the coexistent *SCN5A* R1193Q variant in this case was coincidental.

fMCG makes it possible to noninvasively record weak electrical activities of the fetal heart, enabling the measurement of QT intervals of the fetus, and is therefore helpful for differential diagnosis of fetal arrhythmias, including long QT syndrome [9, 10]. In the present case, using fMCG, we made an accurate diagnosis of complex arrhythmias that consisted of sinus bradycardia, AVB, and QT interval prolongation. Based on the detailed information gathered from the fMCG combined with ultrasound findings, we could begin discussions about the treatment strategy earlier within the fetal period.

Ethical Approval

The manuscript is about a retrospective case that does not require ethics committee approval at our institution.

Conflicts of Interest

The authors declare that there are no conflicts of interest regarding the publication of this paper.

Acknowledgments

The authors would like to thank Mr. Kuniomi Ogata for support of fMCG data analysis and Mr. Thomas D. Mayers for native-speaker revision.

References

- [1] A. W. Liao, R. Snijders, L. Geerts, K. Spencer, and P. K. H. Nicolaides, "Fetal heart rate in chromosomally abnormal fetuses," *Ultrasound in Obstetrics and Gynecology*, vol. 16, no. 7, pp. 610–613, 2000.
- [2] W. Sepulveda, A. E. Wong, and V. Dezerega, "First-trimester sonographic findings in trisomy 18: a review of 53 cases," *Prenatal Diagnosis*, vol. 30, no. 3, pp. 256–259, 2010.
- [3] M. Arnestad, L. Crotti, T. O. Rognum et al., "Prevalence of long-QT syndrome gene variants in sudden infant death syndrome," *Circulation*, vol. 115, no. 3, pp. 361–367, 2007.
- [4] L. Crotti, D. J. Tester, W. M. White et al., "Long QT syndrome-associated mutations in intrauterine fetal death," *JAMA - Journal of the American Medical Association*, vol. 309, no. 14, pp. 1473–1482, 2013.
- [5] Q. Wang, S. Chen, Q. Chen, X. Wan, J. Shen, G. A. Hoeltge et al., "The common SCN5A mutation R1193Q causes LQTS-type electrophysiological alterations of the cardiac sodium channel," *Journal of Medical Genetics*, vol. 41, pp. e66–e66, 2004.
- [6] H. Horigome, M. I. Takahashi, M. Asaka, S. Shigemitsu, A. Kandori, and K. Tsukada, "Magnetocardiographic determination of the developmental changes in PQ, QRS and QT intervals in the fetus," *Acta Paediatrica*, vol. 89, pp. 64–67, 2000.
- [7] J. R. Skinner, S.-K. Chung, D. Montgomery et al., "Near-miss SIDS due to Brugada syndrome," *Archives of Disease in Childhood*, vol. 90, no. 5, pp. 528–529, 2005.
- [8] A. Sun, L. Xu, S. Wang et al., "SCN5A R1193Q polymorphism associated with progressive cardiac conduction defects and long QT syndrome in a Chinese family," *Journal of Medical Genetics*, vol. 45, no. 2, pp. 127–128, 2008.
- [9] D. L. Wiggins, J. F. Strasburger, N. L. Gotteiner, B. Cuneo, and R. T. Wakai, "Magnetophysiological and echocardiographic comparison of blocked atrial bigeminy and 2:1 atrioventricular block in the fetus," *Heart Rhythm*, vol. 10, no. 8, pp. 1192–1198, 2013.
- [10] J. F. Strasburger, B. Cheulkar, and R. T. Wakai, "Magnetocardiography for fetal arrhythmias," *Heart Rhythm*, vol. 5, no. 7, pp. 1073–1076, 2008.