

# Thermal Annuloplasty Using Percutaneous Endoscopic Discectomy for Elite Athletes with Discogenic Low Back Pain

Hiroaki MANABE,<sup>1</sup> Kazuta YAMASHITA,<sup>1</sup> Fumitake TEZUKA,<sup>1</sup> Yoichiro TAKATA,<sup>1</sup>  
Toshinori SAKAI,<sup>1</sup> Toru MAEDA,<sup>1</sup> and Koichi SAIRYO<sup>1</sup>

<sup>1</sup>*Department of Orthopedics, Institute of Biomedical Sciences, Tokushima University  
Graduate School, Tokushima, Tokushima, Japan*

## Abstract

The purpose of this study was to assess the usefulness of radiofrequency thermal annuloplasty (TA) using percutaneous endoscopic discectomy/TA (PED/TA) in elite athletes with discogenic low back pain. Twelve patients (11 men, 1 woman; mean age 27.9 years) underwent PED/TA under local anesthesia. Clinical data for these patients (17 affected intervertebral discs), including type of sport played, average duration of low back pain, disc level affected, presence or absence of a high signal intensity zone on magnetic resonance imaging, and whether the patient returned to playing competitive sport, were retrospectively reviewed. The most common sport played by the patient was baseball ( $n = 8$ ), followed by cycling ( $n = 2$ ), tennis ( $n = 1$ ), and hammer throw ( $n = 1$ ). The average duration of low back pain was 24.3 months. The intervertebral disc levels affected were L4/5 ( $n = 11$ ) and L5/S1 ( $n = 6$ ). A high signal intensity zone was detected in nine discs. Although two patients required additional surgery, all patients were able to return to their original competitive level of play. Duration for the return to play was 2.8 months after surgery except the two revision cases. PED/TA for discogenic pain enables an early return to competitive sports, and so is particularly useful for elite athletes.

Key words: low back pain, percutaneous endoscopic discectomy, thermal annuloplasty, elite athletes

## Introduction

The literature suggests that 75% of top-level athletes experience low back pain at least once during their sporting careers.<sup>1,2)</sup> Low back pain in elite athletes is a serious problem, and early diagnosis and appropriate treatment are required. Some reports suggest that pain originating from an intervertebral disc is relatively common, accounting for up to 26–42% of all cases of low back pain.<sup>3–5)</sup> Although low back pain is often treated conservatively, surgery may be indicated when the pain is refractory to conservative therapy or when an early return to play is desired. For athletes, it is preferable that the treatment is minimally invasive.

Percutaneous endoscopic discectomy (PED), developed by Yeung and Tsou,<sup>6)</sup> is one of the least invasive treatments available for low back pain and is

becoming increasingly popular. PED is commonly performed via a transforaminal approach under local anesthesia and requires an 8-mm skin incision, which is minimally invasive and preserves the back muscles.<sup>7,8)</sup> The PED technique is also used for chronic discogenic back pain.<sup>9,10)</sup> After selective discectomy of the degenerated disc, the posterior annulus fibrosus and site of the tear are modulated by thermal annuloplasty (TA) using a bipolar radiofrequency coagulator. This procedure (PED/TA) has been reported to be an effective treatment for discogenic low back pain.

Here, we report on our series of elite athletes with low back pain who have been treated successfully using PED/TA.

## Materials and Methods

Twelve patients (11 men, 1 woman; mean age 27.9 years) underwent PED/TA under local anesthesia between September 2009 and November 2017 were retrospectively examined. Clinical data for these 12 patients (with 17 affected intervertebral discs),

Received October 24, 2018; Accepted December 7, 2018

Copyright© 2019 by The Japan Neurosurgical Society  
This work is licensed under a Creative Commons Attribution-NonCommercial-NoDerivatives International License.

including type of sport played, average duration of low back pain, level of intervertebral disc affected, presence or absence of a high signal intensity zone (HIZ) on magnetic resonance imaging (MRI), and whether the patient returned to competitive play after PED/TA were retrospectively reviewed. All patients were diagnosed on the basis of clinical symptoms and findings on computed tomography (CT) and MRI. Discography was performed in all cases to confirm reproducible pain.

Percutaneous endoscopic discectomy/thermal annuloplasty was performed under local anesthesia using the method reported by Yeung and Tsou.<sup>9)</sup> An 8 mm incision was made 6–10 cm from the midline and a cannula was placed outside the disc. After excision of the degenerated intervertebral disc, radiofrequency cauterization and coagulation of the damaged annulus with redness was performed using a bipolar system (Fig. 1), and collation with preoperative MRI was checked via fluoroscopy during surgery. If HIZ could not be confirmed by MRI before surgery, treated the part with leakage of contrast material into the posterior annulus fibrosus on CT images of discography. The patient was permitted to walk 2 h after surgery and negative pressure drainage was continued until the next day after operation. Active stretching and core training was started early in the postoperative period.

## Results

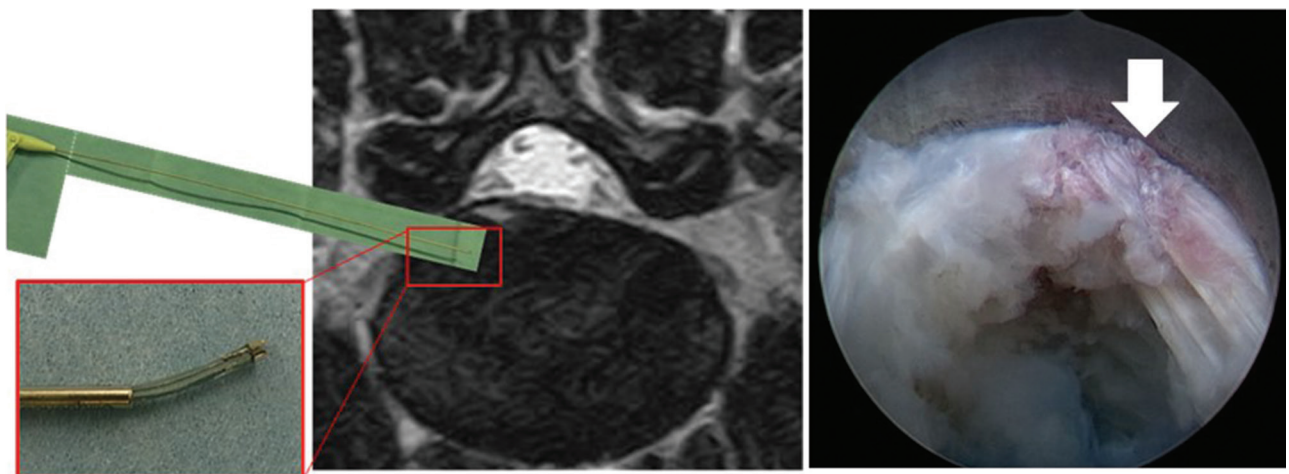
The most common sport played by the patient was baseball ( $n = 8$ ), followed by cycling ( $n = 2$ ), tennis ( $n = 1$ ), and hammer throw ( $n = 1$ ). Average duration of low back pain was 24.3 months. Intervertebral

disc levels affected were L4/5 ( $n = 11$ ) and L5/S1 ( $n = 6$ ). A HIZ was observed in nine intervertebral discs (Table 1). Although two patients required additional surgery, all patients were able to return to their original competitive level of play. Duration for the return to play was 2.8 months after surgery except the two revision cases.

**Table 1 Demographics and clinical characteristics of 12 elite athletes with discogenic pain**

Sex	Age (years)	Sports	Duration of low back pain (months)	Level	HIZ
Male	20	Baseball	8	L5/S1	–
Male	35	Baseball	10	L4/5	–
Male	32	Baseball	12	L4/5	+
Male	35	Baseball	12	L4/5	+
Male	28	Keirin	26	L4/5	–
Male	28	Tennis	36	L4/5	+
Female	30	Hammer throw	120	L4/5	+
Male	20	Road bike	6	L4/5	–
				L5/S1	–
Male	20	Baseball	9	L4/5	+
				L5/S1	+
Male	30	Baseball	14	L4/5	–
				L5/S1	+
Male	23	Baseball	19	L4/5	–
				L5/S1	+
Male	34	Baseball	20	L4/5	–
				L5/S1	+

HIZ: high signal intensity zone.



**Fig. 1** Panel shows a bipolar probe coagulating a damaged annulus in which a high signal intensity zone and a painful annular tear are causing low back pain. Arrow indicate painful annulus tears with redness.

In additional thermal annuloplasty cases, low back pain improved considerably after surgery, but mild pain inducted at the time of bending forward during the competition (road bike) remained. Follow-up MRI showed the bulging of disc persisted at operated level, the second operation was performed at 10 months later. In direct repair case, hernia-related lower extremity pain disappeared and low back pain improved enough to return to competition (tennis) after the first surgery. However, because the patient had pain due to synovitis associated with the original spondylolysis, surgery was performed at the retired timing.

#### Case 1: 30-year-old female hammer throw player

The patient had a history of low back pain of unspecified cause for more than 10 years that did not respond to conservative treatment. T<sub>2</sub>-weighted images on MRI revealed a HIZ at L4/5 (Fig. 2A). We confirmed reproducible pain by using discography and temporary pain relief by discoblock (Figs. 2B and 2C), and performed PED/TA at L4/5 under local anesthesia. The procedure time was 51 min with minimal intraoperative blood loss. The low back pain disappeared immediately after the surgery. She started conditioning 4 weeks later, resumed hammer throw after 8 weeks, and was able to take part in the Japanese championships 4 months later.

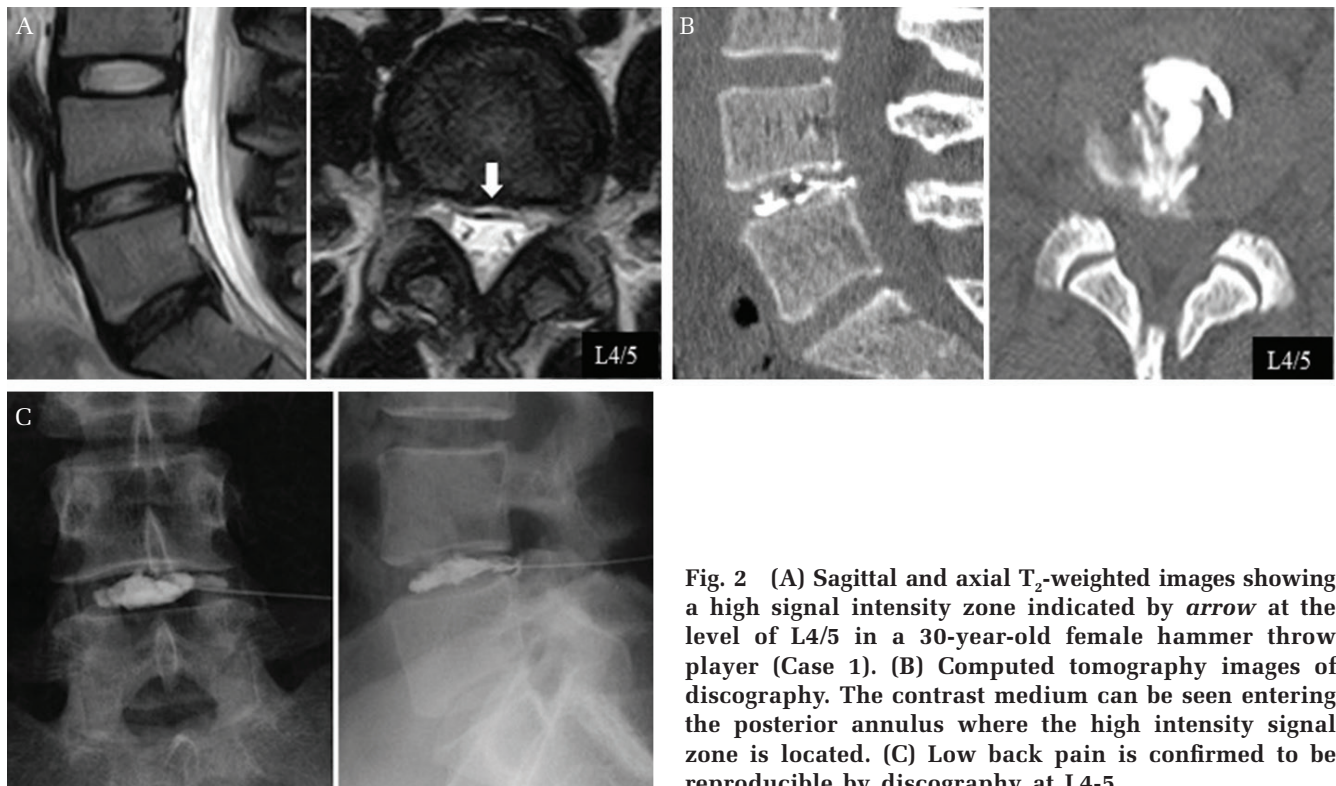


Fig. 2 (A) Sagittal and axial T<sub>2</sub>-weighted images showing a high signal intensity zone indicated by *arrow* at the level of L4/5 in a 30-year-old female hammer throw player (Case 1). (B) Computed tomography images of discography. The contrast medium can be seen entering the posterior annulus where the high intensity signal zone is located. (C) Low back pain is confirmed to be reproducible by discography at L4-5.

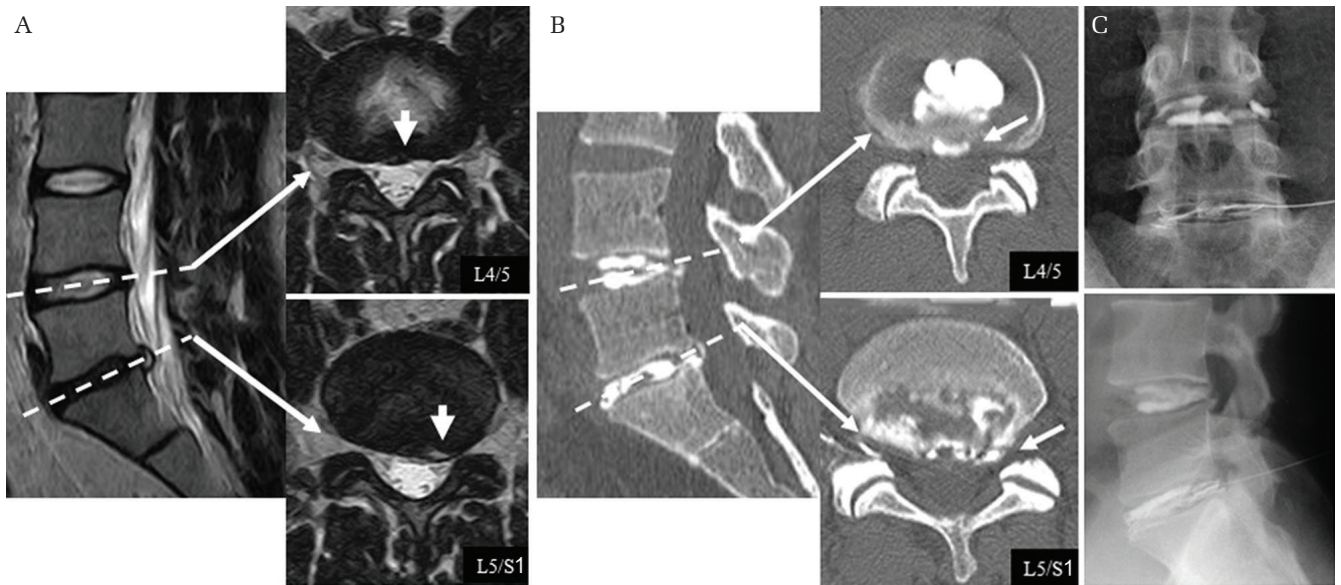
#### Case 2: 30-year-old male baseball player

This patient's back pain had started during exercise 16 months earlier. Disc degeneration had been diagnosed on several occasions when he had sought medical attention. T<sub>2</sub>-weighted images revealed posterior bulging of the intervertebral disc at L4/5 and a HIZ at L5/S1 (Fig. 3A). Discography was performed at both levels and showed leak of contrast into the posterior annulus fibrosus at both levels (Fig. 3B). Intervertebral discoblock achieved temporary pain relief (Fig. 3C). PED/TA was performed at L4/5 and L5/S1 under local anesthesia for the patient's discogenic pain. The operating time was 86 min, intraoperative blood loss was minimal, and the low back pain improved immediately after surgery. The patient started conditioning after 2 weeks, returned to practice after 4 weeks, resumed playing baseball at 6 weeks, and returned to competitive play 3 months after surgery.

## Discussion

#### Mechanism of discogenic pain

The concept of internal disc destruction leading to intervertebral degenerative and non-nerve root-induced intervertebral disc pain was first reported by Crock.<sup>11)</sup> A normal intervertebral disc is a multi-layered structure that consists of a nucleus pulposus and an annulus fibrosus with nerve fibers only on



**Fig. 3** (A) Sagittal and axial T<sub>2</sub>-weighted images that are HIZ (-) at the L4/5 level and HIZ (+) at the L5/S1 level in a 30-year-old male baseball player (Case 2). Arrows indicate bulging disc at L4/5 and HIZ at L5/S1. (B) CT images of discography showing leakage of contrast material indicated by arrow into the posterior annulus fibrosus at both intervertebral disc levels. (C) Discography and discoblock achieved reproducible low back pain and temporary pain relief at both intervertebral disc levels.

the surface. However, a degenerated intervertebral disc releases nociceptive and growth factors that lead to ingrowth of nerve fibers into the intervertebral disc,<sup>12)</sup> and the loads applied to these nerve fibers cause pain. Athletes are more likely to be subjected to repeated overload of the spine than non-athletes; therefore, they are more likely to experience back pain.<sup>13)</sup>

### Diagnosis of discogenic pain

Unlike disc herniation, the physical findings characteristic of discogenic low back pain do not include symptoms in the lower limbs, and the pain typically increases in affected patients on forward bending of the lumbar spine. The reason for this is that flexion of the lumbar spine increases the load on the anterior structures, that is, the discs and endplates of the vertebrae. Therefore, pain on bending of the lumbar spine should raise suspicion for a lesion of the intervertebral disc and its surroundings. A degenerated intervertebral disc is difficult to diagnose on plain radiographs alone except when there is clear disc degeneration, such as the appearance of a vacuum or when there is a decrease in intervertebral disc height. MRI is indispensable when an accurate diagnosis is needed. The concept of a HIZ has been debated.<sup>14)</sup> A HIZ is a region that shows as a high-intensity change at the posterior annulus fibrosus on T<sub>2</sub>-weighted images, and several reports have shown that fluid accumulates at the site of a tear

lesion at the annulus fibrosus and reflects secondary inflammatory changes.<sup>14,15)</sup> On the other hand, a HIZ does not necessarily cause low back pain, so the relation between a HIZ and low back pain remains controversial.<sup>16)</sup> In our study, a HIZ was observed in 52.9% of athletes with low back pain. Nevertheless, confirming reproducible pain and pain relief by discography and discoblock is essential for definitive diagnosis of discogenic pain.

### Treatment of discogenic pain

Although there are several surgical options for discogenic pain, radical surgery consists mainly of interbody fixation.<sup>17,18)</sup> However, radical surgery damages the back muscles and decreases the mobility of the lumbar spine, so is unsuitable for athletes, in whom minimally invasive surgery is desired. Intradiscal electrothermal therapy is one of the minimally invasive techniques that can preserve mobility in patients with discogenic pain.<sup>19,20)</sup> The mechanism by which intradiscal electrothermal therapy works is thought to include degradation of the nerve, causing pain in the intervertebral disc by high circumference coagulation and stabilization of the intervertebral disc in response to contraction of the collagen fibers by application of heat to the disc.<sup>21)</sup> However, the effectiveness of this technique in patients who take part in sustained strenuous activity remains controversial.<sup>22,23)</sup> Total disc replacement is another motion-preserving surgery for

discogenic pain,<sup>18,24)</sup> but concerns remain about the future of the implant in view of the young age of the patients and the significantly increased loads associated with activities performed by athletes.<sup>25)</sup>

We have performed PED/TA in 12 professional athletes with discogenic low back pain and obtained satisfactory results. This procedure is a reliable minimally invasive procedure for patients with discogenic pain. Although various approaches can be used to perform PED, we prefer the transforaminal approach because it provides access to the intervertebral disc without damaging the back muscles, which are very important for elite athletes. Moreover, PED/TA has the advantage of allowing direct visualization of degenerative intervertebral discs and annular tears under endoscopy and can be performed safely and accurately.

### Conclusion

Percutaneous endoscopic discectomy/thermal annuloplasty is particularly useful in the elite athlete with discogenic low back pain because the degenerated intervertebral disc and painful annular tear can be cauterized with pinpoint accuracy and the back muscles can be preserved.

### Conflicts of Interest Disclosure

None declared.

### References

- Ong A, Anderson J, Roche J: A pilot study of the prevalence of lumbar disc degeneration in elite athletes with lower back pain at the Sydney 2000 Olympic Games. *Br J Sports Med* 37: 263–266, 2003
- Swärd L, Hellström M, Jacobsson B, Nyman R, Peterson L: Disc degeneration and associated abnormalities of the spine in elite gymnasts. A magnetic resonance imaging study. *Spine* 16: 437–443, 1991
- Schwarzer AC, Aprill CN, Derby R, Fortin J, Kine G, Bogduk N: The relative contributions of the disc and zygapophyseal joint in chronic low back pain. *Spine* 19: 801–806, 1994
- DePalma MJ, Ketchum JM, Saullo T: What is the source of chronic low back pain and does age play a role? *Pain Med* 12: 224–233, 2011
- Manchikanti L, Singh V, Pampati V, et al.: Evaluation of the relative contributions of various structures in chronic low back pain. *Pain Physician* 4: 308–316, 2001
- Yeung AT, Tsou PM: Posterolateral endoscopic excision for lumbar disc herniation: surgical technique, outcome, and complications in 307 consecutive cases. *Spine* 27: 722–731, 2002
- Choi KC, Lee JH, Kim JS, et al.: Unsuccessful percutaneous endoscopic lumbar discectomy: a single-center experience of 10,228 cases. *Neurosurgery* 76: 372–380; discussion 380–381; quiz 381, 2015
- Henmi T, Terai T, Hibino N, et al.: Percutaneous endoscopic lumbar discectomy utilizing ventral epiduroscopic observation technique and foraminoplasty for transligamentous extruded nucleus pulposus: technical note. *J Neurosurg Spine* 24: 275–280, 2016
- Tsou PM, Alan Yeung C, Yeung AT: Posterolateral transforaminal selective endoscopic discectomy and thermal annuloplasty for chronic lumbar discogenic pain: a minimal access visualized intradiscal surgical procedure. *Spine J* 4: 564–573, 2004
- Sairyō K, Kitagawa Y, Dezawa A: Percutaneous endoscopic discectomy and thermal annuloplasty for professional athletes. *Asian J Endosc Surg* 6: 292–297, 2013
- Crock HV: A reappraisal of intervertebral disc lesions. *Med J Aust* 1: 983–989, 1970
- García-Cosamalón J, del Valle ME, Calavia MG, et al.: Intervertebral disc, sensory nerves and neurotrophins: who is who in discogenic pain? *J Anat* 217: 1–15, 2010
- Sairyō K, Nagamachi A: State-of-the-art management of low back pain in athletes: Instructional lecture. *J Orthop Sci* 21: 263–272, 2016
- Aprill C, Bogduk N: High-intensity zone: a diagnostic sign of painful lumbar disc on magnetic resonance imaging. *Br J Radiol* 65: 361–369, 1992
- Lam KS, Carlin D, Mulholland RC: Lumbar disc high-intensity zone: the value and significance of provocative discography in the determination of the discogenic pain source. *Eur Spine J* 9: 36–41, 2000
- Weishaupt D, Zanetti M, Hodler J, Boos N: MR imaging of the lumbar spine: prevalence of intervertebral disk extrusion and sequestration, nerve root compression, end plate abnormalities, and osteoarthritis of the facet joints in asymptomatic volunteers. *Radiology* 209: 661–666, 1998
- O'Brien JP: The role of fusion for chronic low back pain. *Orthop Clin North Am* 14: 639–647, 1983
- Zigler JE, Burd TA, Vialle EN, Sachs BL, Rashbaum RF, Ohnmeiss DD: Lumbar spine arthroplasty: early results using the ProDisc II: a prospective randomized trial of arthroplasty versus fusion. *J Spinal Disord Tech* 16: 352–361, 2003
- Kloth DS, Fenton DS, Andersson GB, Block JE: Intradiscal electrothermal therapy (IDET) for the treatment of discogenic low back pain: patient selection and indications for use. *Pain Physician* 11: 659–668, 2008
- Maurer P, Block JE, Squillante D: Intradiscal electrothermal therapy (IDET) provides effective symptom relief in patients with discogenic low back pain. *J Spinal Disord Tech* 21: 55–62, 2008

- 21) Fukui S: Changes on MRI in lumbar disc protrusions in two patients after intradiscal electrothermal therapy. *J Anesth* 20: 132–134, 2006
- 22) Assietti R, Morosi M, Migliaccio G, Meani L, Block JE: Treatment of discogenic low back pain with intradiscal electrothermal therapy (IDET): 24 months follow-up in 50 consecutive patients. *Acta Neurochir Suppl* 108: 103–105, 2011
- 23) Freedman BA, Cohen SP, Kuklo TR, Lehman RA, Larkin P, Giuliani JR: Intradiscal electrothermal therapy (IDET) for chronic low back pain in active-duty soldiers: 2-year follow-up. *Spine J* 3: 502–509, 2003
- 24) Guyer RD, McAfee PC, Hochschuler SH, et al.: Prospective randomized study of the Charite artificial disc: data from two investigational centers. *Spine J* 4: 252S–259S, 2004
- 25) Siepe CJ, Wiechert K, Khattab MF, Korge A, Mayer HM: Total lumbar disc replacement in athletes: clinical results, return to sport and athletic performance. *Eur Spine J* 16: 1001–1013, 2007

---

*Address reprint requests to:* Hiroaki Manabe, MD, Department of Orthopedics, Institute of Biomedical Sciences, Tokushima University Graduate School, 3-18-15 Kuramoto-cho, Tokushima, Tokushima 770-8503, Japan.  
*e-mail:* s52726362@yahoo.co.jp