

# Frontal intradiploic meningioma with progressive intracranial invasion

## A rare case report

Sunfu Zhang, MD<sup>a,b</sup>, Jing Zhang, MD<sup>b</sup>, Junchen Chen, MM<sup>a</sup>, Xiaolin Ai, MD<sup>b</sup>, Xia He, BM<sup>a,\*</sup>

### Abstract

**Rationale:** Intradiploic meningiomas are a subset of extradural meningiomas that arise in the skull. They are mostly localized in the frontoparietal and orbital regions, and they are often mistaken for primary bone tumors.

**Patient concerns:** The patient was a 48-year-old man with headache and a 12-year history of frontal cranium occupation, which was first discovered in 2005 and enlarged in 2009. The patient had a history of fracture in his frontal cranium 12 years ago. The computed tomography and magnetic resonance imaging revealed an occupation and intracranial invasion in frontal cranium. And the angiography showed an occlusion at the anterior part of sagittal sinus.

**Interventions:** Bilateral frontal craniotomy, intracranial tumor resection, and cranioplasty were performed.

**Diagnosis:** Histologic examination confirmed an intradiploic ectopic meningioma (World Health Organization Grade I).

**Outcomes:** He was discharged with no neurological deficits 3 days after surgery. At the 6-month clinical follow-up, there was no tumor recurrence or other complaints.

**Lessons:** In this study, we present the case of a frontal intradiploic meningioma with progressive intracranial invasion and review the radiographic and clinical findings of patients with primary intraosseous meningioma.

**Abbreviations:** CT = computed tomography, MRI = magnetic resonance imaging, PET = positron emission tomography, PIM = primary intradural meningioma, WHO = World Health Organization.

**Keywords:** extradural, intradiploic meningioma, intraosseous, surgical resection

## 1. Introduction

A majority of meningiomas arising from meningotheial cells are considered as primary intradural meningiomas (PIMs) and are located in the subdural space. Whereas, meningiomas without any dural connections are called ectopic meningiomas, which arise from skin, nasopharynx, neck, and other places. Primary intradiploic meningiomas are a subset of extradural meningiomas, which covered approximately two-thirds of ectopic meningiomas. Intradiploic meningiomas are mostly localized in the frontoparietal and orbital regions, and they are often

mistaken for primary bone tumors and hyperostosis en plaque meningiomas.<sup>[1]</sup> Here, we report a case of frontal intradiploic meningioma with progressive intracranial invasion, and review the radiographic and clinical findings of patients with primary intraosseous meningioma.

## 2. Case report

Previous written and informed consent were obtained from the patient, and this study was approved by the ethics review board of West China Hospital of Sichuan University. A 48-year-old man was admitted to our hospital with headache and a 12-year history of frontal cranium occupation, which was first discovered in 2005 and enlarged in 2009 (Fig. 1A–D). He had a history of fracture in his frontal cranium 12 years ago. The patient's neurological examination findings were normal, and his physical examination showed a large mass on the forehead. The computed tomography (CT) revealed that the tumor in frontal bone further enlarged and had intracranial invasion, which occluded the anterior part of sagittal sinus (Fig. 1E–I). Enhanced magnetic resonance imaging (MRI) showed homogeneous enhancement of the intracranial lesion (G). Based on such clinical and radiological findings, bilateral frontal craniotomy, intracranial tumor resection and cranioplasty were performed. Postoperative CT showed complete tumor resection (Fig. 2J–L). Histologic examination confirmed an intraosseous ectopic meningioma (WHO Grade I). The patient was discharged with no neurological deficits on postoperative day 3. There was no tumor recurrence or other complaints at the 6-month clinical follow-up.

Editor: Bernhard Schaller.

SZ, JZ, JC, and XA contributed equally to this study.

The authors report no conflicts of interest.

<sup>a</sup>The First People's Hospital of Yibin, Sichuan 81 Rehabilitation Center/Sichuan provincial Rehabilitation Hospital, <sup>b</sup>West China School of Medicine, West China Hospital, Sichuan University, Sichuan, China.

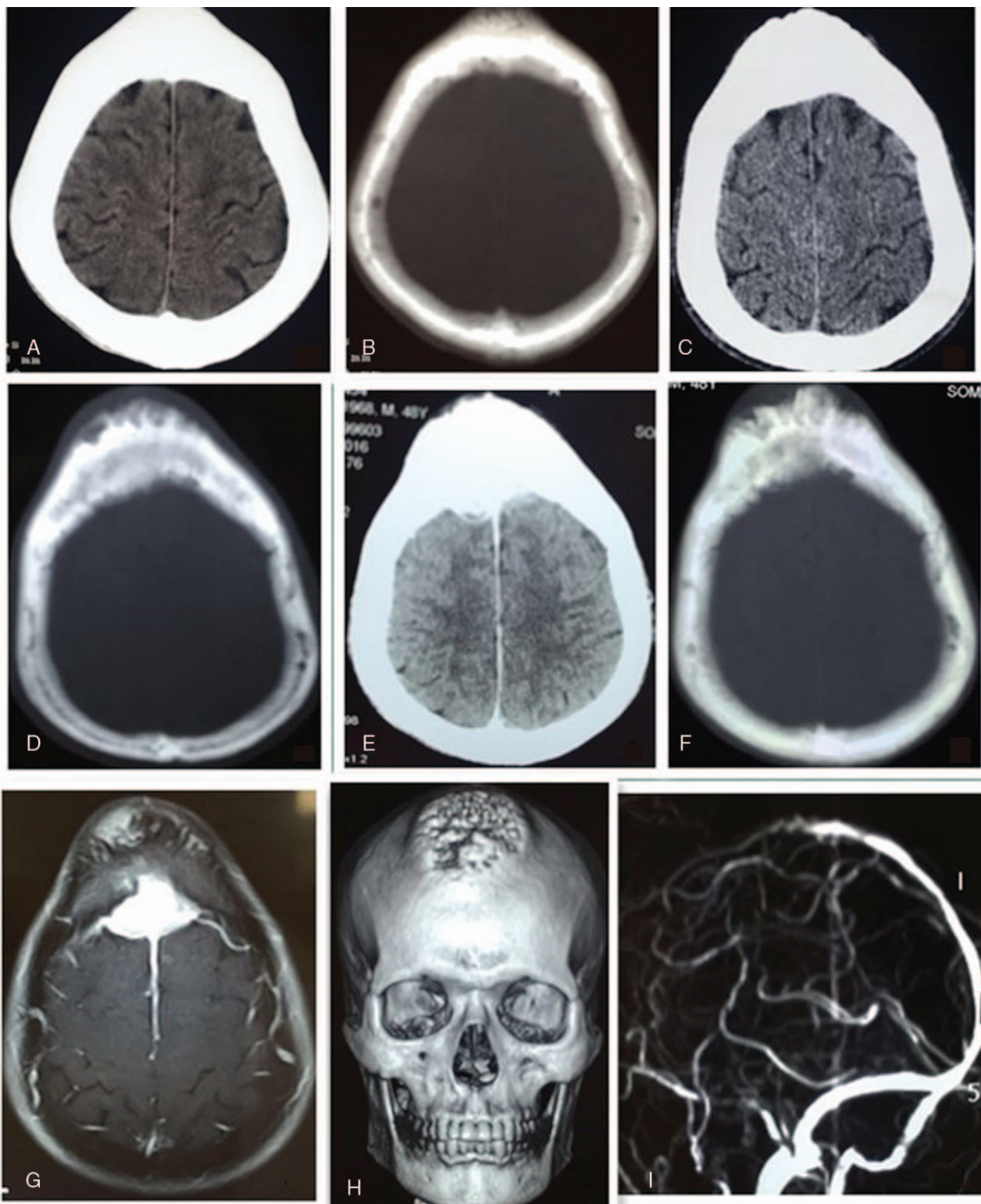
\* Correspondence: Xia He, 81 Bayi Road, Yongning Zhen, Chengdu 611135, Sichuan, China (e-mail: 307229719@qq.com).

Copyright © 2017 the Author(s). Published by Wolters Kluwer Health, Inc. This is an open access article distributed under the terms of the Creative Commons Attribution-Non Commercial-No Derivatives License 4.0 (CCBY-NC-ND), where it is permissible to download and share the work provided it is properly cited. The work cannot be changed in any way or used commercially without permission from the journal.

Medicine (2017) 96:34(e7903)

Received: 25 June 2017 / Received in final form: 19 July 2017 / Accepted: 20 July 2017

<http://dx.doi.org/10.1097/MD.0000000000007903>

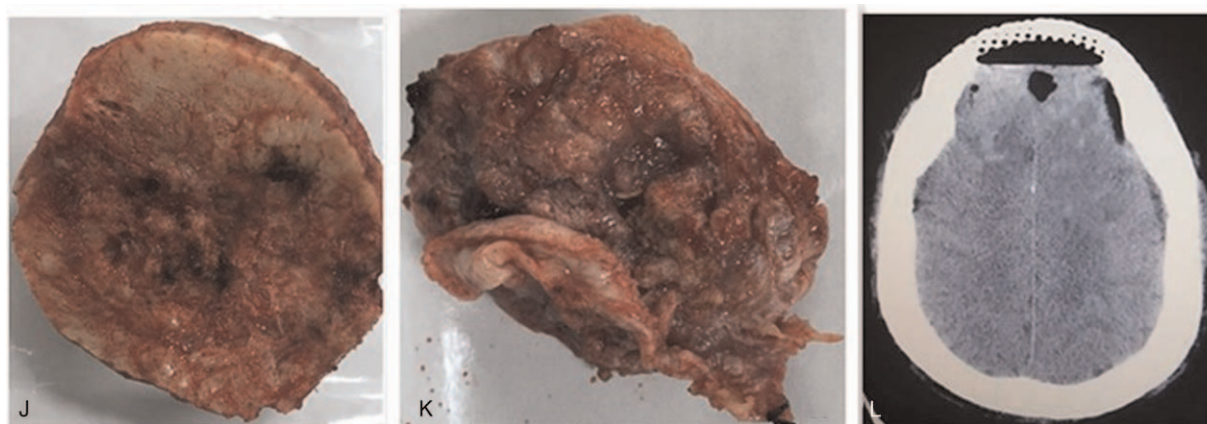


**Figure 1.** Preoperative images, computed tomography (CT) scan showed the tumor enlarged from 2005 (A, B) to 2009 (C, D), and had intracranial invasion on admission (E, F). Enhanced magnetic resonance imaging showed homogeneous enhancement of the intracranial lesion (G). 3-D CT scan showed the frontal cranium destruction (H). MRV showed the anterior part of sagittal sinus was occluded (I). MRV=magnetic resonance venography.

### 3. Discussion

Meningiomas are the most common primary brain tumors.<sup>[2]</sup> Although the majority of meningiomas arise from the dura, they can also develop in extracranial sites as primary extradural

meningiomas, which account for <2% of all meningiomas.<sup>[3]</sup> Primary intradiploic meningiomas are also called primary intraosseous meningioma, which are used to describe the subset of extradural meningiomas that arise in the skull. Most



**Figure 2.** Intraoperative findings and postoperative computed tomography (CT) scan. The resected cranium (J) and intracranial tumor (K). Postoperative CT scan (L).

intradiploic meningiomas tend to be located in frontoparietal and orbital regions,<sup>[4]</sup> and the incidence rates are similar in both sexes. People of all ages could have this disease, and the studies showed a peak incidence during the second decade.<sup>[5]</sup> Most patients usually present with a slow-growing bone mass without pain. Neurologic signs and symptoms are usually absent, unless intrasosseous meningiomas locate in skull base, which may lead to ophthalmoplegia or visual field defect.<sup>[6]</sup>

Most of intradiploic meningiomas are benign. However, they present malignant growth, which usually show both intraosseous and extraosseous extension. CT could reveal both hyperostosis and osteolysis, which account for 65% and 35%, respectively. In our case, we could see both hyperostosis and osteolysis in the CT bone window.<sup>[5]</sup> MRI is helpful to evaluate the soft tissue component and extraosseous extension. It is similar to the primary intradural meningiomas except for the dural tail sign, which could not be seen in intradiploic meningiomas. The meningioma in our case also led to occlusion at the anterior part of sagittal sinus, which could also be seen in PIMs. According to conventional imaging, the intradiploic meningiomas tend to be mistaken for primary or secondary osteosclerotic bone tumors,<sup>[7]</sup> for it could also exhibit hyperostosis and osteolysis of the skull bone. Apart from conventional imaging, molecular imaging by positron emission tomography (PET) is a promising approach in the management of brain tumors, including meningiomas.<sup>[8]</sup> PET could help for meningioma detection, grading, differential diagnosis, prognosis, and even novel therapy in the future.<sup>[8]</sup>

The hypotheses regarding the origin of intradiploic meningiomas remained controversial. Currently, there are 3 main points of view. First, the ectopic meningocyte or arachnoid cap cells are entrapped in cranial sutures during the development of the skull or during delivery.<sup>[3,9]</sup> Some studies found that intraosseous meningiomas tend to be located at suture lines, most commonly the coronal or pterion sutures, which may provide the basis for this view. Some reported cases had a history of trauma in the region of the tumor; however, only 8% to 14% of these patients suffered from trauma.<sup>[10]</sup> In our case, the patient had a history of fracture in his frontal cranium 12 years ago. It might be the reason that can explain his disease. Others thought that proliferation of undifferentiated pluripotent embryonic precursor cells in the bone might be another origin.<sup>[11]</sup> Lang et al<sup>[5]</sup> classified primary extradural meningiomas according to anatomic location of tumors. They divided the tumors into 3 types:

type I, a purely extracalvarial tumor; type 2, a purely calvarial tumor; type 3, a calvarial tumor with extracranial extension, and this classification method has been used so far.

Surgical treatment with wide incision of the lesion followed by cranial reconstruction is the primary therapy.<sup>[6,12]</sup> Although most intradiploic meningiomas are benign, they could present malignant growth, which might lead to erosion of the skull. Therefore, in most cases, complete resection of lesions seems to be impossible, and the residual tumor should be treated with adjuvant therapy,<sup>[7,13]</sup> such as radiation therapy and chemotherapy, especially for the patients who had malignant or atypical features histologically. Present chemotherapeutic agents mainly include cytotoxic chemotherapeutics (hydroxyurea, irinotecan, and temozolomide), hormonal inhibitors (targeting estrogen and progesterone), molecule-targeted drugs (imatinib, sunitinib, vatalanib), and other drugs.<sup>[14]</sup> In addition, postoperative imaging is vital for monitoring tumor recurrence or progress. Therefore, prolonged follow-up of patients is necessary.

Although successful surgery was achieved in this progressive invasive tumor, there is still room for improvement. The lesion was found 12 years ago, and found enlarged 8 years ago. On admission, the tumor had intracranial invasion. If the surgery had been performed earlier, there would be less risk of invasion. Thus, we suggest intradiploic meningiomas should be closely monitored, and surgery should be considered timely.

#### 4. Conclusion

In this study, we presented a case of frontal intradiploic meningioma with progressive intracranial invasion, and reviewed the radiographic and clinical findings of patients with primary intradiploic meningioma. Primary intradiploic meningiomas are rare tumors, which are used to describe the subset of extradural meningiomas that arise in the skull. Most of intradiploic meningiomas are benign. However, they could present malignant growth. CT could reveal both hyperostosis and osteolysis. Regular monitoring is essential in the management of intradiploic meningioma. Surgical treatment with wide incision of the lesion is the primary therapy. Postoperative adjuvant therapy was important for the patients who had residual tumor or malignant/atypical features histologically. More studies are needed to further address the mechanism of intradiploic meningiomas development.



## Acknowledgements

The authors thank the reviewers for their constructive comments.

## References

- [1] Verma SK, Satyarthee G, Borkar SA, et al. Orbital roof intradiploic meningioma in a 16-year-old girl. *J Pediatr Neurosci* 2015;10:51–4.
- [2] Rogers L, Barani I, Chamberlain M, et al. Meningiomas: knowledge base, treatment outcomes, and uncertainties. A RANO Review. *J Neurosurg* 2015;122:4–23.
- [3] Elder JB, Atkinson R, Zee CS, et al. Primary intraosseous meningioma. *Neurosurg Focus* 2007;23:E13.
- [4] Ilica AT, Mossa-Basha M, Zan E, et al. Cranial intraosseous meningioma: spectrum of neuroimaging findings with respect to histopathological grades in 65 patients. *Clin Imag* 2014;38:599–604.
- [5] Lang FF, Macdonald OK, Fuller GN, et al. Primary extradural meningiomas: a report on nine cases and review of the literature from the era of computerized tomography scanning. *J Neurosurg* 2000;93:940–50.
- [6] Inagaki K, Otsuka F, Matsui T, et al. Effect of etidronate on intraosseous meningioma. *Endocrine J* 2004;51:389–90.
- [7] Crawford TS, Kleinschmidt-DeMasters BK, Lillehei KO. Primary intraosseous meningioma. Case report. *J Neurosurg* 1995;83:912–5.
- [8] Schaller BJ, Cornelius JF, Sandu N, et al. Molecular imaging of brain tumors personal experience and review of the literature. *Curr Mol Med* 2008;8:711–26.
- [9] Changhong L, Naiyin C, Yuehuan G, et al. Primary intraosseous meningiomas of the skull. *Clin Radiol* 1997;52:546–9.
- [10] Lopez DA, Silvers DN, Helwig EB. Cutaneous meningiomas: a clinicopathologic study. *Cancer* 1974;34:728–44.
- [11] Yun JH, Lee SK. Primary osteolytic intraosseous atypical meningioma with soft tissue and dural invasion: report of a case and review of literatures. *J Korean Neurosurg Soc* 2014;56:509–12.
- [12] Chen TC. Primary intraosseous meningioma. *Neurosurg Clin North Am* 2016;27:189–93.
- [13] Eras MA, Tari R, Ozturk G, et al. Intraosseous meningioma mimicking osteosarcoma in an adolescent: a case report. *Turkish Neurosurg* 2011;21:663–5.
- [14] Mattox A, Hughes B, Oleson J, et al. Treatment recommendations for primary extradural meningiomas. *Cancer* 2011;117:24–38.