

Tumoral Calcinosis: An Uncommon Cause for a Mass in a Reconstructed Breast

Eugene Koh, MBBS, MSc*
 Nicola R. Dean, MBChB,
 PhD, FRACS(Plas)*
 David I. Watson, MD, FRACS†
 Christopher D. Carter, MBBS,
 FRCPA‡§

Summary: Tumoral calcinosis is a rare clinical and histopathological syndrome whose exact etiology is unknown. We present a case of a 57-year-old woman who presents with a painful lump in her right chest after bilateral breast reconstructions for bilateral asynchronous breast cancers. It is important to be aware of all possible differential diagnoses in a patient presenting with a chest mass after mastectomy and reconstruction for breast cancer as not all lesions of this type represent recurrent cancer. (*Plast Reconstr Surg Glob Open* 2016;4:e700; doi: 10.1097/GOX.0000000000000687; Published online 5 May 2016.)

The appearance of a mass in a reconstructed breast is always of concern for local recurrence of breast cancer and can cause worry and anxiety in a patient. We present an uncommon cause for a mass in a reconstructed breast.

CASE REPORT

A 57-year-old woman presented with a 6-week history of a painful lump in her right chest wall after bilateral mastectomy and reconstruction. In 1991, she had undergone a right partial mastectomy with axillary clearance for a 13-mm grade III invasive cancer. There was no nodal involvement, and she received iridium implant brachytherapy and adjuvant external beam radiotherapy.

Subsequent mammography in 2007 showed some suspicious microcalcifications in the contralateral

(left) breast. An excision biopsy showed the presence of an intermediate-grade ductal carcinoma in situ.

To achieve clearance of the ductal carcinoma in situ, she underwent complete left mastectomy and, at the same time, had a prophylactic right mastectomy and bilateral 2-stage reconstruction with tissue expander and implant. The procedure was complicated by a right-sided periprosthetic infection, which required removal of the implant on that side. She then underwent a free transverse rectus abdominis musculocutaneous (TRAM) flap to reconstruct the right breast in November 2007, and this was complicated by partial flap necrosis a month later, requiring debridement and split skin graft.

In February 2009, the patient presented with discomfort in the reconstructed left breast secondary to mild capsular contracture with thin overlying tissues. To treat this, the patient opted to undergo further surgery to remove the implant and have a latissimus dorsi reconstruction augmented by a smaller implant. For 5 years, she remained symptom-free and happy with her reconstructed breasts, despite an objectively poor aesthetic result (Fig. 1). She then presented with pain in her right chest wall in 2014, 7 years after the TRAM flap breast reconstruction.

Physical examination of the right chest wall revealed a hard mass, deep to the upper scar of the right breast reconstruction (Fig. 1). Serum bio-

From the *Department of Plastic and Reconstructive Surgery, Flinders Medical Centre, Bedford Park, South Australia, Australia; †Department of Surgery, ‡Department of Anatomical Pathology, SA Pathology, and §Department of Pathology, Flinders University, Bedford Park, South Australia, Australia.

Received for publication January 28, 2016; accepted March 1, 2016.

Copyright © 2016 The Authors. Published by Wolters Kluwer Health, Inc. on behalf of The American Society of Plastic Surgeons. All rights reserved. This is an open-access article distributed under the terms of the Creative Commons Attribution-Non Commercial-No Derivatives License 4.0 (CCBY-NC-ND), where it is permissible to download and share the work provided it is properly cited. The work cannot be changed in any way or used commercially.

DOI: 10.1097/GOX.0000000000000687

Disclosure: The authors have no financial interest to declare in relation to the content of this article. The Article Processing Charge was paid for by the Department of Plastic and Reconstructive Surgery, Flinders University, South Australia.

chemistry did not reveal any metabolic or electrolyte abnormalities; calcium and phosphate values were in the normal range. Computed tomography of the chest demonstrated a bone-forming lesion at the anterior end of the right third rib, measuring $2.1 \times 2 \times 2.8$ cm, with little soft tissue component (Fig. 2). Positron emission tomography did not demonstrate a fluorodeoxyglucose-avid malignancy. Recurrent breast cancer was considered unlikely based on this imaging, with sarcoma considered more likely. She was then referred to a regional sarcoma service.

The patient underwent resection of the affected segment of her right third rib at the regional sarcoma center. Macroscopically, extensive changes of radiotherapy and fibrosis were found. There was necrotic, caseating material within the bone, which was excised with the pleura intact. The patient then made an unremarkable recovery and remained symptom-free 12 months after the resection.

RESULTS

The removed mass measured $38 \times 14 \times 14$ mm. Microscopically, the lesion represented a well-circumscribed, lobulated deposit of calcific debris with a granular consistency consistent with hydroxyapatite (Fig. 3). There was no evidence of gout, pseudogout, or amyloid deposits. The lesion was centered in the soft tissue plane and involved skeletal muscle and nonspecialized fibrous connective tissue, including the periosteum and appeared to extend into the underlying rib by an erosive process rather than being osteocentric (Fig. 4).

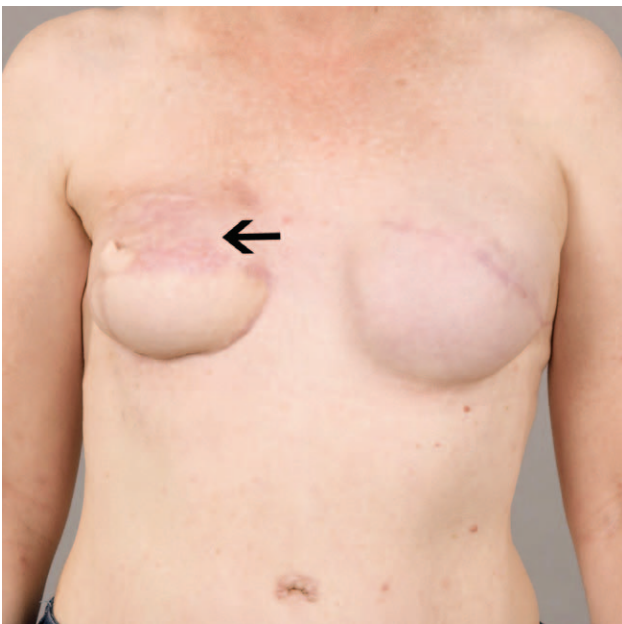

Fig. 1. The patient at a routine follow-up; the arrow marks the location of the right chest wall mass.

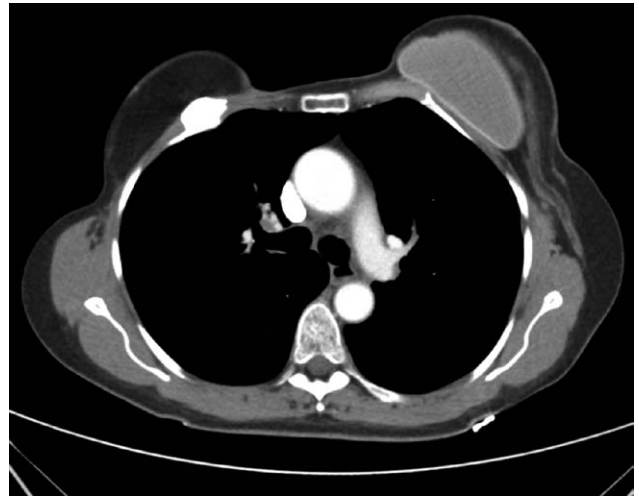

Fig. 2. Computed tomography demonstrating a bone-forming lesion at the anterior end of the third rib.

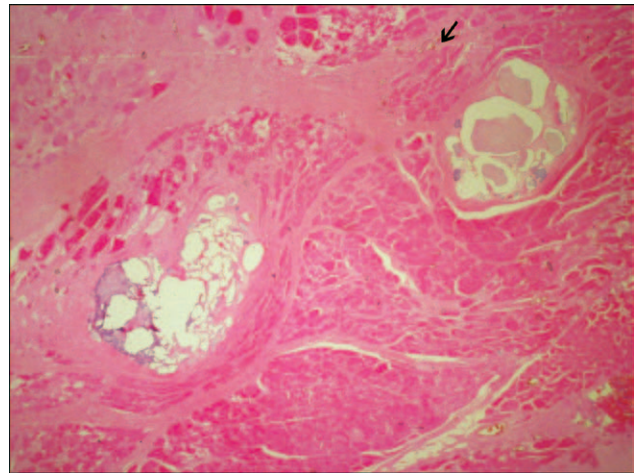


Fig. 3. Well-circumscribed, lobulated deposit of calcific debris with a granular consistency consistent with hydroxyapatite within skeletal muscle.

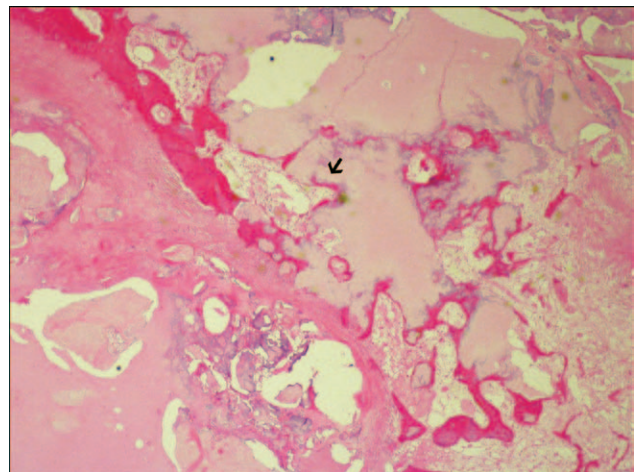


Fig. 4. Deposit of calcific debris with granular consistency consistent with hydroxyapatite within soft tissue and periosteum and eroding the rib.

The calcific material was surrounded by dense hyalinized fibrous tissue, and there was a sparse histiocytic inflammatory reaction at the interface with the calcific deposit. Features of traumatic fat necrosis were not evident. There was no evidence of neoplasia. The affected rib showed nonspecific reactive changes and preserved hematopoietic activity. Although bony involvement was an unusual finding, the appearances were nevertheless interpreted as most in keeping with tumoral calcinosis.

DISCUSSION

Masses can sometimes develop in reconstructed breasts and must be evaluated to determine their nature. In one series, breast masses occurred in 18.1% of reconstructed breasts.¹ Fat necrosis is the most common cause of breast masses after autologous breast reconstruction, followed by recurrent carcinoma. Risk factors in the development of fat necrosis include perforator number and selection, smoking, postreconstruction radiotherapy, obesity, volume of transferred tissue, and hypertension.¹ The incidence of fat necrosis has also been found to be higher in patients receiving brachytherapy when compared with patients receiving whole-breast irradiation.²

There is currently no evidence that immediate reconstruction impairs the detection of local recurrence in patients with early-stage breast cancer; however, the presence of autologous tissue can make it difficult to differentiate between a benign and a malignant lesion on clinical examination.¹ Reddy et al³ found a similar incidence of locoregional recurrence in a series of 921 patients; 3.0% for all patients and 2.2% after reconstruction. Similarly, the time to detect recurrent disease was not significantly affected by breast reconstruction.

Tumoral calcinosis is a rare clinical and histopathological syndrome characterized by calcium salt deposition in different periarticular soft tissue regions, its exact etiology is unknown, but treatment is by complete surgical excision.⁴⁻⁷ Regions most commonly affected by tumoral calcinosis are soft tissues of periarticular upper limb (shoulder and elbow) and hip regions.⁵ Slavin et al⁸ theorized that the lesion of tumoral calcinosis is created by the concurrence of 2 events: first, trauma that initiates a multistep reaction to injury in juxta-articular soft tissues and skin, and second, a multifactorial eleva-

tion of the serum calcium-phosphate product principally caused by hyperphosphatemia.

There are no reported cases of tumoral calcinosis of the rib after breast reconstruction in the literature nor were there reported cases of tumoral calcinosis associated with external beam radiotherapy or brachytherapy. It has also been theorized that the process of tumoral calcinosis may begin with spontaneous necrosis of fat, followed by granuloma formation and calcification, which may be relevant in this setting of autologous flap breast reconstruction complicated by partial flap necrosis.⁷

CONCLUSIONS

We have presented a case of a rare cause for a mass in a reconstructed breast after mastectomy. Awareness of all possible differential diagnoses is important as not all lesions of this type represent recurrent cancer.

Eugene Koh, MBBS, MSSc
Flinders Medical Centre
Flinders Drive
Bedford Park, SA 5042
Australia

E-mail: Eugene.Koh@sa.gov.au

REFERENCES

1. Casey WJ III, Rebecca AM, Silverman A, et al. Etiology of breast masses after autologous breast reconstruction. *Ann Surg Oncol.* 2013;20:607–614.
2. Ajkay N, Collett AE, Bloomquist EV, et al. A comparison of complication rates in early-stage breast cancer patients treated with brachytherapy versus whole-breast irradiation. *Ann Surg Oncol.* 2015;22:1140–1145.
3. Reddy S, Colakoglu S, Curtis MS, et al. Breast cancer recurrence following postmastectomy reconstruction compared to mastectomy with no reconstruction. *Ann Plast Surg.* 2011;66:466–471.
4. Lafferty FW, Reynolds ES, Pearson OH. Tumoral calcinosis: a metabolic disease of obscure etiology. *Am J Med.* 1965;38:105–118.
5. Fathi I, Sakr M. Review of tumoral calcinosis: a rare clinicopathological entity. *World J Clin Cases.* 2014;2:409–414.
6. Xu C, Potter JA, Carter CD, et al. Idiopathic tumoral calcinosis in hand: a case report. *Eplasty* 2014;14:e28.
7. Smit GG, Schmaman A. Tumoral calcinosis. *J Bone Joint Surg Br.* 1967;49:698–703.
8. Slavin RE, Wen J, Barmada A. Tumoral calcinosis—a pathogenetic overview: a histological and ultrastructural study with a report of two new cases, one in infancy. *Int J Surg Pathol.* 2012;20:462–473.