



# Severe visceral pentastomiasis in an oriental small-clawed otter with functional thyroid carcinoma

Chia-Da HSU<sup>1)\*</sup> and Yaoprpa MATHURA<sup>1)</sup><sup>1)</sup>Department of Veterinary Services, Wildlife Reserves Singapore, 80 Mandai Lake Road Singapore 729826, Singapore*J. Vet. Med. Sci.*

80(2): 320–322, 2018

doi: 10.1292/jvms.17-0383

Received: 12 July 2017

Accepted: 18 December 2017

Published online in J-STAGE:

1 January 2018

**ABSTRACT.** In January 2016, a 20-year-old female oriental small-clawed otter (*Aonyx cinereus*) from Night Safari in Singapore was euthanized and diagnosed with a thyroid gland carcinoma. Postmortem examination and histology also revealed metastasis to the regional lymph nodes and severe visceral pentastomiasis. Grossly, the lymph nodes were infested, and encapsulation was observed on the visceral serosal surface. Histopathologically, the lymph nodes were encysted by a thick fibrous connective capsule with minimal inflammatory response. Pentastomiasis has been previously reported in the smooth-coated otter (*Lutrogale perspicillata*) in Malaysia. This report is the first case of severe visceral pentastomiasis in an oriental small-clawed otter with functional thyroid carcinoma.

**KEY WORDS:** otter, pentastomiasis, thyroid carcinoma, tongue worm

Pentastomes (tongue worms) are internal parasitic crustaceans with wormlike features. They were first reported in the nasal cavities of dogs and horses in 1787 [4]. This parasitic disease is zoonotic. Humans and otters are known as its end hosts [5]. In Malaysia, two genera, *Raillietiella* and *Armillifer*, were found in several different animal hosts [7]. The adult worms mainly infest the upper respiratory tract of vertebrates, especially snakes [9]. Several intermediate hosts, such as cockroaches and rodents, can ingest and carry the infectious larvae [1, 8]. The larvae then migrate from the intestinal tract to the lungs of definite hosts or the visceral surface of end hosts after they ingest the larvae or eggs [9].

In their definite hosts, the first-stage larvae migrate from the gut to the lung by penetrating the intestinal wall to enter the coelomic cavity [9]. Vascular and lymphatic invasion of the first-stage larvae has also been found in a study [3]. When they reach the lung, the fertilized females usually need approximately four to eight months to shed embryonated eggs. The eggs are expelled out of the trachea by the respiratory secretions and then may be discharged or ingested. In end hosts, the nymphs will not be able to complete the full life cycle; hence, they die on the site encysted by the host's immune system. Infection in end hosts is usually asymptomatic; however, clinical features, such as fever, abdominal pain, vomiting, diarrhea, jaundice, and abdominal tenderness, can be present [2]. Only calcified cysts can be seen with radiograph examination, which makes non-invasive antemortem diagnosis extremely difficult. The encysted nymphs are usually C-shaped, about 0.7 to 1.3 cm in length, and found on the surface of the liver, kidney, spleen, intestine, omentum, and mesentery [9].

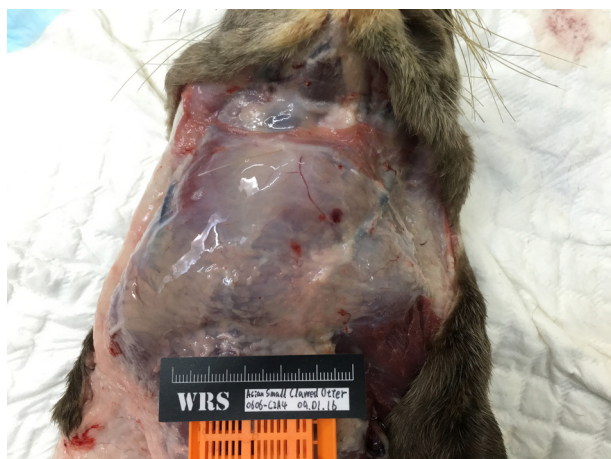A 20-year-old female oriental small-clawed otter (*Aonyx cinereus*) from Night Safari at the Singapore Zoological Gardens was sent to the hospital for a health check after the keeper observed her losing condition despite a normal appetite. She also had difficulty moving her hind legs and swelling of the neck region. Physical examination revealed multiple movable, soft fluid-filled cysts in the right side of her neck near the right thyroid gland. Similar smaller cysts were also palpable on the left side. The otter also had muscle atrophy and poor body condition. Radiographically, the tumors were radiolucent. Radiographs also revealed osteoarthritis on the left hind stifle joint. Blood chemistry exhibited a blood thyroxine (T4) value of 63 nmol/l, and due to a lack of reference data, a comparison was made with other healthy otters in the collection. The average in-house T4 level from other otters was  $\leq 45$  nmol/l. The blood T4 value was three times higher than that of other otters from the same group. A hyperfunctioning thyroid gland carcinoma was suspected. Euthanasia was performed due to her compromised welfare.

On postmortem examination, the neck region was severely swollen, and the subcutaneous region showed moderate edema (Fig. 1). The main cyst in the right thyroid gland was about  $3.5 \times 3.5 \times 3$  cm. The cyst was multilocular and contained light yellowish clear fluid. Severe edema was found in the adjacent tissues. The left thyroid gland was rounded, with a dark red appearance. Multiple small cysts were found posterior to the left thyroid gland, and they were arranged in a linear pattern along

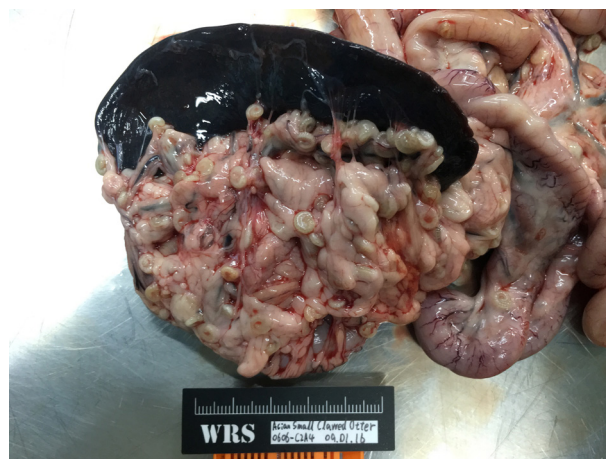\*Correspondence to: Hsu, C.-D.: chiada.hsu@wrs.com.sg

©2018 The Japanese Society of Veterinary Science

This is an open-access article distributed under the terms of the Creative Commons Attribution Non-Commercial No Derivatives (by-nc-nd) License. (CC-BY-NC-ND 4.0: <https://creativecommons.org/licenses/by-nc-nd/4.0/>)



**Fig. 1.** Gross findings of the neck mass. The neck was significantly swollen, and the subcutaneous region showed moderate edematous change.



**Fig. 2.** Gross findings of the visceral pentastomiasis. Abundant C-shaped parasites were found on the omentum and gastrosplenic ligament.



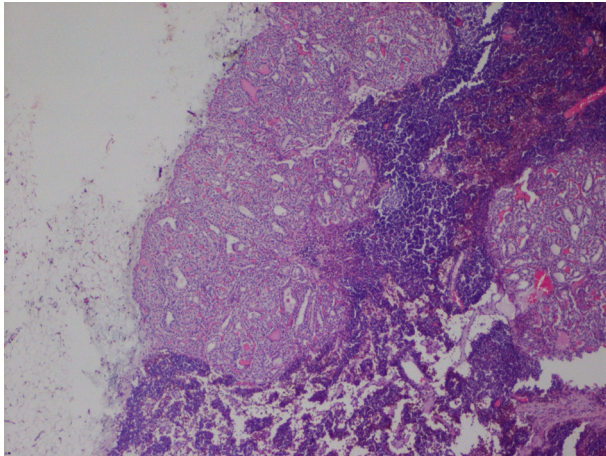
**Fig. 3.** Gross findings of the visceral pentastomiasis. The parasites were scattered across the liver's surface.

the lymphatic duct. A  $0.5 \times 0.5 \times 0.5$  cm cyst was found in a superior deep cervical lymph node. Besides the tumor, seven spiral-shaped parasites were found on the lung surface, and some others were noted embedded in the adipose tissue at the hila. The same parasites were also noted spread haphazardly on the surface of visceral organs in the abdomen and on the mesentery and omentum (Fig. 2). There was a large number of these parasites. A small number of them had migrated into the liver, lungs, and pancreas parenchyma (Fig. 3); these parasites had hard chitinized cuticles. There were also abundant uroliths in both kidneys.

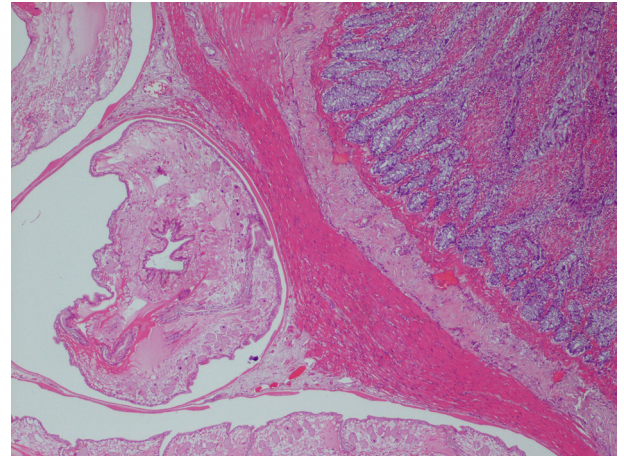
Histopathologically, the tumor in the thyroid presented a large colloid-filling cyst. The wall of the cyst was composed of a mixture of papillary, solid, and cribriform structures. The cribriform structure consisted of a monolayer of cuboidal neoplastic cells, and some of these microcysts contained colloid in the lumen. Metastatic lesions were found in the interior deep cervical and paratracheal lymph nodes (Fig. 4). The parasites were found embedded in the parenchyma. They had invaded the lung, smooth muscle layer of the intestine, liver, pancreas, capsule of the spleen, and adipose tissue on the mesentery. The larvae presented in the spiral shape and were encysted by the thin layer of fibrous connective tissue. There was no significant inflammatory response observed (Fig. 5). These nymphs had thin chitinous cuticles, and oral hooks were noted at their anterior portions. Acidophilic glands were found surrounding the intestine.

Massive pentastomiasis in otters is rarely reported by zoological institutes. Sporadic infections have been found in wild oriental small-clawed otters (*Aonyx cinereus*), smooth-coated otters (*Lutrogale perspicillata*), and giant river otters (*Pteronura brasiliensis*) [4]. In this region, *Armillatus moniliformis* has been reported infesting smooth-coated otters and oriental small-clawed otters. The infestations in humans have usually been asymptomatic, but in some cases, infested persons may show signs of hyperthermia, abdominal pain, vomiting, diarrhea, and jaundice [7]. The clinical manifestations in end hosts depend on the location to which the larvae migrate. In this case, the otter showed no significant clinical signs of pentastomiasis. One publication that studied the





**Fig. 4.** Histopathological findings of the thyroid carcinoma. The tumor cells were arranged in microcysts, which vary in size, and there was a metastatic lesion in the lymph node.



**Fig. 5.** Histopathological findings of visceral pentastomiasis. The nymphs were encapsulated in thin fibrous connective tissue, and there was minimal inflammation in the surrounding tissue.

possible transmission routes of pentastomes in Malaysia suggested that several animals other than snakes can carry the eggs of pentastomes or larvae, which are then transmitted to end hosts by predation or fecal-oral route [7]. These animals include cockroaches, geckoes, rats, toads, and lizards [6]. This may be the possible infestation route in the present case. Besides this otter in this collection, only a group of otters from this particular exhibit has been affected by pentastomiasis in varying severities, and there have been no reports of pentastomes among the otters from other groups. Interestingly, other oriental small-clawed otters in other exhibits didn't show any pentastomiasis during postmortem examination. Thus far, no field research has been conducted to determine the epidemiology and prevalence of pentastomiasis in wild reptiles in Singapore. In neighboring Malaysia, a field study found about a 1.8% infection rate of pentastomiasis in 5,209 wild animals. However, a 20.7% infection rate was found in wild carnivores [6]. Currently, most of the reported cases have been found incidentally during postmortem examination. Hence, there may be many cases that are underdiagnosed. Histopathologically, the oral hooks and chitinous cuticle are the typical criteria for the diagnosis of pentastomes. The major concern with this disease is that it is a zoonotic parasitic disease, and in heavy infestations, death may occur due to secondary septicemia. The only available non-invasive diagnosis is by radiology. However, the X-ray can only pick up calcified nymphs. Ultrasound, CT, or MRI scans may be helpful, depending on the severity of the lesions [11]. Therefore, invasive diagnosis, such as exploratory laparotomy and endoscopy, may be needed, plus biopsy can help with definitive diagnosis of visceral pentastomiasis [10].

Pentastomiasis in mammals hasn't been reported in any other zoo. In nature, pentastomes infect reptiles and cause respiratory disease. In Singapore, pentastomes have been seen in wild pythons. Eradication of the disease from the collection is next to impossible due to the open exhibit design and the connection between the zoo and the adjacent forest. Based on the finding of visceral pentastomiasis in the otter collection, human health is the first concern in the zoo. Regular monitoring of the keepers' health is recommended. Biosecurity education has also been conducted.

## REFERENCES

- Anuar, A. K. and Paran, T. P. 1976. *Periplaneta americana* (L.) as intermediate host of *Moniliformis moniliformis* (Bremser) in Penang, Malaysia. *Southeast Asian J. Trop. Med. Public Health* **7**: 415–416. [Medline]
- Chen, S. H., Liu, Q., Zhang, Y. N., Chen, J. X., Li, H., Chen, Y., Steinmann, P. and Zhou, X. N. 2010. Multi-host model-based identification of *Armillifer agkistrodantis* (Pentastomida), a new zoonotic parasite from China. *PLoS Negl. Trop. Dis.* **4**: e647. [Medline] [CrossRef]
- Chitwood, M. and Lichtenfels, J. R. 1972. Identification of parasitic metazoa in tissue sections. *Exp. Parasitol.* **32**: 407–519. [Medline] [CrossRef]
- Christoffersen, M. J. and De Assis, J. E. 2013. A systematic monograph of the recent Pentastomida, with a compilation of their hosts. *Zool. Meded.* **87**: 1–206.
- Drabick, J. J. 1987. Pentastomiasis. *Rev. Infect. Dis.* **9**: 1087–1094. [Medline] [CrossRef]
- Krishnasamy, M., Singh, I., Jeffery, J., Ambu, S., Ali, J. H. and Baker, E. D. 1985. Some pentastomes from Malaysia, with special emphasis on those from Peninsular Malaysia. *J. Malaysian Soc. Health*: 49–56.
- Latif, B. M. A., Muslim, A. and Chin, H. C. 2016. Human and Animal Pentastomiasis in Malaysia Review. *J. Trop. Life Sci.* **6**: 131–135. [CrossRef]
- Lim Boo, Liat and Krishnansamy, M. 1973. A heavy infection of *Porocephalus armillatus* in *Rattus bowersi*. *Southeast Asian J. Trop. Med. Public Health* **4**: 282–284. [Medline]
- Meyers, W. M., Firpo, A. and Wear, D. J. 2011. Pentastomiasis. In: *Topics on the Pathology of Protozoan and Invasive Arthropod Diseases* (Meyers, W. M. and Neafie, R. C. eds.), Armed Forces Institute of Pathology, Washington, D.C.
- Tappe, D. and Büttner, D. W. 2009. Diagnosis of human visceral pentastomiasis. *PLoS Negl. Trop. Dis.* **3**: e320. [Medline] [CrossRef]
- Wang, H. Y., Zhu, G. H., Luo, S. S. and Jiang, K. W. 2013. Childhood pentastomiasis: a report of three cases with the following-up data. *Parasitol. Int.* **62**: 289–292. [Medline] [CrossRef]