

Vanishing White Matter Disease Presenting as Dementia and Infertility

A Case Report

Jasmine Parihar, DM, Neurology, Deepti Vibha, DM, Neurology, Roopa Rajan, DM, Neurology, Awadh Kishor Pandit, DM, Neurology, Achal Kumar Srivastava, DM, Neurology, and Kameshwar Prasad, DM, Neurology

Correspondence

Dr. Prasad
drkameshwarprasad@gmail.com

Neurol Genet 2022;8:e643. doi:10.1212/NXG.0000000000000643

Abstract

Objectives

Vanishing white matter (VWM), an inherited leukoencephalopathy affecting the brain and the spinal cord, is most often a childhood-onset progressive disorder, generally presenting with ataxia. The adult-onset VWM is relatively rare with slowly progressive cognitive dysfunction dominating the clinical presentation. We report a case of adult-onset VWM from the Indian subcontinent.

Methods

Exome sequencing.

Results

A 58-year-old woman with young-onset diabetes and hypertension presented with gradually progressive cognitive decline beginning at age 40 years. She had early and predominant executive dysfunction and emotional lability and late involvement of memory and navigation. In addition to cognitive dysfunction, the patient experienced bladder and bowel incontinence along with a spastic gait. She also had primary infertility and menopause at age 40 years. Two of the patient's sisters had primary infertility; one of them had urine and stool incontinence along with gait disturbance. An MRI examination of the brain showed diffuse, symmetrical T2/fluid-attenuated inversion recovery white matter hyperintensities. On genetic testing, the patient was found to be homozygous for c.687T>G variation in the *EIF2B3* gene.

Discussion

Adult-onset VWM is rare. Infertility in an adult patient with progressive cognitive decline should raise a suspicion of VWM.

From the Department of Neurology (J.P., D.V., R.R., A.K.P., A.K.S.), All India Institute of Medical Sciences, New Delhi; and Rajendra Institute of Medical Sciences (K.P.), Ranchi, Jharkhand, India.

Go to [Neurology.org/NG](https://www.neurology.org/NG) for full disclosures. Funding information is provided at the end of the article.

The Article Processing Charge was funded by Rajendra Institute of Medical Sciences, Ranchi.

This is an open access article distributed under the terms of the Creative Commons Attribution-NonCommercial-NoDerivatives License 4.0 (CC BY-NC-ND), which permits downloading and sharing the work provided it is properly cited. The work cannot be changed in any way or used commercially without permission from the journal.

Vanishing white matter (VWM) is an autosomal recessive leukoencephalopathy affecting the brain and spinal cord, typically presenting with childhood ataxia. The adult-onset VWM is relatively rare with slowly progressive cognitive dysfunction dominating the clinical presentation. We report a case of a woman with VWM presenting as dementia and infertility from the Indian subcontinent.

Case

A 58-year-old woman, a product of fourth-degree consanguineous marriage, presented with a progressive cognitive decline beginning at 40 years. At the onset, she experienced executive dysfunction in the form of difficulty in planning and performing official work. After 6–8 years, she developed difficulty in managing finance, visuospatial disorientation, and emotional lability. Later, she developed gradual recent memory loss, followed by long-term memory loss. For the past 10 years, she experienced progressive spastic gait and episodic bladder and bowel incontinence; however, she was ambulatory and able to feed herself. The patient had primary infertility and menometrorrhagia with menopause at 40 years. Two of the patient's sisters had primary infertility, and one of them experienced a history of urine and stool incontinence with gait disturbance. On examination, patient had an MMSE score of 13/30 with predominant frontal and parietal dysfunction on detailed assessment. She had upper motor neuron signs in all the limbs. Routine investigations including thyroid profile and vitamin B₁₂ level were normal. Ultrasound pelvis showed small ovaries and uterus with thin endometrial lining. The patient having presented at age 58 years, the hormonal assay was not conducted because it was less likely contributory. An MRI examination of the brain (Figure) showed diffuse, symmetrical leukoencephalopathy involving the cerebral hemispheres. Genetic testing for the *5 EIF2B* genes was performed, and the patient was found to be homozygous for the c687T>G in the *EIF2B3* gene.

Discussion

The age at onset and clinical presentation of VWM is variable severe encephalopathy in infancy, spasticity and

cerebellar ataxia in childhood, and cognitive decline and spastic paraparesis in adulthood.^{1–4} The adult-onset cases are being increasingly reported in the past 2 decades.⁴ The oldest reported age of presentation is 66 years⁵

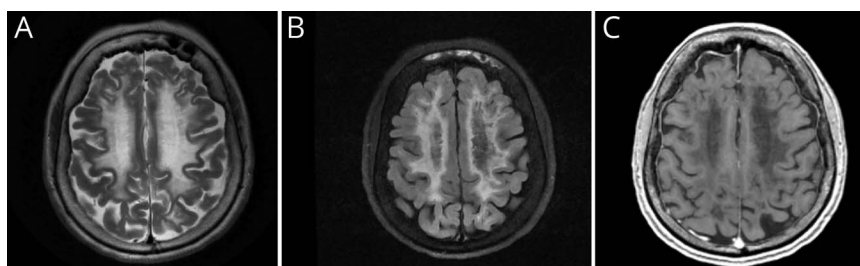
In adults, the disease generally has a chronic progressive course with cognitive decline, psychiatric symptoms, and motor signs, more frequent than cerebellar ataxia. Seizures have been commonly reported in adult patients.^{2,3} Although it is less common in late-onset cases, rapid neurologic deterioration can occur with minor head trauma, febrile infections, or delivery.^{1,2} In an adult series of 16 cases of VWM, symptom onset with the precipitating factor occurred in 2 and clinical worsening in 6, and death after stress-induced deterioration occurred in 2 cases.²

Adult-onset VWM is more frequent in female than male patients.² Wei et al. reviewed 33 female patients, older than 16 years and with genetically confirmed VWM. The mean age at onset in these patients was 36.8 years (range: 16–66 years), which is similar to the age of presentation of our patient. Impaired cognition (predominantly affecting execution and memory) was present in 20 patients with a mean MMSE score of 19.5 (range: 4–27), motor dysfunction was detected in 29 patients, and seizures were observed in 10 patients.³

The presence of ovarian failure with leukodystrophy (ovarioleukodystrophy) has been reported in 62%–72.7% of adult women with VWM.^{2,3} Secondary amenorrhea is commoner than primary amenorrhea, infertility, and menorrhagia.^{2,3} Our patient had primary infertility, menometrorrhagia, and secondary amenorrhea that clinched the diagnosis of VWM.

An MRI examination of the brain in VWM shows diffuse white matter involvement with T1 hypointense and hyperintensities similar to CSF signals on T2/fluid-attenuated inversion recovery and proton density sequences.⁶ Corpus callosum is commonly involved in adult patients. The affected white matter shows lactate and glucose peaks on MRS.⁶ Over time, MRI shows progressive

Figure MRI Brain in Ovarioleukodystrophy



Axial MRI brain T2-weighted (A) and fluid-attenuated inversion recovery (FLAIR) (B) images show almost symmetrical confluent areas of hyperintense white matter that appear hypointense on T1-weighted images (C). The FLAIR image also shows multiple foci of cystic degeneration within the hyperintense areas.

rarefaction and cystic degeneration of the affected white matter.

VWM is caused by mutations in any of the 5 genes (*EIF2B1-5*) encoding the subunits of eukaryotic translation initiation factor (eIF2B α , β , γ , δ , and ϵ) with *EIF2B5* being the most commonly mutated.^{2,3} Most cases of ovarioleukodystrophy reported in the literature are due to mutations in *EIF2B2*, *EIF2B4*, and *EIF2B5* genes.⁷ Overall, the mutations in the exon 3 of the *EIF2B3* gene are rarely reported.⁸ Our patient tested positive for homozygous mutation c687T>G in the *EIF2B3* gene. This variant has previously been reported in a homozygous state in patients with VWM.⁸ There is no specific treatment for VWM. Avoidance of stressful situations such as trauma and active management of fever can prevent rapid deterioration.

Conclusion

VWM should be considered in adults presenting with dementia and white matter changes on brain MRI. Infertility and menstrual abnormalities are other clues that should raise a suspicion of VWM.

Acknowledgment

The authors thank Prof. Marjo van der Knaap, Department of Child Neurology, VU University Medical Center, Amsterdam, for conducting the genetic test for the patient.

Study Funding

The authors report no targeted funding.

Disclosure

None. Go to [Neurology.org/NG](https://www.neurology.org/NG) for full disclosures.

Publication History

Received by *Neurology: Genetics* July 21, 2021. Accepted in final form September 24, 2021.

Appendix Authors

Name	Location	Contribution
Jasmine Parihar, DM	Department of Neurology, All India Institute of Medical Sciences, New Delhi	Drafting/revision of the article for content, including medical writing for content; major role in the acquisition of data; study concept or design; and additional contributions: management of the patient
Deepti Vibha, DM	Department of Neurology, All India Institute of Medical Sciences, New Delhi	Drafting/revision of the article for content, including medical writing for content
Roopa Rajan, DM	Department of Neurology, All India Institute of Medical Sciences, New Delhi	Drafting/revision of the article for content, including medical writing for content
Awadh Kishor Pandit, DM	Department of Neurology, All India Institute of Medical Sciences, New Delhi	Drafting/revision of the article for content, including medical writing for content
Achal Kumar Srivastava, DM	Department of Neurology, All India Institute of Medical Sciences, New Delhi	Drafting/revision of the article for content, including medical writing for content
Kameshwar Prasad, DM	Rajendra Institute of Medical Sciences, Ranchi, Jharkhand, India	Drafting/revision of the article for content, including medical writing for content; study concept or design

References

1. van der Knaap MS, Pronk JC, Scheper GC. Vanishing white matter disease. *Lancet Neurol*. 2006;5(5):413-423.
2. Labauge P, Horzinski L, Ayrignac X, et al. Natural history of adult-onset eIF2B-related disorders: a multi-centric survey of 16 cases. *Brain*. 2009;132(pt 8):2161-2169.
3. Wei C, Qin Q, Chen F, et al. Adult-onset vanishing white matter disease with the EIF2B2 gene mutation presenting as menometrorrhagia. *BMC Neurol*. 2019;19(1):203.
4. Hamilton EMC, van der Lei HDW, Vermeulen G, et al. Natural history of vanishing white matter. *Ann Neurol*. 2018;84(2):274-288.
5. Ghezzi L, Scarpini E, Rango M, et al. A 66-year-old patient with vanishing white matter disease due to the p.Ala87Val EIF2B3 mutation. *Neurology*. 2012;79(20):2077-2078.
6. Senol U, Haspolat S, Karaali K, Lülecı E. MR imaging of vanishing white matter. *AJR Am J Roentgenol*. 2000;175(3):826-828.
7. Mathis S, Scheper GC, Baumann N, et al. The ovarioleukodystrophy. *Clin Neurol Neurosurg*. 2008;110(10):1035-1037.
8. Pronk JC, van Kollenburg B, Scheper GC, van der Knaap MS. Vanishing white matter disease: a review with focus on its genetics. *Ment Retard Dev Disabil Res Rev*. 2006;12(2):123-128.