



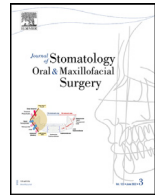
Since January 2020 Elsevier has created a COVID-19 resource centre with free information in English and Mandarin on the novel coronavirus COVID-19. The COVID-19 resource centre is hosted on Elsevier Connect, the company's public news and information website.

Elsevier hereby grants permission to make all its COVID-19-related research that is available on the COVID-19 resource centre - including this research content - immediately available in PubMed Central and other publicly funded repositories, such as the WHO COVID database with rights for unrestricted research re-use and analyses in any form or by any means with acknowledgement of the original source. These permissions are granted for free by Elsevier for as long as the COVID-19 resource centre remains active.



Available online at
ScienceDirect
 www.sciencedirect.com

Elsevier Masson France
EM|consulte
 www.em-consulte.com



Case Report

Ulcers on the bilateral palate mucosa following mRNA-based vaccination for coronavirus disease 2019 (COVID-19): A case report



Keigo Maeda^{a,*}, Daisuke Yamashita^b, Toshihiko Takenobu^a

^a Department of Oral and Maxillofacial Surgery, Kobe City Medical Center General Hospital, 2-1-1, Minatojima Minamimachi, Chuo-ku, Kobe City, Hyogo 650-0047, Japan

^b Department of Pathology, Kobe City Medical Center General Hospital, 2-1-1, Minatojima Minamimachi, Chuo-ku, Kobe City, Hyogo 650-0047, Japan

ARTICLE INFO

Article History:

Received 28 January 2022

Accepted 28 January 2022

Available online 1 February 2022

Keywords:

COVID-19

Oral mucosal ulcer

Adverse effect of vaccine

ABSTRACT

Severe acute respiratory syndrome coronavirus 2 has spread globally. Vaccination for coronavirus disease 2019 (COVID-19) is anticipated to reduce morbidity and mortality. However, the safety of vaccines against COVID-19 is a cause for concern and uncertainty, which leads to vaccine hesitancy. There have been some self-reported questionnaire studies regarding adverse effects after COVID-19 vaccination; however, adverse effects on the oral region are rare. In this report, we present one case of ulcers arising on the bilateral palate mucosa following COVID-19 vaccination, which was suspected to be an adverse effect of vaccination.

© 2022 Elsevier Masson SAS. All rights reserved.

1. Introduction

Coronavirus disease 2019 (COVID-19) is caused by the novel severe acute respiratory syndrome coronavirus 2, which has continued to spread globally since it was first reported in December 2019 [1]. The COVID-19 pandemic has adversely impacted social interactions and has placed tremendous strain on healthcare resources [2]. Vaccination is one of the most effective measures for preventing the spread of COVID-19 and the number of hospitalizations [3].

The United Kingdom became the first country to approve and distribute messenger ribonucleic acid (mRNA)-based vaccines on December 2, 2020 [3]. Subsequently, the United States issued the Emergency Use of Authorization for COVID-19 mRNA vaccines [3]. In Japan, the Ministry of Health, Labor, and Welfare granted the “Special Approval for Emergency on First COVID-19 Vaccine in Japan,” which permitted the use of two mRNA vaccines in February 2021 and May 2021. Vaccination was first initiated among healthcare workers in February 2021 [4].

However, there has been increasing concern regarding the potential adverse effects of COVID-19 mRNA vaccines. This has resulted in vaccine hesitancy, which remains a major issue in many countries. While healthcare professionals in Japan who initially received the vaccination during the phase-in period (February to March) have been closely monitored [4], there remains a dearth of data regarding

potential adverse events, especially those affecting the oral cavity. Herein, we report a case in which ulcers on the bilateral palatal mucosa were attributed to the administration of the mRNA-1273 COVID-19 vaccine.

2. Case report

A 58-year-old Japanese woman with no medical history was referred to our hospital with bilateral palatal mucosal ulcers. She received a second dose of the mRNA-1273 COVID-19 vaccine 20 d earlier. On the day after the second vaccination, she experienced transient mild fatigue and local pain at the injection site, and the symptoms resolved the following day. However, she experienced severe palatal mucosal pain 10 d after the second vaccination. The patient was prescribed a steroid ointment, 4% lidocaine gel, and sodium azulene sulfonate mouthwash at the otolaryngology clinic. As her symptoms persisted, she subsequently sought treatment at a dental clinic; however, due to the unknown origin of the ulcer, she was referred to our hospital.

The patient did not have fatigue, respiratory symptoms, or a history of COVID-19. Intraoral examination revealed ulcers on the bilateral palatal mucosa in the molar region (Fig. 1). The ulcers had well-defined margins, and no masses were present. Odontogenic infection, upper tooth mobility, Nikolsky's signs, and other lesions were not observed. No abnormalities were detected extraorally in the eyes, skin, or vulva. We performed a blood test and a biopsy of the left ulcer and instructed the patient to use a topical 4% lidocaine ointment and acetaminophen (600 mg daily for 7 d).

Informed Consent: Written informed consent was obtained from the patient included in the study.

* Corresponding author.

E-mail addresses: k.maeda@kcho.jp (K. Maeda), daisuke_yamashita@kcho.jp (D. Yamashita), takenobu@kcho.jp (T. Takenobu).

<https://doi.org/10.1016/j.jormas.2022.01.013>

2468-7855/© 2022 Elsevier Masson SAS. All rights reserved.

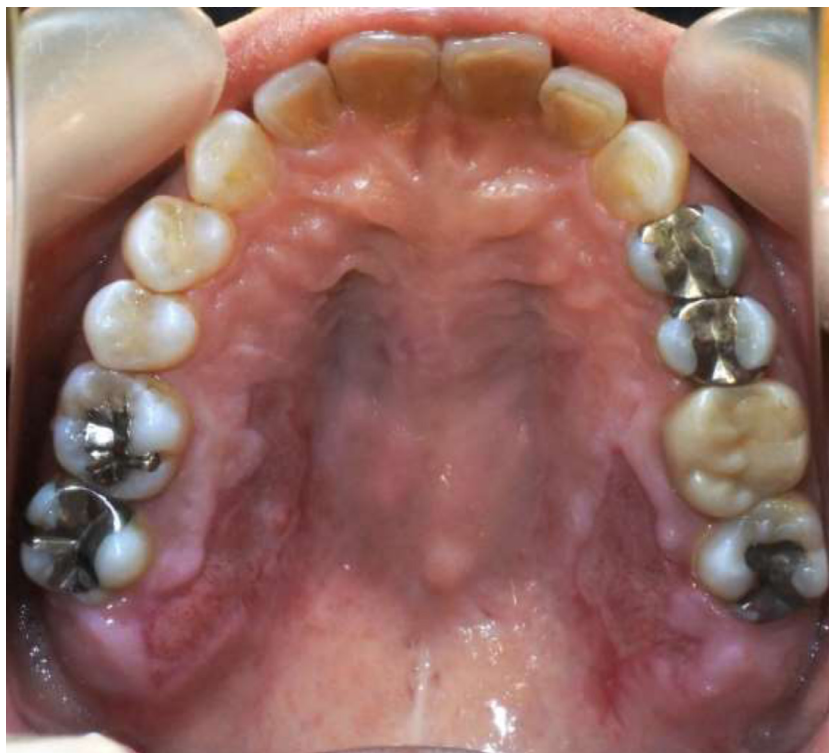

Fig. 1. Initial presentation of the ulcers on the bilateral palate mucosa in the molar region (mirror image).

Histopathological examination indicated a nonspecific ulcer without caseous necrosis; there were no signs of a tumor (Fig. 2). Immunohistochemical staining confirmed the absence of human immunodeficiency virus (HIV) type 1, cytomegalovirus, and Epstein–Barr virus. Periodic acid-Schiff staining indicated the absence of fungal infection. Laboratory tests were negative for white blood cells, C-reactive protein, desmograin 1 and 3 antigens, bullous

pemphigoid-180 antigen, HIV antigen, rapid plasma regain, and tuberculosis. The pain was in remission 1 week later. At 7 days, the ulcer and biopsy wound were almost completely healed, and the patient's eating difficulties were alleviated (Fig. 3). Thus, the patient's clinical presentation, course, and treatment outcome indicated that the intraoral mucosal ulcers were due to the adverse effects of the mRNA vaccine.

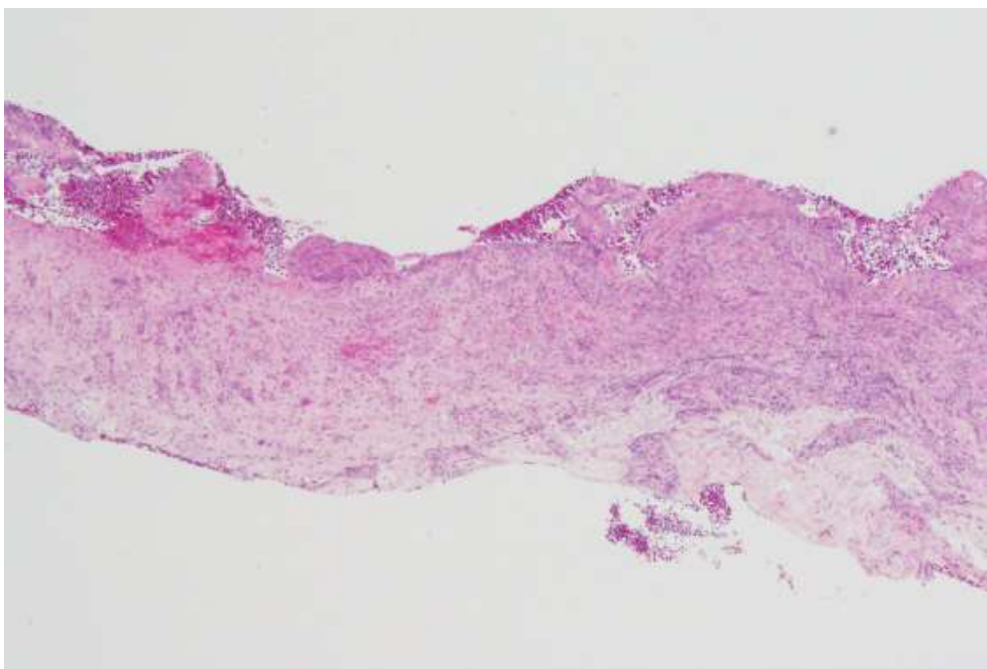


Fig. 2. Histopathological examination of the ulcer demonstrating nonspecific features (hematoxylin and eosin stain; original magnification, $\times 40$).

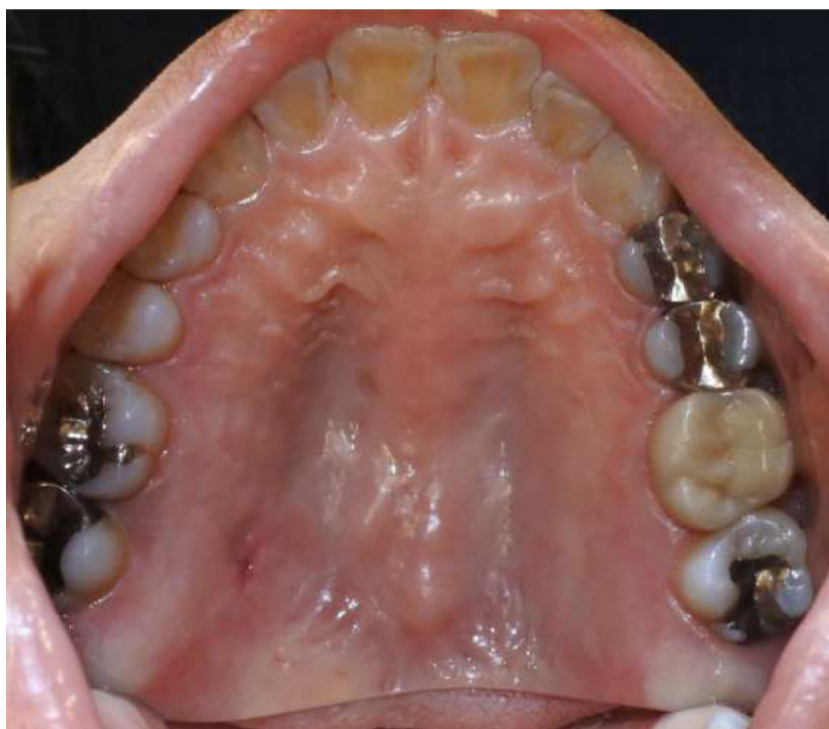

Fig. 3. Intraoral photograph (mirror image) showing a resolving ulcer at 1 week after the initial examination.

3. Discussion

As oral ulcers are often nonspecific, identification of a precipitating cause may be challenging [5]. Oral ulcers may be idiopathic (aphthous stomatitis) or attributed to infections, systemic disease, trauma, or adverse drug reactions. While the ulcers in the present case had a nonspecific appearance, they could be differentiated from aphthous stomatitis, which presents with a central yellow necrotic area surrounded by a distinctive red halo. Bacteria (tuberculosis or syphilis), viral (human simplex virus, cytomegalovirus, or Epstein–Barr virus), and deep fungal infections as well as immunity-related diseases (pemphigus vulgaris, bullous pemphigoid, or Behcet's disease) were ruled out by laboratory tests. An adverse drug reaction was also excluded as a potential cause of ulcers, as the patient was not taking any medications. Therefore, we concluded that the ulcers were caused by the adverse effects of the mRNA vaccine.

Coronavirus disease 19 vaccination has been associated with a myriad of systemic and local adverse effects, some of which mimic natural infections [6]. Prior studies have reported adverse effects in the orofacial region, such as anaphylactoid, aphthous-like lesions, bleeding gums, Bell's palsy, and swelling of the lips, face, and throat [7–10]. Among subjects administered the mRNA-1273 vaccine, 0.69% and 0.23% exhibited intraoral swelling and bleeding gums, respectively [7]. Oral ulcers were observed in 14% of the subjects administered the BNT162b2 COVID-19 mRNA vaccine [8]. Meo et al. [9] reported a higher rate of adverse effects with the mRNA-1273 vaccine compared to that of the BNT162b2 mRNA vaccine. Nevertheless, the lack of reports on oral ulceration with the mRNA-1273 vaccine may be due to the fact that the BNT162b2 mRNA vaccine is more frequently used in most countries. Current evidence indicates that adverse effects in the oral region are rare (fewer than 1 in 1000 vaccinations) [10] and self-limiting [11]. It has been reported that the onset of adverse effects following mRNA vaccine administration may appear up to 4 weeks later [8]. These findings should be interpreted with caution, as they were based on self-reported questionnaires, and some of these studies included information regarding mRNA (BNT162b2, mRNA-1273) and viral vectors (AZD1222).

Adverse mucosal effects have been reported for a wide range of vaccines, including diphtheria, tetanus, cellular pertussis, polio, and hepatitis B [6, 11, 12]. These studies have shown that oral ulceration is associated with increased levels of local and systemic T helper type 1 cytokine (e.g., interferon- γ) production. Our postulation that vaccination was the cause of oral ulceration in the present case is supported by a recent study that reported similar increases in cytokines (including interferon- γ) following mRNA COVID-19 vaccine administration [13].

Our case demonstrates that COVID-19 mRNA vaccines may be associated with oral ulceration. Nevertheless, further surveillance is required to clarify the frequency of this and other potential adverse effects. Dentists' knowledge of these orofacial manifestations will improve the recognition, management, and reporting of vaccine-related adverse effects [10]. It is desirable to increase the vaccination rate and end the COVID-19 pandemic through elimination of vaccine hesitancy by offering information about the adverse effects of vaccination.

Funding

This research did not receive any specific grant from funding agencies in the public, commercial, or not-for-profit sectors.

Declarations of Competing Interest

None

References

- [1] Banerji A, Wickner PG, Saff R, Stone CA, Robinson LB, Long AA, et al. mRNA vaccines to prevent COVID-19 disease and reported allergic reactions: current evidence and suggested approach. *J Allergy Clin Immunol Pract* 2021;9:1423–37. doi: [10.1016/j.jaip.2020.12.047](https://doi.org/10.1016/j.jaip.2020.12.047).
- [2] Baden LR, El Sahly HM, Essink B, Kotloff K, Frey S, Novak R, et al. Efficacy and safety of the mRNA-1273 SARS-CoV-2 vaccine. *N Engl J Med* 2021;384:403–16. doi: [10.1056/NEJMoa2035389](https://doi.org/10.1056/NEJMoa2035389).
- [3] Sun Q, Fathy R, McMahon D.E., Freeman E.E. COVID - 19 vaccines and the skin the landscape of cutaneous vaccine reactions worldwide 2020.

- [4] Iguchi T, Umeda H, Kojima M, Kanno Y, Tanaka Y, Kinoshita N, et al. Cumulative adverse event reporting of anaphylaxis after mRNA COVID-19 vaccine (Pfizer-BioNTech) injections in Japan: the first-month report. *Drug Saf* 2021;44:1209–14. doi: [10.1007/s40264-021-01104-9](https://doi.org/10.1007/s40264-021-01104-9).
- [5] Fitzpatrick SG, Cohen DM, Clark AN. Ulcerated lesions of the oral mucosa: clinical and histologic review. *Head Neck Pathol* 2019;13:91–102. doi: [10.1007/s12105-018-0981-8](https://doi.org/10.1007/s12105-018-0981-8).
- [6] Wojcicki AV, O'Brien KLO. Vulvar aphthous ulcer in an adolescent after Pfizer-BioNTech (BNT162b2) COVID-19 vaccination. *J Pediatr Adolesc Gynecol* 2021. doi: [10.1016/j.jpag.2021.10.005](https://doi.org/10.1016/j.jpag.2021.10.005).
- [7] Kadali RAK, Janagama R, Peruru S, Gajula V, Madathala RR, Chennaiahgari N, et al. Non-life-threatening adverse effects with COVID-19 mRNA-1273 vaccine: a randomized, cross-sectional study on healthcare workers with detailed self-reported symptoms. *J Med Virol* 2021;93:4420–9. doi: [10.1002/jmv.26996](https://doi.org/10.1002/jmv.26996).
- [8] Riad A, Pokorná A, Attia S, Klugarová J, Koščík M, Klugar M. Prevalence of covid-19 vaccine side effects among healthcare workers in the Czech Republic. *J Clin Med* 2021;10. doi: [10.3390/jcm10071428](https://doi.org/10.3390/jcm10071428).
- [9] Meo SA, Bukhari IA, Akram J, Meo AS, Klonoff DC. COVID-19 vaccines: comparison of biological, pharmacological characteristics and adverse effects of pfizer/BioNTech and moderna vaccines. *Eur Rev Med Pharmacol Sci* 2021;25:1663–9. doi: [10.26355/eurrev_202102_24877](https://doi.org/10.26355/eurrev_202102_24877).
- [10] Cirillo N. Reported orofacial adverse effects of COVID-19 vaccines: the knowns and the unknowns. *J Oral Pathol Med* 2021;50:424–7. doi: [10.1111/jop.13165](https://doi.org/10.1111/jop.13165).
- [11] Mazur M, Duś-Ilnicka I, Jedliński M, Ndokaj A, Janiszewska-Olszowska J, Ardan R, et al. Facial and oral manifestations following covid-19 vaccination: a survey-based study and a first perspective. *Int J Environ Res Public Health* 2021;18. doi: [10.3390/ijerph18094965](https://doi.org/10.3390/ijerph18094965).
- [12] Drucker A, Corrao K, Gandy M. Vulvar aphthous ulcer following Pfizer-BioNTech COVID-19 vaccine – a case report. *J Pediatr Adolesc Gynecol* 2021. doi: [10.1016/j.jpag.2021.10.007](https://doi.org/10.1016/j.jpag.2021.10.007).
- [13] Corbett KS, Flynn B, Foulds KE, Francica JR, Boyoglu-Barnum S, Werner AP, et al. Evaluation of the mRNA-1273 vaccine against SARS-CoV-2 in nonhuman Primates. *N Engl J Med* 2020;383:1544–55. doi: [10.1056/NEJMoa2024671](https://doi.org/10.1056/NEJMoa2024671).