

## Percutaneous Gastrostomy Site Metastasis From Head and Neck Tumors: A Single Institution Case Series

James S. Metkus, MD ; David Cognetti, MD; Joseph Curry, MD

**Objectives:** Head and neck cancer (HNC) patients often require percutaneous gastrostomy (PEG) tube placement due to malnutrition and dysphagia. While beneficial, PEG tube placement can cause a rare but reportable complication of metastasis of the original tumor to the gastrostomy exit site. The objectives of this case series were to present HNC patients at a single institution that developed PEG tube metastases, their subsequent treatment, and review of the literature for similar cases.

**Methods:** We describe three HNC patients who underwent PEG tube placement and developed metastasis at their tube site. We also describe their metastatic disease treatment and compare these cases with similar cases in the literature.

**Results:** All three cases' initial staging were node positive and all three cases had their PEG tubes placed by the "pull" method. Two patients presented with masses at their PEG site while one patient had a site mass on surveillance positron emission topography (PET) imaging. Biopsy showed the original HNC metastasized to the gastrostomy site. Two patients were treated with surgical resection while one patient was treated with palliative chemotherapy. The "pull" method has been most associated with cases of metastasis in the literature. In the literature, risk factors for metastasis include initial tumor clinical and pathological staging.

**Conclusion:** PEG site metastasis should be suspected in patients with skin changes at the PEG site. "Pull" procedures may cause metastasis through physical contact with the primary tumor causing tumor seeding at the PEG site. Surgical resection of metastasis has been shown to be an effective treatment strategy for PEG site metastasis. In patients with higher stage cancers, tube insertion methods that avoid contact with the primary tumor should be considered.

**Key Words:** Head and neck, oropharynx, oral cavity, PEG tube.

**Level of Evidence:** NA

### INTRODUCTION

Due to their disease burden and subsequent treatment, many head and neck cancer (HNC) patients face the challenge of malnutrition secondary to tumor or treatment-related dysphagia.<sup>1</sup> Enteral feeding via a percutaneous endoscopic gastrostomy (PEG) tube is frequently required to address this.<sup>2,3</sup> Its advantages include low cost, the ability to maintain gut function, and improved comfort and convenience over nasoenteral feeding.<sup>4</sup> There are three commonly used methods for PEG tube placement which include: the tube being pulled into the stomach via the Ponsky-Gauderer pull, the tube being pushed over a wire through the mouth via the Sacks-Vine push technique, or the tube being pushed over a dilator via the Russel introducer technique. The pull technique is the most commonly used due to its low complication rate.<sup>1</sup> Complication rates with PEG tube placement have

been found to be between 15–35 percent.<sup>1</sup> A rare complication that has been reported in studies of HNC patients is tumor metastasis to the PEG tube site. Due to its rare occurrence, the incidence and risk factors for this complication are not well described. We describe three different patients with HNC who experienced PEG site metastases, including their initial presentation and treatment course.

### CASE REPORT

We identified three HNC patients who underwent PEG tube placement and were subsequently diagnosed with PEG tube metastasis at a single institution. Demographic data as well as primary tumor characteristics and treatment information are summarized in Table I. PEG tube placement characteristics are summarized in Table II.

#### Case 1

Patient 1 was 57 years old at the time of presentation. He underwent a PEG tube placement prior to definitive chemoradiotherapy for a T3N2c squamous cell carcinoma of the oropharynx. The PEG tube placement was complicated by development of a rectus sheath abscess on postoperative day 7. This was successfully treated with incision and drainage and antibiotics. At three months after completion of treatment, computed tomography (CT) imaging revealed evidence of lung metastases. At four months after completion of treatment he presented with a painful bleeding mass at the

This is an open access article under the terms of the Creative Commons Attribution-NonCommercial-NoDerivs License, which permits use and distribution in any medium, provided the original work is properly cited, the use is non-commercial and no modifications or adaptations are made.

From the Department of Otolaryngology, Thomas Jefferson University, Philadelphia, Pennsylvania.

Editor's Note: This Manuscript was accepted for publication 21 October 2017.

There are no financial interests or conflicts of interests to disclose.

Send correspondence to James Metkus, M.D. Thomas Jefferson University Department of Otolaryngology, 925 Walnut Street, Philadelphia, PA, 19107.

DOI: 10.1002/liv.127

TABLE I.  
Patient Demographics.

	Patient 1	Patient 2	Patient 3
Age	57	60	71
Sex	Male	Male	Female
PEG technique	Pull	Pull	Pull
Smoking history	No	No	No
Alcohol history	Yes	Yes	No
Type of cancer	Squamous cell carcinoma	Squamous cell carcinoma	Squamous cell carcinoma
Tumor subsite	Base of tongue and supraglottic larynx (oropharynx)	Oropharynx	Oral cavity
Initial TNM stage	T3N2c	T2N2c	T2N2b
Tumor grade	Moderate	Poor	Poor with extracapsular spread
p16 status	Positive	Positive	Positive
Treatment prior to PEG Insertion	Chemoradiation	Chemoradiation	Chemoradiation
Treatment of primary tumor	Palliative chemoradiation	Resection	Resection and chemoradiation
Other sites of metastasis	Lung	Left and right glossotonsillar sulci	None
Survival after PEG placement (months)	20.6	13.37	NA
Cause of death	Disease metastasis	Complication of treatment of local recurrence	NA

PEG = Percutaneous gastrostomy tube.

PEG tube site (Fig. 1). Biopsy confirmed squamous cell carcinoma. He underwent palliative chemotherapy and ultimately succumbed to his disease.

### Case 2

Patient 2 was 60 years old at the time of presentation. He underwent a PEG tube placement prior to definitive chemoradiotherapy for a T3N2c squamous cell carcinoma of the oropharynx. At three months after completion of treatment, surveillance PET/CT imaging revealed evidence of omental mass. Follow-up ultrasound was concerning for drop metastasis separate from the PEG Tube site. Fine needle aspiration (FNA) was

negative for malignancy. The PEG tube was removed and he was taken to the OR for definitive excisional biopsy which confirmed squamous cell carcinoma with negative margins. At four months after completion of treatment, he presented with a painful bleeding mass at the PEG tube site. Biopsy confirmed squamous cell carcinoma. He subsequently developed recurrence in the oropharynx and succumbed due complications of its treatment

### Case 3

Patient 3 was 71 years old at the time of presentation. She underwent a PEG tube placement at the time of surgery for a T2N2b squamous cell carcinoma of the

TABLE II.  
PEG Tube Characteristics.

	Patient 1	Patient 2	Patient 3
PEG Placement Type	Pull	Pull	Pull
PEG tube Placement during treatment	Prior to chemoradiation,	Prior to chemoradiation	(Prior to surgery)
Months between PEG Placement and Metastasis Biopsy	9.93	6.93	6.53
Complications of PEG tube placement	PEG tube infection, rectus sheath abscess	None	None
Presentation of PEG tube metastasis	Mass at site	PET/CT of abdomen pelvis in omentum	Mass at site associated with pain and bleeding
Treatment for metastasis	Palliative chemoradiation with erbitux, carbo, taxol	Surgical removal of omental met	Removal of met and replacement of tube with J tube
Prognosis	Dead of disease	No evidence of disease, deceased from other cause	No evidence of disease

PEG = Percutaneous gastrostomy tube.

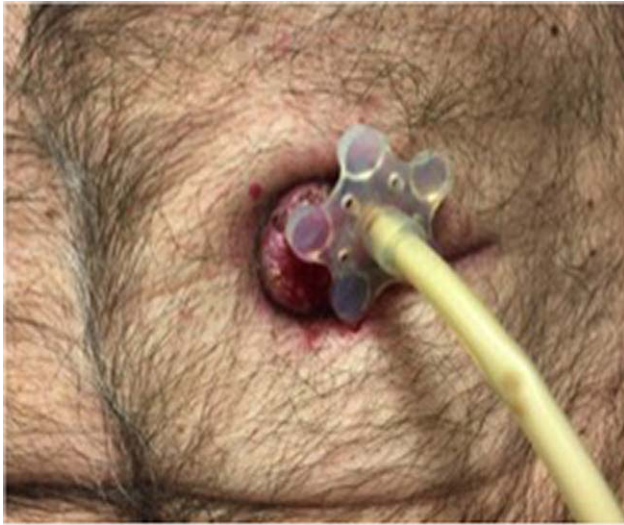


Fig. 1. Case 1 with PEG site abdominal wall metastasis  
PEG = percutaneous gastrostomy.

oral cavity. The surgery was noted for lymph nodes with positive extracapsular extension as well as lymphovascular and perineural invasion. She subsequently completed chemoradiation. At four months after completion of treatment, she presented with pain at the PEG tube site. CT imaging revealed hyperdense lesion at PEG tube site. Biopsy confirmed squamous cell carcinoma. Her tube was removed and underwent resection of the mass with negative margins and jejunostomy tube placement which was subsequently removed. Patient is currently disease free.

## DISCUSSION

Due to its low occurrence, it has been difficult to quantify the incidence of abdominal wall metastasis in HNC patients.<sup>5</sup> There have been 143 reported cases of head and neck cancers seeding to the PEG tube port site as well as one reported case of metastasis from an open gastrostomy tube site.<sup>6</sup> Of those 144 cases, almost all cases were either stage 3 or stage 4 tumors with tumor subsites either in the oral cavity or the larynx. Previous studies have identified key risk factors for stomal metastasis including: primary advanced stage pharyngo-esophageal tumor and squamous cell histology with poor or moderate differentiation.<sup>7</sup> All of these factors were present in this case series.

There have been multiple theories proposed for the mechanism behind stomal seeding in HNC patients. One theory proposed the insertion of the PEG tube in active HNC causes disruption of the primary tumor, leading to seeding of the PEG tube site. One study found 9 of 40 patients with HNC who underwent PEG tube placement via the pull through method had tumor cells at their

stomal site immediately after tube placement.<sup>8</sup> Another theory focuses hematogenous spread from the primary head and neck site to a susceptible site which is supported by patients with PEG tube metastases often have metastases at other locations.<sup>9</sup> For this case series, Patient 1 supports the latter theory, due to the presence of a lung metastasis before the PEG tube metastasis occurred. All three patients also support the disruption theory since both had their PEG tubes placed via the pull method. Overall, the pull method has the greatest association with stomal metastasis compared to the other PEG tube placement techniques.

In reviewing techniques for PEG site metastasis removal, a study reported a successful removal of a PEG tube metastasis via bloc resection including a total gastrectomy with part of the abdominal wall removed with the stomach.<sup>9</sup> This study, along with the above reported cases help show that PEG tube metastasis can be treated surgically that potentially can lead to curative outcomes.

## CONCLUSION

While surgical technique may contribute to the risk of stomal metastasis, tumor biology, location, staging, and differentiation seem to be stronger risk factors for the overall prognosis and risk of metastatic disease. For patients with these risk factors, other methods of PEG tube placement, including the push guidewire and direct introducer may lower the risk of metastatic disease. In addition, surgical resection can be potentially curative for these patients.

## BIBLIOGRAPHY

1. Siegel R, Naishadham D, Jemal A. Cancer statistics, 2013. *CA Cancer J Clin.* 2013;63:11–30.
2. Locher JL, Bonner JA, Carroll WR, et al. Patterns of prophylactic gastrostomy tube placement in HNC patients: a consideration of the significance of social support and practice variation. *Laryngoscope.* 2013;123:1918–1925.
3. Kramer S, Newcomb M, Hessler J, Siddiqui F. Prophylactic versus reactive PEG tube placement in head and neck cancer. *Otolaryngol Head Neck Surg.* 2014;150:407–412.
4. Taller A, Horváth E, Iliás L, Kótai Z, Simig M, Élő J, Harsányi L. Technical modifications for improving the success rate of PEG tube placement in patients with head and neck cancer. *Gastrointest Endosc.* 2001;54:633–636.
5. Fung E, Strosberg DS, Jones EL, Dettorre R, Suzo A, Meara MP, Narula VK, Hazey JW. Incidence of abdominal wall metastases following percutaneous endoscopic gastrostomy placement in patients with head and neck cancer. *Surg Endosc.* 2017;31:3623–3627.
6. Ellrichmann M, Sergeev P, Bethge J, et al. Prospective evaluation of malignant cell seeding after percutaneous endoscopic gastrostomy in patients with oropharyngeal/esophageal cancers. *Endoscopy.* 2013;45(7):526–531.
7. Alagaratnam TT, Ong GB. Wound implantation—a surgical hazard. *Br J Surg.* 1977;64:872–875.
8. Brown MC. Cancer metastasis at percutaneous endoscopic gastrostomy stomata is related to the hematogenous or lymphatic spread of circulating tumor cell. *Am J Gastroenterol.* 2000;95:3288–3291.
9. Fonseca J, Adriana C, Fróis-Borges M, Meira T, Oliveira G, Santos JC. Ostomy metastasis after pull endoscopic gastrostomy: a unique favorable outcome. *Nutr Hosp.* 2015;31:1879–1881.