

MINI-FOCUS ISSUE: CONGENITAL HEART DISEASE

INTERMEDIATE

CASE REPORT: CLINICAL CASE

# Transcatheter Aortic Valve Replacement in a Patient With Levo-Transposition of the Great Arteries



Eric Kellett, MD, Scott Lilly, MD, PhD, Curt Daniels, MD, Saurabh Rajpal, MD

## ABSTRACT

Levo-transposition of the great arteries is a congenital heart disease characterized by atrioventricular and ventricular-arterial discordance. Aortic valve disease in levo-transposition of the great arteries patients is uncommon. We present a patient with levo-transposition of the great arteries and severe aortic stenosis who successfully underwent transcatheter aortic valve replacement and the diagnostic and procedural challenges involved. (**Level of Difficulty: Intermediate.**) (J Am Coll Cardiol Case Rep 2020;2:1730-3) © 2020 The Authors. Published by Elsevier on behalf of the American College of Cardiology Foundation. This is an open access article under the CC BY-NC-ND license (<http://creativecommons.org/licenses/by-nc-nd/4.0/>).

## HISTORY OF PRESENTATION

A 63-year-old White man with history of levo-transposition of the great arteries (LTGA) presented with progressive fatigue and shortness of breath for the last several months. He denied lower extremity edema, palpitations, dizziness, lightheadedness, or syncope. His vitals included heart rate of 90 beats/min, blood pressure of 114/63 mm Hg, and respiratory

rate of 16 breaths/min. On examination, he had a grade III/VI systolic ejection murmur over the upper sternal border and a grade II/VI pansystolic murmur over the left lower sternal border.

## PAST MEDICAL HISTORY

The patient was diagnosed with LTGA during childhood and followed with a cardiologist. He did not have any other cardiac anomalies associated with LTGA, such as ventricular septal defect, pulmonic stenosis, or tricuspid valve dysplasia (1,2). His only surgical history was dual-chamber pacemaker placement for complete heart block 10 years ago. He was on rivaroxaban for paroxysmal atrial fibrillation. The patient had a history of rheumatic fever as a child but no records were available for review. A transthoracic echocardiogram (TTE) done 2 years prior showed normal biventricular function, aortic sclerosis, and mild aortic stenosis. Other noncardiac history included obstructive sleep apnea on continuous

## LEARNING OBJECTIVES

- A patient with history of LTGA who presented with shortness of breath secondary to aortic stenosis amenable to TAVR.
- To generate a differential for shortness of breath in patients with LTGA.
- To understand that typical evaluation and treatment methods may have to be adapted to patients with congenital heart defects because of their atypical anatomy.

From the Division of Cardiology, Department of Internal Medicine, Ohio State University College of Medicine, Columbus, Ohio. All authors have reported that they have no relationships relevant to the contents of this paper to disclose.

The authors attest they are in compliance with human studies committees and animal welfare regulations of the authors' institutions and Food and Drug Administration guidelines, including patient consent where appropriate. For more information, visit the *JACC: Case Reports* [author instructions page](#).

Manuscript received June 11, 2020; accepted July 1, 2020.

positive airway pressure, type II diabetes mellitus, and hyperlipidemia.

### DIFFERENTIAL DIAGNOSIS

LTGA is characterized by an acyanotic functional reversal of the right and left ventricles in the sequence of blood flow so that systemic venous “blue” blood via right atrium and left atrioventricular (mitral) valve reaches the right-sided morphologic left ventricle, which is connected to the pulmonary artery; the pulmonary venous “red” blood via the right atrioventricular (tricuspid) valve reaches the left-sided morphologic right ventricle, which is connected to the anteriorly placed aorta. The differential diagnosis for dyspnea on exertion and fatigue in an adult patient with LTGA includes:

- Systemic ventricular dysfunction. Studies have shown that by the age of 45 years, 67% of patients with associated congenital lesions and 25% of patients without associated congenital lesions develop systemic ventricular dysfunction (3). Our patient did not have an associated causative congenital lesion and last echo showed normal systolic function.
- Systemic atrioventricular (tricuspid) valve regurgitation. Studies have shown that 32% of patients with LTGA develop moderate to severe right atrioventricular (tricuspid) valve regurgitation by age 45 years (3).
- Ischemic heart disease. Coronary artery disease is not uncommon in patients with congenital heart disease and risk factors (4,5). Our patient had advanced age plus multiple risk factors, thus ischemic heart disease was in our differential.
- Complication of chronic arrhythmia and long-term pacing. Retrospective studies have found uni-ventricular pacing in patients with LTGA can be complicated by delayed systemic ventricular dysfunction. Biventricular pacing is preferred because it reduces late-onset complications (6).
- Severe aortic stenosis. Although aortic regurgitation has been shown to occur in roughly 25% patients with LTGA (3), aortic stenosis has been reported only in the setting of coexistent bicuspid aortic valve (4). Our patient did not have a bicuspid aortic valve.

### INVESTIGATIONS

Electrocardiogram showed atrial-sensed ventricular-paced rhythm unchanged from prior. TTE (Videos 1A and 1D) showed moderately reduced systemic ventricular function (right ventricular ejection fraction,

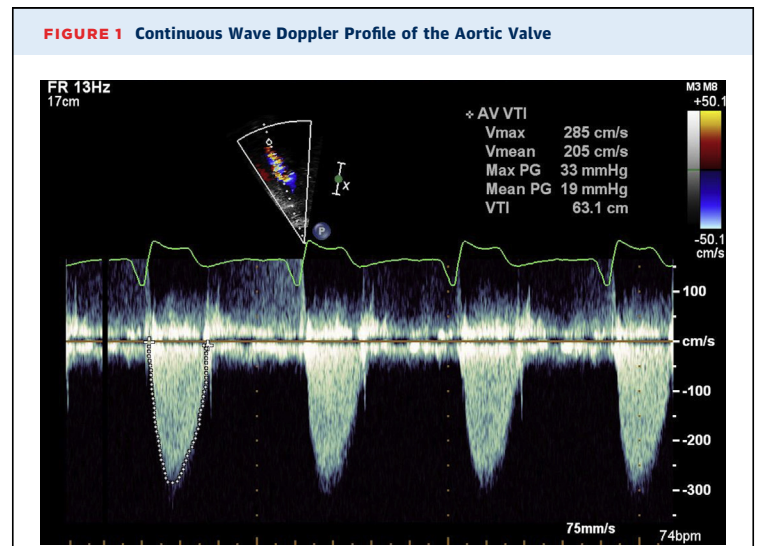
35% to 40%) and subpulmonic ventricular function (left ventricular ejection fraction, 40%). There was mild tricuspid regurgitation (Video 1B). The aortic valve was thickened and calcified with reduced mobility (Videos 1C and 2A). Two-dimensional and Doppler findings were consistent with low-flow low-gradient aortic stenosis (Figure 1, Video 1E). The peak gradient was 33 mm Hg with a mean gradient of 19 mm Hg. Coronary angiogram demonstrated mild nonobstructive coronary artery disease.

Based on the elevated Doppler gradient and aortic valve appearance on TTE we suspected that his aortic valve stenosis could be clinically and hemodynamically significant. Therefore, we elected to perform a hemodynamic catheterization at rest and with dobutamine to evaluate for low-flow low-gradient aortic stenosis.

Hemodynamic catheterization demonstrated an aortic valve gradient of 28 mm Hg, Fick cardiac output of 4.2 l/min, and aortic valve area of 0.9 cm<sup>2</sup> per the Hakki equation (7). With dobutamine 20 µg/kg/min, the aortic valve gradient increased to 39 mm Hg, cardiac output increased to 4.8 l/min, and aortic valve area remained 0.9 cm<sup>2</sup>. This demonstrated that with increasing cardiac output the aortic valve gradient increased 2-fold, whereas the aortic valve area remained in the severe range, confirming

### ABBREVIATIONS AND ACRONYMS

- LTGA = levo-transposition of the great arteries
- LVOT = left ventricular outflow tract
- RVOT = right ventricular outflow tract
- TAVR = transcatheter aortic valve replacement
- TTE = transthoracic echocardiogram



Continuous wave Doppler profile of the aortic valve obtained from the apical 5-chamber view shows a mean gradient of 19 mm Hg and a peak gradient of 33 mm Hg. Although these gradients are in mild-moderate range, poor leaflet mobility in Video 1C and poor systemic ventricular function in Video 1D suggest that the aortic valve gradients may underestimate severity.

the diagnosis of low-flow low-gradient aortic stenosis.

## MANAGEMENT

The patient was assessed in our adult congenital heart disease and interventional cardiology clinics. Based on the presence of symptomatic severe low-flow low-gradient aortic stenosis, we recommended aortic valve replacement and referred to cardiothoracic surgery. He was deemed a high surgical risk because of severe biventricular dysfunction. After discussion in the multidisciplinary case conference, plans were made for transcatheter aortic valve replacement (TAVR). Computed tomography angiography for TAVR evaluation was performed, which showed calcific valvular aortic stenosis with restricted leaflet mobility (Video 2B).

With pre-procedural planning with computed tomography and transesophageal echocardiography guidance intraprocedurally, the patient underwent placement of Medtronic 34 CoreValve Evolute R (Minneapolis, Minnesota) via right iliofemoral approach and tolerated the procedure with no complications.

## DISCUSSION

There are several characteristics that make this case unique. First, aortic stenosis in LTGA is rare and has not been reported in the absence of bicuspid aortic valve (5). We suspect this aortic stenosis may have been caused by the patient's history of rheumatic fever as a child. Patients with LTGA typically develop failure of the systemic tricuspid valve and systemic ventricular dysfunction (3).

Diagnosis was also challenging because of poor echocardiographic windows and complex anatomy. Moreover, because the LTGA aortic valve is in the right ventricular outflow tract (RVOT) instead of the left ventricular outflow tract (LVOT), we could not calculate aortic valve area using the continuity equation because it relies on geometric assumptions for the LVOT but not the RVOT (8). The RVOT is comparatively more muscular, more variable, and more contractile than the LVOT. In addition, it is difficult to obtain an accurate RVOT diameter on TTE.

TAVR placement in the RVOT is also uniquely difficult. The RVOT has a much larger area and more significant variance throughout systole and diastole than the LVOT. Because of the close proximity of the aortic valve and tricuspid valve, tricuspid regurgitation is a concern. Furthermore, the levorotation of the heart and anteriorly placed aorta makes catheter manipulation atypical, with the levo-transposition yielding a high risk of atrioventricular block. Finally, LTGA is frequently associated with coronary anomalies, so the valve placement must consider altered coronary anatomy as well.

Despite the challenges of placing a transcatheter aortic valve in the RVOT, with careful pre-procedural planning our outcome was excellent. In our literature search we could find only 1 report of TAVR placement in the RVOT of an LTGA patient, although in that case the patient did not survive to 1-year post-operation (9).

## FOLLOW-UP

As of most recent follow-up 12 months post-operative, the patient has done well with improved functional capacity back to baseline. Follow-up TTE was performed, which showed improved systemic right ventricle ejection fraction of 55% and estimated mean gradient of 8 mm Hg, with only trivial tricuspid valve regurgitation.

## CONCLUSIONS

TAVR was successful in our patient with LTGA with improvement in symptoms, functional capacity, and echocardiographic measures of systemic and subpulmonic ventricular function without worsening of systemic tricuspid valve function. TAVR can be used as a strategy in LTGA patients who are at high risk of surgery.

**ADDRESS FOR CORRESPONDENCE:** Dr. Eric Kellett, 395 West 12th Avenue, Third Floor, Department of Internal Medicine, Ohio State University College of Medicine, Columbus, Ohio 43210. E-mail: [eric.kellett@osumc.edu](mailto:eric.kellett@osumc.edu).

## REFERENCES

1. Warnes CA. Transposition of the great arteries. *Circulation* 2006;114:2699-709.
2. Lundstrom U, Bull C, Wyse RK, Somerville J. The natural and "unnatural" history of congenitally corrected transposition. *Am J Cardiol* 1990;65:1222-9.
3. Graham TP Jr., Bernard YD, Mellen BG, et al. Long-term outcome in congenitally corrected transposition of the great arteries: a multi-institutional study. *J Am Coll Cardiol* 2000;36:255-61.
4. Lui GK, Saidi A, Bhatt AB, et al. Diagnosis and management of noncardiac complications in adults with congenital heart disease: a scientific statement from the American Heart Association. *Circulation* 2017;136:e348-92.
5. Stout KK, Daniels CJ, Aboulhosn JA, et al. 2018 AHA/ACC guideline for the management of adults with congenital heart disease: executive summary: a report of the American College of Cardiology/American Heart Association Task Force on Clinical Practice Guidelines. *J Am Coll Cardiol* 2019;73:1494-563.

6. Hofferberth SC, Alexander ME, Mah DY, Bautista-Hernandez V, del Nido PJ, Fynn-Thompson F. Impact of pacing on systemic ventricular function in L-transposition of the great arteries. *J Thorac Cardiovasc Surg* 2016;151:131-8.

7. Hakki AH, Iskandrian AS, Bemis CE, et al. A simplified valve formula for the calculation of stenotic cardiac valve areas. *Circulation* 1981;63:1050-5.


8. Saikrishnan N, Kumar G, Sawaya FJ, Lerakis S, Yoganathan AP. Accurate assessment of aortic stenosis: a review of diagnostic modalities and hemodynamics. *Circulation* 2014;129:244-53.

9. Yeong M, Bedair R, Szantho G, et al. Transcatheter aortic valve implantation in adult congenital heart disease - single centre experience. *Heart* 2017;103:A6.

---

**KEY WORDS** aortic valve stenosis, congenital heart defect, echocardiography, levo-transposition of the great arteries, transcatheter aortic valve replacement

---

 **APPENDIX** For supplemental videos, please see the online version of this paper.