



Short Communication

SARS-CoV-2 RNA detection in cerebrospinal fluid: Presentation of two cases and review of literature

María Belén Luis^{a,*}, Nora Fernández Liguori^a, Pablo Adrián López^b, Ricardo Alonso^a^a Department of Neurology, Sanatorio Güemes – University Hospital, Buenos Aires, Argentina^b Department of Neurology, Hospital Alemán, Buenos Aires, Argentina

ARTICLE INFO

Keywords:

SARS-CoV-2
SARS-CoV-2 neurological manifestations
SARS-CoV-2 infection
Meningoencephalitis
Encephalitis
Myelitis
SARS-CoV-2 RNA
Neuroimaging

ABSTRACT

Neurological manifestations of SARS-CoV-2 infection are multiple and heterogeneous. However, confirmation of nervous system impairment by viral RNA detection in cerebrospinal fluid (CSF) is uncommon. We report two cases of central nervous system (CNS) involvement with positive real-time reverse-transcriptase polymerase chain reaction (RT-PCR) test in CSF.

1. Introduction

Since the beginning of the ongoing SARS-CoV-2 pandemic, several studies describing the neurological manifestations of the disease have been published. Although this virus has special predilection for the respiratory and cardiovascular systems, its potential neurotropism is also known (Ahmad and Rathore, 2020). The most common neurological manifestations are smell and taste disturbances, headache, myalgia, dizziness and impaired consciousness. Other reported clinical pictures include ataxia, neuropathies, meningoencephalitis, demyelinating disorders and cerebrovascular disease (Favas et al., 2020; Ibrahim, 2020). As described in previous reports, patients with severe forms of the disease are more prone to developing CNS impairment than those with mild to moderate infections (Mao et al., 2020; Helms et al., 2020). The exact explanation for SARS-CoV-2 CNS involvement is not well established yet, but two possible mechanisms have been proposed: direct viral CNS invasion or cytokine cascade induced by the virus (Tandon et al., 2021; Al-olama et al., 2020).

Despite the wide variety of published literature about neurological disorders associated with SARS-CoV-2 infection, there are few reported cases with viral RNA detection in CSF. We present two cases of young patients with CNS disease due to SARS-CoV-2, with positive viral RT-PCR test in CSF.

2. Case 1

A 25-year-old female was referred to our hospital due to acute impairment of consciousness. She had a personal history of anxiety disorder and had been diagnosed with mild COVID-19 (odynophagia and hyposmia) four months before admission with complete recovery of symptoms afterwards.

Ten days before hospitalization the patient began with a holocranial headache, vomits and fever, and one week later she had a tonic-clonic seizure. At initial evaluation in another hospital, neck stiffness was noted. Brain computed tomography (CT) scan was unremarkable and there were no positive findings in blood tests. Analysis of CSF yielded hypoglycorrachia (37 mg/dl), hyperproteinorrachia (247 mg/dl) and no cells. Acute bacterial meningitis was suspected and treatment with Ceftriaxone was started. The patient quickly developed an altered mental state, and antimicrobial therapy was switched to Meropenem, Vancomycin and Acyclovir. She was then transferred to our hospital. At the initial neurological examination, mutism and stupor were observed. The pupils were symmetrical and reactive to light. There were no signs of cranial nerve involvement. She had nuchal rigidity and upper limbs hyperperonia. Shortly after admission she developed a comatose state and a non-convulsive status epilepticus was ruled out by EEG. The new CSF examination revealed normal opening pressure, lymphocytic pleocytosis (380/mm³ – 90% lymphocytes), hyperproteinorrachia (98.3 mg/dl),

* Corresponding author.

E-mail address: ma.belen.luis@gmail.com (M.B. Luis).<https://doi.org/10.1016/j.bbih.2021.100282>

Received 3 May 2021; Received in revised form 4 June 2021; Accepted 4 June 2021

Available online 8 June 2021

2666-3546/© 2021 The Authors. Published by Elsevier Inc. This is an open access article under the CC BY-NC-ND license (<http://creativecommons.org/licenses/by-nc-nd/4.0/>).

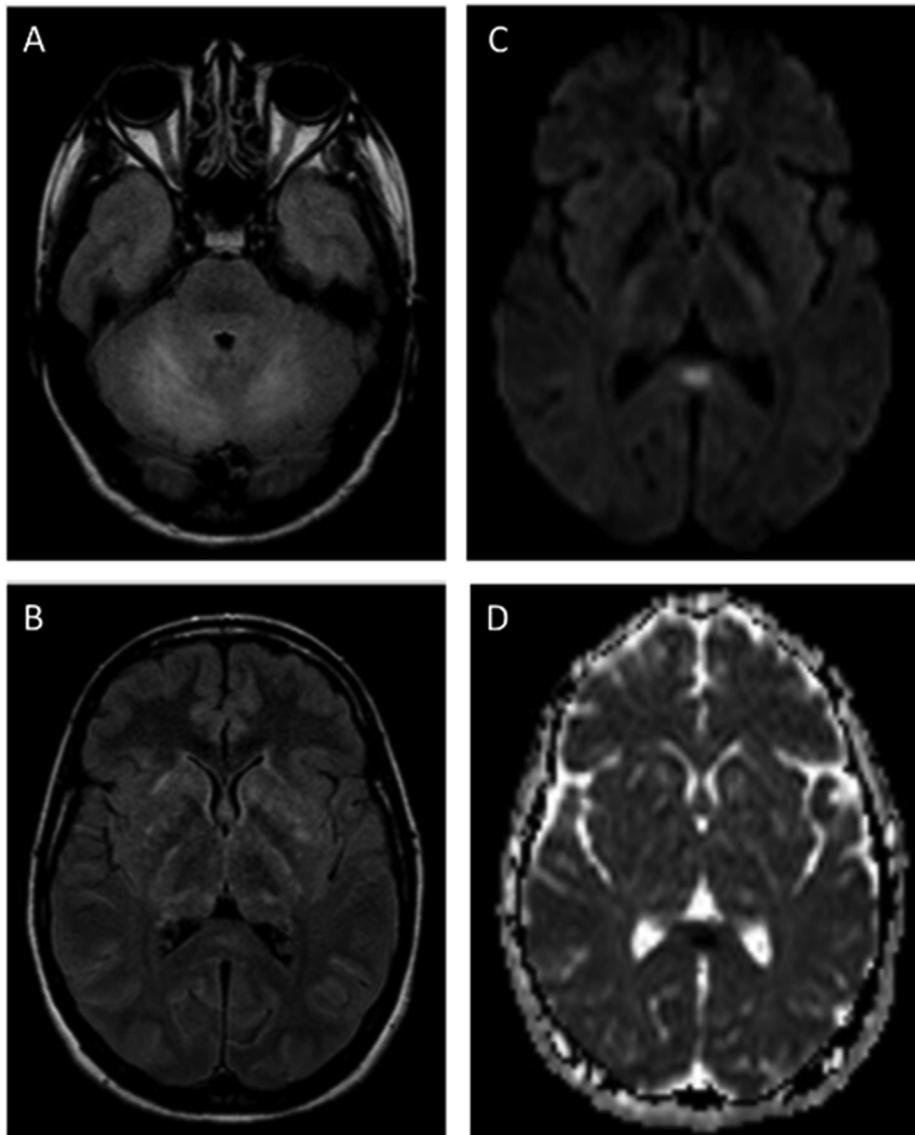


Fig. 1. Case 1 Brain Mri Findings

(A - B) Hyperintense lesions on fluid-attenuated inversion-recovery (FLAIR) sequence involving the cerebellum, thalamus and basal ganglia. (C-D) Focal area of markedly increased signal on diffusion-weighted imaging (DWI) with decrease apparent diffusion coefficient (ADC) in the splenium of the corpus callosum.

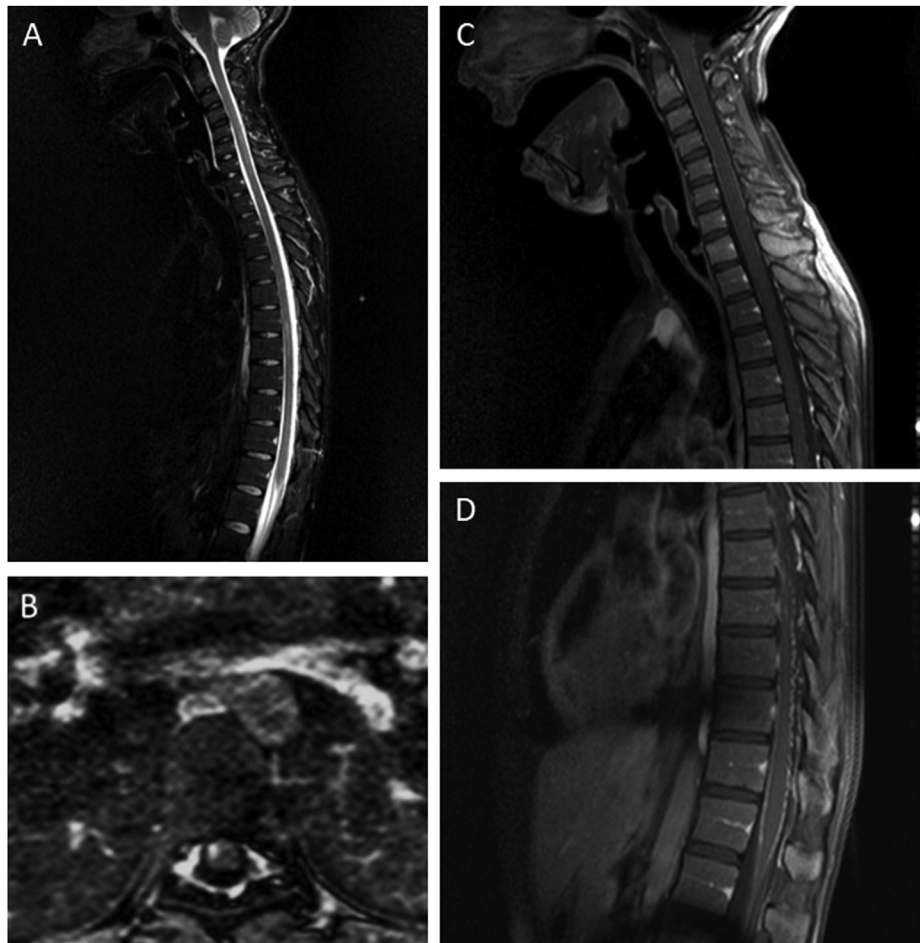


Fig. 2. Case 1 Spinal Cord Mri Findings

(A-D) Signal hyperintensity on Short Tau Inversion Recovery (STIR) sequence extending from C2 to Th3 level and from Th5 to Th10 (longitudinally extensive myelitis), with patchy and eccentric contrast enhancement. T1 post contrast cervical and lumbar pial enhancement associated to conus medullaris enhancement.

normal glucose level (57 mg/dl) and increased lactate concentration (4.32 mmol/l). Brain and spinal cord magnetic resonance imaging (MRI) were abnormal (Figs. 1 and 2). Extensive work-up was conducted to exclude secondary causes such as infection, autoimmune, metabolic and endocrinological diseases (Table 1). The RT-PCR test for SARS-CoV-2 was performed on samples from nasopharyngeal swab and CSF. The specific SARS-CoV-2 RNA was detected in CSF whereas the nasopharyngeal swab test was negative.

After one week in intensive care unit (ICU) with mechanical ventilation, the physical examination revealed bradylalia, square wave jerks, ataxia, myoclonus in four limbs and urinary retention. The patient developed subsequently significant clinical recovery, remaining only with mild gait disturbance. She was finally discharged after three weeks of hospitalization.

3. CASE 2

A 41-year-old male, with a history alcoholism, iron deficiency anemia and chronic cardiovascular disease, was hospitalized because of a septic shock secondary to a skin and soft tissue infection. He had a favorable clinical course and completed antibiotic therapy. As part of our institutional protocol, he was performed a nasopharyngeal swab RT-PCR test for SARS-CoV-2 that resulted positive. The chest computed tomography scan was normal and the patient remained asymptomatic. After 20 days, he developed disorientation, psychomotor agitation and rapidly reached a stuporous state. The rest of the neurological examination was unremarkable. Blood test yielded only a mild chronic hyponatremia. Brain

MRI exhibited no pathological features. A lumbar puncture was performed and the CSF showed mildly increased protein level (95.9 mg/dl), normal glycorrhachia (43 mg/dl) and no cells. RT-PCR SARS-CoV2 test was positive in CSF. Further work-up excluded other infectious etiologies. On the following days, he experienced spontaneous complete recovery.

4. Discussion

Approximately one third of SARS-CoV-2 infected patients develop neurological manifestations that involve predominantly the CNS (Ibrahim, 2020; Mao et al., 2020). We report two cases of CNS manifestations of SARS-CoV-2 infection, confirmed by the detection of viral RNA in CSF. The first case is a female patient who presented with meningoencephalitis and myelitis four months after a mild SARS-CoV-2 infection. The second one is a patient with a SARS-CoV-2 infection entirely confined to the CNS (encephalitis), with no involvement of other organ systems. Several hypotheses have been proposed in order to explain this neurological involvement. One explanation is CNS penetration through hematogenous spread via permeable blood-brain barrier, or retrograde neuronal route through the cribriform plate and olfactory bulb (Tandon et al., 2021; Wu et al., 2020; Montalvan et al., 2020). The ability of SARS-CoV-2 spike protein to bind to angiotensin-converting enzyme 2 (ACE-2) receptors on the capillary endothelium may be responsible for facilitating viral entry into the CNS (Al-olama et al., 2020; Wu et al., 2020). Another hypothesis is based on the inflammatory cytokine release leading to a cascade of immune cells within the CNS. In the latter, the

Table 1
Case 1 and 2 csf analysis and blood tests.

CSF	CASE 1		CASE 2
	First hospital	Second hospital	
White blood cell count/mm ³	0	380 – 90% mononuclear	0
Proteins (mg/dl)	247	98.3	95.9
Glucose (mg/dl)	37	57	43
Lactic acid (mmol/L)	Not available	4.32	2.21
Culture (bacterial, fungal and KOCH)	Negative	Negative	Negative
Viral PCR (Herpes simplex I/II, Human herpes virus VI, Varicella Zoster, Cytomegalovirus, Epstein Barr, Enterovirus, Coxsackie)	Not available	Negative Adenovirus PCR: Negative	Negative
Mycobacterium tuberculosis PCR	Not available	Negative	Not available
Neuronal autoantibodies (Anti-NMDAR, AMPAR, CASPR2, LGI1, GABA _B R)	Not available	Negative	Not available
Blood tests			
Neuronal autoantibodies:			
- Anti-NMDAR, AMPAR, CASPR2, LGI1, GABA _B R	Not available	Negative	Not available
- Anti-GAD			
- Anti-Hu, Ri, Yo			
AQP4-IgG	Not available	Negative	Not available
MOG-IgG	Not available	Negative	Not available
ANA, Anti- dsDNA, RF, RA latex turbid test, LAC, ACL, anti-CCP,			
Complement C3/C4	Not available	Negative	Not available
TSH	Not available	Negative	Negative
HIV	Not available	Negative	Negative
VDRL	Not available	Negative	Negative
Hepatitis B/C	Not available	Negative	Negative
Cytomegalovirus, Epstein Barr, Mycoplasma and Dengue IgM	Not available	Negative	Not available
Vitamin B12, folic acid	Not available	Normal	Not available

NMDAR: N-methyl-d-aspartate receptor; AMPAR: α -amino-3-hydroxy-5-methyl-4-isoxazolepropionic acid receptor; CASPR2: contactin-associated protein-like 2 receptor; LGI1: leucine-rich glioma-inactivated 1; GABA_BR: γ -aminobutyric acid type B receptor; GAD: Glutamic acid decarboxylase; AQP4-IgG: Aquaporin-4 antibodies; MOG-IgG: Myelin oligodendrocyte glycoprotein antibodies; ANA: Anti-nuclear antibody; Anti-dsDNA: Anti double-stranded DNA; RF: Rheumatoid Factor; RA latex turbid test: Rheumatoid arthritis latex turbid test; LAC: Lupus anticoagulant; ACL: Anticardiolipin antibodies; Anti-CCP: Anti-cyclic citrullinated peptide antibodies; TSH: Thyroid-stimulating hormone; VDRL: Venereal Disease Research Laboratory.

consequent endothelial dysfunction predisposes to thrombosis or hemorrhage and results in stroke (Tandon et al., 2021; Al-olama et al., 2020). Furthermore, it is believed that para- and post-infectious complications due to dysregulation of the immune system may lead to antibody mediated damage of the nervous system, causing encephalitis, Guillain Barre Syndrome and its variants (Guilmot et al., 2021; Franke et al., 2021). Autopsy performed in patients with SARS-CoV-2 infection showed hyperemic and edematous brain tissue and neuronal degeneration (National Health Commission & State Administration of Traditional Chinese Medicine, 2020).

As in our cases, it has been previously described that a positive nasal swab does not correlate with the presence or absence of the virus in the CSF of patients with neurological symptoms (Tandon et al., 2021). To date, only a small proportion of reported patients with neurological manifestations and CSF analysis, had positive RT-PCR in CSF (Helms et al., 2020; Moriguchi et al., 2020; Virhammar et al., 2020; Khodamoradi et al., 2020; Barros Domingues et al., 2020; Fadakar et al., 2020; Duong et al., 2020; Huang et al., 2020; Westhoff et al., 2020; Mardani et al., 2020; Cebrián et al., 2020; Novi et al., 2020). Clinical and para-clinical findings of these patients are summarized in Table 2. The most frequent CSF findings were occasionally hyperproteinorrachia and mild lymphocytic pleocytosis. Helms et al. reported a cohort of 118 ICU patients with acute respiratory distress syndrome due to SARS-CoV-2 infection who developed delirium and/or abnormal neurological

examination. CSF analysis was performed in 25 of those patients, with positive RT-PCR SARS-CoV-2 in only one patient (Helms et al., 2020).

As far as neuroimaging is concerned, most commonly reported findings represent cases of cerebrovascular disease. Based on a recent systematic review, the possible SARS-CoV-2 brain MRI patterns are large vessel occlusion infarction, usually with hemorrhagic transformation; lobar and cortical intracerebral hemorrhage; multiple callosal and juxtacortical white matter cerebral microbleeds and hemorrhagic necrotizing encephalopathy (Ladopoulos et al., 2021). Nevertheless, as these features are also seen in critical ill patients, the direct association with SARS-CoV-2 infection is still to be determined. No typical feature of SARS-CoV-2 associated demyelination, leukoencephalopathy and myelitis was identified. Other imaging findings are cerebral venous sinus thrombosis, posterior reversible encephalopathy syndrome, cytotoxic lesion in the corpus callosum, basal ganglia abnormalities, leptomeningeal, cranial and spinal nerve enhancement (Ladopoulos et al., 2021) (Chougar et al., 2020) (Klironomos et al., 2020) (Kremer et al., 2020). Up to now, seven cases of SARS-CoV-2 associated myelitis have been published, only one with viral RNA presence in CSF (Munz et al., 2020) (AlKetbi et al., 2020) (Sotoca and Rodríguez-Álvarez, 2020) (Valiuddin et al., 2020) (Zanin et al., 2020) (Sarma and Bilello, 2020) (Zhao et al., 2020). Clinical and imaging findings are described in Table 3.

Table 2
Patients with neurological manifestations and positive sars-cov-2 rt-pcr in csf, clinical and paraclinical findings.

Author	CSF WBC/mm ³	CSF protein (mg/dl)	CSF glucose (mg/dl)	RT-PCR for SARS-CoV-2 in nasopharyngeal swab	Clinical manifestation	Brain/Spinal cord MRI findings
Moriguchi et al. (Moriguchi et al., 2020)	12 – 83% mononuclear	Not available	Not available	Negative	Meningoencephalitis	FLAIR hyperintensity within the right mesial temporal lobe and hippocampus with slight hippocampal atrophy. Hyperintensity along the wall of right lateral ventricle on DWI. No pathological contrast enhancement.
Virhammar et al. (Virhammar et al., 2020)	No cells	Increased	Not available	Positive	Acute necrotizing encephalopathy	Symmetrical T2/FLAIR hyperintensities in subinsular region, medial temporal lobes and thalami, with restricted diffusion, contrast enhancement and small foci of decreased signal on SWI. FLAIR increased signal in the brain stem.
Khodamoradi et al. (Khodamoradi et al., 2020)	1 st) 90 – 100% mononuclear 2 nd) 23 – 56.5% mononuclear	0.2 685	45 40.3	Negative	Meningitis	Normal
Domingues et al. (Barros Domingues et al., 2020)	1	32	68	Negative	Sensory symptoms	Hyperintensity lesion on T2/STIR sequence at C6 level.
Helms et al. (Helms et al., 2020)	Not available	Not available	Not available	Positive	Delirium	Not available
Fadakar et al. (Fadakar et al., 2020)	Mild pleocytosis	Increased	Normal	Positive	Cerebellitis	Bilateral cerebellar hemispheres and vermis hyperintensities on FLAIR, with T1 post contrast cerebellar cortical-meningeal enhancement.
Huang et al. (Huang et al., 2020)	70 – 100% mononuclear	100	120	Positive	Meningoencephalitis	Not available. Normal brain CT.
Westhaff et al. (Westhaff et al., 2020)	1	110	93	Positive	Meningoencephalitis	White matter hyperintensities on T2 sequence, T1 post contrast linear meningeal enhancement and subtle area of diffusion restriction in the right frontal lobe.
Mardani et al. (Mardani et al., 2020)	1920 - 90% polymorphonuclear	94.8 g/l	10	Positive	Encephalitis	Not available. Brain CT with mild cortical atrophy.
Cebrián et al. (Cebrián et al., 2020)	1	30	82	Positive	Headache, impaired consciousness, acute ischemic stroke	Corticospinal focal area of restricted diffusion in right parietal lobe.
Novi et al. (Novi et al., 2020)	22 – predominantly mononuclear	45.2	Not available	Negative	Acute disseminated encephalomyelitis	Multiple T1 post contrast enhancing lesions in the brain, associated with an enhancing single spinal cord lesion at the Th8 level and bilateral optic nerve enhancement.
Luis et al.	1 st) 0 2 nd) 380 – 90% mononuclear	1 st)247 2 nd)98.3	1 st)37 2 nd)57	Negative	Meningoencephalitis and myelitis	FLAIR hyperintensities involving the cerebellum, thalamus and basal ganglia. Focal area of restricted diffusion in the splenium of the corpus callosum. STIR signal hyperintensity extending from C2 to Th3 level and from Th5 to Th10, with patchy and eccentric contrast enhancement. T1 post contrast cervical and lumbar pial enhancement associated to conus medullaris enhancement.
Luis et al.	0	95.9	43	Positive	Encephalitis	Normal

FLAIR: Fluid-attenuated inversion-recovery; DWI: Diffusion-weighted imaging; SWI: Susceptibility-weighted images; STIR: Short Tau Inversion Recovery.

Table 3
Clinical and imaging features of sars-cov-2 associated myelitis.

Author	Clinical manifestations	Spinal cord MRI findings	Brain MRI findings	RT-PCR SAR-CoV-2 in CSF
Munz et al. (Munz et al., 2020)	Spastic paraparesis, hypoesthesia below the Th9 level, bladder dysfunction.	T2 signal hyperintensity at Th3-5 and Th9-10 level.	Normal	Negative
AlKetbi et al. (AlKetbi et al., 2020)	Distal paresis of upper limbs and paraplegia, truncal weakness, urinary retention.	Hyperintense signal involving predominantly the grey matter of the cervical, dorsal and lumbar regions, with restricted diffusion and no contrast enhancement. Mild enlargement and swelling of the cervical cord.	Not available	Not available
Sotoca et al. (Sotoca and Rodríguez-Álvarez, 2020)	Cervical pain, imbalance, subtle weakness of left hand, right facial and left hand hypoesthesia.	T2 signal hyperintensity extending from the medulla oblongata to Th6, with swelling and diffuse patchy enhancing lesions. Area of central necrosis at Th1 level with peripheral enhancement (Acute necrotizing myelitis)	Normal	Negative
Valiuddin et al. (Valiuddin et al., 2020)	Tetraparesis, paresthesias in hands, abdomen and lower limbs, constipation.	Patchy T2 signal hyperintensity throughout the entire length of the cervical cord with mild swelling, without contrast enhancement.	Not available	Negative
Zanin et al. (Zanin et al., 2020)	Impaired state of consciousness.	Focal T2 signal hyperintensity in bulb-medullary junction, C2 level and from C3 to Th6, without contrast enhancement.	T2 hyperintensity signal of the periventricular white matter, without contrast enhancement.	Negative
Sarma et al. (Sarma and Bilello, 2020)	Mild weakness among with paresthesias and decreased proprioception in upper limbs, hypoesthesia below the Th5 level, Lhermitte's sign, low back pain, wide-based gait, urinary retention.	Signal changes throughout the spinal cord to the conus medullaris.	Not available.	Not available
Zhao et al.	Paresis of upper limbs and paraplegia, hypoesthesia in lower limbs, sensory level at Th10, urinary and bowel incontinence.	Not available	Not available	Not available
Novi et al. (Novi et al., 2020)	Bilateral vision impairment, headache, irritability, right abdominal sensory level, hypoesthesia on the right leg, ageusia and anosmia.	T2 signal hyperintensity at Th8 level, involving less than 2 metameric levels, with eccentric areas of contrast enhancement.	Multiple T1 post contrast enhancing lesions and bilateral optic nerve enhancement.	Positive
Luis et al.	Headache, fever, vomits, nuchal rigidity, impaired consciousness, seizures, ataxia, urinary retention.	STIR signal hyperintensity extending from C2 to Th3 level and from Th5 to Th10 (longitudinally extensive myelitis), with patchy and eccentric contrast enhancement. T1 post contrast cervical and lumbar pial enhancement associated to conus medullaris enhancement.	FLAIR hyperintensities involving the cerebellum, thalamus and basal ganglia. Focal area of restricted diffusion in the splenium of the corpus callosum.	Positive

STIR: Short Tau Inversion Recovery; FLAIR: Fluid-attenuated inversion-recovery.

5. Conclusions

SARS-CoV-2 can affect the nervous system in any stage of infection, and neurological complications can even represent the only manifestation of the disease. Nevertheless, they are currently underdiagnosed and viral RNA detection in CSF is infrequent. In patients with neurological symptoms, SARS-CoV-2 infection should be considered in order to avoid delayed diagnosis and prevent transmission.

Ethical approval

The ethical review board approved this manuscript.

Consent

CASE 1: Consent-to-disclose was signed by a patient's family member.
CASE 2: Consent-to-disclose was signed by the patient.

Declaration of competing interest

The authors declare that there is no conflict of interest.

References

Ahmad, I., Rathore, F.A., 2020 Jul. Neurological manifestations and complications of COVID-19: a literature review. *J. Clin. Neurosci.* 77, 8–12. <https://doi.org/10.1016/j.jocn.2020.05.017>.

- Al-olama, M., et al., 2020 Jul. COVID-19-associated meningoencephalitis complicated with intracranial hemorrhage: a case report. *Acta Neurochir.* 162 (7), 1495–1499. <https://doi.org/10.1007/s00701-020-04402-w>.
- AlKetbi, R., et al., 2020 Jun. Acute myelitis as a neurological complication of Covid-19: A case report and MRI findings. *Radiol Case Rep* 15 (9), 1591–1595. <https://doi.org/10.1016/j.radcr.2020.06.001>.
- Barros Domingues, R., et al., 2020 Nov. First case of SARS-CoV-2 sequencing in cerebrospinal fluid of a patient with suspected demyelinating disease. *J. Neurol.* 267 (11), 3154–3156. <https://doi.org/10.1007/s00415-020-09996-w>.
- Cebrián, J., et al., 2020 Aug. Headache and impaired consciousness level associated with SARS-CoV-2 in CSF: a case report. *Neurology* 95 (6), 266–268. <https://doi.org/10.1212/WNL.00000000000010213>.
- Chougar, L., et al., 2020 Dec. Retrospective observational study of brain MRI findings in patients with acute SARS-CoV-2 infection and neurologic manifestations. *Radiology* 297 (3), E313–E323. <https://doi.org/10.1148/radiol.2020202422>.
- Duong, L., et al., 2020 Jul. Meningoencephalitis without respiratory failure in a young female patient with COVID-19 infection in Downtown Los Angeles, early April 2020. *Brain Behav. Immun.* 87, 33. <https://doi.org/10.1016/j.bbi.2020.04.024>.
- Fadakar, N., et al., 2020 Dec. A first case of acute cerebellitis associated with coronavirus disease (COVID-19): a case report and literature review. *Cerebellum* 19 (6), 911–914. <https://doi.org/10.1007/s12311-020-01177-9>.
- Favas, T.T., et al., 2020 Dec. Neurological manifestations of COVID-19: a systematic review and meta-analysis of proportions. *Neurol. Sci.* 41 (12), 3437–3470. <https://doi.org/10.1007/s10072-020-04801-y>.
- Franke, C., et al., 2021 Mar. High frequency of cerebrospinal fluid autoantibodies in COVID-19 patients with neurological symptoms. *Brain Behav. Immun.* 93, 415–419. <https://doi.org/10.1016/j.bbi.2020.12.022>.
- Guilmot, A., et al., 2021 Mar. Immune-mediated neurological syndromes in SARS-CoV-2-infected patients. *J. Neurol.* 268 (3), 751–757. <https://doi.org/10.1007/s00415-020-10108-x>.
- Helms, J., et al., 2020 Aug. Delirium and encephalopathy in severe COVID-19: a cohort analysis of ICU patients. *Crit. Care* 24 (1), 491. <https://doi.org/10.1186/s13054-020-03200-1>.

- Huang, Y.H., et al., 2020 Jul. SARS-CoV-2 detected in cerebrospinal fluid by PCR in a case of COVID-19 encephalitis. *Brain Behav. Immun.* 87, 149. <https://doi.org/10.1016/j.bbi.2020.05.012>.
- Ibrahim, W., 2020 Oct. Neurological manifestations in coronavirus disease 2019 (COVID-19) patients: a systematic review of literature. *CNS Spectr.* 1–12. <https://doi.org/10.1017/S1092852920001935>.
- Khodamoradi, Z., et al., 2020 Dec. COVID-19 meningitis without pulmonary involvement with positive cerebrospinal fluid PCR. *Eur. J. Neurol.* 27 (12), 2668–2669. <https://doi.org/10.1111/ene.14536>.
- Klironomos, S., et al., 2020 Dec. Nervous system involvement in coronavirus disease 2019: results from a retrospective consecutive neuroimaging cohort. *Radiology* 297 (3), E324–E334. <https://doi.org/10.1148/radiol.2020202791>.
- Kremer, S., et al., 2020 Nov. Brain MRI findings in severe COVID-19: a retrospective observational study. *Radiology* 297 (2), E242–E251. <https://doi.org/10.1148/radiol.2020202222>.
- Ladopoulos, T., et al., 2021 Mar. COVID-19: neuroimaging features of a pandemic. *J. Neuroimaging* 31 (2), 228–243. <https://doi.org/10.1111/jon.12819>.
- Mao, L., et al., 2020 Jun. Neurologic manifestations of hospitalized patients with coronavirus disease 2019 in wuhan, China. *JAMA Neurology* 77 (6), 683–690. <https://doi.org/10.1001/jamaneurol.2020.1127>.
- Mardani, M., et al., 2020 Jul. COVID-19 infection recurrence presenting with meningoencephalitis. *New Microbes New Infect* 37, 100732. <https://doi.org/10.1016/j.nmni.2020.100732>.
- Montalvan, V., et al., 2020 Jul. Neurological manifestations of COVID-19 and other coronavirus infections: a systematic review. *Clin. Neurol. Neurosurg.* 194, 105921. <https://doi.org/10.1016/j.clineuro.2020.105921>.
- Moriguchi, T., et al., 2020 May. A first case of meningitis/encephalitis associated with SARS-Coronavirus-2. *Int. J. Infect. Dis.* 94, 55–58. <https://doi.org/10.1016/j.ijid.2020.03.062>.
- Munz, M., et al., 2020 Aug. Acute transverse myelitis after COVID-19 pneumonia. *J. Neurol.* 267 (8), 2196–2197. <https://doi.org/10.1007/s00415-020-09934-w>.
- National Health Commission & State Administration of Traditional Chinese Medicine, 2020 May. Diagnosis and treatment protocol for novel coronavirus pneumonia (Trial version 7). *Chin. Med. J.* 133 (9), 1087–1095. <https://doi.org/10.1097/CM9.0000000000000819>.
- Novi, G., et al., 2020 Jun. Acute disseminated encephalomyelitis after SARS-CoV-2 infection. *Neurol Neuroimmunol Neuroinflamm* 7 (5), e797.
- Sarma, D., Bilello, L.A., 2020 Aug. A case report of acute transverse myelitis following novel coronavirus infection. *Clinical Practice and Cases in Emergency Medicine* 4 (3), 321–323. <https://doi.org/10.5811/cpcem.2020.5.47937>.
- Sotoca, J., Rodríguez-Álvarez, Y., 2020 Sep. COVID-19-associated acute necrotizing myelitis. *Neurol Neuroimmunol Neuroinflamm* 7 (5), e803. <https://doi.org/10.1212/NXI.0000000000000803>.
- Tandon, M., et al., 2021 Mar. A comprehensive systematic review of CSF analysis that defines neurological manifestations of COVID-19. *Int. J. Infect. Dis.* 104, 390–397. <https://doi.org/10.1016/j.ijid.2021.01.002>.
- Valiuddin, H., et al., 2020 May. Acute transverse myelitis associated with SARS-CoV-2: a Case-Report. *Brain Behav Immun Health* 5, 100091. <https://doi.org/10.1016/j.bbhi.2020.100091>.
- Virhammar, J., et al., 2020 Sep. Acute necrotizing encephalopathy with SARS-CoV-2 RNA confirmed in cerebrospinal fluid. *Neurology* 95 (10), 445–449. <https://doi.org/10.1212/WNL.0000000000010250>.
- Westhoff, T.H., et al., 2020 Nov. Allograft infiltration and meningoencephalitis by SARS-CoV-2 in a pancreas-kidney transplant recipient. *Am. J. Transplant.* 20 (11), 3216–3220. <https://doi.org/10.1111/ajt.16223>.
- Wu, Y., et al., 2020 Jul. Nervous System involvement after infection with COVID-19 and other coronaviruses. *Brain Behav. Immun.* 87, 18–22. <https://doi.org/10.1016/j.bbi.2020.03.031>.
- Zanin, L., et al., 2020 Jul. SARS-CoV-2 can induce brain and spine demyelinating lesions. *Acta Neurochir.* 162 (7), 1491–1494. <https://doi.org/10.1007/s00701-020-04374-x>.
- Zhao, K., et al., 2020. Acute myelitis after SARS-CoV-2 infection: a case report. *Mar. medRxiv.* <https://doi.org/10.1101/2020.03.16.20035105>, 2020.03.16.20035105.