

# Congenital cutaneous solitary mixed hamartoma: An unusual case containing eccrine, neural, and lipomatous components

Ji Yoon Choo, MD, Ji Hyun Lee, MD, Jun Young Lee, MD, and Young Min Park, MD  
Seoul, Korea

**Key words:** cutaneous adnexal neoplasm; dermatopathology; skin tumors.

## INTRODUCTION

Hamartomas are benign malformations composed of the tissue elements that are normally found at the site of their growth and grow in a disorganized fashion. To date, several clinical and histologic presentations of eccrine hamartomas are reported in the literature.<sup>1-3</sup> Cutaneous hamartomas that contain neural or fatty elements are rare, and few cases are reported in the literature.<sup>4-6</sup> Herein, we report an unusual case of a congenital cutaneous solitary mixed hamartoma containing eccrine, neural, and lipomatous components.

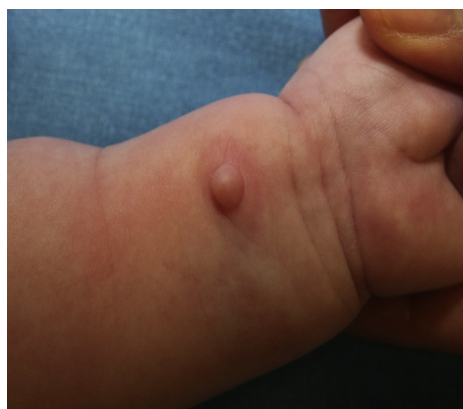## CASE REPORT

A 3-month-old girl presented with a solitary, skin-colored nodule on her left wrist (Fig 1). Her parents reported that the size of the lesion had remained the same since birth and that no increased sweat production had been noted in the affected area. There was no history of any genetic disorders or neural neoplasms in her family. Palpation of the nodule did not elicit any symptoms.

Histologically, the nodule comprised 3 compartments of eccrine, fatty, and neural components in the upper, middle, and lower portions, respectively (Fig 2, A). Numerous mature eccrine glands and ducts proliferated between the dermis and the fat tissue, some of which were focally embedded within the fat tissue (Fig 2, B). Lobules of mature fat cells occupied the middle portion of the nodule. A deeper portion of the lesion comprised clusters of spherical bodies that resembled Pacinian corpuscles (Fig 2, C). Each corpuscle was composed of a central homogenous, acellular, eosinophilic core that was surrounded by

### Abbreviation used:

NLS: Nevus lipomatosus superficialis



**Fig 1.** A firm solitary nodule protruding from the volar side of the patient's left wrist.

13 to 25 pale-staining, concentric lamellae. The inner core and surrounding lamellae were immunopositive for S-100 protein, and the outer perineurial cells stained positive for epithelial membrane antigen. Neurofilament protein reactivity in the inner core showed the presence of axons. The lesion showed no interval changes during the 13-month follow-up period.

## DISCUSSION

Many histologic variants of organoid nevi of the eccrine apparatus have been described, including angiomatous, pilar, lipomatous, and mucinous

From the Department of Dermatology, College of Medicine, Seoul St. Mary's Hospital, The Catholic University of Korea.

Funding sources: None.

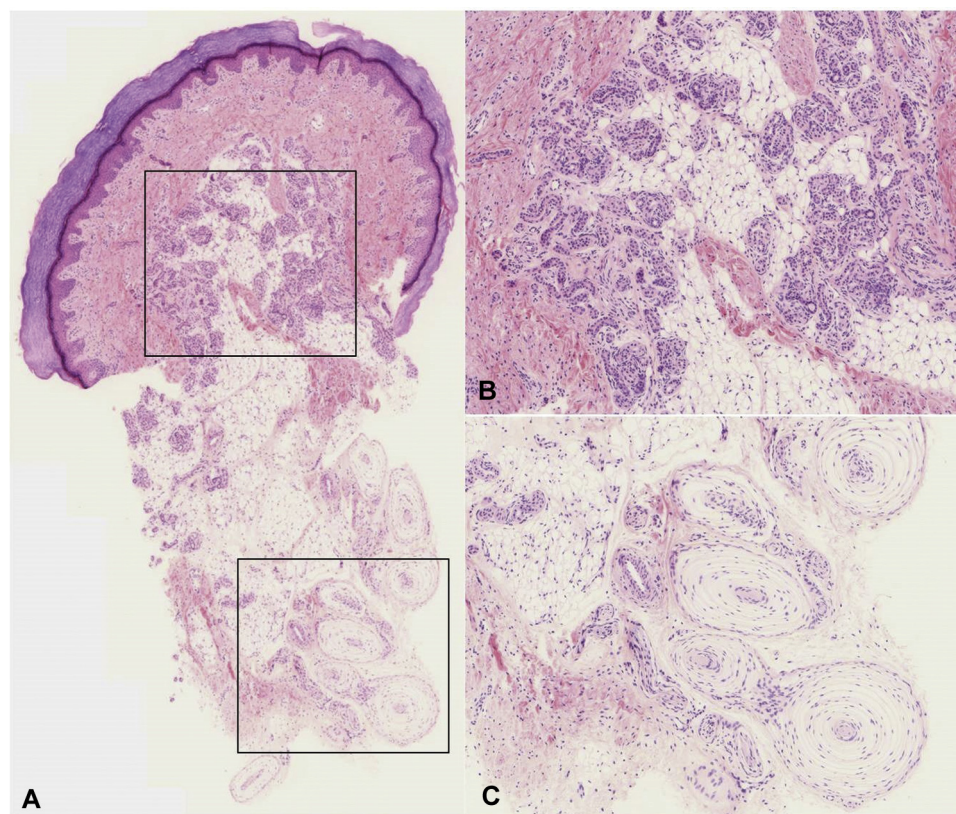
Conflicts of interest: None declared.

Correspondence to: Young Min Park, MD, Department of Dermatology, College of Medicine, Seoul St. Mary's Hospital, The Catholic University of Korea, 222 Banpo-daero, Seocho-gu, Seoul 137-701, Korea. E-mail: [yymppark6301@hotmail.com](mailto:yymppark6301@hotmail.com).

JAAD Case Reports 2015;1:88-90.  
2352-5126

© 2015 by the American Academy of Dermatology, Inc. Published by Elsevier, Inc. This is an open access article under the CC BY-NC-ND license (<http://creativecommons.org/licenses/by-nc-nd/4.0/>).

<http://dx.doi.org/10.1016/j.jidcr.2015.02.003>



**Fig 2.** **A**, The nodule comprised 3 compartments of eccrine, fatty, and neural components in the upper, middle, and lower portions, respectively. **B**, The nodule contained a higher number of normal eccrine sweat glands and ducts **C**, Clusters of Pacinian corpuscles. (**A-C**, Hematoxylin-eosin stain; original magnifications: **A**,  $\times 40$ ; **B** and **C**,  $\times 100$ ).

variants.<sup>5</sup> The presence of these different structures proves their hamartomatous nature, which may be caused by abnormal mesenchymal-epithelial induction during the embryonic period.<sup>5</sup> The principal difference between our case and the previously described variants of eccrine hamartomatous lesions was the presence of spherical bodies that resembled Pacinian corpuscles. These structures can be seen in Pacinian neurofibromas and Pacinian corpuscle hyperplasia. Pacinian neurofibroma is a rare acral perineurioma that shows a Pacinian configuration in which cells and fibers are concentrically layered, but they do not form true Pacinian corpuscles. The onion bulb formation is noncapsulated, often poorly or incompletely differentiated, and devoid of a central nerve fiber.<sup>7</sup> Pacinian corpuscle-like structures are often embedded in the myxoid stroma, which stains positively with alcian blue.<sup>7</sup> In our case, however, the structures within the lower compartment of the nodule were composed of encapsulated corpuscles with eosinophilic central cores surrounded by 13 to 25 concentric lamellae of attenuated cells. The inner core and surrounding lamellae were immunopositive for S-100 protein, and the

outer perineurial cells stained positive for epithelial membrane antigen. Neurofilament protein reactivity highlighted the presence of axons. The presence of aggregates of small nerves was observed adjacent to the corpuscles. We consider that these features support our interpretation that this lesion contained hyperplastic Pacinian corpuscles.

Both eccrine glands and Pacinian corpuscles originate from neuroectodermal cells. During development, genetic factors or localized molecular factors can stimulate the proliferation and differentiation of specific neuroectodermal cells.<sup>8</sup>

Lipomatous hamartomas, including lipofibromatous hamartomas and nevus lipomatosus superficialis (NLS), can be considered for the middle portion of the lesion. Indeed, lipofibromatous hamartomas are commonly associated with neural components.<sup>9</sup> Some cases of NLS associated with epithelial components, for example, hypertrophic pilosebaceous units and folliculosebaceous units, have been reported.<sup>6</sup> Lipofibromatous hamartoma is a rare tumorlike overgrowth of fibroadipose tissue that surrounds nerves and, most commonly, the median nerve.<sup>9</sup> Histologically, perineural and endoneurial fibrosis

cause thickening of the nerve fascicles.<sup>9</sup> The inter-fascicular connective tissue is infiltrated by mature fat cells.<sup>9</sup> Unlike in lipofibromatous hamartoma, our case did not show any fibrous tissue proliferation. NLS is an uncommon cutaneous hamartoma that, histologically, comprises groups of mature fat cells located among the bundles of dermal collagen.<sup>6</sup> The current case can be differentiated from NLS because the fat cells were separated from the dermal collagen.

This case represented a very distinctive cutaneous hamartoma that comprised eccrine glands, fat tissue, and Pacinian corpuscles.

#### REFERENCES

1. Kawaoka JC, Gray J, Schappell D, Robinson-Bostom L. Eccrine nevus. *J Am Acad Dermatol*. 2004;51(2):301-304.
2. Nakatsui TC, Schloss E, Krol A, Lin AN. Eccrine angiomatous hamartoma: report of a case and literature review. *J Am Acad Dermatol*. 1999;41(1):109-111.
3. Man XY, Cai SQ, Zhang AH, Zheng M. Mucinous eccrine naevus presenting with hyperhidrosis: a case report. *Acta Derm Venereol*. 2006;86(6):554-555.
4. Al Habeeb A, Alkhalidi H, Idikio H, Ghazarian D. Cutaneous solitary neural hamartoma: report of an unusual case. *Am J Dermatopathol*. 2009;31(5):484-486.
5. Lee HW, Han SS, Kang J, et al. Multiple mucinous and lipomatous variant of eccrine angiomatous hamartoma associated with spindle cell hemangioma: a novel collision tumor? *J Cutan Pathol*. 2006;33(4):323-326.
6. Bancalari E, Martinez-Sanchez D, Tardio JC. Nevus lipomatosus superficialis with a folliculosebaceous component: report of 2 cases. *Patholog Res Int*. 2011;2011:105973.
7. Nath AK, Timshina DK, Thappa DM, Basu D. Pacinian neurofibroma: a rare neurogenic tumor. *Indian J Dermatol Venereol Leprol*. 2011;77(2):204-205.
8. Tss A, Jd P, Jt S. Chapter 30 Tumors of the epidermal appendages. In: De E, Wf L, eds. *Histopathology of the Skin*. Philadelphia, PA: Lippincott Williams&Wilkins; 2009:851.
9. Sirinoglu H, Sonmez A, Sav A, Numanoglu A. Lipofibromatous hamartoma of the median nerve. *Ann Plast Surg*. 2010;65(2):174-176.