

# The effect of intact fibula on functional outcome of reamed intramedullary interlocking nail in open and closed isolated tibial shaft fractures: A prospective study

S Muthukumar Balaji, P Madhu Chandra, Sathish Devadoss, A Devadoss

## ABSTRACT

**Background:** Isolated tibial shaft (ITS) fracture with intact fibula is a common injury but records often fail to mention it. Our primary aim was to study the effect of the intact fibula in ITS fractures in closed and open injuries and that these fractures can unite without a primary fibulectomy.

**Materials and Methods:** 56 patients who sustained an ITS fracture with an intact fibula who underwent closed or open reduction and reamed intramedullary interlocking nailing (IM IL nail) for closed and open fractures between August 2008 and April 2014 were included in this study. Four patients were lost to followup. One patient died due to causes not related to the surgery. At the time of final followup, 51 patients with 51 ITS fractures were available for the analysis. There were 33 closed and 18 open fractures. Patients were followed up at 4 weekly intervals until radiological signs of union were noted. They were assessed for functional outcome using the IOWA knee and ankle score systems at the time of final followup.

**Results:** The average time to union was 19.7 weeks. Closed fractures united in 17.7 weeks as compared to 23.5 weeks for open fractures ( $P < 0.05$ ). A delay in union occurred in 6 patients (4 open) and in 3 patients fractures failed to unite (2 open). The functional outcome as per the knee score and ankle score evaluation system was 93.13 and 92.54, respectively. The knee scores were 93.81 and 91.8 for closed and open ITS fractures, respectively ( $P > 0.05$ ). Similarly, the ankle scores were 94.96 and 88.1 for closed and open ITS fractures, respectively ( $P < 0.05$ ).

**Conclusion:** ITS fracture with intact fibula is a common occurrence, and they can be treated safely with reamed IM nailing that provides good union rates and the excellent functional result even in open fractures.

**Key words:** Fibulectomy, intact fibula, isolated tibial shaft fracture, reamed intramedullary nailing

**MeSH terms:** Fracture, bone, tibial fracture, fracture fixation, intramedullary, fibula

## INTRODUCTION

Isolated tibial shaft (ITS) fractures with intact fibula are a fairly common injury.<sup>1</sup> Hospital records often fail to mention the intact fibula in such injuries. Various forms of treatment have been described in the literature and have been associated with nonunion rates ranging from 1% to 17%.<sup>2</sup>

Primary fibulectomy has been recommended in order to overcome the adverse effect of an intact fibula accepting the additional morbidity associated with this procedure. The intact fibula is often blamed for problems related to union in these fractures. Most studies state the effect of intact fibula in closed ITS fractures only.<sup>1-4</sup> The primary aim of our study was to study the effect of the intact fibula in ITS fractures in closed and open injuries and whether these fractures can unite without a primary fibulectomy. We have studied the effect of an intact fibula on the duration of healing for closed and open isolated fractures of tibial shaft.

Department of Orthopaedics, Devadoss Multispeciality Hospital, Institute of Orthopaedic Research and Accident Surgery, Madurai, Tamil Nadu, India

**Address for correspondence:** Dr. S Muthukumar Balaji, 75/1, Devadoss Multispeciality Hospital, Algar Kovil Main Road, Surveyor Colony, Madurai - 625 007, Tamil Nadu, India. E-mail: mkbmb79@gmail.com

This is an open access article distributed under the terms of the Creative Commons Attribution-NonCommercial-ShareAlike 3.0 License, which allows others to remix, tweak, and build upon the work non-commercially, as long as the author is credited and the new creations are licensed under the identical terms.

**For reprints contact:** reprints@medknow.com

Access this article online	
Quick Response Code:	Website: www.ijoonline.com
	DOI: 10.4103/0019-5413.177584

**How to cite this article:** Balaji SM, Chandra PM, Devadoss S, Devadoss A. The effect of intact fibula on functional outcome of reamed intramedullary interlocking nail in open and closed isolated tibial shaft fractures: A prospective study. Indian J Orthop 2016;50:201-5.

## MATERIALS AND METHODS

56 patients who sustained an ITS fracture with an intact fibula who underwent closed or open reduction and reamed intramedullary interlocking nailing (IM IL nail) for closed and open fractures between August 2008 and April 2014 were included in this study. Four patients were lost to followup. One patient died due to causes not related to the surgery. At the time of final followup, 51 patients with 51 ITS fractures were available for the analysis. All patients with age below 18 and above 80 years and those who had undergone other forms of treatment such as casting, orthofix stabilization and plating were excluded from the study. Among the 51 ITS fractures, 37 occurred in isolation and 14 were part of multiple injuries. Thirty three fractures were closed and 18 were open ITS fractures. All patients were followed up at 4 weekly intervals from the time of discharge until the radiological signs of union were noted. Patients were assessed for functional outcome using the IOWA knee score and IOWA ankle score systems at the time of final followup. The IOWA knee and ankle scores as mentioned by Merchant and Deitz is a joint specific outcome.<sup>5</sup> It is based on a 100 point system and includes patient's self-assessment of pain and function as well as the data from physical examination with regard to range of motion, gait and deformity.

The information collected regarding all the selected cases were recorded in a Master Chart. Data analysis was done with the help of computer using Epidemiological Information Package (EPI 2010) developed by Centre for Disease Control, Atlanta. Using this software range, frequencies, percentages, means, standard deviations, Chi-square, *t*-test, and "*P*" values were calculated. *T*-test and ANOVA tests were used to assess the significance of difference between quantitative variables and Yates's and Fisher's Chi-square tests for qualitative variables. A *P* < 0.05 was taken to denote significant relationship.

## RESULTS

The average followup period in our study was 27.1 months (range 6-72 months) (24 months for closed fractures and 28.1 months for open fractures). The average age of patients in our study was 36.25 years (range 19-71 years). The average age of patients who sustained open ITS fractures was 30.1 ± 9.1 years and closed ITS fractures was 39.3 ± 13.5 years (*P* < 0.05). Forty patients were male and 11 were females. Thirty three patients sustained a closed fracture (64.7%) and 18 were open fractures (35.3%) [Figures 1 and 2]. Of the 51 ITS fractures, 29 occurred in right tibia (13 open fractures) and 22 patients

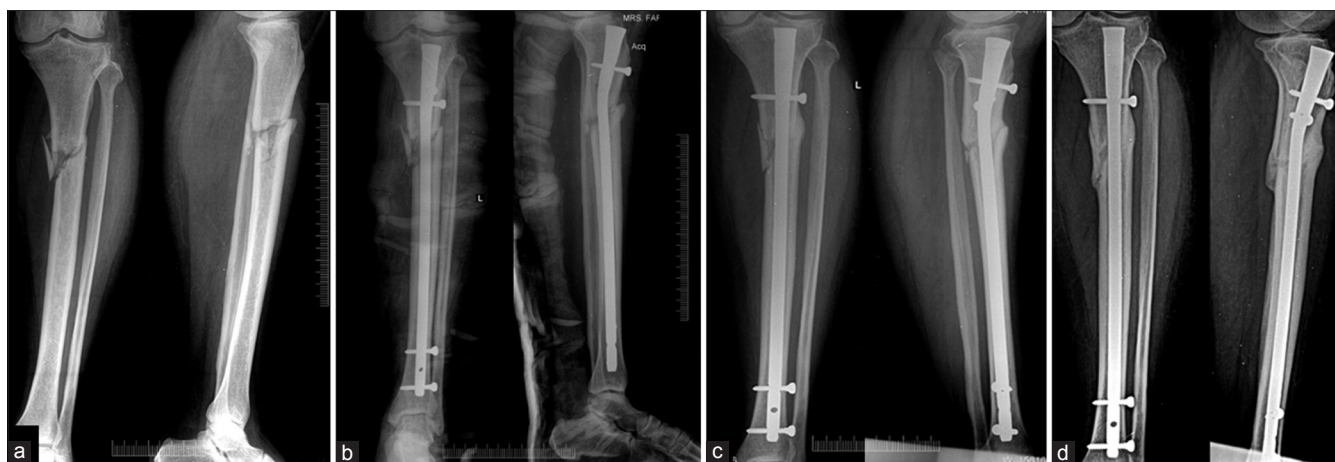sustained injury to left tibia (5 open fractures). Among the 18 open fractures included in study, 9 were type 1, 5 type 2, 2 type 3A, and 2 type 3B - Gustilo and Anderson type open fractures. Twenty nine fractures were noticed in the middle shaft (13 open), 17 occurred in distal (3 open) and 5 in the proximal shaft (2 open). The middle shaft was the most common site involved followed by the distal tibial shaft fractures. Forty five fractures were either transverse, short oblique or oblique and 6 fractures were either spiral or comminuted.

The average time to union was 19.7 weeks. Closed fractures united in 17.7 weeks as compared to 23.5 weeks in open fractures (*P* < 0.05).

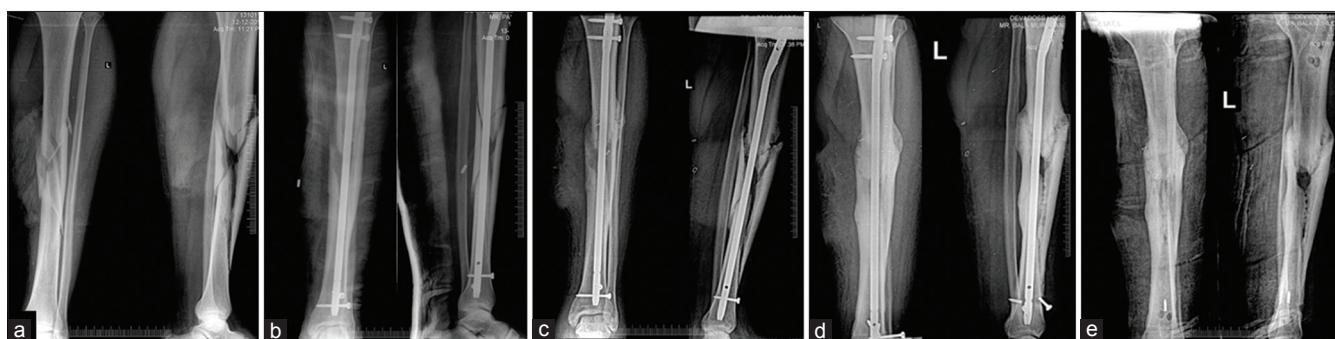
In our series, we did a reamed IM IL nailing in all the cases. Union was achieved in 42 patients (85%) at an average 19.1 weeks without any further intervention and with a good functional result. Although union-related problems occurred in 9 patients (15%; 6 delayed union, 3 nonunion), careful followup and timely intervention led to union and good functional results in all these patients irrespective of the nature of original injury.

Among the 33 closed fractures, 2 patients needed augmentation for delay in union in the form of dynamization of the IM IL nail and bone marrow injection (BMI) [Figure 3]. One patient failed to show any radiological signs of union and underwent autologous iliac crest bone graft at 16 weeks, and it eventually united at 32 weeks. One patient had superficial wound infection and was treated by debridement, vacuum dressing and antibiotics as per the culture and sensitivity report. Three patients had signs of compartment syndrome and had undergone double incision fasciotomy and delayed primary skin grafting on 3<sup>rd</sup> postoperative day. Fourteen patients had nail removal at the time of final followup as an elective procedure as a routine implant removal after fracture union.

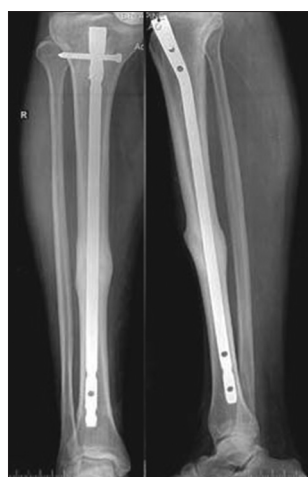All of the 18 open fractures were primarily debrided and IM IL nailing done. Five patients needed primary soft tissue procedures for closure of the wound. The average time to debridement in our series was 8 h with all patients operated within 24 h of sustaining the injury. Superficial infection occurred in 3 patients and was treated by debridement, vacuum dressing and antibiotics as per the culture and sensitivity report. One of these patients needed skin grafting, 4 patients needed augmentation for healing in the form of dynamization and BMI and 4 patients needed bone grafting for union to occur. One patient developed deep infection and was treated by implant removal, orthofix external stabilization for 6 weeks and later patellar tendon-bearing cast immobilization for 6 weeks [Figure 4]. This fracture



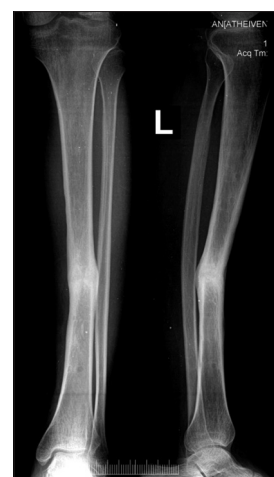**Figure 1:** A case of type 2 open isolated tibial shaft fracture treated by wound debridement and primary closure and closed reamed intramedullary interlocking nailing. X-ray anteroposterior and lateral views showing (a) fracture proximal 1/3 tibia with intact fibula (b) immediate postoperative x-ray with intramedullary nail *in situ* (c) implant in position and fracture uniting at 24 weeks followup (d) at 1 year followup showing union



**Figure 2:** A case of type IIIB open isolated tibial shaft fracture treated by wound debridement and reamed intramedullary nailing and primary wound coverage. X-ray anteroposterior and lateral views showing (a) fracture M/3 tibia comminuted with intact fibula (b) immediate postoperative x-ray showing intramedullary implant *in situ* (c) x-rays at 12 weeks followup showing fracture uniting, implant *in situ* at 12 weeks followup (d) Union at 36 weeks followup with union (e) Union and implant has been removed at 40 weeks followup



**Figure 3:** X-rays anteroposterior and lateral views of a case of closed isolated tibial shaft fracture. 18 months after distal dynamization and bone marrow injection showing solid union



**Figure 4:** X-ray anteroposterior and lateral views of a case of infected implant in open isolated tibial shaft fracture, treated by implant removal (2 months after the original injury) and orthofix stabilization for 12 weeks and later by patellar tendon bearing cast for 6 weeks at 1 year followup showing union in mild varus and posterior angulation

eventually united at the end of 28 weeks [Figure 4]. Two patients in this group had nail removal done at the time of final followup as an elective procedure as a routine implant removal after fracture union.

The functional outcome analysis as per the IOWA knee score and ankle score evaluation system in our series was



93.13 and 92.54, respectively. The IOWA knee scores were 93.81 and 91.8 for closed and open ITS fractures, respectively ( $P > 0.05$ ). Similarly, the IOWA ankle scores were 94.96 and 88.1, respectively ( $P < 0.05$ ) [Table 1].

## DISCUSSION

An intact fibula seems to interfere with the healing of ITS fracture by preventing effective compression at fracture site as one of the essential feature in the healing process is a physiological cyclical application of weight bearing forces across the fracture.<sup>2</sup> Jorgensen in their study revealed that in the presence of an intact fibula, a considerable fraction of force applied is spent in deforming the intact fibula before compressing the tibial fracture, thereby reducing the compressive force across the tibial fracture fragments.<sup>3</sup> They believed that the tibial fracture surfaces are held apart by the intact fibula. Teitz *et al.* also believed that when the fibula remains intact, a tibio fibular length discrepancy occurs and causes altered strain patterns that may lead to delayed union, nonunion, or malunion of the tibial shaft fracture.<sup>2</sup>

The nonunion rate in our series was 5% and our results are similar to other studies.<sup>1,3-5</sup>

Court-Brown *et al.* studied 14 ITS fractures and the average time for union in their study was 15.1 weeks in comparison to fractures of both bones that was 16.9 weeks ( $P < 0.05$ ).<sup>1</sup> Bone *et al.* in their study of 99 closed ITS fractures noted that fractures treated by reamed IM nailing united faster (18 weeks,  $P < 0.05$ ) than those treated by casting (26 weeks). In that study, nonunion was 10% in those treated with a cast and 2% in patients treated by reamed IM nailing.<sup>4</sup> They concluded that IM nailing is safe and provides functional results that are superior to those obtained by the use of cast in displaced closed ITS fractures. Our results were comparable to their study despite the inclusion of open fractures ( $P > 0.05$ ). Problems related to healing are more common in open ITS fractures. Keating *et al.* noted 9% nonunion in open fractures treated by reamed IM IL nailing. They found that the clinical and radiological results of nailing with reaming are similar to those of nailing without reaming.<sup>6</sup> The average time to union of open fractures in their study with reamed nail was 30 weeks and unreamed nail was 29 weeks ( $P > 0.05\%$ ). In our series, the average time to union in open fractures was 23.5 weeks ( $P < 0.05$ ) as against the closed fractures 17 weeks [Figures 1 and 2]. Keating *et al.* concluded that although reaming damages the endosteal circulation, it did not seem to have demonstrable detrimental effect on fracture union. In our series, union related problems in open fractures were similar to their study of open

fractures (11%;  $P > 0.05$ ). Delayed union is common in closed ITS fractures and this delay is augmented in open fractures and the need for a second surgery is more in the open fracture group [Table 2 and Figure 3]. The type of fracture pattern also seemed to have an effect on the union as problems did not occur in fractures that were either spiral or comminuted [Table 3] ( $P > 0.05$ ).

DeLee *et al.* recommended fibulectomy when clinical and roentgenographic signs of bone union are not progressing normally. The rationale is simple. Fracture of fibula heals in 6 weeks and an osteotomy heals in 4 weeks. Seventy seven percentage of their patients progressed to union at average of 25 weeks following fibulectomy.<sup>7,8</sup> In our study, 3 cases of nonunion were encountered (1 closed and 2 open fractures) and all cases were treated by fibulectomy, exchange nailing and autologous iliac crest bone grafting which led to fracture union [Table 2]. Thomas *et al.* in a biomechanical study on cadaveric lower limbs noted that tibial strains measured on the anteromedial and anterolateral surfaces were consistently in relative tension, indicating a posterior bending force (anterior bowing) of the tibia. After partial fibulectomy, strains on these surfaces became relatively more compressive. However, they cautioned that partial fibulectomy may not be a uniformly successful treatment method for delayed union of the tibia due to the fact that the anteromedial and anterolateral surfaces of the tibia were always in tension.<sup>9</sup>

**Table 1: Functional results using the IOWA knee and IOWA ankle scores**

Group	Knee score			Ankle score		
	Range	Mean	SD	Range	Mean	SD
Open fracture cases	84-98	91.9	3.8	62-98	88.1	10.8
Closed fracture cases	76-100	93.8	4.5	72-100	95.0	6.7
"P"	0.1315 (not significant)			0.0072 (significant)		

SD=Standard deviation

**Table 2: Second surgery requirement**

Group	Second surgery requirement		Total (%)
	Delayed union	Nonunion	
Open ITS fracture	4	2	9 (33)
Closed ITS fracture	2	1	3 (9)
"P"			0.0056 (significant)

ITS=Isolated tibial shaft

**Table 3: Type of fracture and problems related to union**

Type	Open ITS number (%)	Closed ITS number (%)	Delayed union	Nonunion
Transverse	6 (33.3)	6 (18.2)	3	2
Short oblique	6 (33.3)	16 (48.5)	1	
Oblique	4 (22.2)	7 (21.2)	2	1
Spiral	1 (5.6)	2 (6.1)	-	-
Comminuted	1 (5.6)	2 (6.1)	-	-

ITS=Isolated tibial shaft

The presence of an intact fibula does not seem to influence the incidence of infection in open ITS fractures ( $P > 0.05\%$ ) similar to earlier studies by Cannada *et al.* They noted infection rates of 1% in closed fractures, 5% in type 1, 10% in type 2 and  $>15\%$  in type 3 open fractures.<sup>6,7,10-13</sup> They recommended removal of hardware when infection is diagnosed 4 weeks after injury and addition of external fixation device for unstable fracture to eradicate the infection. If the implant is stable and soft tissue is healthy and fracture not healed, fixation may be retained. C-reactive protein may be of help when one suspects infection and provides means of determining the effectiveness of treatment.

Functional results in our series were comparable to other series.<sup>1,5,6</sup> Although knee scores were similar in both the groups, ankle scores were significantly low in open ITS fractures group ( $P < 0.05$ ) [Table 4]. The difference in the ankle scores in the two groups is statistically significant but does not have any clinical significance. The lower ankle scores in open fractures were attributed to the associated soft tissue injury in open fractures. Higher the type of open fracture, worse were the ankle scores [Figure 5]. The limitations of the study were small sample size ( $n = 18$ ) and a lack of control group.

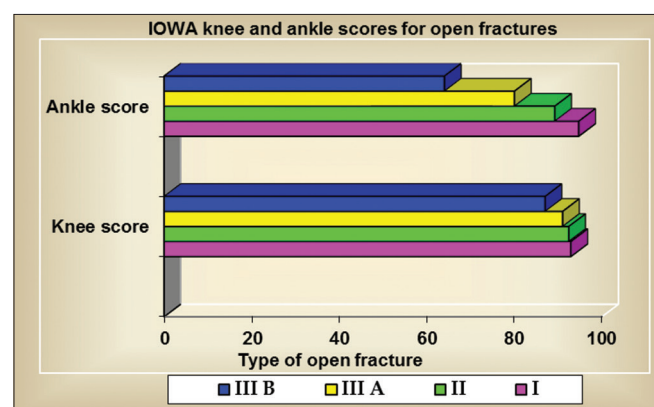
## CONCLUSION

ITS fracture with intact fibula is a common occurrence.

**Table 4: Type of open fractures and their characteristics**

Type of fractures	Number of cases		Time for union (weeks)		Knee score		Ankle score	
	n	Percentage	Mean	SD	Mean	SD	Mean	SD
I	9	50	22.8	4.9	92.9	4.4	94.7	2.8
II	5	27.8	26.8	4.8	92.4	2.6	89.2	2.3
III A	2	11.1	21.0	1.4	91.0	1.4	80.0	14.1
III B	2	11.1	21.0	4.2	87.0	1.4	64.0	2.8
"P"			0.3138	not significant	0.2534	not significant	0.0001	significant

SD=Standard deviation



**Figure 5:** A graph showing IOWA knee and ankle scores for open fractures

These fractures can be treated safely with reamed IM nailing that provides good union rates and excellent functional result even in compound fractures. Primary fibulectomy is not warranted in these injuries due to high union rates.

## Financial support and sponsorship

Nil.

## Conflicts of interest

There are no conflicts of interest.

## REFERENCES

- Court-Brown CM, Christie J, McQueen MM. Closed intramedullary tibial nailing. Its use in closed and type I open fractures. *J Bone Joint Surg Br* 1990;72:605-11.
- Teitz CC, Carter DR, Frankel VH. Problems associated with tibial fractures with intact fibulae. *J Bone Joint Surg Am* 1980;62:770-6.
- Jorgensen TE. The influence of the intact fibula on the compression of a tibial fracture or pseudoarthrosis. *Acta Orthop Scand* 1974;45:119-29.
- Bone LB, Sucato D, Stegemann PM, Rohrbacher BJ. Displaced isolated fractures of the tibial shaft treated with either a cast or intramedullary nailing. An outcome analysis of matched pairs of patients. *J Bone Joint Surg Am* 1997;79:1336-41.
- Merchant TC, Dietz FR. Longterm followup after fractures of the tibial and fibular shafts. *J Bone Joint Surg Am* 1989;71:599-606.
- Keating JF, O'Brien PJ, Blachut PA, Meek RN, Broekhuysen HM. Locking intramedullary nailing with and without reaming for open fractures of the tibial shaft. A prospective, randomized study. *J Bone Joint Surg Am* 1997;79:334-41.
- DeLee JC, Heckman JD, Lewis AG. Partial fibulectomy for ununited fractures of the tibia. *J Bone Joint Surg Am* 1981;63:1390-5.
- Butt M, Mir BA, Halwai MA, Farooq M, Dhar SA. Partial resection of fibula in the treatment of ununited tibial shaft fractures. *Indian J Orthop* 2006;40:247-9.
- Thomas KA, Harris MB, Willis MC, Lu Y, MacEwen GD. The effects of the interosseous membrane and partial fibulectomy on loading of the tibia: A biomechanical study. *Orthopedics* 1995;18:373-83.
- Cannada LK, Anglen JO, Archdeacon MT, Herscovici D Jr, Ostrum RF. Avoiding complications in the care of fractures of the tibia. *J Bone Joint Surg Am* 2008;90:1760-8.
- Gustilo RB, Anderson JT. Prevention of infection in the treatment of one thousand and twenty-five open fractures of long bones: Retrospective and prospective analyses. *J Bone Joint Surg Am* 1976;58:453-8.
- Webb LX, Bosse MJ, Castillo RC, MacKenzie EJ; LEAP Study Group. Analysis of surgeon-controlled variables in the treatment of limb-threatening type-III open tibial diaphyseal fractures. *J Bone Joint Surg Am* 2007;89:923-8.
- Cross WW 3<sup>rd</sup>, Swiontkowski MF. Treatment principles in the management of open fractures. *Indian J Orthop* 2008;42:377-86.