

Evaluation of postoperative change in lung volume in adolescent idiopathic scoliosis

Measured by computed tomography

Dong Kyu Lee, Eun Mi Chun¹, Seung Woo Suh², Jae Hyuk Yang², Sung Shine Shim³

ABSTRACT

Background: Change in total lung volume after surgical correction in adolescent idiopathic scoliosis (AIS), measured by computed tomography (CT), has not been studied previously. The primary objective of this study was to measure the change in lung volume between pre and postoperative AIS using low-dose CT and secondary objective was to investigate its relationship to postoperative pulmonary complications.

Materials and Methods: 55 AIS patients underwent surgery for correction and fusion using a posterior only approach and pedicle screws. Pre and postoperative lung volumes were measured using a 3-dimensional (3D) whole spine CT (low dose protocol: Tube current, 60 mA; tube voltage 120 kV). Postoperative low dose CT was undertaken at 4 weeks after operation to evaluate the acute changes of postoperative lung volumes and pulmonary complications. The software that was used recognizes the “air density shade” of the lung and the volume of every section of the lung. The software then automatically calculates total lung volume by summation of all section volumes. The relationships between postoperative pulmonary complications and changes in lung volume on low dose CT as well as preoperative forced vital capacity (FVC) and forced expiratory volume in 1 s (FEV₁) were calculated using logistic regression analysis.

Results: There was a decrease of 12% ± 23.2% in total lung volume postoperatively on 3D low dose CT ($P < 0.001$). Thirteen patients had increased lung volume while 42 had decreased lung volume postoperatively. Pulmonary complications were treated without severe sequale. Lung volume increased by 19.65% ± 19.84% in 13 patients and decreased by 21.85% ± 13.32% in 42 patients ($P = 0.647$). Lung volume was increased in patients whose preoperative lung volume, FEV₁ and FVC were lower than in patients whose values were higher ($r = -0.273, -0.291$ and -0.348 ; $P = 0.044, 0.045$ and 0.015 , respectively). Postoperative lung volume was also increased when intraoperative fluid administration was larger and operative time was longer ($r = 0.354, 0.417$ and $P = 0.008, 0.002$, respectively). There was a statistically significant negative correlation in the change of lung volume in female patients when compared with male patients ($r = -0.294, P = 0.03$).

Conclusion: Patients with AIS who have preoperative reduced lung volumes or lung functions can achieve further increased lung volume after surgical correction. Pulmonary complications during perioperative period were mostly treated with proper management without severe sequale. Therefore, although surgery for AIS is considered to be a high risk procedure, we can recommend to correct spine deformity in patients with severe AIS in order to improve lung function and long term prognosis.

Key words: 3-dimensional low dose computed tomography, adolescent idiopathic scoliosis, lung volume, surgical correction

MeSH terms: Tomography, computed, scoliosis, lung volume measurement

Departments of Anesthesiology and Pain Medicine, and ²Orthopedics, Scoliosis Research Institute, Korea University, Guro Hospital, ¹Department of Internal Medicine, Division of Pulmonology and Critical Care Medicine, ³Department of Radiology, Ewha Womans University, School of Medicine, Seoul, Republic of Korea

Address for correspondence: Prof. Eun Mi Chun, Department of Internal Medicine, Division of Pulmonology and Critical Care Medicine, Ewha Womans University, Mokdong Hospital, Seoul, Republic of Korea. E-mail: cem@ewha.ac.kr

Access this article online	
Quick Response Code:	Website: www.ijoonline.com
	DOI: 10.4103/0019-5413.136223

INTRODUCTION

Estimation of change in lung volume is of significant interest in studying the respiratory mechanics of scoliosis because large asymmetrical thoracic deformities often accompany spinal curvature, suggesting that the intrathoracic space may be reduced more on one side of the chest cavity than the other.¹ Differences of opinion exist regarding the relationship between severity of scoliosis and degree of pulmonary compromise. Smith *et al.*² suggested a direct relationship, while Tsiligiannis and Grivas,³ Redding *et al.*⁴ and Upadhyay *et al.*⁵ found no correlation in idiopathic curves. These studies were based on assessment of pulmonary function tests

(PFTs).^{6,7} However, most investigators generally agree that Cobb angle $>90^\circ$ frequently predisposed to respiratory impairment.⁸ A method for based volumetric reconstruction of the pulmonary system was presented by Gollogly *et al.*⁹ in 2004, allowing for individual determination of left and right lung parenchyma volumes from thoracic computed tomography (CT) scans. They used this method to establish baseline left, right and total lung volumes according to age and sex from CT scans of 1050 thoracically normal children aged 5-18 years. The children in the study underwent CT to screen for either metastases or trauma. Reduction in pulmonary capacity has been linked to severity of abnormal curvature, with reported correlations between pulmonary capacity and Cobb angle, vertebral rotation, number of vertebrae in the thoracic curve, cephalad location of the major curve and thoracic hypokyphosis.¹⁰⁻¹³

Recently, Chun *et al.* studied the effects of severity of scoliosis, degree of hypokyphosis/lordosis and rotation of apical vertebra on individual lung volume (measured by CT) in asymptomatic adolescent idiopathic scoliosis (AIS) patients.¹⁴ This CT-based program recognizes the “air density shade” of the lung and the volume of every section of the lung. The program then automatically calculates individual lung volume by summation of all section volumes. Thus, total lung volume can be measured. In asymptomatic AIS patients, they found that lung volume decreased with increased degree of curvature, rotation of apical vertebra and ratio of convex to concave side, indicating that lung volume on the concave side is comparatively more affected (decreased) than lung volume on the convex side. However, what happens to total lung volume after surgical correction and how it affects the development of pulmonary complications has not been studied. In the present study, we investigated the change in total lung volume after surgery in 55 AIS patients, measured by low dose whole spine CT. The purpose of the current study was to measure low dose CT based change in lung volume and also to determine its correlation with postoperative pulmonary complications.

MATERIALS AND METHODS

55 AIS patients underwent surgery for correction and fusion using a posterior only approach and pedicle screws between 2006 and 2008. None of the patients underwent an anterior procedure; however, thoracoplasty was performed at the apex in all patients to maintain uniformity of the study. We resected 4-5 ribs partially at the apex of the curve in thoracoplasty.

All patients had King type II or III scoliotic curves. Patients with a left-sided thoracic curve; King type I, IV, or V; or congenital scoliosis were excluded from the study. All participants gave an informed consent before the participation. This study was performed with retrospective

charts and radiography review. Low dose CT was performed to evaluate the changes of lung volume and postoperative pulmonary complications. We conducted retrospective study only with charts and radiography review. To diminish the radiation dose, we used a low-dose protocol, which is usually used to detect early lung cancer and has radiation doses one-sixth to one-tenth of the dose of a usual chest CT scan. Therefore, the risk of radiation exposure can be decreased, although, it cannot be removed completely. There were 18 male and 37 female patients with an average age of 17.9 ± 9.7 years. All patients underwent standing anteroposterior, lateral and side-bending whole-spine radiography preoperatively. In addition, they underwent standing anteroposterior and lateral whole-spine radiography postoperatively and at follow up. All patients underwent 3-dimensional (3D) low-dose whole-spine CT preoperatively and at 4 weeks postoperative.

PFTs were conducted preoperatively in all patients. For lung volume assessment, CT images of the thorax were obtained using a commercially available, 16-channel, multi detector-row scanner (Sensation 16; Siemens, Erlangen, Germany) pre and postoperatively. Images were acquired from the lung apex to the base using a low-dose protocol (tube current, 60 mA; tube voltage, 120 kV). Scanning was performed at 1.5-mm collimation and sections were obtained at 7-mm intervals (section thickness). Total lung volume was calculated by adding both lung volumes acquired by 3D image reconstruction software (RAPIDIA 2.7; INFINITT, Seoul, South Korea),¹⁵⁻¹⁷ which has a sensitivity of 94.25% with 1-mm collimation and 80% with 2.5-mm collimation.¹⁸ This program recognizes the “air density shade” of the lung and the volume of every section of the lung. It then automatically calculates total lung volume by summation of all section volumes [Figure 1]. All patients underwent the same low-dose CT at 4 weeks postoperative because, by that time, all patients were pain free and undergoing the procedure in full inspiration was easier [Figure 2]. All low-dose CT scans were performed with the same machine and volumes were calculated by a radiologist who was unaware of the purpose of the study.

Cobb angle and pelvic obliquity were measured on coronal radiographs, while thoracic kyphosis and lumbar lordosis were measured on sagittal radiographs pre and postoperatively. Peri operatively and for a postoperative period of 1 month, patients' were observed for any pulmonary complications. All patients were reviewed at the latest followup to confirm maintenance of scoliotic correction. We also measured preoperative forced expiratory volume in 1 s (FEV_1) and forced vital capacity (FVC), intraoperative blood loss and fluid administration and operative time. In usual clinical setting, the criteria of severe compromised lung function are less than 50% of

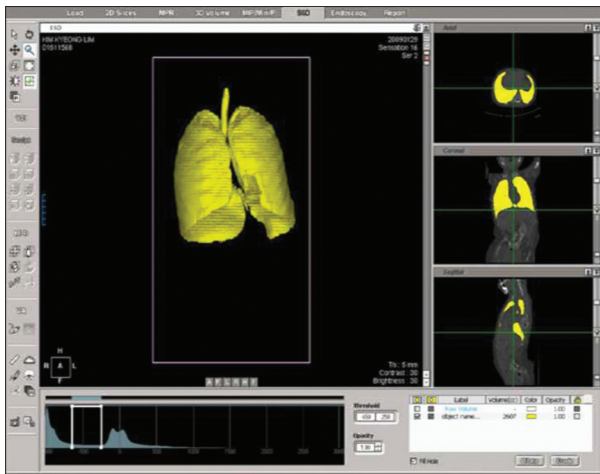

Figure 1: Preoperative measurement of total lung volume using 3-dimensional computed tomography, which automatically identifies the area of air filled spaces (shadow) and calculates total lung volume

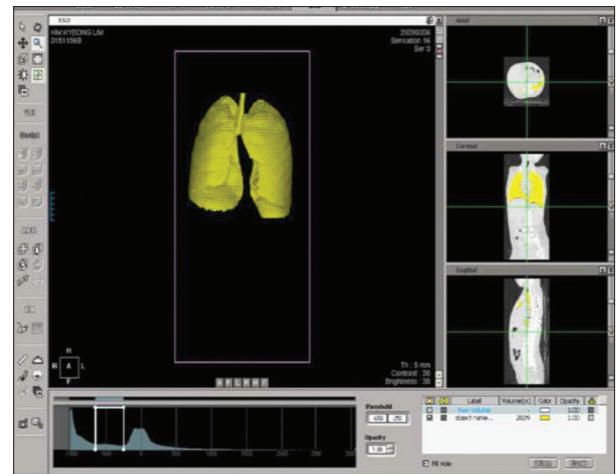


Figure 2: Postoperative measurement of total lung volume using 3-dimensional (3D) computed tomography (CT). It is important to note that implant *in situ* does not interfere with 3D CT based measurement

FEV₁ and FVC. We define preoperative poorer lung function as less than 60% of FEV₁ and FVC. We divided the patients into two groups by the change of lung volume.

Statistical analysis

From the data available, the change in lung volume was calculated in percentage between pre and postoperative (4 weeks) status. Relationships between parameters were calculated using a logistic regression curve. All parameters were compared with postoperative pulmonary complications using Spearman’s correlation coefficient test. All statistical analyses were performed using SPSS version 15 software (IBM Corporation, Armonk, NY).

RESULTS

The average pre and postoperative Cobb angles were 66.9° ± 23.9° (range, 40-152°) and 13.5° ± 13.3° (range, 1-68°), respectively and the average pre and postoperative pelvic obliquities were 3.8° ± 6.6° (range, 0-23°) and 2.4° ± 2.7° (range, 0-13°), respectively. There was significant improvement in both the Cobb angle (*P* < 0.001) and the pelvic obliquity (*P* = 0.005). There was no statistically significant correlation between high degree Cobb angle (>90°) and the change in lung volume. However, there was statistically significant correlation between the change of Cobb angle after deformity correction and the change in lung volume (*r* = 0.943, *P* = 0.005). Similarly, thoracic kyphosis and lumbar lordosis improved from 44.0° ± 23.2° and -8.6° ± 43.1° preoperatively to 28.0° ± 15.1° and -27.7° ± 25.8° postoperatively, respectively. There was significant change in both thoracic kyphosis (*P* < 0.001) and lumbar lordosis (*P* = 0.008), suggesting correction in sagittal balance. Interestingly, the average pre and postoperative lung volumes were 2443.3 ± 827 mL and 2097.7 ± 781.6 mL, respectively, suggesting a decrease of 12 ± 23.2% postoperatively (*P* < 0.001) [Table 1].

Table 1: Demographic data, pre and postoperative radiographic values and measured lung volume

Variables	Values
Age, year	17.96±9.79
Sex, male/female, n	18/37
Weight, kg	45.99±13.24
Height, m	1.53±0.14
No. of instrumentation levels	12.09±2.79
Intraoperative blood loss,* mL/kg	56.03±45.59
Intraoperative fluid administration,* mL/kg	201.84±116.38
Operation time, min (%)	298.40±100.03
FVC	68.29±18.23
FEV ₁	65.92±16.59

	Preoperative	Postoperative	<i>P</i> value [‡]
Lung volume,† mL	2443.27±826.98	2097.73±781.57	<0.001 [§]
Cobb angle (°)	66.91±23.87	13.51±13.31	<0.001 [§]
Pelvic obliquity (°)	3.84±6.60	2.38±2.71	0.050 [§]
Thoracic kyphosis (°)	44.02±23.21	28.00±15.12	<0.001 [§]
Lumbar lordosis (°)	-8.63±43.06	-27.74±25.78	0.008 [§]

Values are expressed as mean±SD. *Corrected for body weight, †Measured using CT, ‡Calculated using the paired *t* test, §Statistically significant. FEV₁=Forced expiratory volume in 1 s, FVC=Forced vital capacity, SD=Standard deviation, CT=Computed tomography. *P*<0.05 was taken as statistically significant

Thirteen patients had increased lung volume while 42 had decreased lung volume postoperatively. Lung volume increased 19.6% ± 19.8% in 13 patients and decreased 21.8% ± 13.3% in 42 patients (*P* = 0.647). The 13 patients who had increased lung volume had significantly lower preoperative FEV₁ and FVC compared with the other 42 patients (*P* < 0.05). Other preoperative radiographic parameters in the 13 patients were more severely affected than those in the 42 patients whose lung volume decreased postoperatively; however, the *P* values were not significant [Table 2]. Postoperative lung volume was increased in patients whose preoperative lung volume, FEV₁ and FVC were lower than in patients whose values were higher

($r = -0.273$, -0.291 and -0.348 ; $P = 0.044$, 0.045 and 0.015 , respectively). Postoperative lung volume was also increased when intraoperative fluid administration was larger and operative time was longer ($r = 0.354$, 0.417 and $P = 0.008$, 0.002 , respectively). There was a negative correlation with the change of postoperative lung volume in female patients when compared to male patients ($r = -0.294$, $P = 0.03$). Male patients had further increased lung volume postoperatively than female patients. Although, preoperative PCO_2 had no statistically significant correlation with postoperative lung volume, patients with preoperative high PCO_2 had increased lung volume postoperatively ($r = 0.277$, $P = 0.073$) [Table 3]. Pulmonary complications included pleural effusion, atelectasis, pneumothorax, edema and 2 cases of mild pneumonia. Most pulmonary complications were treated without severe sequelae. Preoperative FVC had little correlation with postoperative lung complications ($r^2 = 0.24$, $P = 0.113$). However, the development of postoperative lung complications was significantly correlated with change in lung volume in mL ($r^2 = 0.60$, $P < 0.001$) and change in lung volume in % ($r^2 = 0.63$, $P < 0.001$); indicating that increased change in lung volume after surgery was significantly indicative of postoperative pulmonary complications regardless of preoperative lung function [Table 4].

DISCUSSION

Our study revealed that after surgical correction in AIS, patients with poor preoperative lung function had increased lung volume after 1 month of surgery when compared to patients with better preoperative lung function. Lung volume is negatively correlated with scoliosis deformity in the coronal plane and with lordotic deformity in the sagittal plane.¹⁹ Nash and Nevins,²⁰ Ogilvie and Schendel²¹ suggested that severe degree of scoliosis affects the size and dimension of the thoracic cage and hence, decreases pulmonary function. In more than 90° of curvature, lung volume is severely affected, doubling the likelihood of early death from cor pulmonale.^{22,23} However, this correlation was determined using spirometrically evaluated lung function, except in the study by Gollogly *et al.*²² The present study is the first to compare the change in lung volume using 3D low dose CT with the risk of postoperative pulmonary complications in AIS patients. The data derived by CT is more reliable than that by PFT because the results by PFT are less accurate as it depends on the degree of cooperation by the patient. Low dose CT has advantage to decrease the radiation hazard from one-sixth to one-tenth compared to a usual chest CT and this CT is adjustable for followup radiological images. Therefore, we believe that this method can be useful in other types of scoliosis, such as congenital or neuromuscular scoliosis.

Table 2: Comparison of groups according to postoperative change in total lung volume

Variables	Decrease in lung volume	Increase in lung volume	P value
No. of patients	42	13	-
Sex, male/female, n	10/32	8/5	0.011**
Change in lung volume [†] , %	21.85±13.32	19.65±19.84	0.647
No. of instrumentation levels	12.12±2.93	12.00±2.38	0.895
Intraoperative blood loss, mL/kg	2272.62±1315.30	2438.46±1838.72	0.576
Intraoperative fluid administration, mL/kg	185.44±99.079	254.83±153.04	0.060
Operation time, min (%)	282.57±73.86	349.54±150.59	0.144
FVC	71.11±17.69	57.60±17.00	0.036 [‡]
FEV ₁	68.68±15.89	55.40±15.64	0.023 [‡]
Preoperative Cobb angle (°)	65.40±23.49	71.77±25.37	0.406
Preoperative pelvic obliquity (°)	3.81±7.26	3.92±3.99	0.957
Preoperative thoracic kyphosis (°)	43.37±23.16	45.92±24.20	0.736
Preoperative lumbar lordosis (°)	-7.62±41.83	-11.75±48.51	0.776
Pulmonary complications, %	73.80	69.20	0.746
Severe pulmonary complications, %	66.70	69.20	0.863

Values are expressed as mean±SD. *Calculated using the Chi-square test, †Percentage of decreased or increased lung volume, respectively, ‡Statistically significant. FEV₁=Forced expiratory volume in 1 s; FVC=Forced vital capacity, SD=Standard deviation. $P < 0.05$ was taken as statistically significant

Table 3: Correlation coefficients of postoperative change in lung volume

Variables	Correlation coefficient	P value
Age	-0.069	0.618
Sex*	-0.294	0.03 [†]
Weight	-0.109	0.426
Height	-0.078	0.571
Preoperative lung volume	-0.273	0.044
Intraoperative fluid administration	0.354	0.008 [†]
Operation time	0.417	0.002 [†]
FVC	-0.291	0.045 [†]
FEV ₁	-0.348	0.015 [†]
PO ₂	-0.217	0.163
PCO ₂	0.277	0.073
Preoperative Cobb angle	0.13	0.344
Preoperative pelvic obliquity	0.08	0.564
Preoperative thoracic kyphosis	0.035	0.806
Preoperative lumbar lordosis	-0.011	0.939
Corrected Cobb angle	0.054	0.695
Corrected pelvic obliquity	0.008	0.955
Corrected thoracic kyphosis	0.016	0.913
Corrected lumbar lordosis	-0.064	0.665

*Analyzed with nonparametric correlation analysis under the assumption of male sex as the indicator (i.e., female sex produces negative correlation with change in lung volume, compared with male sex). †Statistically significant. FEV₁=Forced expiratory volume in 1 s, FVC=Forced vital capacity, PCO₂=Partial pressure of carbon dioxide, PO₂=Partial pressure of oxygen

Yuan *et al.*²⁴ noted that immediately after surgery, the PFT value decreased by up to 60% of the baseline value. In

Table 4: Correlation coefficients of radiographic and computed tomographic parameters

Spearman correlation	r ² *	P value
Preoperative Cobb angle	0.08	0.564
Preoperative pelvic obliquity	-0.02	0.88
Preoperative thoracic kyphosis	-0.001	0.992
Preoperative lumbar lordosis	0.017	0.908
Preoperative lung volume	0.101	0.462
Postoperative lung volume	-0.26	0.052
Change in lung volume	0.60†	0.0001†
% change in lung volume	0.63†	0.0001†
Preoperative FVC	0.24	0.113

*Suggestive of strength of correlation, †Statistically significant. FVC=Forced vital capacity

addition, they stated that the PFT value would return to baseline by 1 or 2 months postoperatively. In our study, lung CT was taken 1 month later postoperatively so that patients could breathe to the level of their baseline lung functions without pain. In a previous adult study, thoracic and upper abdominal surgery reduced the lung volume and flow rate by 50-75% of preoperative baseline values.²⁵ In our study, postoperative lung volumes were also decreased in three-fourth cases at 4 weeks postoperatively. In our study, we found that there was statistically significant reduction of 12.04% ± 23.21% in the lung volume postoperatively. This result may be explained by the fact that postoperative pulmonary complications such as pleural effusion, atelectasis, edema, pneumonia etc., postoperatively generally decrease postoperative lung volumes. Several previous studies reported that pulmonary function (FEV₁ and FVC) recovered to approximately 5% to 10% higher than preoperative level at 12 months after surgery.²⁶⁻²⁸ Therefore, we expect that the reduced lung volume seen in our study may be improved after scoliotic correction and we are collecting data to evaluate the postoperative lung functions with same patients after 12 months later postoperatively. Theoretically, most patients are expected to have increased lung volume after correction of deformity; however, only one fourth of patients had increased lung volume and three fourth had decreased lung volume after surgical correction. But interestingly, 13 patients who had increased lung volume had significantly lower preoperative lung volume, FEV₁ and FVC compared with than those in the 42 patients whose lung volume decreased postoperatively ($P < 0.05$). There was statistically no significant correlation between Cobb angle more than 90° and change of lung volumes. However, there was a strong correlation between the change of pre and post Cobb angle and the change in lung volumes ($r = 0.943$, $P = 0.005$). So the postoperative lung volume gains from surgical correction were higher in patients who had poorer lung function and significantly reduced lung volume preoperatively. From our study, we may suggest that the patients who have preoperative lower lung volumes or lung functions can achieve increased lung volume. In addition,

the patients who required a large amount of intraoperative fluid administration and longer operative time had increased postoperative lung volumes. These findings imply that more severely affected patients who require high technical operation skills can get more advantages from surgical correction. Patients with preoperative higher PCO₂ also had increased lung volume after surgical correction, although there was no statistical significance. The AIS patients whose preoperative lung volumes and lung functions are slightly decreased have courses similar to subjects who have normal lung functions after surgical correction. Therefore, their lung volumes usually decrease after surgical correction in the short. On the contrary, severely affected AIS patients have more suppressed lung volume due to spine deformities and may achieve increased lung volumes, enough to overcome the phenomenon of postoperative decreased lung volume. We acknowledge that there were some limitations in this study. The first is that there are no guidelines on when or how to measure lung volume on 3D low-dose CT. We measured lung volumes at 4 weeks postoperative to evaluate the acute changes of lung volume and postoperative pulmonary complications, by this time, patients were almost pain free and there would be little interference with the respiratory efforts. To avoid the bias regarding radiological examinations, patients underwent CT using the same machine and one radiologist without any information on the study, measured the lung volume in all patients. 3D low dose CT which we used for present study was not an advanced model but during the study time (2006-2008), this was the CT scan available in our hospital. Another limitation is that the present study was a retrospective research without postoperative PFTs. Hence we could not explain clearly the change of postoperative lung function according to the change of postoperative lung volume. But this limitation can be compensated by the fact that patients with AIS mostly have healthy lungs without any component of severe chronic obstructive lung pattern, so generally lung function increases as lung volume increases. This means that the lung volumes of patients with AIS would be relatively well correlated with lung functions. Hence, we may accept that increased lung volume can be matched with improved lung function. Therefore long term more than 6 months and prospective follow up study for lung volumes and lung functions after surgical correction of AIS will be needed to evaluate long term and accurate results.

Our study showed that the patients with AIS who have preoperative lower lung volumes or more decreased lung functions can achieve higher lung volumes after surgical correction. This result may be evidence that curative surgical correction will bring more hopeful results postoperatively in more severe AIS patients who have decreased preoperative lung functions and volumes. Although AIS surgery is considered a high risk procedure, we can recommend to

correct spine deformity in AIS in order to improve lung function and long term prognosis. In our study, there was no postoperative PFT; therefore, future studies including a prospectively large number of patients, postoperative PFT and CT at a longer followup of more than 6 months are needed to obtain more accurate data.

REFERENCES

- Jones RS, Kennedy JD, Hasham F, Owen R, Taylor JF. Mechanical inefficiency of the thoracic cage in scoliosis. *Thorax* 1981;36:456-61.
- Smith J, King T, Weber B, Cole J, Briscoe W, Levine D. Lung function in idiopathic scoliosis: Adolescence to old age. *J Bone Joint Surg Am* 1974;56-A: 440.
- Tsiligiannis T, Grivas T. Pulmonary function in children with idiopathic scoliosis. *Scoliosis* 2012;7:7.
- Redding G, Song K, Inscore S, Effmann E, Campbell R. Lung function asymmetry in children with congenital and infantile scoliosis. *Spine J* 2008;8:639-44.
- Upadhyay SS, Ho EK, Gunawardene WM, Leong JC, Hsu LC. Changes in residual volume relative to vital capacity and total lung capacity after arthrodesis of the spine in patients who have adolescent idiopathic scoliosis. *J Bone Joint Surg Am* 1993;75:46-52.
- Holbert JM, Brown ML, Scirba FC, Keenan RJ, Landreneau RJ, Holzer AD. Changes in lung volume and volume of emphysema after unilateral lung reduction surgery: Analysis with CT lung densitometry. *Radiology* 1996;201:793-7.
- Kauczor HU, Heussel CP, Fischer B, Klamm R, Mildenerger P, Thelen M. Assessment of lung volumes using helical CT at inspiration and expiration: Comparison with pulmonary function tests. *AJR Am J Roentgenol* 1998;171:1091-5.
- Koumbourlis AC. Scoliosis and the respiratory system. *Paediatr Respir Rev* 2006;7:152-60.
- Gollogly S, Smith JT, White SK, Firth S, White K. The volume of lung parenchyma as a function of age: A review of 1050 normal CT scans of the chest with three-dimensional volumetric reconstruction of the pulmonary system. *Spine (Phila Pa 1976)* 2004;29:2061-6.
- Kearon C, Viviani GR, Kirkley A, Killian KJ. Factors determining pulmonary function in adolescent idiopathic thoracic scoliosis. *Am Rev Respir Dis* 1993;148:288-94.
- Upadhyay SS, Mullaji AB, Luk KD, Leong JC. Relation of spinal and thoracic cage deformities and their flexibilities with altered pulmonary functions in adolescent idiopathic scoliosis. *Spine (Phila Pa 1976)* 1995;20:2415-20.
- Lin MC, Liaw MY, Chen WJ, Cheng PT, Wong AM, Chiou WK. Pulmonary function and spinal characteristics: Their relationships in persons with idiopathic and postpoliomyelitic scoliosis. *Arch Phys Med Rehabil* 2001;82:335-41.
- Newton PO, Faro FD, Gollogly S, Betz RR, Lenke LG, Lowe TG. Results of preoperative pulmonary function testing of adolescents with idiopathic scoliosis. A study of six hundred and thirty-one patients. *J Bone Joint Surg Am* 2005;87:1937-46.
- Chun EM, Suh SW, Modi HN, Kang EY, Hong SJ, Song HR. The change in ratio of convex and concave lung volume in adolescent idiopathic scoliosis: A 3D CT scan based cross sectional study of effect of severity of curve on convex and concave lung volumes in 99 cases. *Eur Spine J* 2008;17:224-9.
- Chung JW, Yoon CJ, Jung SI, Kim HC, Lee W, Kim YI, *et al.* Acute iliofemoral deep vein thrombosis: Evaluation of underlying anatomic abnormalities by spiral CT venography. *J Vasc Interv Radiol* 2004;15:249-56.
- Lee W, Kim HS, Kim SJ, Kim HH, Chung JW, Kang HS, *et al.* CT arthrography and virtual arthroscopy in the diagnosis of the anterior cruciate ligament and meniscal abnormalities of the knee joint. *Korean J Radiol* 2004;5:47-54.
- Wood KB, Schendel MJ, Dekutoski MB, Boachie-Adjei O, Heithoff KH. Thoracic volume changes in scoliosis surgery. *Spine (Phila Pa 1976)* 1996;21:718-23.
- Won HJ, Choi BI, Kim SH, Kim YI, Youn BJ, Han JK. Protocol optimization of multidetector computed tomography colonography using pig colonic phantoms. *Invest Radiol* 2005;40:27-32.
- Aaro S, Ohlund C. Scoliosis and pulmonary function. *Spine (Phila Pa 1976)* 1984;9:220-2.
- Nash C, Nevins K. A lateral hook at pulmonary functions in scoliosis. *J Bone Joint Surg Am* 1974;56-A: 440.
- Ogilvie JW, Schendel MJ. Calculated thoracic volume as related to parameters of scoliosis correction. *Spine (Phila Pa 1976)* 1988;13:39-42.
- Gollogly S, Smith JT, Campbell RM. Determining lung volume with three-dimensional reconstructions of CT scan data: A pilot study to evaluate the effects of expansion thoracoplasty on children with severe spinal deformities. *J Pediatr Orthop* 2004;24:323-8.
- Lonstein J, Bradford D, Winter R, Ogilvie J. Natural history of spinal deformity. In: Moe's Textbook of Scoliosis and Other Spinal Deformities. 3rd ed. Philadelphia, PA: WB Saunders Company; 1995. p. 87-93.
- Yuan N, Fraire JA, Margetis MM, Skaggs DL, Tolo VT, Keens TG. The effect of scoliosis surgery on lung function in the immediate postoperative period. *Spine (Phila Pa 1976)* 2005;30:2182-5.
- Lin HY, Nash CL, Herndon CH, Andersen NB. The effect of corrective surgery on pulmonary function in scoliosis. *J Bone Joint Surg Am* 1974;56:1173-9.
- Izatt MT, Harvey JR, Adam CJ, Fender D, Labrom RD, Askin GN. Recovery of pulmonary function following endoscopic anterior scoliosis correction: Evaluation at 3, 6, 12, and 24 months after surgery. *Spine (Phila Pa 1976)* 2006;31:2469-77.
- Gagnon S, Jodoin A, Martin R. Pulmonary function test study and after spinal fusion in young idiopathic scoliosis. *Spine (Phila Pa 1976)* 1989;14:486-90.
- Lenke LG, Bridwell KH, Baldus C, Blanke K. Analysis of pulmonary function and axis rotation in adolescent and young adult idiopathic scoliosis patients treated with Cotrel-Dubousset instrumentation. *J Spinal Disord* 1992;5:16-25.

How to cite this article: Lee DK, Chun EM, Suh SW, Yang JH, Shim SS. Evaluation of postoperative change in lung volume in adolescent idiopathic scoliosis Measured by computed tomography. *Indian J Orthop* 2014;48:360-5.

Source of Support: Nil, **Conflict of Interest:** None.