

# Botulinum Toxin A as an Adjunct to Abdominal Wall Reconstruction for Incisional Hernia

Sinor Soltanizadeh, MS\*†  
 Frederik Helgstrand, MD,  
 DMSc†  
 Lars N. Jorgensen, MD, DMSc\*

**Background:** Repair of large incisional hernias remains a surgical and costly challenge. Temporary paralysis of the lateral abdominal wall muscles with topical administration of botulinum toxin A (BTA) is a new therapeutic concept, which may obviate the need for component separation technique (CST) for repair of large incisional hernias. Current literature on the administration of BTA as adjunct to surgical repair of abdominal incisional hernias was investigated.

**Methods:** The electronic databases PubMed and Embase were searched for eligible studies. Two independent investigators evaluated the literature. Data were sought regarding primary fascial closure with and without CST, safety, hernia recurrence, method of application, and preoperative radiological imaging.

**Results:** Six cohort studies including a total of 133 patients receiving BTA were identified. No randomized or case-control studies were found. In total, 83.5% of the patients achieved primary fascial closure. Supplemental CST was necessary in 24.1% of the patients. Two patients developed hernia recurrence during follow-up. No postoperative complications or adverse events were considered related to the administration of BTA, except for impairment of postoperative coughing and sneezing. Additionally, radiological imaging showed that BTA increased the length of lateral abdominal muscles before surgery.

**Conclusions:** Preoperative administration of BTA increases muscle length and may facilitate primary fascial closure. Optimal administration is at least 2 weeks before repair, whereas the optimal dose of BTA remains to be defined. Carefully designed randomized controlled trials are warranted to identify patients who would benefit from BTA and to eliminate the confounding effect of CST. (*Plast Reconstr Surg Glob Open* 2017;5:e1358; doi: 10.1097/GOX.0000000000001358; Published online 21 June 2017.)

## INTRODUCTION

Surgical repair of incisional ventral hernias is associated with considerable postoperative morbidity, risk of hernia recurrence, and costs.<sup>1,2</sup> Reconstruction of ventral defects with primary fascial closure is suggested to lead to lower rates of hernia recurrences.<sup>3</sup> To facilitate closure of the hernia defect, Ramirez et al.<sup>4</sup> developed the components separation technique (CST), which implies a complete bilateral division of the abdominal external oblique aponeuroses allowing medialization of the rectus

abdominis muscles. The traditional Ramirez technique is associated with large dissection surfaces as huge lipocutaneous skin flaps are raised, and the rate of wound morbidity is considerable due to the invasiveness of the technique.<sup>5</sup> Minimally invasive CST has been described as a promising concept for reduction of the rate of wound-associated complications.<sup>6</sup> However, recurrence rates after CST combined with mesh insertion for repair of giant incisional hernias are still 4–32%.<sup>7</sup> Iatrogenic deep muscle injury under CST is suggested to additionally result in lateral abdominal weakness, predisposing the patient to lateral herniation.<sup>8</sup> A pharmacological safe, temporary, and reversible alternative to CST rather than a surgical permanent division of aponeurotic tissue would thus seem clinically attractive.

The lateral abdominal muscles (external abdominal oblique, internal abdominal oblique, and transversus abdominis) partly insert through the rectus sheath in the linea alba. Muscle contractions by the lateral abdominal

From the \*Digestive Disease Center, Bispebjerg Hospital, University of Copenhagen, Copenhagen NV, Denmark; and †Department of Surgery, Zealand University Hospital, Køge, Denmark.

Received for publication March 1, 2017; accepted April 17, 2017.

Copyright © 2017 The Authors. Published by Wolters Kluwer Health, Inc. on behalf of The American Society of Plastic Surgeons. This is an open-access article distributed under the terms of the Creative Commons Attribution-Non Commercial-No Derivatives License 4.0 (CCBY-NC-ND), where it is permissible to download and share the work provided it is properly cited. The work cannot be changed in any way or used commercially without permission from the journal.

DOI: 10.1097/GOX.0000000000001358

**Disclosure:** The authors have no financial interest to declare in relation to the content of this article. The Article Processing Charge was paid for by the authors.

muscles exert a lateral force vector on this tendinous tissue, which is the reason why insufficient healing of a midline wound may result in hernia progression, and recreation of the midline may become challenging for the surgeon.

Botulinum toxin A (BTA) is a neurotoxic protein produced by *Clostridium botulinum*. BTA binds to glycoproteins in the cholinergic nerve terminal, blocking signal transmission temporarily in both motoric and autonomic innervations. The toxin has an advantageous safety profile when applied in small doses to local tissue remote from vital muscles and organs. The paralyzing effect reaches a maximum 2 weeks after topical administration and declines gradually after 2.5 months.<sup>9</sup>

Animal studies have shown that preoperative paralysis of the lateral abdominal muscles from intramuscular administration of BTA reduces the intraabdominal pressure,<sup>10</sup> allowing closure of a hernia defect under less muscular tension.<sup>11</sup> Ideally, temporary paralysis of the abdominal wall muscles with BTA prior to hernia repair may allow primary fascial closure without the need for CST.

This systematic review investigates the current clinical evidence for administration of BTA as an adjunct to surgical repair of abdominal incisional hernias in terms of efficacy, safety, and long-term results. Additionally, results of radiological imaging and application methods will be addressed.

## METHODS

### Eligibility Criteria

The study questions were conducted according to the population, intervention, comparison, outcome criteria.<sup>12</sup> The study population was patients undergoing incisional hernia repair. The intervention was administration of BTA as an adjunct to surgical hernia repair. If possible, a comparison was undertaken between the intervention group and a control group within the study. The primary outcome was the efficacy of BTA in relation to abdominal repair, and secondary outcomes were safety and long-term results.

### Search and Sources

The search was conducted in PubMed and Embase in July 2016. All types of published human clinical studies were included. Publication language was limited to English, Spanish, and Scandinavian. These databases were subject to a similar search strategy with the following string:

("Botulinum Toxins, Type A"[Mesh] OR "Clostridium botulinum type A"[Mesh] OR "Botulinum Toxins"[Mesh] OR bta OR btx OR btxa OR onabotulinum OR onabotulinumtoxin OR onabotulinumtoxina OR botox OR botulinum OR "chemical components separation") AND ("Hernia"[Mesh] OR "Incisional Hernia"[Mesh] OR "Hernia, Umbilical"[Mesh] OR "Hernia, Ventral"[Mesh] OR "Hernia, Abdominal"[Mesh] OR "abdominal defect" OR "abdominal defects" OR hernia OR hernias OR herniation).

### Study Selection and Extraction of Data

Articles were identified, screened, reported, and included in accordance with the Preferred Reporting Items for Systematic Reviews and Meta-Analysis guidelines<sup>13</sup> (Fig. 1). Two investigators (S.S. and F.H.) independently screened all records based on title and abstract, and potentially relevant papers were then full-text screened for inclusion. Studies suspected of repeatedly reporting on the same patient population were discussed with the authors. Only the most recent publication was included, if patients were reported on in more than 1 publication (Fig. 1). Two investigators (S.S. and F.H.) reviewed reference lists of primary articles for relevant additional papers based on their title.

Demographic data of the included study populations are presented in Table 1. The primary outcome was the rate of primary fascial closure. The secondary outcomes were safety and long-term results. The following data were extracted from the included studies: preoperative transverse diameter of the hernia defect, timing of BTA administration before repair and the need for supplemental CST, adverse events related to BTA, postoperative complications, follow-up time, hernia recurrence, and mortality (Tables 2 and 3). Furthermore, radiological data were sought to compare defect measures before and after the preoperative administration of BTA. Authors of reference publications were contacted to obtain missing data.

### Evaluation of Evidence

The quality of evidence of the included cohort studies was determined according to the Scottish Intercollegiate Guidelines Network,<sup>14</sup> a validated methodology checklist for evaluation of the risk of bias according to selection, assessment, confounding, and statistical analysis. CST performed as an adjunct procedure was considered a confounder for the operative hernia closure rate, rendering a study vulnerable to a high risk of bias. Additionally, follow-up time could affect the reporting of hernia recurrence, as studies of short follow-up times underestimate the recurrence rate, exposing studies for lead-time bias.<sup>15</sup>

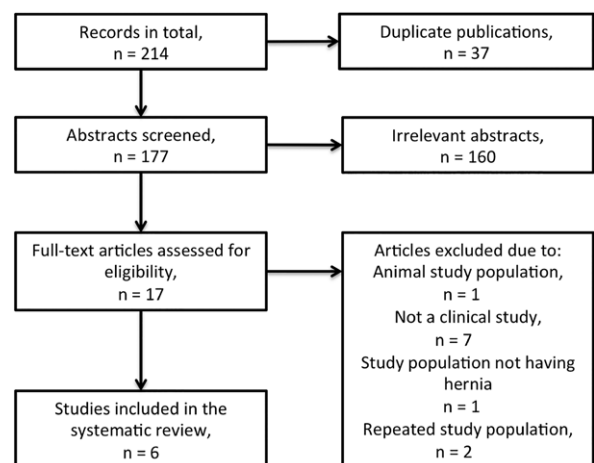


Fig. 1. Flow diagram outlining selection of studies.

**Table 1. Study Characteristics**

Study	Country	Year	Study Design	N	Mean Age (y) (SD or Range)	Sex (M:F)	No. Previous Repairs	Total Dose of BTA	Surgical Technique
Elstner et al. <sup>16</sup>	Australia	2016	Prospective	32	58 (36–84)	17:15	1–7	300 U	Laparoscopic or laparoscopic-assisted open with mesh
Zendejas et al. <sup>17*</sup>	United States	2013	Retrospective	22	62 (11)	13:9	Mean of 1.7	300 U	Open or laparoscopic with mesh
López et al. <sup>18</sup>	Mexico	2015	Retrospective	36	52 (19–84)	15:21	—	100 U‡	Rives-Stoppa, mesh technique or simple closure
Ibarra-Hurtado et al. <sup>19</sup>	Mexico	2013	Prospective	17	35 (12)	17:0	0	500 U	Rives-Stoppa mesh technique or simple closure
Ibarra-Hurtado et al. <sup>20</sup>	Mexico	2009	Prospective	12	34 (13)	12:0	—	500 U	Simple closure
Cháves-Tostado et al. <sup>21</sup>	Mexico	2014	Retrospective	14	58	5:9	4 Patients had previous repairs	100 U	Onlay, retromuscular, underlay or sandwich mesh technique
Total				133		79:54			

— Signifies not reported.

\*Compared with a control group of 66 undergoing hernia repair without BTA.

‡Received from author.

**Table 2. Efficacy of BTA**

Study	Mean Transverse Defect Size, cm (SD or Range)	Timing of BTA Administration Before Repair	Primary Fascial Closure (%)	Primary Fascial Closure Rate without CST (%)	Primary Fascial Closure Rate with CST (%)
Elstner et al. <sup>16</sup>	12.3 (5–24)	1–4 wk	32 (100)	26 (81.3)	6 (18.7)
Zendejas et al. <sup>17</sup>	*	Median 6 d	9 (40.9)	5 (22.7)	4 (18.2)
López et al. <sup>18</sup>	(10–15)	4 wk	31 (86.1)	27 (75.0)	4 (11.1)
Ibarra-Hurtado et al. <sup>19</sup>	14.7 (2.18)	4 wk	17 (100)	8 (47.1)	9 (52.9)
Ibarra-Hurtado et al. <sup>20</sup>	13.9 (1.49)	4 wk	12 (100)	6 (50.0)	6 (50.0)
Cháves-Tostado et al. <sup>21</sup>	17.6 (7.35)	Mean 40 d	10 (71.4)	7 (50.0)	3 (21.4)
Calculated total			111 (83.5)	79 (59.4)	32 (24.1)

\*Transverse defect size not reported, mean defect size was 59.7 cm<sup>2</sup>.

**Table 3. Safety and Long-Term Results**

Study	Mean Follow-Up Time (mo)	Adverse Events Related to Administration of BTA	Complications Related to Surgery	n	Mortality During Follow-Up	Recurrence, n
Elstner et al. <sup>16</sup>	19.0	Abdominal distension, impaired coughing, and sneezing	—	0	0	0
Zendejas et al. <sup>17</sup>	15.6	None	Wound related	2	0	2
			Other	7		
López et al. <sup>18</sup>	18.0	Abdominal distension	Wound related	8	0	0
			Other	1		
Ibarra-Hurtado et al. <sup>19</sup>	49.0	None	Wound related	7	0	0
Ibarra-Hurtado et al. <sup>20</sup>	7.3	None	Wound related	2	0	0
Cháves-Tostado et al. <sup>21</sup>	15.0	—	Wound related	2	0	0
			Other	2		
Total					0	2
Wound				21		
Other				10		

Wound-related complications included seromas, enterocutaneous fistulas, hematomas, and surgical-site infections. Other complications included cardiovascular, urologic, and gastrointestinal events.

## RESULTS

The search strategy identified a total of 214 articles (Fig. 1). We excluded 37 articles due to duplicate publications across databases and 160 articles based on an irrelevant abstract. Additional 11 articles were excluded after full-text review, as they did not meet the eligibility criteria or repeatedly reported on the same study population. Six papers thus remained for further investigation.<sup>16–21</sup>

### BTA Application

BTA was administered through 3<sup>16,17</sup> or 5<sup>18–21</sup> injection sites on each side of the abdomen. The administered total

doses were 100 U<sup>18,21</sup>, 300 U<sup>16,17</sup>, and 500 U<sup>19,20</sup>. Four studies reported that BTA was diluted with 0.9% saline before administration to the following final concentrations: 2 U/ml<sup>16,17</sup>, 50 U/ml<sup>21</sup>, or 100 U/ml<sup>19</sup>. The BTA dilution was then divided into 6<sup>16,17</sup> to 10<sup>18–21</sup> equal doses. Ultrasonographic<sup>16,17</sup> or electromyographic<sup>19–21</sup> guidance allowed identification of the 3 muscle layers (external abdominal oblique, internal abdominal oblique, and transversus abdominis) at the 3<sup>16,17</sup> to 5<sup>18–21</sup> planned injection sites on each side of the abdomen. The BTA dilution was equally administered into each of the 3 muscle layers at each injection site, resulting in a total of 9<sup>16,17</sup> to 15<sup>18–21</sup> distri-

butions on each side of the abdomen. A total of 133 patients had undergone administration of BTA<sup>16–21</sup> followed by incisional hernia repair ranging from 6 days<sup>17</sup> to more than 4 weeks later.<sup>16,18–21</sup> (Table 2). Figure 2 illustrates the technique of BTA injection under ultrasonographic guidance as described by Zendejas et al.<sup>17</sup> None of the studies reported on the logistics of the procedure and who performed the injections.

### Efficacy

The transverse mean defect size of the fascial defects ranged from 12.3 to 17.6 cm. Primary fascial closure was achieved in 79 patients (59.4%) without the need for adjunctive CST. Supplementary CST was required in 32 patients (24.1%) for facilitation of fascial closure (Table 2), resulting in a total of 111 patients (83.5%) achieving successful primary fascial closure.

Elstner et al.<sup>16</sup> reported 32 patients, of which 23 and 9 patients presented with midline and lateral hernia defects, respectively. A total dose of 300 U of BTA was applied 1–4 weeks before scheduled laparoscopic or laparoscopic-assisted open hernia repair with mesh implantation. A total of 26 patients (81%) achieved primary fascial closure with the application of BTA, whereas 6 patients (19%) required additional unilateral or bilateral endoscopic CST with division of the external oblique.

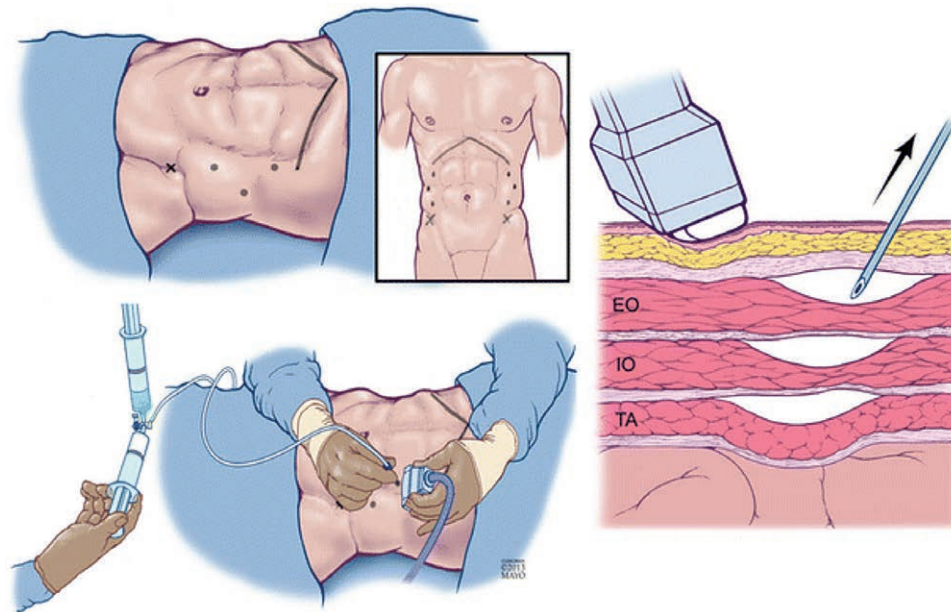
Zendejas et al.<sup>17</sup> administered BTA (total dose of 300 U) in 22 patients a median of 6 days (range, 1–19 days) before hernia mesh repair and matched them with a control group of 66 patients based on age, sex, body mass index, history of hernia recurrence, and type of repair. There were no significant differences in patient demographics including the hernia grade between the 2 groups. All but one patient in the intervention group presented with a

midline defect. In total, successful fascial closure was achieved in 9 patients (41%) in the BTA group and 24 patients (36%) in the control group ( $P = 0.3$ ). Five patients (8%) in the control group and 4 patients (18%) in the BTA group additionally required CST ( $P = 0.2$ ), resulting in a 23% primary fascial closure rate exclusively with the administration of BTA.

López et al.<sup>18</sup> reported 36 patients undergoing BTA (total dose of 100 U) 4 weeks before repair of large ventral hernia defects of unknown location ranging between 10 and 15 cm in transverse size. Surgical repairs were performed with retromuscular mesh repair, Sandwich-technique, or simple closure with onlay mesh. Primary fascial closure was obtained in 27 patients (75%) without CST as an adjunct procedure. Five and 4 patients required sack plicature and supplemental CST, respectively, resulting in a total of 31 (86%) achieving primary fascial closure.

Ibarra-Hurtado et al.<sup>19,20</sup> published 2 studies including a total of 29 patients with midline defects who received a total dose of 500 U BTA 4 weeks before the hernia repair. Surgical repair was done with retromuscular mesh repair or simple suture closure without mesh. Successful primary fascial closure was achieved in all patients. However, 15 patients (53%<sup>19</sup> and 50%<sup>20</sup>) required additional CST for abdominal closure.

Chávez-Tostado et al.<sup>21</sup> reported 14 patients receiving a total of 100 U BTA, 40 days (mean) before hernia repair with onlay, retromuscular, underlay, or sandwich mesh technique. In this study, 10 and 4 patients presented with midline and lateral defects, respectively. Primary fascial closure was obtained in 7 patients without the requirement of CST. Four and 3 patients underwent sack plicature and CST, respectively. Thus primary fascial closure was achieved in 10 patients (64%).



**Fig. 2.** Application of botulinum toxin A. EO, the external abdominal oblique muscle; IO, the internal abdominal oblique muscle; TA, the transversus abdominis muscle. Reproduced from by Zendejas et al: "Outcomes of chemical component paralysis using botulinum toxin for incisional hernia repairs" *World J Surg.* 2013;37:2830–2837 with permission from Springer.



### Safety and Long-Term Results

Adverse events after administration of BTA were reported in 2 studies. Some patients experienced weaker sneezing and coughing or abdominal distension, which was diagnosed subjectively.<sup>16,18</sup> However, no patients developed pulmonary complications. Major complications such as surgical site occurrences were considered unrelated to the preoperative administration of BTA. The mean follow-up across studies ranged from a mean of 7–49 months (Table 3). In the study by Zendejas et al.<sup>17</sup>, 2 patients (9%) in the BTA group and 6 patients (9%) in matched control group were reported with hernia recurrence after a mean follow-up of 15.6 and 18.4 months. The incidences of both any-type of complications and surgical site complications were found comparable between the groups (40% versus 28%,  $P = 0.29$ ; and 9% versus 14%,  $P = 0.72$ , respectively).

### Radiological Assessments

The effect of BTA administration was evaluated by radiological examinations in 4 studies with computed tomography.<sup>16,19–21</sup>

Elstner et al.<sup>16</sup> compared CT scans from before BTA administration with preoperative post-BTA scans and described a transverse hernia defect reduction up to 58% with the administration of 300 U. Similarly, both studies by Ibarra-Hurtado et al.<sup>19,20</sup> showed significant reductions of the transverse hernia defect (mean decrease, 4.79 cm; 95% confidence interval [CI], 3.63–6.31;  $P < 0.001$  and 5.25 cm; 95% CI, 3.59–6.91;  $P < 0.001$ ) secondary to administrations of 500 U of BTA. In a comparable study, administration of 100 U of BTA resulted in a small and statistically nonsignificant transverse reduction of the hernia defect after 4 weeks.<sup>21</sup>

The length and thickness of the 3 lateral abdominal muscle layers were also compared before and after BTA administration in 2 studies.<sup>16,19</sup> In the study by Elstner et al.<sup>16</sup>, a bilateral significant 4 cm mean increase (95% CI, 3.38–4.60;  $P < 0.0001$ ) of the lateral abdominal muscle length was observed. Similarly, Ibarra-Hurtado et al.<sup>19</sup> reported a significant 2.4–2.6 cm elongation of the lateral muscles,  $P < 0.001$ . Additionally, a mean reduction of 1.0 cm muscle thickness was observed ( $P < 0.001$ ).

### Level of Study Evidence

Only 1 study compared the results of the intervention group with a matched control group.<sup>17</sup> However, controls were not matched according to hernia size, which was only available for 9 patients in the BTA and 39 patients in the control group. This may lead to a low-quality score according to the Scottish Intercollegiate Guidelines Network methodology<sup>14</sup> as hernia size has a confounding effect on the primary fascial closure rate. The rest of the included studies had a single cohort design equivalent with low-to-acceptable quality.<sup>16,18–21</sup> All studies but one<sup>19</sup> were exposed to lead-time bias, and Elstner et al.<sup>16</sup> declared a conflict of interest directly related to the submitted work. However, this was considered to have no effect on the reported results.

## DISCUSSION

Although only few studies on the administration of BTA prior to incisional hernia repair have been published so far, both safety of the procedure and the primary fascial closure rate appeared high irrespective of hernia location. However, CST was needed in one-third of the patients as an adjunct to the preoperative BTA administration,<sup>16,19,20</sup> which might overestimate the effect of BTA.

The current literature has sufficiently described methodological aspects of the BTA administration, whereas details were lacking on logistics including and who performed the procedures. Future studies should report all necessary steps of the BTA application, and international consensus on the procedure should be achieved through standard operating procedures.

In this review, it was not possible to predict which patients would require additional CST, as only 1 study reported on a threshold for the indication of CST (> 18 cm transverse hernia diameter).<sup>16</sup> All patients presented with incisional hernias exceeding 10 cm in transverse fascial defect size. There were few details regarding patient demography and hernia classification, which is a critical aspect concerning the reported results. Therefore, it was not possible to determine the appropriate indication for using BTA as an adjunct to the hernia repair. Furthermore, the included literature was heterogenic and did not compare differences in results between surgical techniques, making conclusions on type of operation impossible. A satisfactory clinical effect from preoperative BTA administration might be limited to patients with a certain hernia size and type, but due to the lack of a control group in most of the currently published studies, the prognostic patient characteristics are unknown.

The relatively high rate of patients who required supplementary CST to obtain a satisfactory hernia repair raises the question if administration of BTA and adjuvant CST result in a synergetic effect. A higher abdominal compliance following BTA administration was suggested by the radiological demonstration of flaccid paralysis of all the lateral abdominal muscles. An anterior CST implies division of the external oblique aponeurosis, leaving the internal oblique and transversus abdominis muscles intact. After BTA administration, these muscles elongate allowing primary midline closure for complex cases. Alternatively, the synergetic effect of BTA and CST may be limited if administration of BTA primarily affects the released muscles. There are multiple techniques for CST: open traditional anterior, minimally invasive anterior (open perforator sparing or endoscopic), or transversus abdominis release. However, information regarding the techniques for CST in the current literature was scarce, precluding a clear interpretation of the presented results. Thus, the potential clinical gain from combining BTA with CST still needs to be scientifically documented.

Timing and dose were essential factors for reaching an optimal effect of BTA. Administration of BTA a median of 6 days before hernia repair failed to improve clinical results as compared with a control group without BTA.<sup>17</sup> According to earlier evidence, it takes at least 2 weeks be-

fore the paralyzing effect reaches a maximum.<sup>9</sup> Most studies achieved significant relaxation with 300–500 U of BTA. Only 100 U were applied in 2 studies resulting in conflicting results.<sup>18,21</sup> Thus, the optimal total dose of BTA is still unclear, but seems to be at least 300 U.

The lateral abdominal muscles are also involved in the accessory respiration, and concern has been raised as to the effect of BTA on postoperative respiratory function.<sup>17</sup> Two studies observed BTA-related weakness in accessory abdominal muscle function, as patients experienced weakness of coughing and sneezing.<sup>16,18</sup> This suggests that caution should be exercised administering BTA to patients with chronic respiratory dysfunction.

The most common postoperative complications of incisional hernia repairs were surgical-site occurrences including seroma, enterocutaneous fistula, hematoma, and surgical-site infection. These complications were in 2 studies reported as related to the surgical technique rather than the administration of BTA.<sup>19,20</sup> Ventral hernia repairs with open CST are complex due to the wide subcutaneous dissection needed to raise huge skin flaps, which may jeopardize skin perfusion. Thus, randomized controlled studies are highly warranted to confirm if surgical repair with BTA decreases the risk of postoperative complications as compared with CST.

The evidence concerning the efficacy of BTA was considered weak, as the literature was based on small population sizes as well as heterogeneity concerning study design, surgical procedures, and methods of BTA application. Given the low rate of reported hernia recurrences, one may expect that the flaccid effect caused by BTA throughout 2.5 months allowed the surgical incision to heal with minimal tension, reducing the risk of hernia recurrence. However, due to the large subset of patients undergoing CST, these results might be biased. Additionally, the length of follow-up was insufficient for a proper evaluation of hernia recurrence except for 1 study.<sup>19</sup>

Pharmacological paralysis of the lateral abdominal muscles appears promising as a supplementary preoperative method to achieve primary fascial closure in repair of large ventral hernias. At present, safety, efficacy, and feasibility of BTA cannot be fully evaluated due to lack of controlled data and limited details regarding indications and contraindications. Before BTA therapy becomes more widespread as a preoperative therapy, comparative cohort data on indication, application techniques, dosing, efficacy, safety, and costs are required. This review sets up the stage for large randomized studies comparing preoperative BTA with and without CST to provide conclusive evidence for a formal guideline.

Sinor Soltanizadeh, MS

Center for Surgical Science  
Zealand University Hospital  
Lykkebaekvej 1  
DK-4600 Koege  
Denmark  
E-mail: sinor\_soltani@hotmail.com

## REFERENCES

- Gillion JF, Sanders D, Miserez M, et al. The economic burden of incisional ventral hernia repair: a multicentric cost analysis. *Hernia*. 2016;20:819–830.

- Ecker BL, Kuo LE, Simmons KD, et al. Laparoscopic versus open ventral hernia repair: longitudinal outcomes and cost analysis using statewide claims data. *Surg Endosc*. 2016;30:906–915.
- Nguyen DH, Nguyen MT, Askenasy EP, et al. Primary fascial closure with laparoscopic ventral hernia repair: systematic review. *World J Surg*. 2014;38:3097–3104.
- Ramirez OM, Ruas E, Dellon AL. “Components separation” method for closure of abdominal-wall defects: an anatomic and clinical study. *Plast Reconstr Surg*. 1990;86:519–526.
- Switzer NJ, Dykstra MA, Gill RS, et al. Endoscopic versus open component separation: systematic review and meta-analysis. *Surg Endosc*. 2015;29:787–795.
- Ghali S, Turza KC, Baumann DP, et al. Minimally invasive component separation results in fewer wound-healing complications than open component separation for large ventral hernia repairs. *J Am Coll Surg*. 2012;214:981–989.
- Eriksson A, Rosenberg J, Bisgaard T. Surgical treatment for giant incisional hernia: a qualitative systematic review. *Hernia*. 2014;18:31–38.
- Clarke JM. Incisional hernia repair by fascial component separation: results in 128 cases and evolution of technique. *Am J Surg*. 2010;200:2–8.
- Dressler D. Clinical applications of botulinum toxin. *Curr Opin Microbiol*. 2012;15:325–336.
- Cakmak M, Caglayan F, Somuncu S, et al. Effect of paralysis of the abdominal wall muscles by botulinum A toxin to intraabdominal pressure: an experimental study. *J Pediatr Surg*. 2006;41:821–825.
- Rodríguez-Ruiz G, Cruz-Zárate A, Oña-Ortiz FM, et al. Chemical components separation (botulinum toxin A) in the planned ventral hernia repair: a mice model [in Spanish]. *Rev Hispanoam Hernia*. 2015;3:139–146.
- O'Connor D, Green S, Higgins JPT. Chapter 5: Defining the review question and developing criteria for including studies. In: Higgins JPT, Green S, eds. *Cochrane Handbook of Systematic Reviews of Intervention*. Version 5.1.0. London, United Kingdom: The Cochrane Collaboration; 2011.
- Moher D, Liberati A, Tetzlaff J, et al.; PRISMA Group. Preferred reporting items for systematic reviews and meta-analyses: the PRISMA statement. *Int J Surg*. 2010;8:336–341.
- Scottish Intercollegiate Guidelines Network (SIGN), ed. *SIGN 50: A Guideline Developer's Handbook*. Edinburgh, Scotland: SIGN; 2015.
- Fink C, Baumann P, Wente MN, et al. Incisional hernia rate 3 years after midline laparotomy. *Br J Surg*. 2014;101:51–54.
- Elstner KE, Read JW, Rodríguez-Acevedo O, et al. Preoperative chemical component relaxation using botulinum toxin a: enabling laparoscopic repair of complex ventral hernia [published online June 28 2016]. *Surg Endosc*. 2016.
- Zendejas B, Khasawneh MA, Svantstyan B, et al. Outcomes of chemical component paralysis using botulinum toxin for incisional hernia repairs. *World J Surg*. 2013;37:2830–2837.
- López AH, Rubalcava EJV. Botulinum toxin type a infiltration in the preoperative preparation of hernias with 10–15 cm defects [in Spanish]. *Rev Hispanoam Hernia*. 2016;4:43–49.
- Ibarra-Hurtado TR, Nuño-Guzmán CM, Miranda-Díaz AG, et al. Effect of botulinum toxin type A in lateral abdominal wall muscles thickness and length of patients with midline incisional hernia secondary to open abdomen management. *Hernia*. 2014;18:647–652.
- Ibarra-Hurtado TR, Nuño-Guzmán CM, Echeagaray-Herrera JE, et al. Use of botulinum toxin type a before abdominal wall hernia reconstruction. *World J Surg*. 2009;33:2553–2556.
- Chávez-Tostado KV, Cárdenas-Lailson LE, Pérez-Trigos H. Results of preoperative application of botulinum toxin type a in treatment of giant incisional hernias [in Spanish]. *Rev Hispanoam Hernia*. 2014;2:145–151.