



Access this article online

Quick Response Code:



Website:

www.turkjemergmed.org

DOI:

10.4103/2452-2473.290063

Prolongation of QT interval due to hydroxychloroquine overdose used in COVID-19 treatment

Gökhan Aksel^{1*}, Mehmet Muzaffer Islam¹, Tuncay Aslan¹, Serkan Emre Eroglu¹

¹Department of Emergency Medicine, University of Health Sciences, Ümraniye Training and Research Hospital, Istanbul, Turkey

*Corresponding author

Abstract:

Hydroxychloroquine is one of the most commonly used drugs in COVID-19 treatment. In this case report, we aimed to present a young patient whose QT interval was prolonged due to hydroxychloroquine overdose which was given for COVID-19 treatment. This is the first reported case of QT interval prolongation at a low dose of 1.600 mg in the literature. A 28-year-old male patient was admitted to the emergency department with the complaints of nausea, diarrhea, and weakness. The patient was diagnosed with COVID-19 a day prior and home isolation was recommended with hydroxychloroquine and oseltamivir P. O. treatment. His complaints started 6 h after accidentally taking 1.600 mg of hydroxychloroquine P. O. at the same time. On physical examination, the Glasgow Coma Scale was 15, and neurological, respiratory, and abdominal examinations were normal. His pulse was 54 beats/min, oxygen saturation was 99%, arterial blood pressure was 122/82 mmHg, and fever was 36.5°C. Electrocardiography (ECG) showed sinus bradycardia and corrected QT interval was calculated as 510 ms. The QT interval prolongation and bradycardia persisted, and the patient was hospitalized for follow-up and treatment. He was discharged on the 3rd day of his hospitalization after the corrected QT interval was detected to be 420 ms and his bradycardia improved. Due to the potential cardiac side effects, patients who are sent to home isolation with treatment should be educated about the use, dosage, and possible side effects of this medicine, and serial ECG monitoring should be provided to patients who are hospitalized.

Keywords:

2019 novel coronavirus infection, coronaviruses, COVID-19, COVID-19 pandemic, COVID-19 virus disease, COVID-19 virus infection, SARS-CoV-2 infection

Submitted: 23-04-2020

Revised: 19-05-2020

Accepted: 01-06-2020

Published: 18-07-2020

ORCID:

GA: 0000-0002-5580-3201

MMI: 0000-0001-6928-2307

TA: 0000-0003-0418-8373

SEE: 0000-0002-3183-3713

Address for correspondence:

Gökhan Aksel, M. D,
Ümraniye Eğitim Ve
Arastırma Hastanesi, Acil
Tıp Kliniği, Elmalikent
Mahallesi Adem Yavuz
Cad. No: 1 Ümraniye,
Istanbul, Turkey.
E-mail: aksel@
gokhanaksel.com

Introduction

In December 2019, cases presented with atypical pneumonia, which did not respond to antibiotherapy, fever, cough, acute respiratory failure, and a typical radiological pulmonary infiltration, began to appear in Wuhan, China.^[1] Subsequently, it was understood that a previously noninfectious strain of the Coronaviridae family was responsible for these cases,

the virus was isolated, and the genome structure was identified and was named as 2019 novel coronavirus which is also known as COVID-19 and SARS-CoV-2.^[2] The World Health Organization has declared a pandemic on December 3, 2020, for COVID-19 that spread to the world quite rapidly.^[3]

Although many treatment options for COVID-19 have been theoretically defined and clinical trials are still ongoing, there are not any fully effective drugs defined in the treatment of this disease yet.^[4] However,

This is an open access journal, and articles are distributed under the terms of the Creative Commons Attribution-NonCommercial-ShareAlike 4.0 License, which allows others to remix, tweak, and build upon the work non-commercially, as long as appropriate credit is given and the new creations are licensed under the identical terms.

How to cite this article: Aksel G, Islam MM, Aslan T, Eroglu SE. Prolongation of QT interval due to hydroxychloroquine overdose used in COVID-19 treatment. Turk J Emerg Med 2020;20:149-51.

For reprints contact: reprints@medknow.com

due to its potential benefits, some medications that are previously used in the treatment of various diseases in humans are being used in the treatment of these patients worldwide despite the possible side effects and predicted to be effective against COVID-19. Hydroxychloroquine is one of the most commonly used drugs in COVID-19 treatment. In this case report, it aimed to present a young patient who was diagnosed with COVID-19 and was sent home for isolation by giving hydroxychloroquine treatment whose QT interval was prolonged due to overdose after accidentally receiving 1,600 mg of hydroxychloroquine. Although this case is not the first in the literature for hydroxychloroquine intoxication, it is the first case with prolonged QT interval due to COVID-19-related hydroxychloroquine overdose. In addition, while the previously reported intoxication cases were due to a much higher dose of hydroxychloroquine intake, a relatively low dose of intoxication in this case is noteworthy.

Case Report

A 28-year-old male patient was admitted to the emergency department with the complaints of nausea, diarrhea, and weakness that started 12 h ago. The patient, who had no known chronic disease, was diagnosed with COVID-19 a day prior. Home isolation was recommended by giving hydroxychloroquine 2 × 200 mg P. O. and oseltamivir 2 × 75 mg P. O. for 5 days. When the patient's detailed history was taken, it was learned that the patient's complaints started 6 h after accidentally taking 1.600 mg of hydroxychloroquine at the same time as a result of misunderstanding about how to use the medication. The Glasgow Coma Scale was 15, and neurological, respiratory, and abdominal examinations were normal. His pulse was 54 beats/min, oxygen saturation was 99%, arterial blood pressure was 122/82 mmHg, fever was 36.5°C, electrocardiography (ECG) showed sinus bradycardia, and corrected QT interval was calculated as 510 ms [Figure 1]. Although complete blood count, liver and kidney function tests, C-reactive protein, and

blood electrolytes were normal in blood samples, 20 mEq potassium chloride was given intravenously with 500cc 0.9% isotonic sodium chloride as a liquid electrolyte supplement to the patient with prolonged QT interval in 2 h because blood potassium level was 3.2 mEq/L. The QT interval prolongation and bradycardia persisted, and the patient was hospitalized for follow-up and treatment due to the risk of sudden cardiac death and malign arrhythmias. Hydroxychloroquine was discontinued and treatment with oseltamivir 2 × 75 mg P. O. was continued to be given. The patient was discharged on the 3rd day of his hospitalization after the corrected QT interval was detected to be 420 ms [Figure 2] and his bradycardia improved. The patient gave written consent to publish his case and clinical images.

Discussion

Chloroquine and its derivative, hydroxychloroquine, have previously been shown to have antiviral activity in animal models for avian flu (H5N1) and in human studies for HIV.^[5,6] It has also been shown to successfully inhibit COVID-19 in *in vitro* experiments.^[7] However, current clinical trials of hydroxychloroquine indicate that this medication does not cause a significant difference compared to standard treatment for mortality, oxygen support requirement, frequency of acute respiratory distress, and negative conversion of SARS-CoV-2. However, patients treated with hydroxychloroquine were reported to have significantly more frequent side effects, including cardiac arrest.^[8-10]

As the Centers for Disease Control and Prevention (CDC) similarly suggested, Turkish Ministry of Health recommended hydroxychloroquine treatment (200 mg twice daily) in its national COVID-19 guideline as it was promising in the early stages of the pandemic, and this proposal is still up-to-date despite the publications against hydroxychloroquine. As studies against hydroxychloroquine came out, CDC updated their current recommendations, especially against high-dose

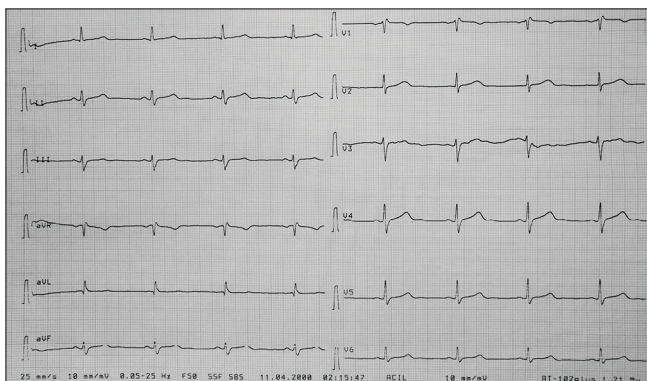


Figure 1: Electrocardiography of the patient when admitted to the emergency department for the first time: QT interval was calculated as 510 ms

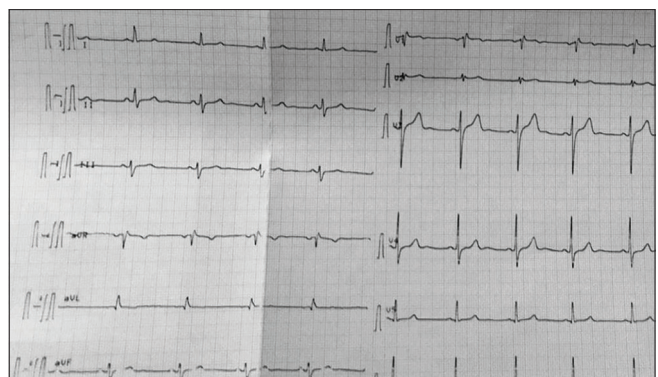


Figure 2: Electrocardiography of the patient on the 3rd day of his hospitalization: QT interval was calculated as 420 ms

use (600 mg twice daily).^[11,12] We already know that hydroxychloroquine has a wide profile of side effects. Cardiac side effects associated with hydroxychloroquine are QRS interval prolongation, torsades de pointes, and QT interval prolongation which has generally been reported in acute intoxications or chronic overdoses.^[13-15] To our knowledge, there is not a reported case of prolonged QT interval because of hydroxychloroquine use or overdose due to COVID-19 treatment.

The therapeutic, toxic, and lethal dose reported for chloroquine in the literature is 10 mg/kg, 20 mg/kg, and 30 mg/kg, respectively; however, no clear fatal dose threshold has been reported for hydroxychloroquine yet. In the case series, cardiac arrhythmias were reported between 4000 mg and 20,000 mg and death at 12,000 mg intake.^[16] Although the total dose taken was 1,600 mg in our case and this dose is well below the reported doses, prolonged QT interval and bradycardia were observed. This is also the first reported case of QT interval prolongation at a low dose of 1.600 mg in the literature.

Conclusion

Health-care providers and patients should be alert for possible side effects of hydroxychloroquine, which is now used quite frequently in COVID-19 pandemic. Patients recommended for treatment in home isolation should be educated about the use, dosage, and possible side effects of this medicine. Serial ECG monitoring should be performed in patients who are admitted to the hospital due to drug-related QT interval prolongation and other cardiac side effects.

Consent to participate

The authors certify that they have obtained all appropriate patient consent forms. The patient gave written consent to publish his/her case and clinical images. The patient understand that name and initials will not be published and due efforts will be made to conceal identity, but anonymity cannot be guaranteed.

Funding

None declared.

Conflicts of interest

None declared.

Author Contribution Statement

GA, MMI, TA, SEE conceived and designed the experiments, GA and MMI analyzed and interpreted the data, GA, MMI, TA and SSE

contributed analysis tools or data, GA and MMI drafted the manuscript All authors approved the final submitted version of the manuscript.

References

1. Lake MA. What we know so far: COVID-19 current clinical knowledge and research. *Clin Med (Lond)* 2020;20:124-7.
2. Zhu N, Zhang D, Wang W, Li X, Yang B, Song J, et al. A novel coronavirus from patients with pneumonia in China, 2019. *N Engl J Med* 2020;382:727-33.
3. Available from: <http://www.euro.who.int/en/health-topics/health-emergencies/coronavirus-covid-19/news/news/2020/3/who-announces-covid-19-outbreak-a-pandemic>. [Last accessed on 2020 May 22].
4. Khan S, Siddique R, Shereen MA, Ali A, Liu J, Bai Q, et al. The emergence of a novel coronavirus (SARS-CoV-2), their biology and therapeutic options. *J Clin Microbiol* 2020. pii: JCM.00187-20. doi: 10.1128/JCM.00187-20.
5. Savarino A, Di Trani L, Donatelli I, Cauda R, Cassone A. New insights into the antiviral effects of chloroquine. *Lancet Infect Dis* 2006;6:67-9.
6. Yan Y, Zou Z, Sun Y, Li X, Xu KF, Wei Y, et al. Anti-malaria drug chloroquine is highly effective in treating avian influenza A H5N1 virus infection in an animal model. *Cell Res* 2013;23:300-2.
7. Wang M, Cao R, Zhang L, Yang X, Liu J, Xu M, et al. Remdesivir and chloroquine effectively inhibit the recently emerged novel coronavirus (2019-nCoV) *in vitro*. *Cell Res* 2020;30:269-71.
8. Rosenberg ES, Dufort EM, Udo T, Wilberschied LA, Kumar J, Tesoriero J, et al. Association of treatment with hydroxychloroquine or azithromycin with in-hospital mortality in patients with COVID-19 in New York State. *JAMA* 2020. pii: e208630.
9. Tang W, Cao Z, Han M, Wang Z, Chen J, Sun W, et al. Hydroxychloroquine in patients with mainly mild to moderate coronavirus disease 2019: Open label, randomised controlled trial. *BMJ* 2020;369:m1849.
10. Mahévas M, Tran VT, Roumier M, Chabrol A, Paule R, Guillaud C, et al. Clinical efficacy of hydroxychloroquine in patients with covid-19 pneumonia who require oxygen: Observational comparative study using routine care data. *BMJ* 2020;369:m1844.
11. Turkish Ministry of Health. Available from: <https://covid19bilgi.saglik.gov.tr/depo/algorithmalar/COVID19-PLKACILHASTAYONETIMI.pdf>. [Last accessed on 2020 May 22].
12. Centers of Disease Control and Prevention, USA. Available from: <https://www.cdc.gov/coronavirus/2019-ncov/hcp/therapeutic-options.html>. [Last accessed on 2020 May 22].
13. Chen CY, Wang FL, Lin CC. Chronic hydroxychloroquine use associated with QT prolongation and refractory ventricular arrhythmia. *Clin Toxicol (Phila)* 2006;44:173-5.
14. Isbister GK, Dawson A, Whyte IM. Hydroxychloroquine overdose: A prospective case series. *Am J Emerg Med* 2002;20:377-8.
15. Radke JB, Kingery JM, Maakestad J, Krasowski MD. Diagnostic pitfalls and laboratory test interference after hydroxychloroquine intoxication: A case report. *Toxicol Rep* 2019;6:1040-6.
16. Marquardt K, Albertson TE. Treatment of hydroxychloroquine overdose. *Am J Emerg Med* 2001;19:420-4.