




Contents lists available at ScienceDirect

Acta Orthopaedica et Traumatologica Turcica

journal homepage: <https://www.elsevier.com/locate/aott>

Selection of distal fusion level in terms of distal junctional kyphosis in Scheuermann kyphosis. A comparison of 3 methods



Fatih Dikici^a, Turgut Akgul^b, Kerim Sariyilmaz^{a,*}, Murat Korkmaz^c, Okan Ozkunt^a,
Cuneyt Sar^b, Unsal Domanic^a

^a Acibadem University Atakent Hospital, Department of Orthopaedics and Traumatology, Istanbul, Turkey

^b Istanbul University, Istanbul Medical School, Department of Orthopaedics and Traumatology, Istanbul, Turkey

^c Koc University Hospital, Department of Orthopaedics and Traumatology, Istanbul, Turkey

ARTICLE INFO

Article history:

Received 11 November 2016

Received in revised form

22 November 2017

Accepted 28 November 2017

Available online 28 December 2017

Keywords:

Scheuermann kyphosis

Distal junctional kyphosis

Sagittal stable vertebra

First lordotic vertebra

Lower end vertebra

ABSTRACT

Objective: The aim of this study was to investigate the effect of distal fusion level selection on the distal junctional kyphosis (DJK) in Scheuermann kyphosis (SK) patients who underwent posterior fusion.

Methods: Thirty-nine SK patients who underwent posterior fusion with a minimum follow-up of 3 years were retrospectively evaluated. According to the distal fusion level, patients were divided into 3 groups. Group S; lowest instrumented vertebra (LIV) was the sagittal stable vertebra (SSV), Group F; LIV was the first lordotic vertebra (FLV) and, Group L; LIV was the lower end vertebra (LEV). DJK was evaluated according to distal level selection.

Results: Thoracic kyphosis (TK) decreased from 73.3° (SD ± 7.9°) to 39° (SD ± 8.7°) postoperatively, with a mean correction rate of 46% (SD ± 13) (p < 0.0001). In 11 patients, FLV and SSV was the same vertebra. In remaining 28 patients, 10 patients were in Group S, 15 patients were in Group F and 3 patients were in Group L. In Group S, none of them developed DJK, however, DJK was observed 9 of 15 patients in Group F. DJK was developed in all cases in Group L. There is a statistically higher risk for developing DJK when FLV or LEV was selected as LIV (p < 0.05).

Conclusion: Selecting SSV for the distal fusion level has been found to be effective for preventing DJK. Selecting distal fusion level proximal to SSV will increase the risk of DJK which may become symptomatic and require revision surgery.

Level of evidence: Level IV, therapeutic study.

© 2017 Turkish Association of Orthopaedics and Traumatology. Publishing services by Elsevier B.V. This is an open access article under the CC BY-NC-ND license (<http://creativecommons.org/licenses/by-nc-nd/4.0/>).

Introduction

Scheuermann kyphosis (SK) is a rigid developmental thoracic kyphosis. Although conservative treatment measures are initially applied, surgical treatment is indicated for radiological >70–75° kyphosis, clinically pain, cosmetic and neurological problems.^{1–7} Post-surgery complication rates up to 15% have been reported after surgery with an emphasis on the proximal and distal junctional problems.^{8–12} Junctional kyphosis is a common problem after SK surgery and may be related to an improper selection of fusion

levels, ligament disruption or an overcorrection of the deformity.¹³ Although the upper instrumentation level selection is clear, i.e., the upper end vertebrae of the deformity,^{9,14} the distal instrumentation level selection is controversial.

To determine the distal instrumentation level, the first lordotic vertebra (FLV) or sagittal stable vertebra (SSV) can be used.^{9–11} In the literature, the vertebra at the distal part of the first lordotic disc space was classified as the FLV, and it was reported that it can be chosen safely as the distal level.^{14–16} However, Cho et al¹⁰ noted that distal junctional problems occur when the FLV is selected and emphasized that the FLV was not always a safe choice. Thus, they developed the sagittal stable vertebra (SSV) concept, which refers to the most proximal vertebra touched by the posterior sacral vertical line (PSVL). Currently, some surgeons prefer the FLV for the distal level. However, some surgeons suggest SSV for the distal level, and there is no consensus on the distal level selection. The aim of our study was to compare the FLV and SSV for the distal

* Corresponding author. Acibadem University Atakent Hospital, Department of Orthopaedics and Traumatology, Turgut Ozal Bulvarı No: 16, 34303, Kucukcekmece, Istanbul, Turkey. Fax: +90 212 404 44 45.

E-mail address: ksariyilmaz@gmail.com (K. Sariyilmaz).

Peer review under responsibility of Turkish Association of Orthopaedics and Traumatology.

fusion level, in terms of the distal junctional kyphosis (DJK), in SK patients.

Material and method

Forty-six patients who underwent a posterior approach and pedicle screw instrumentation for SK between 1998 and 2010 with a minimum follow-up of 3 years were retrospectively evaluated. Kyphosis due to other causes such as post-trauma, tumors, infection, neuromuscular and iatrogenic kyphosis were not included. Two patients with deficient data and inappropriate X-rays, 1 patient who underwent an anterior approach, 2 patients who underwent osteotomy, 1 patient whose distal level was determined as a result of an additional coronal spinal deformity, and 1 patient with a follow up time shorter than three years were excluded from the study. Finally, 39 SK patients were included in the study. The surgeries were performed by two senior surgeons in two different centers by virtue of using the cantilever reduction and apical compression maneuvers by polyaxial pedicle screws and titanium rods. A combination of allografts and autografts harvested from facetectomies and thoracic transverse processes during screw insertion were used for posterior fusion. While taking the preoperative and last follow-up long lateral spine X-rays, patients were instructed to stand straight and relaxed, with their hips and knees fully extended. The elbows were in extension, with both forearms were resting on a horizontal bar at the level of their shoulders.

Thoracic kyphosis was measured from the upper end vertebra to the lower end vertebra of the kyphosis according to Cobb's method. For the determination of the distal fusion level, 3 methods were used. The intersection of a vertical line drawn through the posterior border of the sacrum and the first-touched vertebra proximally was classified as the sagittal stable vertebra (SSV), and the first vertebra distal to the kyphosis where the disc space turned to lordosis was identified as the first lordotic vertebra (FLV) and a line drawn along lower plate of the lowest end vertebrae of the kyphosis was the lower end vertebra (LEV) (Fig. 1). The patients were divided into 3 groups according to their distal fusion levels. In Group S, the LIV was the SSV; in Group F, the LIV was the FLV; and in Group L, the LIV was the lower end vertebra (LEV).

To evaluate the effect of sacropelvic parameters on DJK, preoperative and last follow-up sacral slope (SS), pelvic incidence (PI) and, pelvic tilt (PT) angles were measured. The PI, PT, and SS were measured as the angle between the vertical line to the upper sacral plate and the line connecting the midpoint of the sacral plate to the midpoint of the line between the center of femoral heads, the angle between the plumb line and the line connecting the midpoint of the line between the center of femoral heads, and the angle between the sacral plate and the horizontal line, respectively. Thereafter, patients were divided into 2 groups; patients who had DJK as DJK group and patient who had not DJK as non-DJK group.

Distal junctional kyphosis (DJK) was defined by a distal junctional angle greater than 10° between the caudal endplate of the lower instrumented vertebra to the caudal endplate that was one vertebra below.⁹ In the case of having no complaints or being asymptomatic, the diagnosis was classified as asymptomatic DJK.

All statistical analyses were conducted with SPSS (Statistical Package for the Social Sciences) 15.0 for Windows. Kolmogorov–Smirnov test was utilized to assess distribution of study parameters between groups which did not yield a normal distribution. Wilcoxon Sum Rank test was used for to compare the preoperative and postoperative values. Comparisons between groups created according to distal fusion level were made with the Kruskal Wallis test. Mann Whitney *U* test was used to compare the DJK and non-DJK group. $p < 0.05$ was used to indicate statistical significance.

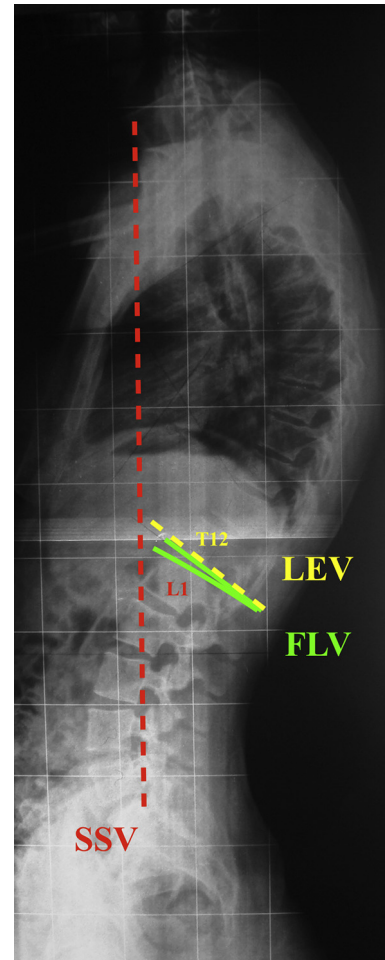


Fig. 1. The determination of the sagittal stable vertebra (SSV), first lordotic vertebra (FLV) and lower end vertebra (LEV). SSV (red dotted line) is the most proximal vertebra touched by the posterior sacral vertical line. FLV (green line) is the distal first vertebra of the kyphosis where the disc space turned to lordosis. LEV (yellow dotted line) is determined according to Cobb method. In this patient SSV and FLV is the same vertebra, which is L1 and, LEV is T12.

Results

Thirty-nine patients who had a mean follow-up of 8 ($SD \pm 3.4$) years were retrospectively evaluated. The mean age of the patients was 18.6 ($SD \pm 3.4$) years, and there were 20 males and 19 females. Preoperative and postoperative mean thoracic kyphosis were 73.3° ($SD \pm 7.9^\circ$) and 39° ($SD \pm 8.7^\circ$), respectively. The correction rate was 46% ($SD \pm 13$), and this was statistically significant ($p < 0.0001$).

When the lateral X-rays at the final follow-up were evaluated, the FLV and SSV were the same vertebra in 11 patients. In the remaining 28 patients, 10 patients were in Group S, 15 patients were in Group F and 3 patients were in Group L (Fig. 2). The groups were similar in terms of age, follow-up, preoperative and postoperative Cobb angle, flexibility rate, and correction rate ($p > 0.05$) (Table 1).

DJK was detected in 12 of the patients. None of the patients in Group S developed DJK. However, DJK was observed in 9 of the 15 (60%) patients in Group F. All of the patients in Group L developed DJK (100%) (Fig. 3). The risk of developing DJK with a LIV selected as FLV or LEV was higher than it was SSV, and this difference was statistically significant ($p < 0.05$).

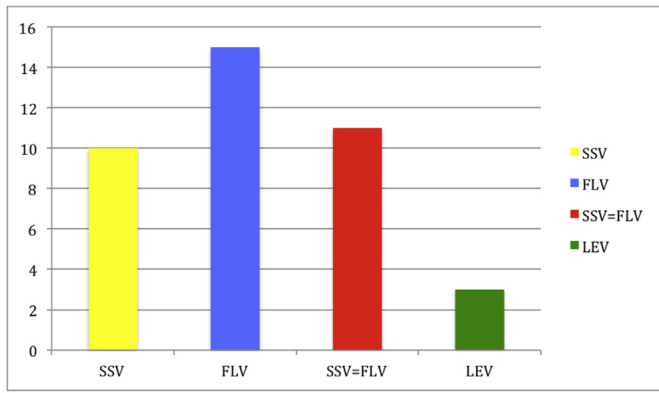


Fig. 2. The distribution of patients to groups.

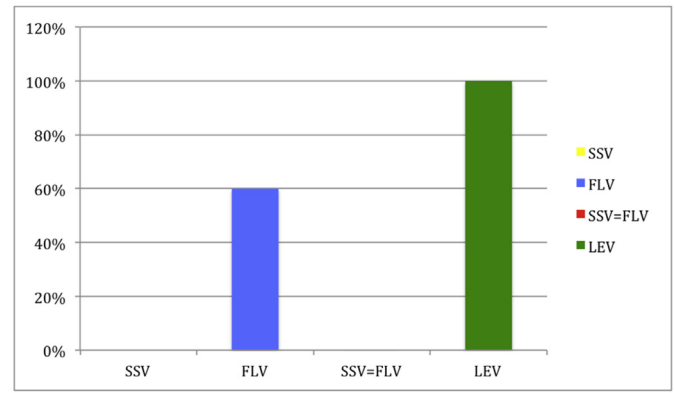


Fig. 3. DJK distribution of patients.

In 2 of the 12 patients who developed DJK, the fusion level was expanded to the SSV because the patients were symptomatic (Fig. 4). One of them was in Group F (6.6%), and the other was in Group L (33.3%). In these patients, the posterior ligamentous complex was insufficient with facet joint subluxation. In addition, most of the patients with DJK were detected as being asymptomatic. Symptomatic patients treated surgically did not report any complication during follow-ups.

When we analyzed the sacropelvic parameters and DJK, we did not find statistically significant difference between DJK and non-DJK group, in terms of sacral slope, pelvic incidence and pelvic tilt angles (Table 2).

The upper instrumentation level for these patients was the upper end vertebra (UEV) of the curves, which was T2 in 26 patients, T3 in 11 patients, and T4 in 2 patients. We did not observe any symptomatic PJK in our patients.

Discussion

In this current study, we compared the effect of SSV, FLV, and LEV selection on DJK development in SK patients. We found that selecting SSV for the distal fusion level is effective for preventing DJK and there is a statistically higher risk for developing DJK when FLV or LEV was selected as LIV.

Scheuermann kyphosis is commonly presented with thoracic hyperkyphosis. Surgical indications for the treatment of SK that were reported included a severe deformity, progressive kyphosis and pain that does not respond to conservative treatment.^{1–3,5,17}

The surgical treatment was composed of a posterior or combined anterior–posterior approach with various types of anchors. Bradford et al⁵ reported that a sufficient correction can be achieved by only the posterior approach but that the combined surgery had a

higher rate of success. However, Lee et al⁷ showed in their comparative study that only the posterior approaches were more successful and had lower rates of complications compared to the combined surgery. Koller et al¹⁸ compared the anteroposterior and posterior-only correction of SK patients and found that both approaches averaged similar degrees of correction with higher fusion levels in posterior-only group. In 2005, Herrera-Soto et al¹⁹ published their experience of combined video-assisted thoracoscopic surgery (VATS) anterior spinal release and posterior spinal fusion in SK patients, and they concluded that for more severe and rigid curves, this technique is a viable option with no junctional problems.

The standardization of a lateral spinal radiograph is essential to evaluate the alignment of the spine and have marked effects on the reproducibility of measurements between subsequent radiographs. A relaxed, arms at sides standing position prevents adequate visualization of the spine because of the humeri. However flexing the arms may influence the sagittal parameters. There are several lateral spine x-ray acquisition techniques. In 2000, Jackson and Hales²⁰ took the lateral radiographs of healthy volunteers to decide parameters and ranges for congruent sagittal spinopelvic alignment. They positioned the patients in standing straight and relaxed position, with their knees extended as much as possible and supported the arms by a horizontal bar at a little below chest level with the elbows slightly flexed. We used this positioning technique in our patients. Later, other techniques have begun to be used. The most common techniques are ‘fists on clavicles’ and ‘shoulder flexed’ positions. Faro et al²¹ compared these techniques and concluded that ‘fists on clavicles’ position has less negative in sagittal vertical axis (SVA), and more representative of a patients’ functional balance. In a prospective study, Marks et al,²² evaluated the effects of 4 various positions of the upper extremity on

Table 1
Data and statistics of age, gender, follow-up, radiographic parameters and correction rate in groups.

	Age (year)	Gender	Follow-up (year)	Preop Cobb (°)	Postop Cobb (°)	Flexibility (%)	UIV	LIV	Correction Rate (%)	DJK	Symptomatic DJK
SSV	19.1 (SD ± 3.5)	F: 4 M: 6	7.1 (SD ± 2.7)	76.6 (SD ± 8.3)	42.6 (SD ± 9.7)	39.7 (SD ± 6.7)	T2: 7 T3: 3	L2: 4 L3: 6	44.2 (SD ± 10.4)	0	0
FLV	18.5 (SD ± 3.5)	F: 9 M: 6	8.7 (SD ± 3.1)	73.3 (SD ± 6.9)	39 (SD ± 7.8)	41.8 (SD ± 5.2)	T2: 9 T3: 5 T4: 1	L1: 4 L2: 9 L3: 2	46.6 (SD ± 9.8)	9	1
SSV=FLV	19.1 (SD ± 2.7)	F: 4 M: 7	8.3 (SD ± 4.6)	70.1 (SD ± 7.4)	36.8 (SD ± 6.6)	43.6 (SD ± 8.3)	T2: 8 T3: 2 T4: 1	L1: 2 L2: 3 L3: 6	47.3 (SD ± 10.7)	0	0
LEV	18 (SD ± 3.9)	F: 2 M: 1	7 (SD ± 1.8)	71.7 (SD ± 5.5)	37.2 (SD ± 12)	43.2 (SD ± 11.5)	T2: 2 T3: 1	T12: 1 L1: 2	47.7 (SD ± 17.8)	3	1
p	0.870		0.618	0.170	0.361	0.516			0.695	<0.001	

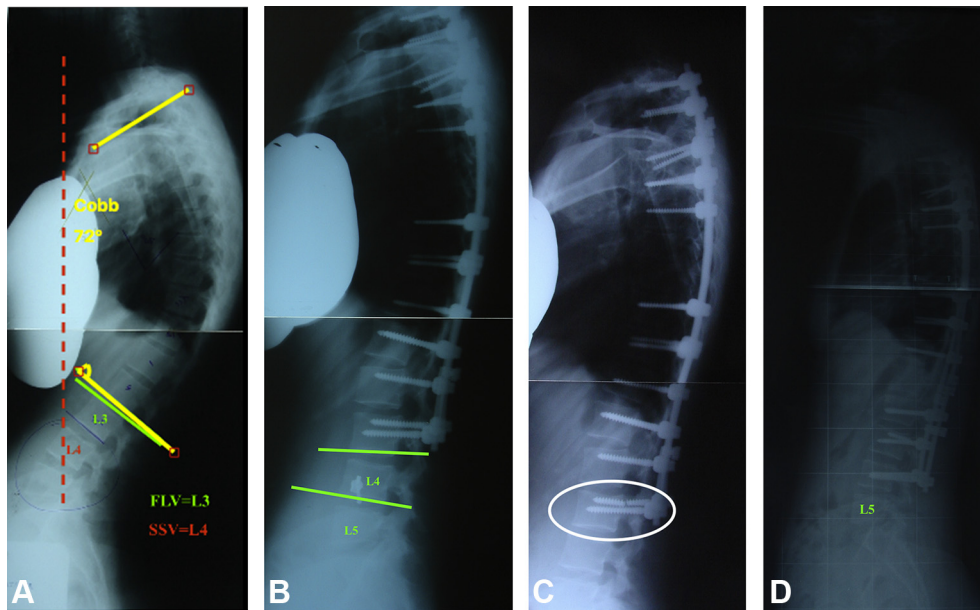


Fig. 4. Twenty year-old women with SK. A – Preoperative lateral X-ray shows that FLV is L3 and SSV is L4. The patient was operated through a posterior approach through T2-L3. B – After 1 month DJK was observed. C – Six months later distal screw was broken (white circle). D – Because of being symptomatic, the instrumentation level extended to L4, which was the SSV preoperatively.

Table 2
Data and statistics of sacropelvic radiographic parameters in Non-DJK versus DJK group.

	Preoperative			Postoperative		
	Non-DJK (n:27)	DJK (n:12)	p value	Non-DJK (n:27)	DJK (n:12)	p value
Pelvic incidence	51 ± 9.6	49 ± 9.7	0.77	51.8 ± 8.6	48 ± 9.1	0.71
Pelvic tilt	11 ± 9.1	10 ± 2	0.84	107.9	12.2 ± 3	0.81
Sacral slope	39 ± 8.3	39 ± 8.9	0.70	40.4 ± 7.6	37.7 ± 7.6	0.41

They are >0.05 and all of the p values are insignificant.

thoracolumbar sagittal alignment and found that standing with the hands supported while flexing the shoulders 30° during lateral spinal radiograph acquisition is the best way with the least effect on overall sagittal balance. This position is not the same but similar to our lateral x-ray acquisition technique.

Proximal junctional kyphosis (PJK) is more common than DJK. However, DJK is an undesirable complication of SK surgery.^{8–10,15} Recommended upper instrumentation level is the upper end vertebrae of the deformity.^{9,14} In our patients, we choose the upper end as vertebra upper instrumentation level and we did not observe any symptomatic PJK. Because they are mostly asymptomatic, distal junctional problems were reported in up to 71% of patients and were usually neglected.^{9–11} There is very limited information and no consensus on the prevention of distal junctional problems. Ascani and Rosa²³ reported that the fusion level should be the vertebra distal to the neutral vertebra and should always include the L1. However, Wenger and Frick⁴ suggested the posterior instrumented fusion from T3-L2. Hosman, Denis and Otsuka identified the distal fusion level as the first vertebra distal to the first lordotic disc.^{9,15,16} Cho et al¹⁰ reported that the fusion level might not be a standard vertebra and that it might change due to the SSV on the lateral plane.

Few studies in the literature have compared distal instrumentation levels for SK. Cho et al¹⁰ reported a rate of DJK of 71% if the fusion level was proximal to the SSV. Lundine et al reported a rate of DJK development of 13% if the SSV was selected as the LIV and a rate of DJK development of 38% if the FLV was selected as the LIV.¹¹ In contrast to these studies, Yanik et al²⁴ reported that it is not

necessary to extend the fusion down to the SSV and that fusion to the FLV is sufficient and saves the level. In our study, DJK was not noticed in 10 patients for whom the SSV was selected as the LIV. However, DJK developed in 12 of the 18 patients for whom the LIV was proximal to the SSV (those in Group F and Group L). DJK developed in 9 of the 15 patients for whom the FLV was selected as the LIV. There is a statistically significant higher risk for the development of DJK if the FLV and LEV were selected as the LIV. The revision rate of the instrumentation due to symptomatic DJK was 33% when the LIV was higher than the FLV or SSV (those in Group L).

Cho et al¹⁰ reported DJK in 5 of the 6 patients for whom the distal fusion level was proximal to the FLV or SSV. Lonner et al,⁸ in a series of 78 patients, stated that DJK developed in 4 patients, and in 3 of these patients, the LIV was proximal to the FLV and SSV. In our study, DJK developed in 3 patients who underwent a fusion proximal to the SSV and FLV, which is similar to the results of previous studies.

In our study, the FLV and SSV were identified as being the same vertebra in 11 of the 39 (28%) patients. In previous studies, various incidences that were reported were between 15% and 33%.^{10,11,24} The SSV was located more proximal than the FLV in none of these studies.

Another important result of our study is that DJK was likely to develop and become symptomatic when the LIV was selected proximal than the SSV. The patients who developed DJK and became symptomatic included 1 of the 9 FLV patients and 1 of the 3 LEV patients, and they both needed revisional surgery. None of the SSV patients developed DJK and became symptomatic. This shows

that selecting the LIV higher than the SSV is more likely to lead to the patient becoming symptomatic and needing revisional surgery if DJK develops.

The mean preoperative thoracic kyphosis angle of the patients is relatively low and the DJK rate of the patients is slightly high. According to our results, we think that high DJK rates were associated with inappropriate distal level selection, not with the preoperative kyphosis angles. The Cobb angles were similar between the groups (Table 1), however, DJK was seen only in FLV and LEV. As a supportive study of our findings, Denis et al⁹ analyzed the incidence and risk factors in their surgically treated SK patients and found that PJK was associated with failure to incorporate the proximal end vertebra, disruption of junctional ligamentum flavum or combination of both and DJK was associated with unfusing the first lordotic disk. They also found that the onset of PJK was not related to either the magnitude of preoperative kyphosis measurement or amount of correction achieved.

Although, there is a strong correlation between high pelvic incidence and proximal junctional problems in Scheuermann kyphosis,^{8,25} the influence of sacropelvic parameters on distal junctional kyphosis is unclear in the literature. In our study, we did not find statistically significant difference in sacropelvic parameters between DJK group and non-DJK group.

This study is not without limitations. First, this is a retrospective study and it lacks randomization of the patients. The measurements were done by a computer-based software, so there could have been some measurement errors. The number of patients included in the sample was relatively small. Lack of early postoperative radiographs is another important restriction. Comparison of early postoperative and last follow-up data can show us if there is a correction loss during follow-up. However, this was not our aim for this study. Finally, we did not evaluate patient self-reported outcome parameters; this would be beneficial in further studies. We aimed only a radiologic evaluation on SK patients to analyze DJK development.

Conclusion

The selection of an appropriate distal level for SK patients is important for preventing distal junctional problems. Our study shows that selecting the SSV for the distal fusion level would prevent the development of DJK. The distal junctional kyphosis develops not uncommonly and becomes symptomatic if the LIV is selected proximal to the SSV, which requires revisional surgery.

References

1. Bezalel T, Carmeli E, Been E, Kalichman L. Scheuermann's disease: current diagnosis and treatment approach. *J Back Musculoskelet Rehabil.* 2014;27(4):383–390.
2. Murray PM, Weinstein SL, Spratt KF. The natural history and long-term follow-up of Scheuermann kyphosis. *J Bone Jt Surg Am.* 1993;75(2):236–248.
3. Morscher E. [Nature, diagnosis and therapy of Scheuermann's disease]. *Schweiz Med Wochenschr.* 1967;97(24):763–766.
4. Wenger DR, Frick SL. Scheuermann kyphosis. *Spine (Phila Pa 1976).* 1999;24(24):2630–2639.
5. Bradford DS, Ahmed KB, Moe JH, Winter RB, Lonstein JE. The surgical management of patients with Scheuermann's disease: a review of twenty-four cases managed by combined anterior and posterior spine fusion. *J Bone Jt Surg Am.* 1980;62(5):705–712.
6. Herndon WA, Emans JB, Micheli LJ, Hall JE. Combined anterior and posterior fusion for Scheuermann's kyphosis. *Spine (Phila Pa 1976).* 1981;6(2):125–130.
7. Lee SS, Lenke LG, Kuklo TR, et al. Comparison of Scheuermann kyphosis correction by posterior-only thoracic pedicle screw fixation versus combined anterior/posterior fusion. *Spine (Phila Pa 1976).* 2006;31(20):2316–2321.
8. Lonner BS, Newton P, Betz R, et al. Operative management of Scheuermann's kyphosis in 78 patients: radiographic outcomes, complications, and technique. *Spine (Phila Pa 1976).* 2007;32(24):2644–2652.
9. Denis F, Sun EC, Winter RB. Incidence and risk factors for proximal and distal junctional kyphosis following surgical treatment for Scheuermann kyphosis: minimum five-year follow-up. *Spine (Phila Pa 1976).* 2009;34(20):E729–E734.
10. Cho KJ, Lenke LG, Bridwell KH, Kamiya M, Sides B. Selection of the optimal distal fusion level in posterior instrumentation and fusion for thoracic hyperkyphosis: the sagittal stable vertebra concept. *Spine (Phila Pa 1976).* 2009;34(8):765–770.
11. Lundine K, Turner P, Johnson M. Thoracic hyperkyphosis: assessment of the distal fusion level. *Glob Spine J.* 2012;2(2):65–70.
12. Tonbul M, Orhan O, Yilmaz MR, Adas M, Yurdoglu HC, Altan E. Is there any correlation between the preoperative parameters and correction loss in patients operated for hyperkyphosis? *Acta Orthop Traumatol Turc.* 2010;44(4):300–305.
13. Arlet V, Aebi M. Junctional spinal disorders in operated adult spinal deformities: present understanding and future perspectives. *Eur Spine J.* 2013;22(suppl 2):S276–S295.
14. Lowe TG, Kasten MD. An analysis of sagittal curves and balance after Cotrel-Dubouset instrumentation for kyphosis secondary to Scheuermann's disease. A review of 32 patients. *Spine (Phila Pa 1976).* 1994;19(15):1680–1685.
15. Hosman AJ, Langeloo DD, de Kleuver M, Anderson PG, Veth RP, Slot GH. Analysis of the sagittal plane after surgical management for Scheuermann's disease: a view on overcorrection and the use of an anterior release. *Spine (Phila Pa 1976).* 2002;27(2):167–175.
16. Otsuka NY, Hall JE, Mah JY. Posterior fusion for Scheuermann's kyphosis. *Clin Orthop Relat Res.* 1990;(251):134–139.
17. Palazzo C, Sailhan F, Revel M. Scheuermann's disease: an update. *Jt Bone Spine.* 2014;81(3):209–214.
18. Koller H, Lenke LG, Meier O, et al. Comparison of anteroposterior to posterior-only correction of Scheuermann's kyphosis: a matched-pair radiographic analysis of 92 patients. *Spine Deform.* 2015;3(2):192–198.
19. Herrera-Soto JA, Parikh SN, Al-Sayyad MJ, Crawford AH. Experience with combined video-assisted thoracoscopic surgery (VATS) anterior spinal release and posterior spinal fusion in Scheuermann's kyphosis. *Spine (Phila Pa 1976).* 2005;30(19):2176–2181.
20. Jackson RP, Hales C. Congruent spinopelvic alignment on standing lateral radiographs of adult volunteers. *Spine (Phila Pa 1976).* 2000;25(21):2808–2815.
21. Faro FD, Marks MC, Pawelek J, Newton PO. Evaluation of a functional position for lateral radiograph acquisition in adolescent idiopathic scoliosis. *Spine (Phila Pa 1976).* 2004;29(20):2284–2289.
22. Marks M, Stanford C, Newton P. Which lateral radiographic positioning technique provides the most reliable and functional representation of a patient's sagittal balance? *Spine (Phila Pa 1976).* 2009;34(9):949–954.
23. Ascani EL, Rosa. *Scheuermann Kyphosis. The Pediatric Spine: Principles and Practice.* 1994:557–584.
24. Yanik HS, Ketenci IE, Coskun T, Ulusoy A, Erdem S. Selection of distal fusion level in posterior instrumentation and fusion of Scheuermann kyphosis: is fusion to sagittal stable vertebra necessary? *Eur Spine J.* 2016;25(2):583–589.
25. Nasto LA, Perez-Romera AB, Shalabi ST, Quraishi NA, Mehdian H. Correlation between preoperative spinopelvic alignment and risk of proximal junctional kyphosis after posterior-only surgical correction of Scheuermann kyphosis. *Spine J.* 2016;16(suppl 4):S26–S33.