

# Peripheral Neurectomy for Trigeminal Neuralgia: A Report of Seventeen Cases and Review of the Literature

## Abstract

**Background:** Surgical intervention for trigeminal neuralgia (TN) is indicated if there is a failure of the medical treatment. Peripheral neurectomy is one of the oldest surgical procedures for TN. **Objective:** The aim is to evaluate the clinical outcome and the recurrence rate following peripheral neurectomy for the management of TN. **Patients and Methods:** This was a retrospective cohort study of 17 patients with classical TN treated by peripheral neurectomy. The visual analogue scale (VAS) was used for pain assessment preoperatively and during the follow-up period. The outcome of surgery was graded as a marked, moderate, or mild improvement. Kaplan–Meier analysis was used for the time to recurrence to predict the probability of recurrence at any given time following the procedure. **Results:** The mean pain-free interval was  $29.3 \pm 16.3$  months. At 2 and 5 years of the follow-up period, the mean VAS improved significantly ( $P < 0.001$  and  $P = 0.042$  respectively). Thirteen patients had marked improvement of pain. There was recurrence of pain in 4 patients (23.5%). By Kaplan–Meier analysis, the survival rate without recurrence at 2, 3, 4, and 5 years following the procedure were 92.9%, 79.6%, 59.7%, and 29.8%, respectively. The mean preoperative Hospital Anxiety and Depression Scale-Anxiety and Depression scores significantly improved on the last follow-up visit following the procedure ( $P < 0.001$  for both). **Conclusion:** Peripheral neurectomy provides short to medium-term good pain control for patients with TN. The preoperative severity of pain, anxiety, and depression levels improved markedly after the procedure.

**Keywords:** *Inferior alveolar, infraorbital nerve, peripheral neurectomy, trigeminal neuralgia*

## Introduction

Trigeminal neuralgia (TN) is a sudden, sharp, severe, intermittent, lancinating, usually unilateral facial pain in the distribution of one or more divisions of the trigeminal nerve,<sup>[1]</sup> lasting from a fraction of a second to minutes and is triggered by trivial cutaneous or intraoral stimuli.<sup>[2]</sup> The estimated annual incidence of TN is about 13 per 100,000 persons/year.<sup>[3]</sup> It most commonly occurs over the age of 40 years with a slight female predilection.<sup>[4]</sup> Spending adequate time in the patient interview and physical examination of the regions supplied by the trigeminal nerve is important to reach a proper diagnosis of TN.<sup>[5]</sup>

The medical treatment fails in 30% of the patients, either through inadequate pain control or due to intolerable side effects;<sup>[6]</sup> therefore, surgical management is indicated in these patients. There are many available

surgical procedures used for the treatment of TN.<sup>[7]</sup> Peripheral neurectomy is a simple, low-risk procedure that involves surgical avulsion of the postganglionic part of the trigeminal nerve divisions, usually performed under local anesthesia for managing peripheral pain in TN.<sup>[8]</sup> Despite it is one of the oldest surgical procedures for TN, none of the previous studies about peripheral neurectomy for treatment of TN had been subjected to good statistical analysis.<sup>[7]</sup>

This study aims to evaluate the clinical outcome and the recurrence rate following peripheral neurectomy for the management of TN. To the best of our knowledge, this is the first study to use Kaplan–Meier analysis for the time to recurrence to predict the probability of recurrence at any given time following the procedure. The severity of the disease and the anxiety and depression status of the patients before and after the procedure were also discussed.

This is an open access journal, and articles are distributed under the terms of the Creative Commons Attribution-NonCommercial-ShareAlike 4.0 License, which allows others to remix, tweak, and build upon the work non-commercially, as long as appropriate credit is given and the new creations are licensed under the identical terms.

For reprints contact: WKHLRPMedknow\_reprints@wolterskluwer.com

**How to cite this article:** Nagy MR, Mahmoud B. Peripheral neurectomy for trigeminal neuralgia: A report of seventeen cases and review of the literature. *Asian J Neurosurg* 2021;16:281-7.

**Submitted:** 24-Jul-2020

**Revised:** 22-Nov-2020

**Accepted:** 16-Mar-2021

**Published:** 28-May-2021

**Mohamed Ragab Nagy,  
Bokhary Mahmoud<sup>1</sup>**

*Department of Neurosurgery,  
Faculty of Medicine, Cairo  
University, Cairo, Egypt,  
<sup>1</sup>Department of Neurosurgery,  
Armed Forces Hospital Southern  
Region, Khamis Mushait,  
Saudi Arabia*

**Address for correspondence:**  
Dr. Mohamed Ragab Nagy,  
446, Al Haram Street, Giza,  
Egypt.  
E-mail: dr\_mohamedragab@  
hotmail.com

Access this article online

**Website:** www.asianjns.org

**DOI:** 10.4103/ajns.AJNS\_361\_20

**Quick Response Code:**



## Patients and Methods

This was a retrospective cohort study of 17 patients with classical TN treated by peripheral neurectomy, operated on in Royal Commission Hospital, Jubail and Southern Armed Forces Hospital, KSA from January 2013 to December 2018. The study was approved by the local ethical committee. The classical TN was diagnosed according to Sweet's criteria (the pain is paroxysmal, may be provoked by light touch to the face, confined to trigeminal distribution, unilateral and the clinical sensory examination is normal). The patients in the study included those who are resistant to medical treatment or developed intolerance to medications due to their side effects and those who are unfit because of either old age or co-morbidity or reluctant to have invasive neurosurgical procedures. Patients younger than 30 years old, those with symptomatic TN (a causative lesion, other than vascular compression like multiple sclerosis or tumor), those with an atypical presentation like bilateral involvement, and the patients with follow-up periods <1 year were excluded from the study.

The patients were assessed preoperatively including a detailed history, clinical general and neurological examination, and the response of pain to carbamazepine was detected. Diagnostic block with 2% lignocaine was used to confirm the involved division of the nerve in the patients after detecting the site of the pain by history and clinical examination when it gave complete relief from the symptoms. All patients underwent magnetic resonance imaging of the brain to rule out underlying structural lesions such as tumors or vascular malformations. Carbamazepine tablets 600–1200 mg daily were prescribed for all patients. It was used continuously or intermittently for an average of one to 3 years, sometimes alone and sometimes with other drugs to treat the condition. The visual analogue scale (VAS) was used for pain assessment preoperatively and during the follow-up period.

Informed written consent was obtained from all the patients included in this study for peripheral neurectomy of the involved branch of the trigeminal nerve. Regarding the surgical technique used, the supraorbital nerve was accessed under local anesthesia through an upper eyebrow incision. The nerve was avulsed, while its remnants were cauterized. The supraorbital foramen was blocked by bone wax. Double layer closure was done at the conclusion of surgery. The infraorbital nerve was approached through an intraoral vestibular incision under local anesthesia where the infraorbital foramen was identified. The infraorbital nerve was avulsed from the soft tissues and the infraorbital canal while the remnants of the nerve were cauterized deeply in the foramen. The foramen was blocked by bone wax and suturing the wound in layers was done. For inferior alveolar neurectomy, an incision about 1.5 inches long was made along the anterior border of the ascending ramus to expose a point on the mandible midway between the last

molar tooth and the angle of the jaw. After the fibers of the masseter muscle have been separated to expose the bone, a burr hole was placed in the outer table of the mandible to expose the mandibular canal. The perforator was applied carefully to prevent nerve damage. By deepening the burr hole, the thin cortical roof of the canal was removed to expose the large nerve within it. A blunt hook is passed around the nerve and slightly distracted from the canal so that two hemostatic forceps can be applied to the full thickness of the nerve. Without allowing the nerve to fray, the forceps were applied. The entire length of the nerve was withdrawn from the mandibular canal. Traction was then applied proximally to drag about 1 cm of nerve down into the wound before cutting it. The proximal part of the nerve was divided rather than avulsed to avoid possible traction damage to the ganglion with undesirable anesthesia, especially to the lingual nerve. The distal end of the nerve was avulsed and its remnants were cauterized deep in the foramen. The mental foramen was blocked by bone wax and suturing of the wound in layers was done. Antibiotics and anti-inflammatory drugs were prescribed for all patients postoperatively for 5–7 days. The initial postoperative relief of pain was assessed during the 1<sup>st</sup> week after surgery.

The patients were followed up after surgery at 1 month, 3 months, 6 months then annually or if a change of pain severity appeared. VAS was used for pain assessment during the follow-up period. The outcome of surgery was graded as (A) Marked improvement (reduction of pain more than 85% of preoperative pain without medications for TN); (B) Moderate improvement (50%–84.9% reduction of preoperative pain, treatment with low doses of Carbamazepine was allowed in this group); and (C) Mild improvement (reduction of pain <50% compared to preoperative pain, long-term medication was resumed, or an additional procedure was performed for TN). Recurrence was defined as a transition from marked improvement group to either the moderate or mild improvement group during the follow-up period. Kaplan–Meier analysis was used for the time to recurrence to predict the probability of recurrence at any given time. Hospital Anxiety and Depression Scale (HADS) was used for the assessment of anxiety and depression status of the patients during the follow-up visits in comparison to the preoperative status. The degree of relief of pain, recurrence of pain, postoperative complications, the need for additional procedures in case of recurrent pain were recorded during the follow-up visits.

## Statistical analysis

Data were statistically described in terms of mean  $\pm$  standard deviation, median and range, or frequencies (number of cases), and percentages when appropriate. Numerical data were tested for the normal assumption using the Shapiro–Wilk test. Comparison

between pre- and post-operative data was done using the Wilcoxon signed-rank test for paired (matched) samples. Survival analysis for the time to recurrence was done using Kaplan–Meier statistics calculating the mean and median survival time for each group with their 95% confidence interval and the corresponding survival graphs. Two-sided  $P < 0.05$  was considered statistically significant. All statistical calculations were done using the computer program IBM Statistical Package for the Social Science (SPSS) (SPSS; IBM Corp, Armonk, NY, USA) release 22 for Microsoft Windows.

## Results

The study included 17 patients who fulfilled the inclusion criteria. The mean age of the patients was  $54.4 \pm 10$  (range, 31–67) years. The female/male ratio was 2.4:1. The characteristics of the patients in the study are shown in Table 1 [Figures 1-3].

The mean preoperative VAS was  $7.47 \pm 0.8$  (range, 6–9). Initially, the pain was relieved in all patients following the procedure. The mean pain-free interval was  $29.3 \pm 16.3$  (range, 14–85) months. The mean follow-up period was  $44.9 \pm 23.2$  (range, 14–90) months. The VAS had significantly improved during the follow-up period. At 2 and 5 years of follow-up period, the mean VAS was  $0.81 \pm 1.276$  and  $1.6 \pm 0.894$  ( $P < 0.001$  and  $P = 0.042$  respectively) [Table 2 and Figure 4].

Thirteen patients (76.5%) had marked improvement of pain until their last follow-up visit. The duration of pain relief was  $< 2$  years in seven patients (53.8%), between 2 and 5 years in 5 patients (38.5%), and more than 5 years in only 1 patient (7.7%). There was a recurrence of pain in four patients (23.5%). Three of them had both V2 and V3 involved while one case had V3 only involved. The mean time of recurrence in these cases was  $3.5 \pm 1.3$  (range, 2–5) years. Three of these cases (17.6%) had declined to moderate improvement group during the follow-up period. These patients were managed by a lower dose of carbamazepine (400 mg daily). The fourth patient (5.9%) has declined to the mild improvement group 2 years after the procedure. He was referred for microvascular decompression (MVD). Three patients out of seventeen who have been lost to follow-up for reasons other than death were included as censored data as they had the same distribution of outcomes as assessed on their last follow-up visit. By Kaplan–Meier analysis, the survival rate without recurrence at 2, 3, 4, and 5 years following the procedure were 92.9%, 79.6%, 59.7%, and 29.8%, respectively [Figure 5].

The mean preoperative HADS-Anxiety score was  $11.59 \pm 2.12$ , which significantly improved to  $6.35 \pm 1.77$  on the last follow-up visit following the procedure ( $P < 0.001$ ). Likewise, the mean HADS-Depression score was

**Table 1: The characteristics of the patients in the study (n=17)**

Characteristic	Value (%)
Age (years)	
30-39	1 (5.9)
40-49	3 (17.6)
50-59	7 (41.2)
$\geq 60$	6 (35.3)
Sex	
Male	5 (29.4)
Female	12 (70.6)
Side of the face involved	
Right	13 (76.5)
Left	4 (23.5)
Preoperative duration of symptoms (years)	
Mean $\pm$ SD	5.8 $\pm$ 2.4
Range	1–10
Divisions of the trigeminal nerve involved	
V2 only	3 (17.6)
V3 only	6 (35.3)
V2 and V3	7 (41.2)
V1, V2, and V3	1 (5.9)

SD – Standard deviation

**Table 2: Comparison of Visual Analogue Scale over time in the study patients (n=17)**

VAS (years)	n (%)	Mean $\pm$ SD	P
Preoperative	17 (100)	7.47 $\pm$ 0.800	
1.5	17 (100)	0.53 $\pm$ 0.624	$< 0.001^*$
2	16 (94.1)	0.81 $\pm$ 1.276	$< 0.001^*$
3	14 (82.4)	1.07 $\pm$ 0.730	0.001*
4	7 (41.2)	1.43 $\pm$ 0.787	0.017*
5	5 (29.4)	1.60 $\pm$ 0.894	0.042*
6	4 (23.5)	1.25 $\pm$ 0.500	0.066*
7	2 (11.8)	1.50 $\pm$ 0.707	0.180
7.5	2 (11.8)	1.00 $\pm$ 0.000	0.180

\* $P < 0.05$  was considered statistically significant. SD – Standard deviation, VAS – Visual Analogue Scale

$11.12 \pm 1.9$  which significantly improved to  $6.24 \pm 1.72$  on the last follow-up visit ( $P < 0.001$ ) [Tables 3].

All patients had the expected sensory loss in the distribution of the avulsed division of the trigeminal nerve. It was less annoying than the stress of pain in 12 patients (70.6%). Despite five patients (29.4%) were initially unpleasant with this facial anesthesia, they were reassured and they reported that they became adaptive with it over time. Two patients (11.8%) developed postoperative facial swelling which was managed conservatively and resolved gradually over days.

## Discussion

TN is a neuropathic facial pain syndrome, described as a sudden, severe, brief, stabbing, usually unilateral, recurring pain in the distribution of one or more divisions

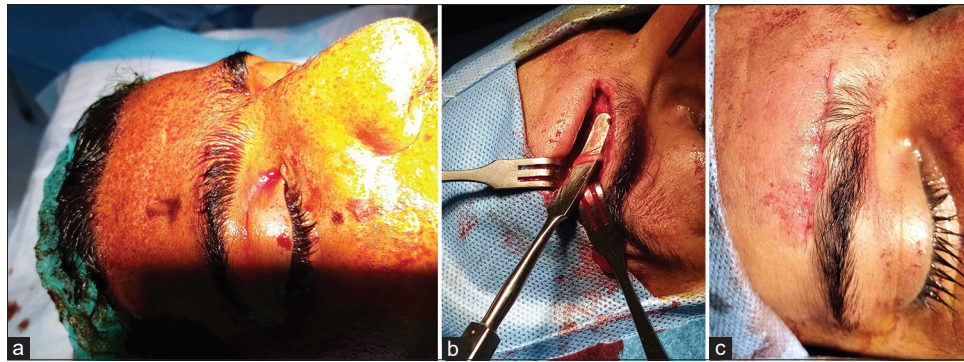


Figure 1: Supraorbital neurectomy in a 31-year-old male patient who had all the three divisions involved on the right side and refused more invasive neurosurgical procedures: (a) Sterilization of the skin, (b) Exposure of the supraorbital nerve before avulsion, and (c) Closure of skin at the conclusion of surgery

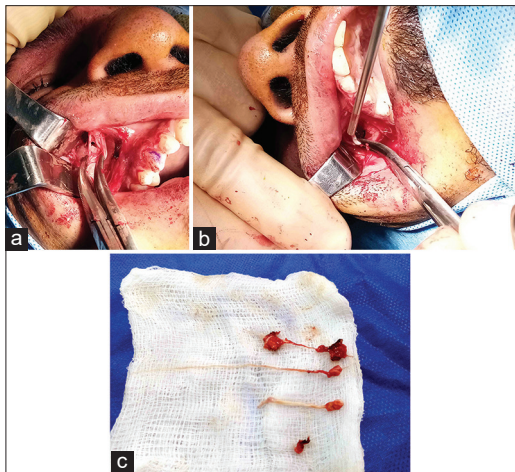


Figure 2: Right infraorbital neurectomy in the same patient illustrated in (a) Exposure of the infraorbital nerve branches through a vestibular incision, (b) The infraorbital nerve stump, and (c) The avulsed branches of the infraorbital nerve

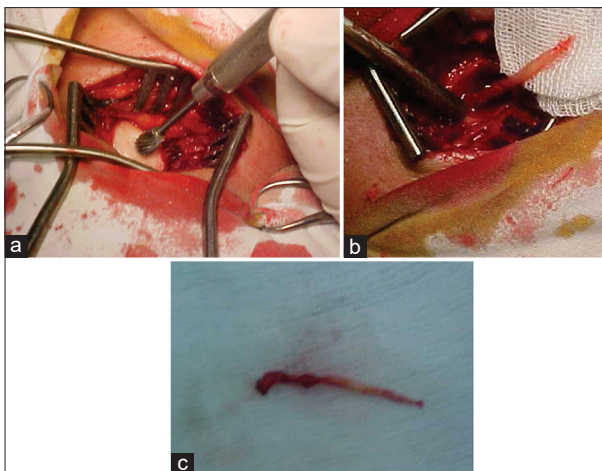


Figure 3: Right inferior alveolar neurectomy in a 52-year-old female patient who had only V3 involvement: (a) Exposure of the angle of the mandible and preparation for the burr hole, (b) Exposure of the mental nerve, and (c) The avulsed nerve specimen

of the trigeminal nerve. The pain lasts from seconds to minutes and is triggered by trivial stimuli such as shaving,

**Table 3: Comparison of preoperative anxiety and depression versus on the last follow-up visit in the study patients**

HADS	n	Mean±SD	P
Anxiety (preoperative)	17	11.59±2.123	
Anxiety (on last follow-up visit)	17	6.35±1.766	<0.001*
Depression (preoperative)	17	11.12±1.900	
Depression (on last follow-up visit)	17	6.24±1.715	<0.001*

\*P<0.05 was considered statistically significant. SD – Standard deviation, HADS – Hospital Anxiety and Depression Scale

brushing the teeth, washing the face, talking, and eating. These patients are usually in constant fear that the pain will recur taking into consideration that the attacks of pain increase in frequency, severity, and duration as time passes unless definitive treatment is started.<sup>[9]</sup> They typically seek medical advice from different medical practitioners seeking to alleviate their pain.

The peak age of onset of TN is reported to be after the fourth decade of life with a slight predilection for females ranging from 2:1 to 3:2. The condition usually affects the right side of the face.<sup>[10]</sup> Similar results were obtained in our study as 76.5% of the patients were above 50 years old, the female/male ratio was 2.4:1, and the right side of the face was involved in 76.5% of the patients. TN may be classical or symptomatic resulting from compression of the trigeminal nerve root or nucleus by tumors, multiple sclerosis plaques, aneurysms, or vascular malformations.<sup>[11]</sup> The pathophysiology of classic TN is associated with neurovascular compression in the trigeminal root entry zone resulting in demyelination and dysregulation of voltage-gated sodium channel expression in the membrane, leading to pain attacks in patients with TN.<sup>[12]</sup> A recent study found that pathological vascular changes in peripheral vasculature leading to demyelination of the inferior alveolar nerve may have a role in the initiation and precipitation of pain in patients with TN.<sup>[13]</sup> In this study, the mandibular division (V3) was involved in about 35% whereas both V2 and V3 were involved in about 41% of the patients. The mandibular division is the

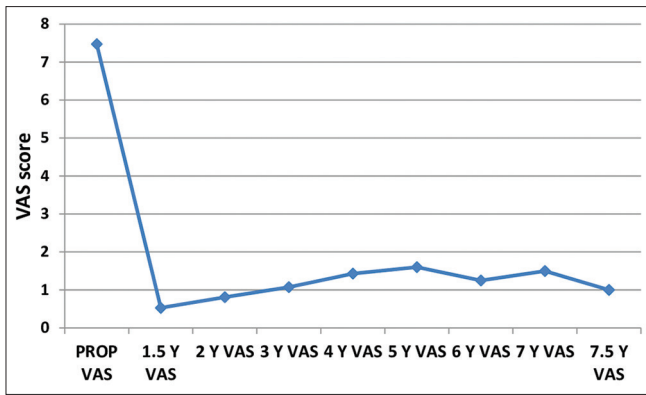


Figure 4: Mean visual analog scale score over the time in the study sample. (PROP – Preoperative)

most commonly involved and the ophthalmic division (V1) was less commonly involved in patients with TN.<sup>[10,14]</sup> Farooq *et al.* reported that V3 was involved either alone or in combination with V2 in 62.5% of the patients in their study of 72 patients with idiopathic TN.<sup>[15]</sup> Shankland reported that both V2 and V3 were involved in one-third of the patients in their study.<sup>[16]</sup>

Peripheral neurectomy is a minor, safe, and minimally invasive, daycare surgical procedure. It can be done as an outpatient procedure under local anesthesia. It involves the transection of the branches of the trigeminal nerve after their exit through their foramina on the facial skeleton. It interrupts the conduction of afferent impulses thereby aborting the episodes of pain.<sup>[17]</sup> The demyelination of involved nerve fibers due to peripheral vascular changes as seen on both histopathological and immunohistochemical examination gives a rationale for peripheral neurectomy in alleviating the pain in the patients with TN.<sup>[2,13]</sup> It is particularly carried out in old aged or debilitated patients in whom other invasive neurosurgical procedures are contraindicated.

In our study, the pain of TN had significantly improved during the follow-up period. The mean pain-free interval was 29 months. This is similar to the results of Quinn who reported a retrospective case series of 63 patients with 112 neurectomies. A Pain relief period of 24–32 months was reported within a follow-up period of 0–9 years. He concluded that the total pain-free period obtained from repeated peripheral neurectomies is significant and justifies the use of the procedure.<sup>[18]</sup> This is not so varied from the results of Freemont too who studied 146 patients, of whom 26 patients underwent neurectomy and noted an average pain-free period of 26.5 months following a single peripheral neurectomy. Twenty of these patients had remained pain-free until death or the end of the study.<sup>[19]</sup> Despite this pain-free period is less than reported in the study of Grantham who reported an average pain relief period of 33.2 months in a case series of 55 patients with 55 neurectomies during a follow-up

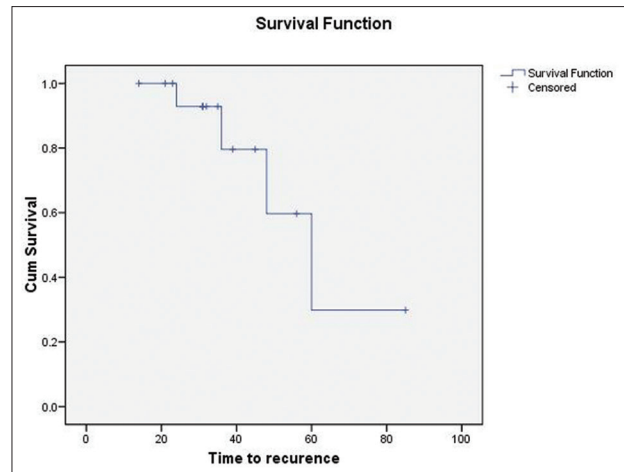


Figure 5: Kaplan-Meier curve for the recurrence over the time in the study sample

period of 6 months to 8 years, their study included only supraorbital and infraorbital nerves.<sup>[20]</sup> Cerovic *et al.* reported a pain-free interval of 12–15 months for infraorbital neurectomy and 15–18 months for mandibular neurectomy.<sup>[7,21]</sup> Khanna and Galinde reported a pain relief period of 24 months following infraorbital neurectomy and 26 months following mental neurectomy.<sup>[22]</sup> Mason observed that infraorbital neurectomy was likely to be more successful than inferior alveolar neurectomy.<sup>[23]</sup> We could not analyze the pain-free period of each division separately in our study as multiple nerve divisions were involved in the majority of cases.

In this study, 76.5% of the patients had marked improvement of pain until their last follow-up visit. Four patients (23.5%) developed a recurrence of pain. The mean time of recurrence in these cases was 3.5 years. Three of these cases had declined to the moderate improvement group during the follow-up period. They were managed by a lower dose of carbamazepine which is consistent with other studies.<sup>[19,24]</sup> One patient (5.9%) has declined to the mild improvement group and was referred for MVD. These results are comparable to the results of Chandan *et al.* who reported that 80% of patients had excellent pain relief lasting for 3 years without any medication following peripheral neurectomy done for 20 Indian patients with TN.<sup>[25]</sup> This is also near to the results of Shah *et al.*'s study on fifty patients with 70% of the patients having excellent pain relief lasting for 2–5 years without any medications and a recurrence rate of 12% uncontrolled even with medication.<sup>[26]</sup> Murali and Rovit reported an excellent (79% of the patients) or good pain relief for at least 5 years following peripheral neurectomy for the recurrent pain who had previously undergone radiofrequency thermocoagulation. Six patients out of 40 had a recurrence of pain after 2 years but responded well to a second neurectomy.<sup>[27]</sup> Cerovic *et al.* reported that the recurrence of pain following the first surgery on the

infraorbital nerve was seen in 41% of the cases, 35% of the patients had recurrence after the second surgery between 9 and 12 months and the recurrence was seen in 44% of the patients after the third surgery with pain-free period no longer than 12 months. They conclude that the remission time after repetitive peripheral neurectomy decreases, hence there is no point in repeating the surgery on the same nerve division more than three times.<sup>[21]</sup>

To the best of our knowledge, this is the first study to use Kaplan–Meier analysis for the time to recurrence to predict the probability of recurrence at any given time following peripheral neurectomy for TN. The postoperative survival rate was 92.9% after 2 years and 59.7% after 4 years. Zakrzewska used the Kaplan–Meier plots to analyze all the recurrence rates during his study. He found a median pain relief period of 6 months and a mean time to recurrence of 10 months in a 10-year follow-up series of 145 patients treated with cryotherapy for TN and as compared with the median pain relief period of 24 months in 265 patients treated with radiofrequency thermocoagulation. Sixty-two percent of 65 patients were pain-free 5 years after MVD.<sup>[28]</sup> Barker *et al.* have reported a long-term (20 years) prospective longitudinal study on the outcome of MVD for TN in 1185 patients. By Kaplan–Meier analysis, they found that the postoperative survival was 93% after 10 years and 70% after 20 years.<sup>[29]</sup>

We cauterized the nerve remnants and occluded the related foramina with bone wax to reduce the recurrence rate in our study. This is consistent with other studies.<sup>[2]</sup> The recurrence of pain following peripheral neurectomy for TN may be from the main ascending trunk remaining after the neurectomy, other branches of the same division of trigeminal nerve, or from the intact collateral branches, neuroma formation in the avulsed nerve, and demyelination and central sensitization which is increased excitability of neurons in adjacent spinal segments and cortical areas.<sup>[30–32]</sup> Peripheral neurectomy for TN followed by obscuration of the foramen with fat, stainless screw, titanium screws, and gold foils were tried with variable success rates.<sup>[19,23,24,33]</sup> Despite obturation with fat gives good results, it usually causes distant site morbidity. In a comparative study, the pain-free period following the procedure ranged from 15 to 24 months in cases without placing a stainless screw in the foramen, while none of the patients had recurrent pain after 2 years of follow-up when placement of stainless screws in the foramina was applied.<sup>[33]</sup> Hong-Sai reported that in 4 patients the infraorbital and mental foramina were occluded with titanium screws out of 12 cases that underwent peripheral neurectomies. There was no recurrence in these patients in 4 years.<sup>[34]</sup>

In our study, the anxiety and depression levels on HADS on the last follow-up visits had significantly improved in comparison to the preoperative levels. To the best of our knowledge, this is the first study to assess the anxiety

and depression states before and after the peripheral neurectomy done for patients with TN. This was done as a step to try to evaluate the quality of life in these patients following the procedure. Zakrzewska found that 39% were depressed and 42% were anxious out of 24 patients before undergoing cryotherapy for the treatment of TN. Following the procedure, only 15% were depressed and 30% were anxious.<sup>[28]</sup>

The complications of the procedure in this study included sensory loss in the area supplied by the avulsed nerve and temporary facial swelling. Lamichhane *et al.* reported the same complications.<sup>[8]</sup> Other complications reported in the literature included weakness of masseter muscles and very rarely, loss of the corneal reflex. In comparison with other peripheral procedures for TN, alcohol injection can cause local edema, dysesthesia, and necrosis with the surrounding tissues with a risk of pain recurrence.<sup>[35]</sup> Despite radiofrequency thermocoagulation usually provides longer pain-free interval than the peripheral procedures, yet moderate dysesthesia in 5%–25% of patients, anesthesia dolorosa occurring in 1%–5%, keratitis in 1%–3%, and very low mortality rate are among the possible complications.<sup>[36]</sup> Recurrences may also occur after MVD, although the time interval appears to be much longer. Its major complications included deaths (0.2%), brain-stem infarction (0.1%), and ipsilateral hearing loss (1%).<sup>[29]</sup>

There are trials for advancement in the technique of peripheral neurectomy for TN. In a recent study, Ward *et al.* described a technique for endoscopic microdissection of the infraorbital nerve in two patients with medically refractory V2 TN localized to the lateral midface and concluded that infraorbital microdissection is a safe and effective technique for symptomatic management of V2 TN while sparing sensation in asymptomatic portions of the dermatome.<sup>[37]</sup> Huang *et al.* concluded that endoscope-assisted neurectomy and avulsion of the inferior alveolar nerve is effective in pain relief in patients with TN involving the mandibular division, with limited invasiveness and speedy recovery.<sup>[38]</sup>

Peripheral neurectomy is recommended to do for the patients with TN who are refractory to medical treatment, refuse, or are unfit for major neurosurgical interventions; providing short to medium-term good pain control. It is a simple, safe, and effective procedure for the treatment of TN.

The limitations of this study include that it is a retrospective one with a relatively small number of patients. Prospective studies with a larger sample size with more concern about the quality of the life of the patients following peripheral neurectomy for TN are recommended to authenticate the results.

## Conclusion

Peripheral neurectomy provides short to medium-term good pain control for patients with TN. The preoperative severity

of pain, anxiety, and depression levels improved markedly after the procedure.

### Declaration of patient consent

The authors certify that they have obtained all appropriate patient consent forms. In the form the patient(s) has/have given his/her/their consent for his/her/their images and other clinical information to be reported in the journal. The patients understand that their names and initials will not be published and due efforts will be made to conceal their identity, but anonymity cannot be guaranteed.

### Financial support and sponsorship

Nil.

### Conflicts of interest

There are no conflicts of interest.

### References

- Okeson JP. The classification of orofacial pains. *Oral Maxillofacial Surg Clin N Am* 2008;20:133-44.
- Jeyaraj P. Efficacy of peripheral neurectomy in the management of refractory cases of trigeminal neuralgia. *Otolaryngology* 2019;8:178.
- Koopman JS, Dieleman JP, Huygen FJ, de Mos M, Martin CG, Sturkenboom MC. Incidence of facial pain in the general population. *Pain* 2009;147:122-7.
- Scrivani SJ, Mathews ES, Maciewicz RJ. Trigeminal neuralgia. *Oral Surg Oral Med Oral Pathol Oral Radiol Endod* 2005;100:527-38.
- Yuvaraj V, Krishnan B, Therese BA, Balaji TS. Efficacy of neurectomy of peripheral branches of the trigeminal nerve in trigeminal neuralgia: A critical review of the literature. *J Maxillofac Oral Surg* 2019;18:15-22.
- Sillanpää M. Carbamazepine. *Pharmacology and clinical uses. Acta Neurol Scand Suppl* 1981;88:115-9.
- Ong KS, Keng SB. Evaluation of surgical procedures for trigeminal neuralgia. *Anesth Prog* 2003;50:181-8.
- Lamichhane NS, Du X, Li S, Poudel DC. Effectiveness of peripheral neurectomy in refractory cases of trigeminal neuralgia. *J Orofac Sci* 2016;8:86-91.
- Liu JK, Apfelbaum RI. Treatment of trigeminal neuralgia. *Neurosurg Clin N Am* 2004;15:319-34.
- Loh HS, Ling SY, Shanmugasantharam P, Zain R, Yeo JF, Khoo SP. Trigeminal neuralgia. A retrospective survey of a sample of patients in Singapore and Malaysia. *Aust Dent J* 1998;43:188-91.
- Toda EK. Trigeminal neuralgia: Symptoms, diagnosis, classification and related disorders. *Oral Sci Int* 2007;4:1-9.
- Gambeta E, Chichorro JG, Zamponi GW. Trigeminal neuralgia: An overview from pathophysiology to pharmacological treatments. *Mol Pain* 2020;16:1-18.
- Sahoo NK, Thakral A, Deb P, Roy ID. Histopathological evaluation of inferior alveolar neurovascular bundle in cases of trigeminal neuralgia. *J Maxillofac Oral Surg* 2020;19:54-60.
- Jainkittivong A, Aneksuk V, Langlais RP. Trigeminal neuralgia: A retrospective study of 188 Thai cases. *Gerodontology* 2012;29:e611-7.
- Farooq S, Shah A, Hamid R. Idiopathic trigeminal neuralgia: A study of 72 cases. *Int J Appl Dent Sci* 2018;4:282-5.
- Shankland WE 2<sup>nd</sup>. Trigeminal neuralgia: Typical or atypical? *Cranio* 1993;11:108-12.
- Chole R, Patil R, Degwekar SS, Bhowate RR. Drug treatment of trigeminal neuralgia: A systematic review of the literature. *J Oral Maxillofac Surg* 2007;65:40-5.
- Quinn JH. Repetitive peripheral neurectomies for neurogia of second and third divisions of trigeminal nerve. *J Oral Surg* 1965;23:600-8.
- Freemont AJ, Millac P. The place of peripheral neurectomy in the management of trigeminal neuralgia. *Postgrad Med J* 1981;57:75-6.
- Grantham EG, Segerberg LH. An evaluation of palliative surgical procedures in trigeminal neuralgia. *J Neurosurg* 1952;9:390-4.
- Cerovic R, Juretic M, Gobic MB. Neurectomy of the trigeminal nerve branches: Clinical evaluation of an "obsolete" treatment. *J Craniomaxillofac Surg* 2009;37:388-91.
- Khanna JN, Galinde JS. Trigeminal neuralgia. Report of 140 cases. *Int J Oral Surg* 1985;14:325-32.
- Mason DA. Peripheral neurectomy in the treatment of trigeminal neuralgia of the second and third divisions. *J Oral Surg* 1972;30:113-20.
- Agrawal SM, Kambalimath DH. Peripheral neurectomy: A minimally invasive treatment for trigeminal neuralgia. A retrospective study. *J Maxillofac Oral Surg* 2011;10:195-8.
- Chandan S, Halli R, Sane VD. Peripheral neurectomy: Minimally invasive surgical modality for trigeminal neuralgia in Indian population: A retrospective analysis of 20 cases. *J Maxillofac Oral Surg* 2014;13:295-9.
- Shah SA, Khattak A, Shah FA, Khan Z. The role of peripheral neurectomies in the treatment of trigeminal neuralgia in modern practice. *Pak Oral Dent J* 2008;28:237-40.
- Murali R, Rovit RL. Are peripheral neurectomies of value in the treatment of trigeminal neuralgia? An analysis of new cases and cases involving previous radiofrequency gasserian thermocoagulation. *J Neurosurg* 1996;85:435-7.
- Zakrzewska JM. Cryotherapy for trigeminal neuralgia: A 10 year audit. *Br J Oral Maxillofac Surg* 1991;29:1-4.
- Barker FG, Jannetta PJ, Bissoneete DJ, Larkins MV. The long-term outcome of microvascular decompression for trigeminal neuralgia. *N Eng J Med* 1996;334:1077-83.
- Sung RR. Peripheral neurectomy as treatment for incipient trigeminal neuralgia. *Oral Surg Oral Med Oral Pathol* 1951;4:296-302.
- Stokvis A. Surgical management of painful neuromas. In: *Nederlands Tijdschrift Voor Geneeskunde. Netherlands, Rotterdam: Optima Grafische Communicatie; 2010. p. 160.*
- Love S, Coakham HB. Trigeminal neuralgia: Pathology and pathogenesis. *Brain* 2001;124:2347-60.
- Ali FM, Prasant M, Pai D, Aher VA, Kar S, Safiya T. Peripheral neurectomies: A treatment option for trigeminal neuralgia in rural practice. *J Neurosci Rural Pract* 2012;3:152-7.
- Hong-Sai L. Surgical treatment of trigeminal neuralgia. *J Oral Rehabil* 1999;26:613-7.
- Nurmikko TJ, Eldridge PR. Trigeminal neuralgia – Pathophysiology, diagnosis and current treatment. *Br J Anaesth* 2001;87:117-32.
- Brisman R. Complications of intracranial pain surgery. 188 procedures for trigeminal neuralgia. *Anesth Prog* 2003;50:181-8.
- Ward M, Majmundar N, Mammis A, Paskhover B. Endoscopic infraorbital microdissection for localized v2 trigeminal neuralgia. *J Oral Maxillofac Surg* 2020;78:374.e1-7.
- Huang D, Zhu S, Guo J, Chen S. Endoscope-assisted neurectomy and inferior alveolar nerve avulsion in treating trigeminal neuralgia. *J Craniomaxillofac Surg* 2017;45:1531-4.