

Left atrial appendage thrombosis during therapy with rivaroxaban in elective cardioversion for permanent atrial fibrillation

Walter Serra,¹ Mauro Li Calzi,¹
Paolo Coruzzi²

¹Department of Cardiology, University Hospital of Parma; ²Don Gnocchi Foundation, University of Parma, Italy

Abstract

Electric external cardioversion (EEC) for permanent atrial fibrillation (AF) carries a risk of thromboembolic events (TE). The use of transesophageal echocardiography (TEE) to guide the management of atrial fibrillation may be considered a clinically effective alternative strategy to conventional therapy for patients in whom elective cardioversion is planned. Therapeutic anticoagulation with novel oral anticoagulants (NOAC) is recommended for 3 to 4 weeks before and an anticoagulation life-long therapy is recommended after EEC to reduce TE, in patients with high CHA₂DS₂-VASc score; however, only few data are currently available about safety of short-term anticoagulation with NOAC in the setting of EEC. Patients with increased risk of thromboembolism have not been adequately studied and the monitoring of anticoagulant effects can also have important benefits in case of drug interactions. We report a case of a 68-year old man with AF from September 2014. Moderate depression of global left ventricular systolic function was detected by echocardiographic exam. On the basis of a high thromboembolic risk, an anticoagulant therapy with rivaroxaban, at the dose of 20 mg/day, was started. TEE showed a thrombus in the left atrial appendage. This case demonstrates the utility of performing TEE prior than EEC in patients with hypokinetic cardiomyopathy other than AF in therapy with NOAC. We underline the presence of significant pharmacodynamic interference of rivaroxaban with other drugs such as oxcarbazepine.

Introduction

Electric external cardioversion (EEC) for permanent atrial fibrillation or atrial flutter (AF) carries a risk of thromboembolic events (TE). The use of transesophageal echocardiography to guide the management of atrial fibril-

lation may be considered a clinically effective alternative strategy to conventional therapy for patients in whom elective cardioversion is planned. Therapeutic anticoagulation with vitamin K-antagonists (VKA) or novel oral anticoagulants (NOAC) is recommended for 3 to 4 weeks before and 4 weeks after EEC to reduce TE;¹⁻³ however, only few data are currently available about safety of short-term anticoagulation with the NOAC (dabigatran, rivaroxaban, apixaban and edoxaban) in the setting of EEC.

Case Report

A 68-year old man was found to have permanent AF in September 2014. He was symptomatic for fatigue and dyspnea. In his medical history he had arterial hypertension, diabetes mellitus and past episodes of seizures in treatment with oxcarbazepine.

The echocardiographic exam showed: moderate depression of global left ventricular systolic function (38%), atrial enlargement and mild mitral regurgitation. The main laboratory tests (including hemochrome, coagulation, hepatic, renal and thyroid function) were normal. On the basis of a high thromboembolic risk (CHA₂DS₂-VASc score=4), an anticoagulant therapy with rivaroxaban, at the dose of 20 mg/day, was started.

After 6 weeks of treatment with rivaroxaban, in prevision of an EEC of AF, it was performed a TEE, which showed a thrombus in the left atrial appendage and low auricular flow rate (Figure 1 and Video 1).

EEC was not performed and the anticoagulation therapy was empirically shifted from rivaroxaban to warfarin (with a therapeutic target of international normalized ratio of 2-3). A TEE was repeated after six more weeks and demonstrated the complete resolution of the thrombus.

Discussion and Conclusions

The X-VERT⁴ study enrolled adult patients, who were hemodynamically stable and had non-valvular atrial fibrillation >48 h or of unknown duration, and who were scheduled for either electrical or pharmacologic cardioversion. The trial randomized 1504 non-valvular atrial fibrillation patients undergoing elective cardioversion to rivaroxaban (20 mg once daily, 15 mg if creatinine clearance was between 30 and 49 mL/min) or dose-adjusted VKAs in a 2:1 ratio. Patients were also assigned to either an early (1-5 days) or delayed (3-8 weeks) cardioversion strategy. Among these patients, 0.51% in the rivaroxa-

Correspondence: Walter Serra, Department of Cardiology, University Hospital of Parma, Strada pedemontana 3, 43010 Pilastro di Langhirano (PR), Italy.
Tel.: +39.0521.702070 - Fax: +39.0521.702189.
E-mail: wserra@libero.it

Key words: Rivaroxaban; transesophageal echocardiography; atrial fibrillation; pharmacological interference.

Conflict of interest: the authors declare no potential conflict of interest.

Received for publication: 17 May 2015.

Revision received: 3 July 2015.

Accepted for publication: 31 July 2015.

This work is licensed under a Creative Commons Attribution NonCommercial 3.0 License (CC BY-NC 3.0).

©Copyright W. Serra et al., 2015
Licensee PAGEPress, Italy
Clinics and Practice 2015; 5:788
doi:10.4081/cp.2015.788

ban group experienced primary efficacy events - stroke, transient ischemic attack, peripheral embolism, myocardial infarction or cardiovascular death - compared to 1.02% in the VKA group. The percentage of primary efficacy events following early cardioversion was somewhat similar across both groups, with 0.71% of rivaroxaban patients and 1.08 percent of VKA patients experiencing events. In terms of major bleeding, results were similar across both groups with 0.6% of rivaroxaban patients and 0.8% of VKA patients experiencing bleeding events.

In another retrospective cohort study,⁵ Ajay Yadlapati and coll. showed that the use of short-term dabigatran or rivaroxaban therapy for EEC of AF appears safe. No patients were found to have episodes of TE within 60 days of EEC. No patients were found to have major bleeding events.

Some studies have addressed this issue, but populations with increased risk of thromboembolism or with left ventricular dysfunction have not been adequately studied and the monitoring of anticoagulant effects can also have important benefits in case of drug interactions.

In this case we underline the presence of significant pharmacodynamic interference of rivaroxaban with other drugs such as oxcarbazepine. This drug is in fact a strong inducer of the CYP3A4 enzyme, which is important for degradation of rivaroxaban.⁶ So, although the main advantage of NOAC compared to VKA is the fact that routine monitoring of the anticoagulant effects does not seem necessary, this can have important clinical benefits in case of

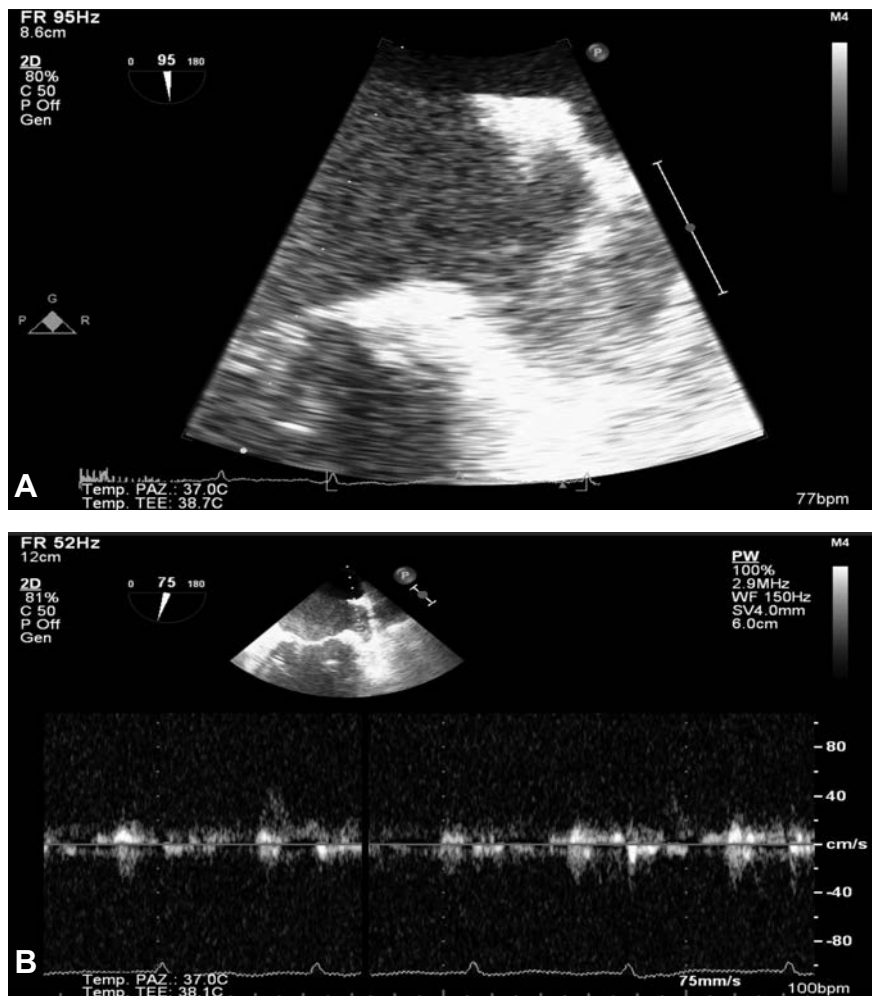


Figure 1. A) Trans-esophageal echocardiogram (TEE) showing a thrombus in the left atrial appendage and low auricular flow; B) TEE showing a low auricular flow.

drug interactions. The choice of rivaroxaban in this patient was probably wrong, and this drug should be used by a careful drug concentration monitoring. However, this kind of testing is not currently disposable in our center. In this case, as we demonstrated, it is very useful performing TEE prior than EEC.

However, an anticoagulation life-long therapy after EEC to reduce TE, in patients with CHA_2DS_2 -VASc score=4, should be suggested.

Learning objective

The main learning objective is a *warning* to a treatment with rivaroxaban (NOA) with other drugs inducer of the CYP3A4 enzyme, which is important for degradation of rivaroxaban, in atrial fibrillation for an EEC, in patients with left heart dysfunction, in patients with high CHA_2DS_2 -VASc score, without performing TEE.

Video

See the online video associated to this case report.

Video 1: Trans-esophageal echocardiogram showing a thrombus in the left atrial appendage and smoke in left atrial cavities.

References

1. Klein AL, Grimm RA, Murray RD, et al. Use of transesophageal echocardiography to guide cardioversion in patients with atrial fibrillation. *N Engl J Med* 2001;344:1411-20.
2. Camm AJ, Kirchhof P, Lip GYH, et al. Guidelines for the management of atrial fibrillation: The Task Force for the Management of Atrial Fibrillation of the European Society of Cardiology (ESC). *Eur Heart J* 2010;31:2369-429.
3. Fuster V, Rydén LE, Cannom DS, et al. 2011 ACCF/AHA/HRS focused updates incorporated into the ACC/AHA/ESC 2006 guidelines for the management of patients with atrial fibrillation: a report of the American College of Cardiology Foundation/American Heart Association Task Force on Practice Guidelines. *Circulation* 2011;123:e269-367.
4. Ezekowitz MD, Cappato R, Klein AL, et al. Rationale and design of the eXplore the efficacy and safety of once-daily oral rivaroxaban for the prEvention of cardiovascular events in patients with nonvalvular atrial fibrillation scheduled for cardioversion trial: A comparison of oral rivaroxaban once daily with dose-adjusted vitamin K antagonists in patients with nonvalvular atrial fibrillation undergoing elective cardioversion X-Vert study. *Am Heart J* 2014;167:646-52.
5. Yadlapati A, Groh G, Passman R. Safety of short-term use of dabigatran or rivaroxaban for direct-current cardioversion in patients with atrial fibrillation and atrial flutter. *Am J Cardiol* 2014;113:1362-3.
6. Xarelto (rivaroxaban) US prescribing information. Janssen Pharmaceuticals, Inc. March, 2014.