

Scientific Article

Moderately Hypofractionated Radiation for Benign Meningiomas and Schwannomas: A Report of 70 Patients Treated Between 2008 and 2018



Vishal R. Dhere, MD,^{a,*} Sibo Tian, MD,^a Zachary Buchwald, MD, PhD,^a Xiaojun Jiang, PhD,^a Chao Zhang, PhD,^b Zhengjia Chen, PhD,^b Bree R. Eaton, MD,^a Hui-Kuo G. Shu, MD, PhD,^a Walter J. Curran, MD,^a and Jim Zhong, MD^a

^aDepartment of Radiation Oncology, Emory University, Winship Cancer Institute, Atlanta, Georgia; and ^bDepartment of Biostatistics, Emory University, Winship Cancer Institute, Atlanta, Georgia

Received 22 June 2020; revised 28 August 2020; accepted 14 September 2020

Abstract

Purpose: Radiosurgery and fractionated intensity modulated radiation therapy (IMRT) are effective treatment modalities for meningiomas and schwannomas. Although fractionated IMRT yields favorable tumor control, daily treatments for 5 to 6 weeks can be burdensome for patients and health care systems. Thus, hypofractionated radiation may be a reasonable alternative. The purpose of this study was to review the results of patients with benign meningiomas or schwannomas treated at our institution with moderately hypofractionated IMRT.

Methods and Materials: After institutional review board approval, patients treated at a single academic institution between 2008 and 2018 with a primary diagnosis of either meningioma or schwannoma and who received 30 Gy at 3 Gy per fraction were identified. Patient and tumor characteristics, as well as follow-up documentation, were reviewed. Tumor progression was determined by reviewing patient imaging and provider notations.

Results: From 2008 to 2018, 70 patients with either meningioma or schwannoma were treated to 30 Gy. The median patient age was 73 years (range, 43-92 years). At the median follow up of 3.2 years, the local control was 92.9%. Two patients (2.9%) had disease progression, which occurred at 9.6 and 6.6 years after treatment. One patient developed asymptomatic radiographic changes consistent with radiation necrosis, which resolved without intervention. All patients completed the prescribed course without interruption. The mean tumor volume was 18.9 cm³, median volume was 36.6 cm³ (range, 3.4-245.5 cm³), and tumor volume was not associated with recurrence risk. Both tumors with progression were schwannomas.

Conclusions: Hypofractionated radiation with 30 Gy at 3 Gy per fraction is an effective, convenient, and well-tolerated alternative for patients with benign meningiomas or schwannomas. Modest hypofractionation provided durable control for a wide range of tumor volumes and should be considered for patients with a limited life expectancy or those unable to receive a more extended fractionated radiation therapy course.

© 2020 The Authors. Published by Elsevier Inc. on behalf of American Society for Radiation Oncology. This is an open access article under the CC BY-NC-ND license (<http://creativecommons.org/licenses/by-nc-nd/4.0/>).

Introduction

Meningiomas and schwannomas are benign tumors of the central nervous system (CNS). These tumors account for up to one-third of intracranial neoplasms, and >90% of these tumors are benign on pathologic analysis.¹ Definitive treatment for these tumors is often considered

Sources of support: No external funding sources to disclose.

Disclosures: The authors have no pertinent conflicts of interest.

* Corresponding author: Vishal Dhere, MD; E-mail: vdhere@emory.edu

<https://doi.org/10.1016/j.adro.2020.09.009>

2452-1094/© 2020 The Authors. Published by Elsevier Inc. on behalf of American Society for Radiation Oncology. This is an open access article under the CC BY-NC-ND license (<http://creativecommons.org/licenses/by-nc-nd/4.0/>).

due to symptomatic burden or interval increase in size. Both symptomatic burden and rate of growth influence management decisions. Radiation therapy (RT) can be used as a primary treatment modality or after surgical resection as indicated.

Radiation to meningiomas and schwannomas can be delivered as single-fraction stereotactic radiosurgery (SRS) or fractionated stereotactic radiation depending on the tumor size and location relative to critical organs at risk. In general, patients can be divided into 3 groups of fractionation: SRS (≤ 5 fractions), fractionated radiation (≥ 25 fractions), and moderately hypofractionated radiation.

For tumors not amenable to radiosurgery, fractionated RT is an alternative option that provides excellent local control. However, conventional fractionation requires 5 to 6 weeks of daily radiation, which can lead to financial toxicity and patient inconvenience, especially for the elderly. Consequently, having a fractionated radiation treatment available to patients who are not candidates for radiosurgery would be ideal.

Previous reports have suggested that a lower biologically effective dose (BED) may be sufficient to control these benign tumors due to a lower alpha/beta ratio.¹ Although multifraction radiosurgery regimens have been reported, there have been no significant reports of moderately hypofractionated treatment.¹⁻⁸ The purpose of this study was to review single-institution local control and toxicity outcomes of patients with meningiomas or schwannomas treated with a moderately hypofractionated radiation regimen.

Methods and Materials

After institutional review board approval, our institutional radiation treatment planning database was queried for patients with a primary diagnosis of either meningioma or schwannoma who had received 30 Gy at 3 Gy per fraction. This fractionation was typically offered to either elderly patients (age >65 years) or those with travel limitations precluding daily treatment for 5 to 6 weeks that is standard with a conventionally fractionated approach. In addition to patients with a limited life expectancy, moderate hypofractionation was also used for larger volume tumors with an increased risk for toxicity to critical structures, such as the brain stem or optic structures, which precludes the use of single- or multifraction treatments.

Patients were treated using intensity modulated RT. All patients underwent computed tomography (CT) simulation after the creation of a thermoplastic head mask for daily immobilization. CT simulation images were registered to magnetic resonance images (MRIs) with and without contrast using Velocity (Varian Medical Systems, Palo Alto, CA). Gross target volume was defined as the

gross enhancing tumor on postcontrast isotropic 3-dimensional MRIs. Clinical target volume incorporated the risk of subclinical disease extension and used an expansion of 2 mm in most cases (range, 0-5 mm). The planning target volume, incorporating setup uncertainty, was generally 3 mm (range, 1-3 mm). On-board imaging was used daily for setup confirmation.

Medical records were reviewed for patient baseline demographic information and tumor characteristics such as tumor site and volume. Additional clinical outcomes, such as tumor control and treatment toxicities, were retrospectively reviewed. Toxicities were graded based on the Common Terminology Criteria for Adverse Events, version 4.03.⁹

Patients returned for follow up 1 month after RT with a brain MRI with and without contrast. Follow up, consisting of a brain MRI and a history and physical examination, occurred every 6 to 9 months for the first 3 years and annually thereafter. Tumor progression was determined by a review of patient imaging, need for additional therapy, and provider notation. The presence of radiation necrosis was based on MRI radiology reports. Patients without evidence of a recurrence or death were censored at the time of the last follow up and not counted as events in the progression-free survival analysis. Tumor volume changes were calculated by the minimum cross-sectional tumor length change between treatment planning and the most recent follow-up image.

Statistical analysis

The descriptive statistics for each variable were reported. For numeric covariates, the median and range were calculated and presented, and frequency and its percentage are shown for categorical variables. A Kaplan-Meier curve is presented for progression-free survival. The statistical analysis was conducted using SAS, version 9.4.

Results

Between 2008 and 2018, 70 patients with meningiomas or schwannomas who received moderate hypofractionation were identified. All 70 patients received moderately fractionated intensity modulated RT with 30 Gy at 3 Gy per fraction. Sixty-four patients were treated in the definitive setting and 6 patients in an adjuvant setting. No patients had received prior radiation, and no patients were treated in the salvage setting. There were no differences in outcomes in adjuvant- versus definitively treated patients.

The group consisted of 60% meningiomas and 40% schwannomas. Patient baseline characteristics are listed in [Table 1](#). The median age at the time of radiation was 73 years (range, 43-92 years), and most patients were

Table 1 Patient and tumor pretreatment characteristics

Median age, years (range)	72 (56-92)
Sex, n (%)	43 female (61) 27 male (39)
Eastern Cooperative Oncology Group score, n (%)	ECOG 0: 14 (20) ECOG 1: 47 (67) ECOG 2: 6 (9) ECOG 3: 3 (4)
Meningioma, n (%); VS, n (%)	40 (57) 30 (43)
Median tumor size, cm ³ (range)	36.6 (3.1-245.5)
Prior resection, n (%)	6 (9)
Symptomatic, n (%)	69 of 70 (97)

Abbreviations: ECOG = Eastern Cooperative Oncology Group; VS = Vestibular Schwannoma.”

symptomatic at the time of presentation. The mean tumor volume was 18.9 cm³ and median volume was 36.6 cm³ (range, 3.4-245.5 cm³). Most patients did not have a prior biopsy or surgical resection. Of the 6 patients (8%) who had a surgical resection before radiation, pathology testing confirmed World Health Organization grade 1 tumors in all cases. The median number of follow up MRI scans was 5 (range, 1-9).

Ninety-three percent of our population was age ≥60 years and 61% was age ≥70 years at the time of treatment. Uncommonly, this schedule was used in younger patients, such as age 43 years, who were treated for a 100 cm³ tumor bordering the optic apparatus and who lived a substantial distance from the treatment center.

Local control and survival

At the median follow up of 3.2 years, the local control rate was 92.9% (Fig 1). The median follow up of 3.2 years included both clinical and radiographic follow up. The local control at 3, 5, and 8 years was 100.0%, 100.0%, and 92.9%, respectively (confidence interval [CI], 59.1%-99.0%). Meningioma location was diverse

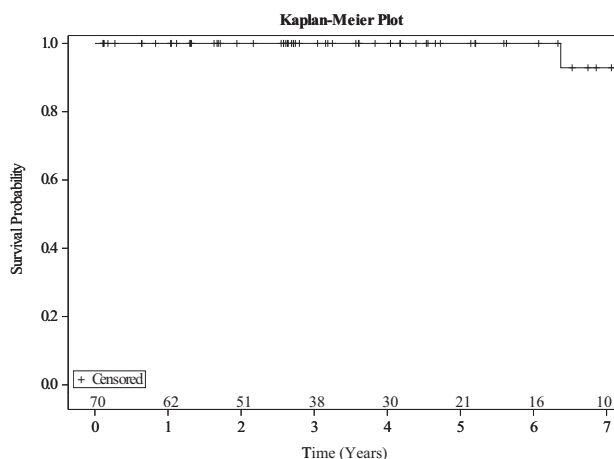


Figure 1 K-M curve for progression-free survival.

including cavernous sinus, cerebellopontine angle, sphenoid wing, as well as others (Table 2). Vestibular schwannomas were the most common with respect to anatomic location (Table 2). Two patients had disease progression, and the time from radiation treatment until progression was 9.6 years and 6.6 years. Both tumors that progressed were schwannomas. After progression, 1 patient was offered microsurgical resection while the other had asymptomatic progression and was observed. Post-treatment tumor volume decrease was uncommon: <10% of patients had >25% volume decrease (Table 2). All patients completed the prescribed course without interruption.

The overall survival data mirrored the local control data, except for a single patient who passed at our center from a comorbid condition. Many patients were treated as community referrals and were lost to follow up or only seen for interval follow up of their brain tumors.

Toxicity, symptom, and size response

Treatment was well tolerated with most patients experiencing grade 1 to 2 side effects, including fatigue, headache, or nausea (Table 2). One patient (1.4%) developed asymptomatic radiographic changes consistent with grade 1 radiation necrosis, which resolved without intervention. Three patients experienced grade 3 fatigue that resolved without intervention.

Ninety-seven percent of patients were symptomatic at the time of presentation with a variety of presenting symptoms, including grade ≤2 hearing loss or balance difficulties (60%), visual changes (15%), and trigeminal pain (15%). Three patients (5%) presented with seizures, and although none of the patients had a seizure recurrence, they remained on antiepileptic treatments throughout the follow up. One patient developed worsening of symptoms related to tumor recurrence, but the remainder of patients had stable or marginally improved symptoms. Of the patients who presented with trigeminal-related pain (15%), no changes in pharmacologic therapy was noted. Unfortunately, no objective measures were assessed, such as baseline hearing or balance testing. Five patients had a decrease in tumor size of ≥25%, and most size changes occurred within the first 3 years.

Discussion

This study demonstrated effective local control with the use of moderately hypofractionated radiation for benign CNS tumors. This finding is supported by the relatively large single-institution cohort described and with adequate follow up for an elderly population with a limited life expectancy. Additionally, a variety of tumor locations and sizes were amenable to treatment with this regimen. Although originally used to

Table 2 Tumor sites, treatment planning, toxicity, and volume change

Meningioma location (n = 40)	Sphenoid wing	9
	Cerebellopontine angle	9
	Cavernous sinus	6
	Other	16
Schwannoma location (n = 30)	Vestibular	26
	Trigeminal	3
	Facial	1
Adverse effects, n (%) [*]	Fatigue grades 1-2	48 (69)
	Fatigue grade 3	2 (3)
	Nausea grade 1	10 (14)
	Headache grade 1	10 (14)
	Radiation necrosis grade 1	1 (1)
Clinical target volume margin, mm (%)	0	10 (14)
	2	27 (39)
	3	22 (31)
	5	9 (13)
Volume change, decrease, n (%)	Stable	65 (93)
	≥25%	5 (7)

* Common Terminology Criteria for Adverse Events, version 4.03

maximize convenience for elderly patients, the regimen also capitalizes on the radiobiologic advantage of hypofractionation.

Numerous publications have previously reported a low BED for benign CNS tumors. One study by Vernimmen et al. investigated this ratio for both meningiomas and vestibular schwannomas through the use of fractionation equivalent plots and Tucker calculations incorporating previously published studies that cover a variety of conventionally and hypofractionated radiation schedules.¹ The researchers identified an alpha/beta ratio of 3.3 Gy to 3.7 Gy for meningioma and 1.8 Gy to 2.4 Gy for acoustic neuroma. These values are congruent with other published literature.^{2,10-12} Given an alpha/beta ratio of 3, a schedule of 30 Gy at 3 Gy per fraction delivers a BED of 60 Gy. This is comparable to a schedule of 25 Gy at 5 Gy per fraction that delivers a BED of 66.67 Gy.

The control rate we observed using moderately hypofractionated radiation was similar to other series, our median tumor volume was significantly larger, and our side effect burden was lower. Flickinger et al. reported on the single-fraction treatment of 219 benign meningiomas using gamma-knife SRS, and found a control rate of 93% at 5 and 10 years with a median treatment volume of 5.0 cm³ (range, 0.47-56.5 cm³). However, the researchers also encountered actuarial post-SRS injury in 8.8% of patients with an increased risk of injury correlating with larger tumor volumes, which is similar as shown in other published reports.¹³⁻¹⁶ Pollock reported on 356 meningiomas treated with single-fraction SRS, found a control rate of 94% at the median follow up of 3.5 years, and noted a median tumor volume of 7.3 cm³ (range, 0.5-50.5 cm³) and treatment-related complication rate of 8%.¹⁷ Similarly, Vernimmen reported on 18 skull

meningiomas treated with a 3-fraction course of proton radiation, and found a control rate of 88% with a mean target volume of 15.6 cm³ (range, 2.6-63 cm³).¹⁸ Publications of hypofractionated regimens have reported similar rates of control (>90%), but with a limited range of tumor volumes (<75 cm³).^{4,11,19-24} In the context of these studies, our findings support a similar efficacy of moderately hypofractionated radiation for larger tumor volumes (up to 245 cm³) and those near critical structures.

In addition to convenience, tolerance, and radiobiologic advantages, this regimen could also decrease health care-associated costs of treatment. With the advent of advanced payment models, the capacity to deliver hypofractionated radiation for a variety of tumor sizes and locations will be critical. As shown in prostate cancer, where a shift from 44 to 20 treatment days decreased treatment-associated costs by 50%,²⁵ the ability to move from 30 to 10 treatments for benign meningiomas and schwannomas could have a similar impact.

The limitations of our study include a lack of objective symptomatic measures at the time of diagnosis and follow up, limited long-term follow up in an elderly patient population, and problems inherent to a retrospective analysis, such as selection bias. In particular, longer follow up is critical in evaluating meningioma treatment regimens based on the capacity for recurrence at ≥10 years after treatment.²⁶ Given the elderly population we evaluated, patients could have died from comorbid conditions before evidence of tumor progression. Despite these limitations our study provides substantial evidence for moderately hypofractionated radiation from a sizeable single-institution cohort. Additionally, given the age of our study population, a follow-up of 3 years supports the use of this regimen in patients with multiple comorbid

conditions and a limited life expectancy. We believe this study supports further multi-institutional investigation in prospective trials to confirm its efficacy and safety for a variety of tumor sizes and locations.

Conclusions

A moderately hypofractionated regimen of 30 Gy at 3 Gy per fraction was efficacious and well tolerated in this sizeable single-institution cohort. This regimen allowed for the treatment of large tumors, especially those that bordered the brain stem or other critical structures. This regimen should be considered for patients with a limited life expectancy or for whom fully fractionated radiation regimens are too tedious.

References

- Vernimmen FJAI, Slabbert JP. Assessment of the alpha/beta ratios for arteriovenous malformations, meningiomas, acoustic neuromas, and the optic chiasma. *Int J Radiat Biol*. 2010;86:486-498.
- Shrieve DC, Hazard L, Boucher K, Jensen RL. Dose fractionation in stereotactic radiotherapy for parasellar meningiomas: Radiobiological considerations of efficacy and optic nerve tolerance. *J Neurosurg*. 2004;101:390-395.
- Flannery TJ, Kano H, Lunsford LD, et al. Long-term control of petroclival meningiomas through radiosurgery. *J Neurosurg*. 2010;2010:957-964.
- Lee JYK, Niranjan A, McNerney J, Kondziolka D, Flickinger JC, Lunsford LD. Stereotactic radiosurgery providing long-term tumor control of cavernous sinus meningiomas. *J Neurosurg*. 2002;2002:65-72.
- McTyre E, Helis CA, Farris M, et al. Emerging indications for fractionated gamma knife radiosurgery. *Neurosurgery*. 2017;2017(2):210-216.
- Murphy ES, Suh JH. Radiotherapy for vestibular schwannomas: A critical review. *Int J Radiat Biol Phys*. 2011;2011:985-997.
- Sheehan JP, Starke RM, Kano H, et al. Gamma knife radiosurgery for sellar and parasellar meningiomas: A multicenter study. *J Neurosurg*. 2014;2014:1268-1277.
- Zhong J, Press RH, Olson JJ, Oyesiku NM, Shu HG, Eaton BR. The use of hypofractionated radiosurgery for the treatment of intracranial lesions Unsuitable for single-fraction radiosurgery. *Neurosurgery*. 2018;83(5):850-857.
- U.S. Department of Health and Human Services. Common Terminology Criteria for Adverse Events, version 4.03. Available at: https://ctep.cancer.gov/protocoldevelopment/electronic_applications/docs/CTCAE_v5_Quick_Reference_5x7.pdf. Accessed October 28, 2020.
- Gross MW, Hamm K, Henzel M, Surber G, Kleinert G, Engenhart-Cabillic R. Alpha/beta ratios for tumor shrinkage after fractionated and single-dose irradiation for neuromas and meningiomas. *Strahlenther Onkol*. 2007;79:288.
- Henzel M, Gross MW, Hamm K, Surber G, Kleinert G, Failing T, et al. Stereotactic radiotherapy of meningiomas: Symptomatology, acute and late toxicity. *Strahlenther Onkol*. 2006;7:382-388.
- Linskey M. Stereotactic radiosurgery versus stereotactic radiotherapy for patients with vestibular schwannoma: A Leksell Gamma Knife Society 2000 debate. *J Neurosurg*. 2000;93:90-95.
- Chang JH, Chang JW, Choi JY, Park YG, Chung SS. Complications after gamma knife radiosurgery for benign meningiomas. *J Neurol Neurosurg Psychiatry*. 2003;74:226-230.
- Chin LS, Ma L, DiBiase S. Radiation necrosis following gamma knife surgery: A case-controlled comparison of treatment parameters and long-term clinical follow up. *J Neurosurg*. 2001;94:899-904.
- Flickinger JC, Kondziolka D, Maitz AH, Lunsford LD. Gamma knife radiosurgery of imaging-diagnosed intracranial meningioma. *Int J Radiat Biol Phys*. 2003;56:801-806.
- Blonigen BJ, Steinmetz RD, Levin L, Lamba MA, Warnick RE, Breneman JC. Irradiated volume as a predictor of brain radionecrosis after linear accelerator stereotactic radiosurgery. *Int J Radiat Biol Phys*. 2010;77:996-1001.
- Pollock B. Stereotactic radiosurgery for intracranial meningiomas: Indications and results. *Neurosurg Focus*. 2003;14:4.
- Vernimmen FJ, Harris JK, Wilson JA, Melvill R, Smit BJ, Slabbert JP. Stereotactic proton beam therapy of skull base meningiomas. *Int J Radiat Biol Phys*. 2001;49:99-105.
- Conti A, Pontoriero A, Midili F, et al. CyberKnife multisession stereotactic radiosurgery and hypofractionated stereotactic radiotherapy for petrioptic meningiomas: Intermediate-term results and radiobiological considerations. *Springerplus*. 2015;4:37.
- Colombo F, Casentini L, Cavedon C, Scalchi P, Cora S, Francescon P. CyberKnife radiosurgery for benign meningiomas: Short-term results in 199 patients. *Neurosurgery*. 2009;64:A7-A13.
- Kondziolka D, Lunsford LD, McLaughlin MR, Flickinger JC. Long-term outcomes after radiosurgery for acoustic neuromas. *N Engl J Med*. 1998;339:1426-1433.
- Mahadevan A, Floyd S, Wong E, Chen C, Kasper E. Clinical outcome after hypofractionated stereotactic radiotherapy (HSRT) for benign skull base tumors. *Comput Aided Surg*. 2011;16:112-120.
- Roche PH, Pellet W, Fuentes S, Thomassin JM, Régis J. Gamma knife radiosurgical management of petroclival meningiomas results and indications. *Acta Neurochir (Wien)*. 2003;145:883-888.
- Wegner RE, Hasan S, Abel S, et al. Linear accelerator-based stereotactic radiotherapy for low-grade meningiomas: Improved local control with hypofractionation. *J Cent Nerv Syst Dis*. 2019;11:1179573519843880.
- Moore A, Stav I, Den RB, et al. The financial impact of hypofractionated radiation for localized prostate cancer in the United States. *J Oncol*. 2019;2019:8170428.
- Jääskeläinen J. Seemingly complete removal of histologically benign intracranial meningioma: Late recurrence rate and factors predicting recurrence in 657 patients. A multivariate analysis. *Surg Neurol*. 1986;26:461-469.