

Evaluations of Computed Tomography Images and Lumbar Specimens in Mimic Operations of Transverse Rotation Laminoplasty for Lumbar Spinal Stenosis

Xian-Wu Pei¹, Yong-Hui Liang², Hui Zhang¹, Zi-Shun Gong¹, Hong-Xing Song³

¹Department of Orthopedics, Beijing Fangshan District Liangxiang Hospital, Capital Medical University, Beijing 102401, China

²Department of Orthopedics, Chinese People's Liberation Army General Hospital, Beijing 100853, China

³Department of Orthopedics, Beijing Shijitan Hospital, Capital Medical University, Beijing 100038, China

Xian-wu Pei and Yong-hui Liang contributed equally to this work.

Abstract

Background: Laminectomy is a major method to treat lumbar spinal stenosis (LSS), but it has lots of flaws such as scar tissue can form around the dura again or spinal instability. This study aimed to investigate the feasibility of transverse rotation laminoplasty (TRL) in the treatment of LSS.

Methods: The mimic operations of TRL were performed both in the computerized image processing and on the lumbar specimen. Computed tomography (CT) images were either collected from 80 clinical patients with complaints of lumbago or obtained from 40 sets of lumbar specimens after rebuild of spinal canals. In the CT image processing the heights of the spinous process and laminae at L3–L5 were measured. The total length of the spinous process plus one side laminae after the operation was evaluated and compared with the length of inner margin of pedical before the operation. The areas of the vertebral canal were examined before and after the operation.

Results: In the CT images, the height of spinous process of L3, L4 and L5 was 24.74 ± 3.45 , 22.68 ± 5.96 and 21.54 ± 4.12 mm respectively, and that of laminae was 23.66 ± 2.32 , 22.68 ± 5.36 and 20.99 ± 3.67 mm respectively ($P > 0.05$). Distance of inner border of pedical of L3, L4 and L5 was 23.01 ± 6.59 , 24.65 ± 5.54 and 26.03 ± 7.34 mm respectively, and length of spinous process with laminae of those was 29.76 ± 4.91 , 29.31 ± 6.43 and 32.53 ± 5.76 mm respectively ($P < 0.05$). Preoperative area of spinal canals of L3, L4 and L5 was 299.81 ± 10.09 , 297.66 ± 9.54 and 308.22 ± 10.04 mm² respectively, and postoperative area was 480.01 ± 9.33 , 487.32 ± 8.65 and 501.03 ± 9.12 mm² respectively ($P < 0.05$). In the human lumbar vertebrae specimen, the data similar to the former.

Conclusions: The excised canal posterior was covered, and the lumbar canals enlarged by TRL. The TRL provided a new alternative in the treatment of LSS.

Key words: Epidural Adhesion; Laminae; Lumbar Spinal Stenosis; Spinous Process

INTRODUCTION

Lumbar spinal stenosis (LSS) is a complex clinical syndrome resulting from degenerative changes in the lumbar spine. It is usually caused by the slow progressive degenerating process that predominates at the three lower lumbar levels.^[1] Anatomically, degenerative LSS can involve the central canal, lateral recess, foramina or any combination of these locations. The symptom most commonly attributed to LSS is neurogenic claudication. Neurogenic claudication refers to leg symptoms encompassing the buttock, groin, and anterior thigh, as well as radiation down the posterior part of the leg to the feet.

There are many methods to treat LSS.^[2-5] The majority of the patients will respond well to nonoperative treatment modalities. However, for patients who fail to respond to nonsurgical treatment, surgical decompression may be considered.^[6-9] Regarding lateral recess stenosis and lumbar foraminal stenosis, fenestration and micro-endoscopic decompressive laminotomy generally be applied.^[2,3,10,11] However for the central canal stenosis, full lamina need be resected for complete decompression. After extensive laminectomy, due to deficit coverage of dura scar tissue can form around the dural mate, dura and nerve root adhesion and oppression can emerge. Simultaneously, many risks are increased such as spinal instability.^[12,13] This may induce the stenosis of the spinal canal again. The clinical symptoms can recur, implying a deficient of this approach.^[14,15]

Access this article online

Quick Response Code:



Website:
www.cmj.org

DOI:
10.4103/0366-6999.149196

Address for correspondence: Dr. Hong-Xing Song,
Department of Orthopedics, Beijing Shijitan Hospital,
Capital Medical University, Beijing 100038, China
E-Mail: xiansonghongxing@126.com

In order to prevent the formation of hematoma and scar tissue, several laminoplasty have been carried out for LSS.^[16] Restorative laminoplasty was also reported. However, it is difficult to restore the excised laminae precisely. The fixation of the restored laminae was not so rigid that the laminae can be drifted.^[17,18] In addition, the enlargement of the central spinal canal is limited.

Sangwan's technique is a modification of the open-door laminoplasty used for cervical canal stenosis. Its advantage is that it decompresses the nerve roots by expanding the cross-sectional area of the spinal canal without compromising the spinal stability. This avoids neither delayed deformities of the spine nor laminectomy membrane formation postoperatively, but the nerve roots at hinge side cannot be fully decompressed, and flaval ligaments cannot be eliminated thoroughly.^[19]

A scholar reported the application of laminoplasty for intraspinal tumor in the thoracic and lumbar spine and ossification of thoracic ligamentum flavum.^[20] Spinous process and laminae were removed after cutting the juncture between articular process and lamina. After decompression of the intra spine canal, the excised laminae connected with the spinous process were rotated transversely by 90° to rebuild the spinal canal. To the best of our knowledge, the surgical procedure has not been applied for LSS. No image studies and the measurements of spinal specimen have been reported for the laminoplasty.

For the surgical procedure of laminoplasty was performed conveniently, formed dura scar tissue is lower around the dural mate and spinal stability are higher, the present work transverse rotation laminoplasty (TRL) is simulated on the computer. The relevant data are collected. We will observe the coverage of the posterior arch of the spinal canal as well as the enlargement of the canal cross section after the operation. We also perform the surgery on the lumbar specimen and analyze the relevant statistics data, so that theoretical evidence can be obtained for clinical performance of the operation.

METHODS

Measurement on the computed tomography image of the lumbar vertebrae

Patient samples

The 80 studied objects were the patients with low back pains from the hospitals outpatient, the scans were obtained as part of the patients' clinical work-up. Totally 80 computed tomography (CT) images were used, during which 25 cases were males, age 20–61 years old, 34 years old on average, 25 females, 20–63 years old, 36 years old on average.

Methods of computed tomography scan

The CT scanning was carried out using PHILIPS Brilliance 64 row of screw CT (PHILIPS, Inc. USA). Transverse section, sagittal plane and three-dimensional images were obtained at L3, L4 and L5. The image evaluations were performed on the section 2 mm above the pedicle before and after the operation. The thickness of the slice was 0.625 mm × 64 mm.

Thread interval 0.891. Rebuilt slice thickness 0.7 mm. MAS 80–250.

Measure methods and contents

The height of the spinous process and laminae were evaluated on the three-dimensional images directly at the CT. And then the CT images were read into the computer. With the help of image analysis software Photoshop CS5 (Adobe Inc. USA), the lamina was dissected at the medial border of pedicle. The spinous process and laminae were rotated 100° clockwise or counter-clockwise. The spinous process plus one side of laminae were put on the decompressed vertebral canal posterior wall as shown in Figures 1 and 2. And then a cursor was used to trace the landmarks and borders on the CT images at L3-L5 for the Photoshop software could be used to calculate the preoperative distance of inner border of pedical and the area of lumbar canal on the cross section were determined, and the postoperative length of the spinous process plus one side of the laminae and the area of vertebral canal were measured as well. These data was compared each other. Due to hand-made landmarks, so the values are not accuracy absolutely, but reliability is high because the same one works.

The height of the spinous process and laminae: The height of the spinous process and laminae were measured directly in the three dimensional images on the CT. The height of laminae AB is the distance between the upper and the lower border of laminae, determined on the spinous process base. The height of spinous process CD is the distance between the upper and the lower border of spinous process, measured in the middle region [Figures 3 and 4].

The lengths of inner margin of pedical and spinous process plus one side of the laminae: The measurements were conducted on the cross section. The length EF between the two sides of the inner border of pedical is measured on the anterior part. The length of the spinous process plus one side of laminae GH is the straight line distance [Figure 2].

The preoperative and postoperative areas of lumbar spinal canal: The irregular circle includes posterior border of the vertebral column, anterior border of laminae or spinous process and inner borders of pedicle on both sides. Its area is defined as the osseous vertebral canal area.

Measure of human lumbar vertebrae specimen

Lumbar specimen

Specimens were purchased from Beijing Qiao Bo Wei Ye Technology Limited Company, 40 sets of L3, L4 and L5 specimen without spinal deformity were employed.

Surgical procedure

Place the specimen L3, L4, and L5 at prone position on the operative table, First, two hinges at the junction of the lateral mass and lamina were created by thinning the dorsal cortex with surgical drill and 2 mm chisels, and then the bilateral laminae were completely cut off through the ventral cortex. The isolated spinous process and laminae edge were prepared to fit the vertebral canal. Before the laminae was removed completely, small holes were made in each lamina and in the articular process bilaterally. The spinous

process and laminae was rotated by 100° at clockwise or counter-clockwise direction to rebuild a posterior wall on the spinal canal, and then were fixed by wire or titanium mini-plate [Figures 5 and 6].

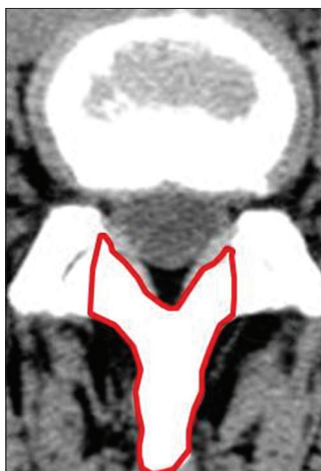

Figure 1: Preoperative spinous process and laminae.

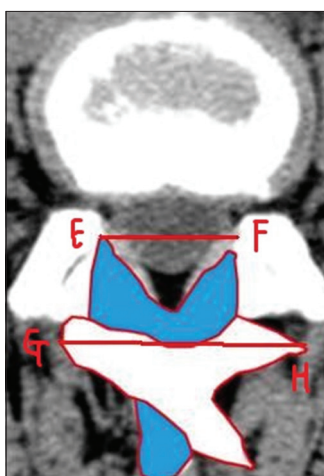


Figure 2: Rotated spinous process and laminae. The length two sides of inner border of pedicle EF, and the length of spinous process and half of laminae GH. The spinal canal enlarged.

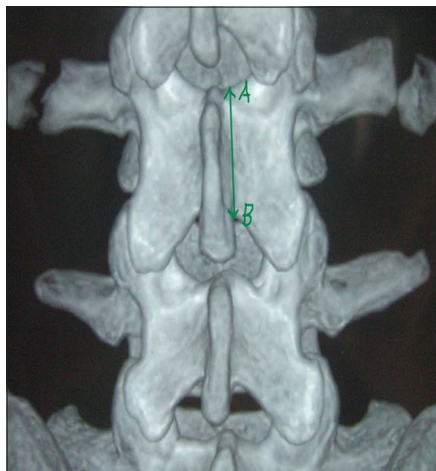


Figure 3: The height of laminae AB.

Method of measurement

Measurements were taken with calipers. The height of laminae was determined between the upper and lower border of laminae on the spinous process base. The height of the spinous process was evaluated between the upper and lower border of the spinous process in the central region. The distance of the inner

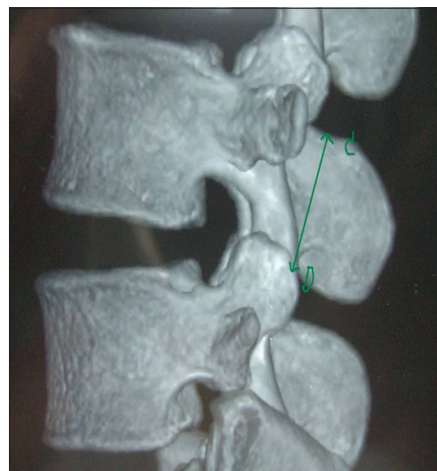


Figure 4: The height of spinous process CD.



Figure 5: Preoperative spinal canal.



Figure 6: Postoperative spinal canal, and spinal canal enlarged.

border of bilateral pedical was decided on the anterior part. After dissection of the laminae, the straight line distance of the spinous process plus one side of the laminae was measured.

Measurement of the area of the vertebral canal

The lumbar vertebra specimen were digital photographed at preoperation and postoperation respectively with the same camera (Canon sd1300, Japan). The photos were read into the computer. The canal was traced as an irregular circle line and hence that the osseous vertebral canal shape can be determined with Photoshop, including posterior border of vertebral column, anterior border of laminae or spinous process and bilateral inner border of pedicle. The area of the spinal canal was calculated by Photoshop.

Statistical analysis

All values are expressed as mean \pm standard deviation (SD) or median. Statistical significance between groups was assessed by the *t*-test. $P < 0.05$ was considered as statistically significant. All analyses were performed using SPSS 16.0 (SPSS Inc., Chicago, IL, USA).

RESULTS

Measurement in the computed tomography images of the lumbar vertebrae

The results of measurements are shown: The difference in the height between the spinous process and laminae is not significant ($P > 0.05$) [Table 1]. The length of the spinous process plus one side of laminae exceeded the distance between the two sides of the inner border of pedical ($P < 0.05$) [Table 2]. Obviously, the area of the postoperative vertebral canal was increased and larger than that of preoperative ($P < 0.05$) [Table 3].

Measure of human lumbar vertebrae specimen

There was no significance difference in the height between the spinous process and of laminae ($P > 0.05$). The height of the covered spinous process was almost equals to that of the laminae [Table 1].

The straight line length of the spinous process plus the laminae exceeded that of inner margin of bilateral pedical ($P < 0.05$). It could cover the postoperative vertebral canal posterior wall [Table 2].

The vertebral canal area was different between pre- and post-operation. It was increased after the operation ($P < 0.05$) [Table 3].

DISCUSSION

In the treatment of LSS, although minimally invasive surgery has achieved gratifying results,^[21-23] but operative exposure may not be sufficient, decompression may not be complete and has other shortcomings.

The fenestration or laminectomy is generally performed for the treatment of LSS. Laminectomy is applied when multilevel fenestration is insufficient that is, central canal stenosis. When the laminectomy was performed, however, removal

Table 1: Height of SP and laminae on CT images and specimen respectively (mm, mean \pm SD)

Lumbar	CT images (n = 80)		Specimen (n = 40)	
	Height of SP	Height of laminae	Height of SP	Height of laminae
L3	24.74 \pm 3.45	23.66 \pm 2.32	25.55 \pm 3.66	24.65 \pm 3.77
L4	22.68 \pm 5.96	22.68 \pm 5.36	23.44 \pm 3.36	23.55 \pm 4.02
L5	21.54 \pm 4.12	20.99 \pm 3.67	22.32 \pm 2.91	21.77 \pm 4.52

$P > 0.05$. SP: Spinous process; CT: Computed tomography; SD: Standard deviation.

Table 2: Distance of inner border of pedical and length of SP with laminae on CT images and specimen respectively (mm, mean \pm SD)

Lumbar	CT images (n = 80)		Specimen (n = 40)	
	Inner border of pedical	Length of SP with laminae	Inner border of pedical	Length of SP with laminae
L3	23.01 \pm 6.59	29.76 \pm 4.91	24.25 \pm 6.45	31.81 \pm 5.76
L4	24.65 \pm 5.54	29.31 \pm 6.43	24.86 \pm 6.32	31.56 \pm 5.55
L5	26.03 \pm 7.34	32.53 \pm 5.76	25.81 \pm 7.45	32.26 \pm 4.32

$P < 0.05$. SP: Spinous process; CT: Computed tomography; SD: Standard deviation.

Table 3: Preoperative and postoperative areas of spinal canals on CT images and specimen respectively (mm², mean \pm SD)

Lumbar	CT images (n = 80)		Specimen (n = 40)	
	Preoperative ASC	Postoperative ASC	Preoperative ASC	Postoperative ASC
L3	299.81 \pm 10.09	480.01 \pm 9.33	266.66 \pm 11.45	418.03 \pm 10.52
L4	297.66 \pm 9.54	487.32 \pm 8.65	297.65 \pm 10.21	406.17 \pm 9.35
L5	308.22 \pm 10.04	501.03 \pm 9.12	309.55 \pm 10.32	400.57 \pm 10.13

$P < 0.05$. CT: Computed tomography; SD: Standard deviation; ASC: Areas of spinal canals.

of the posterior elements, including the vertebral arches, supraspinous ligament and interspinous ligament, reduced the stability of the lumbar spine. In addition, due to insufficient coverage of dura, the invasion of the hematoma and scar tissue into the spinal canal would give rise to compression of dura and nerve root as well as their adhesions. It has been a difficult problem for a long time to spine the surgeon.

Some scholars thought the scar tissue around dura mater of the spinal cord was originated from the posterior injured sacrospinalis and the anterior injured anulus fibrosus as well as the posterior longitudinal ligament. Stuck scar tissue formed around the nerve root would then spread to the bilateral recess and nerve root canals. The lack of coverage for the dura mater was the basis reason for the adhesion and symptoms.

A variety of methods has been attempted to prevent postoperative epidural adherence. Some researchers found that placing isolative material between the dura and sacrospinal muscle could prevent their contact.^[24] An ideal

epidural isolation material should have good biocompatibility and exhibit the barrier effect for the sacrospinalis and fibrous tissue and optimal biological degradation function. The material can be degraded easily and absorbed in presumptive times without the local or systematic adverse reaction and scar generation. However, the materials employed presently cannot satisfy these requirements. Moreover, the nonsteroidal antiinflammatory drugs and inhibitor of inflammatory cytokines have been employed to prevent the formation of scar tissue and its adhesion.^[25,26] Nevertheless, these methods are still in the phase of animal tests and waited for further investigation.

In the present work, the LSS was treated with TRL. The operation was simulated in the computer and performed on the lumbar specimen. The feasibility of the treatment was investigated by evaluations of relevant data. Laminectomy provided a sufficient operative exposure for the safe decompression of lateral recesses and nerve root canal.

Both measurements on the CT images and of lumbar specimen indicated that the length of the spinous process and one side of the laminae exceeded the distance of the inner border of bilateral pedicle. The difference in the height between the spinous process and laminae is insignificant. Therefore, the vertebral canal posterior wall could be sufficiently covered in height and width by the rotated spinous process connected with laminae after TRL, preventing practically baffle scar. The Postoperative vertebral canal diameter and area were increased obviously compared to the preoperative. As a result, the compression of dura mater and nerve root from vertebral canal stenosis was removed. The decompression of laminae is achieved.

The present epidural isolation materials belong to the soft or adhesive ones with low hardness. They can hardly resist the compression of scar tissues on dura mater. The reconstructed spinal arch consists of the turn-overed spinous process and laminae. It is undoubtedly the most ideal baffle material. It can not only overcome the shortages of hardness for the soft and adhesive materials, but also have the advantage of promoting and participating in the new bone regeneration in the laminae during reconstruction, whose properties are missing for most rigid materials.

In the TRL surgery, spinous process and laminae build up the vertebral canal posterior wall. The rebuild of the vertebral canal means regeneration of new bone on the turn-over spinous process and laminae. During the initial stage, the reconstructed spinal canal posterior wall acts as structural grafts of new bone regeneration. The new bone grows along the curvature of the spinous process and remodels the spinal canal. In the middle phase, vertebral canal rebuilding progresses by its osteoinductive and osteoconductive abilities. Creeping substitution of the new cover plays a role of resistance and bearing weight together. In the late or remodeling phase, rebuild of a new vertebral canal is achieved by completing the creeping substitution procedure and fusion between the postero-lateral and laminae

bone graft. This could be a long time procedure through the creeping substitution activity. Therefore, the rotated spinous process and laminae can keep the mechanical hardness of lumbar vertebrae and prevent the formation of scar tissues on dura mater.

The present work describes a simulated surgical procedure performed digitally on CT scan images and physically on vertebral specimens. The study demonstrates that performing the described procedure will cause the vertebral foramina of the lower lumbar spine to increase in size. But it has severe limitation, which is the *in vivo* effects (good and bad) are completely unknown, we have no further the clinical application of this procedure based on the data presented here.

CONCLUSIONS

The present work provides a possible laminoplasty to treat LSS. Removing spinous process and laminae enables an enough large open view for the operation, and facilitates the decompression of lateral recessus and nerve root canal. Moreover, the central spinal canal is enlarged after its reconstruction so that the vertebral canal posterior wall is well covered to prevent the invasion of hematoma and scar tissue.

This operative method belongs to the autogenous bone graft without the reject reaction. The lumbar vertebrae can reach permanent stabilization with the osseous fusion. Nevertheless, it is just an concept, must has many flaws, continual improvements and optimizations are needed in the clinical application in the future.

REFERENCES

1. Amundsen T, Weber H, Lilleås F, Nordal HJ, Abdelnoor M, Magnaes B. Lumbar spinal stenosis. Clinical and radiologic features. *Spine (Phila Pa 1976)* 1995;20:1178-86.
2. Verhoof OJ, Bron JL, Wapstra FH, van Royen BJ. High failure rate of the interspinous distraction device (X-Stop) for the treatment of lumbar spinal stenosis caused by degenerative spondylolisthesis. *Eur Spine J* 2008;17:188-92.
3. Takaso M, Nakazawa T, Imura T, Okada T, Fukushima K, Ueno M, *et al.* Less invasive and less technically demanding decompressive procedure for lumbar spinal stenosis – Appropriate for general orthopaedic surgeons? *Int Orthop* 2011;35:67-73.
4. Kuchta J, Sobottke R, Eysel P, Simons P. Two-year results of interspinous spacer (X-Stop) implantation in 175 patients with neurologic intermittent claudication due to lumbar spinal stenosis. *Eur Spine J* 2009;18:823-9.
5. Shabat S, Miller LE, Block JE, Gepstein R. Minimally invasive treatment of lumbar spinal stenosis with a novel interspinous spacer. *Clin Interv Aging* 2011;6:227-33.
6. Subramaniam V, Chamberlain RH, Theodore N, Baek S, Safavi-Abbasi S, Senoglu M, *et al.* Biomechanical effects of laminoplasty versus laminectomy: Stenosis and stability. *Spine (Phila Pa 1976)* 2009;34:E573-8.
7. Atlas SJ, Keller RB, Wu YA, Deyo RA, Singer DE. Long-term outcomes of surgical and nonsurgical management of lumbar spinal stenosis: 8 to 10 year results from the maine lumbar spine study. *Spine (Phila Pa 1976)* 2005;30:936-43.
8. Weinstein JN, Lurie JD, Tosteson TD, Hanscom B, Tosteson AN, Blood EA, *et al.* Surgical versus nonsurgical treatment for lumbar degenerative spondylolisthesis. *N Engl J Med* 2007;356:2257-70.

9. Shabat S, Arinon Z, Folman Y, Leitner J, David R, Pevzner E, *et al.* Long-term outcome of decompressive surgery for lumbar spinal stenosis in octogenarians. *Eur Spine J* 2008;17:193-8.
10. Haufe SM, Mork AR, Pyne MA, Baker RA. Endoscopic laminoforaminoplasty success rates for treatment of foraminal spinal stenosis: Report on sixty-four cases. *Int J Med Sci* 2009;6:102-5.
11. Pao JL, Chen WC, Chen PQ. Clinical outcomes of microendoscopic decompressive laminotomy for degenerative lumbar spinal stenosis. *Eur Spine J* 2009;18:672-8.
12. Tai CL, Hsieh PH, Chen WP, Chen LH, Chen WJ, Lai PL. Biomechanical comparison of lumbar spine instability between laminectomy and bilateral laminotomy for spinal stenosis syndrome – An experimental study in porcine model. *BMC Musculoskelet Disord* 2008;9:84.
13. Seong YJ, Lee JS, Suh KT, Kim JI, Lim JM, Goh TS. Posterior decompression and fusion in patients with multilevel lumbar foraminal stenosis: A comparison of segmental decompression and wide decompression. *Asian Spine J* 2011;5:100-6.
14. Takeshima N, Miyakawa H, Okuda K, Hattori S, Hagiwara S, Takatani J, *et al.* Evaluation of the therapeutic results of epiduroscopic adhesiolysis for failed back surgery syndrome. *Br J Anaesth* 2009;102:400-7.
15. Kawaguchi Y, Kanamori M, Ishihara H, Kikkawa T, Matsui H, Tsuji H, *et al.* Clinical and radiographic results of expansive lumbar laminoplasty in patients with spinal stenosis. *J Bone Joint Surg Am* 2005;87 Suppl 1:292-9.
16. Tuli SM, Kapoor V, Jain AK, Jain S. Spinoplasty following lumbar laminectomy for multilevel lumbar spinal stenosis to prevent iatrogenic instability. *Indian J Orthop* 2011;45:396-403.
17. Lawson KJ, Malycky JL, Berry JL, Steffee AD. Lamina repair and replacement to control laminectomy membrane formation in dogs. *Spine (Phila Pa 1976)* 1991;16:S222-6.
18. Adachi K, Futami T, Ebihara A, Yamaya T, Kasai N, Nakazawa T, *et al.* Spinal canal enlargement procedure by restorative laminoplasty for the treatment of lumbar canal stenosis. *Spine J* 2003;3:471-8.
19. Sangwan SS, Kundu ZS, Walecha P, Siwach RC, Kamboj P, Singh R. Degenerative lumbar spinal stenosis-results of expansive laminoplasty. *Int Orthop* 2008;32:805-8.
20. Hida S, Naito M, Arimizu J, Morishita Y, Nakamura A. The transverse placement laminoplasty using titanium miniplates for the reconstruction of the laminae in thoracic and lumbar lesion. *Eur Spine J* 2006;15:1292-7.
21. Min SH, Yoo JS. The clinical and radiological outcomes of multilevel minimally invasive transforaminal lumbar interbody fusion. *Eur Spine J* 2013;22:1164-72.
22. Minamide A, Yoshida M, Yamada H, Nakagawa Y, Maio K, Kawai M, *et al.* Clinical outcomes of microendoscopic decompression surgery for cervical myelopathy. *Eur Spine J* 2010;19:487-93.
23. Nellensteijn J, Ostelo R, Bartels R, Peul W, van Royen B, van Tulder M. Transforaminal endoscopic surgery for lumbar stenosis: A systematic review. *Eur Spine J* 2010;19:879-86.
24. Tao H, Fan H. Implantation of amniotic membrane to reduce postlaminectomy epidural adhesions. *Eur Spine J* 2009;18:1202-12.
25. Sandoval MA, Hernandez-Vaquero D. Preventing peridural fibrosis with nonsteroidal anti-inflammatory drugs. *Eur Spine J* 2008;17:451-5.
26. Olmarker K. Reduction of adhesion formation and promotion of wound healing after laminectomy by pharmacological inhibition of pro-inflammatory cytokines: An experimental study in the rat. *Eur Spine J* 2010;19:2117-21.

Received: 22-08-2014 **Edited by:** Li-shao Guo

How to cite this article: Pei XW, Liang YH, Zhang H, Gong ZS, Song HX. Evaluations of Computed Tomography Images and Lumbar Specimens in Mimic Operations of Transverse Rotation Laminoplasty for Lumbar Spinal Stenosis. *Chin Med J* 2015;128:191-6.

Source of Support: This work was supported by Capital Medical Development Research Fund, China (No. 2007-3184).

Conflict of Interest: None declared.