

Spinal extradural hemangioblastoma: A systematic review of characteristics and outcomes

ABSTRACT

Extradural spinal nerve root hemangioblastoma is a rare entity with very few cases reported in the literature. A comprehensive picture of the treatments and outcomes of the same is thus not available. A systematic search was done according to PRISMA guidelines. Search criteria included terms: spinal extradural hemangioblastoma, extradural hemangioblastoma, and spinal root hemangioblastoma. The parameters considered were treatment, motor, and sensory outcome, association with von-Hippel-Lindau (VHL) syndrome. Twenty-two studies (19 full text articles) were available for the review. A total of 39 cases of extradural spinal nerve root hemangioblastoma have been reported. These cases had a median age of 44 years with male predominance (2:1) and up to 48% occur in the thoracic level, similar to our case. Thirty-six percent of patients were associated with VHL syndrome. Surgical resection was the primary modality of treatment with embolization used in selected cases (20%). They had mean follow-up of 23 (± 11) months. The prognosis was better than the intradural counterpart with no motor deficit and sensory deficit in only 9%. Preoperative identification of the extradural nature of this pathology and complete excision at the first surgery offers excellent outcomes compared to intradural lesion. Targeted embolization may be used in cases anticipated with high blood loss.

Keywords: Hemangioblastoma, nerve root hemangioblastoma, spinal hemangioblastoma, systematic review

INTRODUCTION

Hemangioblastoma is a benign neoplasm of the nervous system, 95% of them being located in the posterior fossa and spine.^[1] It is associated with von Hippel-Lindau (VHL) Syndrome in 25%–30% of them.^[2] Among the spinal hemangioblastomas, 75% are intramedullary, the remaining 25% of them are extramedullary in location, mainly in cauda equina, filum terminale, and rarely in the spinal nerve root.^[3] The spinal root hemangioblastomas generally have an intradural component, and pure extradural hemangioblastomas are a rare entity.

There has been no systematic review of all reported cases and hence outcomes, recurrences, and clinicodemographic details of the same are not clear. We have attempted to present a complete picture of all reported cases in English literature along with a sample case from our institution. A number of cases of intradural/intramedullary hemangioblastomas have been operated and reported previously and hence we examine their differences in terms of presentation and outcomes.

METHODS

A comprehensive review of the literature was performed on July 26, 2019, from the MEDLINE (1966 to July 2019), EMBASE (1975 to July 2019), and Web of Science (1900 to July 2019). Search criteria included all occurrences in the title or abstract of the terms: spinal extradural hemangioblastoma, extradural hemangioblastoma, and

**KIRIT ARUMALLA, HARSH DEORA, SHILPA RAO¹,
ABHINITH SHASHIDHAR, MALLA BHASKARA RAO**

Departments of Neurosurgery and ¹Neuropathology, National Institute of Mental Health and Neurosciences, Bengaluru, Karnataka, India

Address for correspondence: Dr. Harsh Deora, Department of Neurosurgery, National Institute of Mental Health and Neurosciences, Bengaluru - 560 029, Karnataka, India. E-mail: demo5601@gmail.com

Submitted: 15-Jul-20
Published: 26-Nov-20

Accepted: 20-Aug-20

Access this article online	
Website: www.jcvjs.com	Quick Response Code 
DOI: 10.4103/jcvjs.JCVJS_112_20	

This is an open access journal, and articles are distributed under the terms of the Creative Commons Attribution-NonCommercial-ShareAlike 4.0 License, which allows others to remix, tweak, and build upon the work non-commercially, as long as appropriate credit is given and the new creations are licensed under the identical terms.

For reprints contact: WKHLRPMedknow_reprints@wolterskluwer.com

How to cite this article: Arumalla K, Deora H, Rao S, Shashidhar A, Rao MB. Spinal extradural hemangioblastoma: A systematic review of characteristics and outcomes. J Craniovert Jun Spine 2020;11:254-61.

spinal root hemangioblastoma. The inclusion criteria for the literature search were defined using the Population, Intervention, Comparator, Outcome, and Study Design approach [Table 1]. The population included were males and females of all ages. The intervention was the surgical resection of extradural spinal hemangioblastomas. The comparator was intradural spinal hemangioblastomas. The study design included case reports, case series, case-control, and cohort studies, and randomized controlled trials. Conference proceedings and unpublished studies were included if they provided sufficient information including demographics and outcomes.

Table 1: Population, intervention, comparator, outcome, and study design inclusion criteria for systematic search

	Inclusion criteria
Population	Male and females of all ages with diagnosis of spinal extradural hemangioblastoma which were operated upon
Intervention	Primary surgery, embolization
Comparator	Intradural (intra- and extra-medullary) hemangioblastoma
Outcome	Recurrence, re-surgery, motor, and sensory recovery
Study design	Case studies, case series, case-control, cohort, randomized controlled trial

Two investigators (HD and KA) independently performed the eligibility assessment of data in a standardized manner. Both reviewers were blinded to the other’s assessment. In case of dispute, a consensus was reached among the two. Duplicate records were removed. The abstract of each citation was then screened for relevance to cases of extradural spinal hemangioblastomas. Irrelevant citations and case reports were excluded. The full texts of the remaining citations were obtained along with additional records from the reference lists of the published articles. The full-text articles were reviewed and noneligible studies were excluded. Studies not written in the English language were excluded. Conference proceedings were excluded if they did not include the necessary information, including sample size and raw data. Studies fulfilling the inclusion and exclusion were included for qualitative and quantitative synthesis. The study was in line with the PRISMA guidelines of 2019 [Figure 1].

Data extraction and analysis

All included studies^[1-22] were coded and data were systematically extracted and compiled in a spreadsheet [Table 2]. Data gathered from full-text articles included population

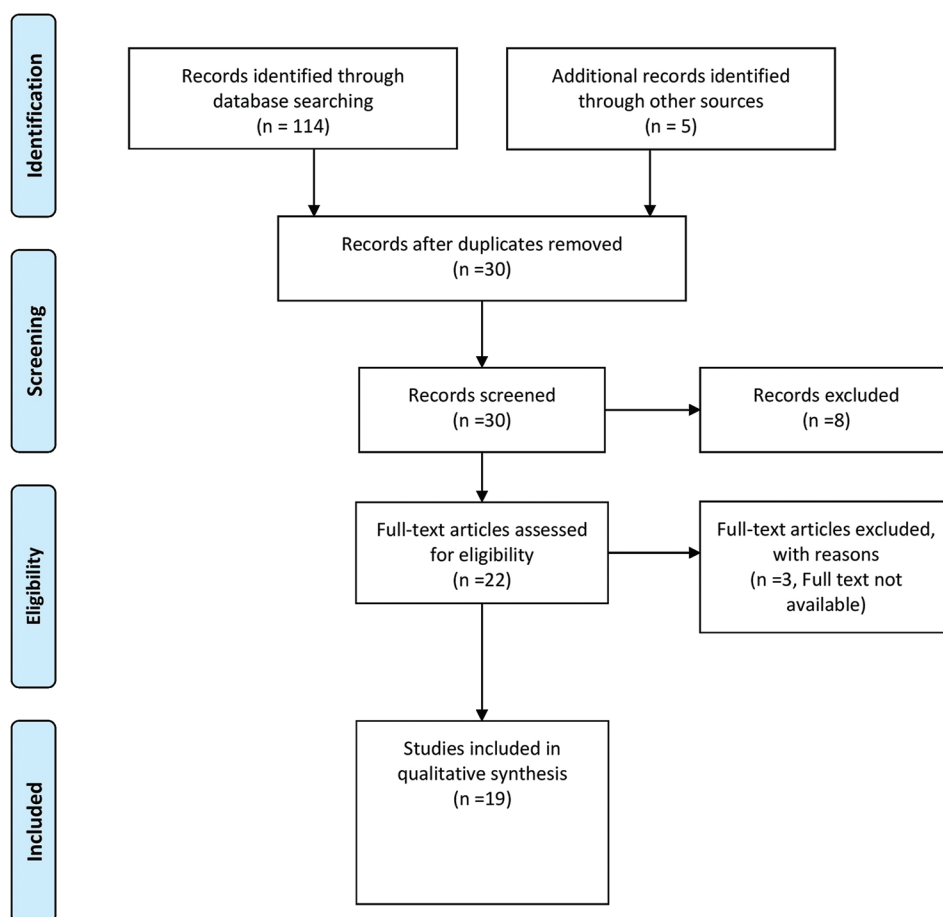


Figure 1: PRISMA chart of methodology of the systematic review

Table 2: A complete review of all spinal extradural hemangioblastomas reported in English literature

Authors/year	Age/ gender	Spinal level	VHL syndrome	Presentation	Treatment	Follow-up (months)	Outcome
Tarlov/1947 ^[1]	42/Male	T11-T12	No	Neck mass	2 surgeries	NA	Functional recovery
Smith and Estridge/1963 ^[2]	N/A	N/A	N/A	N/A	N/A	N/A	N/A
Murota and Symon/1989 ^[3]	33/male 56/female	T10 C5	No Yes	Weakness of leg Weakness of right hand	Incomplete excision Incomplete excision	36 12	Improved to moderate disability, recurred after 3 years No change
Higgins et al./1996 ^[4]	30/male	T9	N/A	Lower back pain	N/A	N/A	N/A
Chazono et al./1999 ^[5]	48/female	L5	No	Progressive muscle weakness of left leg	<i>En bloc</i> excision of the tumor	Absent	Complete improvement in power of limb with mild dysesthesia
Chu et al./2001 ^[6]	24/female	S1	Yes	Pain in left foot	Complete excision	N/A	N/A
Hermier et al./2002 ^[7]	58/male	S1	No	Right Sciatica	Embolization followed by complete excision	48	Complete resolution
Lee et al./2003 ^[8]	29/male	T12-L1, L5-S1	Yes	N/A	Surgical excision	N/A	Resolution
Escott et al./2004 ^[9]	62/male	C8	No	Bilateral lower limb weakness and tingling	Complete excision	N/A	Complete improvement in power of limb
Gläscher et al./2005 ^[10]	35/male	T10	Yes	Imbalance, back pain	Complete excision	N/A	Postoperative hematoma (evacuated) Complete recovery
	52/male	C7	No	Paresthesia-upper limb	In-complete excision	24	Complete recovery-symptomatic recurrence
	40/female	T6	Yes	Asymptomatic	Complete excision	N/A	Asymptomatic
	48/female	L5	Yes	Radicular pain	Complete excision	N/A	Complete recovery
	44/male	T6	No	Paraparesis	Incomplete excision	36	Complete recovery-symptomatic recurrence
	46/female	S1	Yes	Radicular pain	Complete excision	48	Complete recovery-symptomatic recurrence
Kern et al./2006 ^[11]	34/female	T10	Yes	Thoracic radicular pain	Embolization followed by Surgery	3	Hypoesthesia improved
Purandare and Misra/2012 ^[12]	32/male	T2	N/A	Left arm and D2-D3 dermatome paraesthesia	Complete excision	N/A	N/A
Choudhury et al./2012 ^[13]	N/A	TL	Yes	N/A	N/A	N/A	N/A
Mitchell et al./2013 ^[14]	72/male	L3	No	B/L lower limb radiculopathy	Preoperative embolization + subtotal excision	24	Complete recovery followed by symptomatic recurrence for which RT given
Sun et al./2014 ^[15]	63/female	T4	No	Backache	Gross total resection	36	Complete recovery
Law et al./2014 ^[16]	59/male	L4	No	Lower back pain, numbness of L4	Embolization f/b Subtotal excision	6	Significant improvement
Román-de Aragón et al./2014 ^[17]	48/male	L4	No	L4 radiculopathy	Excision	N/A	No deficit
Zakaria et al./2014 ^[18]	40/male	T3	No	Back Pain with acute paraplegia	Complete excision	24	Functionally independent
Doyle and Fletcher/2014 ^[19]	12 patients	C-2 patients T-6 Patients L-4 patients	N/A	N/A	N/A	N/A	N/A
Laviv and Rappaport/2015 ^[20]	N/A	T3	No	Paresthesia in lower limbs and urinary Incontinence	3 surgeries, 3 rd surgery-preoperative embolization	33	Functional recovery, residue present

Contd...

Table 2: Contd....

Authors/year	Age/gender	Spinal level	VHL syndrome	Presentation	Treatment	Follow-up (months)	Outcome
Aytar et al./2015 ^[21]	43/male	T7	No	Low back pain with paraparesis	Gross total excision	N/A	Functional recovery
Leung et al./2020 ^[22]	59/male	L3-L5	No	Low back pain and claudication	Primary surgery f/b Embolization and re-surgery	24	Numbness, no motor deficit
Present case	39/female	T8	No	Severe stiffness and lower limb weakness	Laminectomy and <i>En bloc</i> excision	12	Complete recovery

VHL: Von-Hippel Lindau syndrome, RT: Radiotherapy, N/A: Not available

demographics, study design, date of publication, location of the primary tumor, the primary treatment offered, recurrence rates, embolization use, re-surgery, and overall patient morbidity. The risk of bias was assessed at the study level by examining each study design, the authors' stated purpose for the study, and the source of patient data collection.

The initial database query identified 114 citations (44 from EMBASE, 30 from PubMed/MEDLINE, and 40 from Web of Science). After the application of exclusion criteria, there were 104 citations available for review. Fifty-three duplicate citations were removed, resulting in a total of 22 citations for the systematic review. Abstracts were reviewed for relevance to the diagnosis and management of spinal extradural hemangioblastomas. The full text was not available for three articles but they were included in the review. Manual searching of reference lists of the 19 full-text articles resulted in no additional eligible studies.

In comparison, intradural hemangioblastomas [Table 3] presented in younger populations probably due to early presentation of intramedullary symptoms and were equally distributed among males and females.^[23,24] Cervical cord was the most common location of these lesions and they had a poorer recovery profile with 14% cases deteriorated after surgery. They had a lower rate of embolization because of the smaller size at presentation and shared blood supply to the spinal cord. Recurrence rates were higher (32%) and were more likely to be treated with radiotherapy (28%) when compared to extradural lesions.^[23-25]

RESULTS

A total of 39 (excluding ours) cases to date were reported from 1947^[1] to date. The median age of all reported cases was 44 years with a male to female ratio of 2:1 in contrast to intradural hemangioblastoma which were seen in a decade younger up to 36.5 years and distributed equally among both the sexes. The most common location of the extradural lesion was thoracic (54%) followed by lumbar (33%) and

then cervical (13%) while the intradural lesions were more commonly seen in the cervical region (50%) followed by thoracic (42%). The most common presentation of extradural lesions was pain and paresthesia of the involved segment in 54% cases followed by motor weakness in 25% cases and combined motor and sensory symptoms in 16% cases with only one case being asymptomatic at presentation, while intradural lesions presented in majority of them with long tract signs. The follow-up was only available for 16 cases and was a mean of 23 (± 11) months. Preoperative embolization was used only in 20% and 12% of extradural and intradural lesion, respectively. The primary modality of treatment was surgery. The surgical outcome was excellent in the extradural lesions with only a 9% rate of sensory deficit and no motor deterioration while the intradural lesions had significant morbidity with 37% improvement and 59% remaining stable with the preoperative deficits. Re-surgery was required in 3 cases (12% cases), 2 for recurrence and one for postoperative hematoma evacuation while. Postoperative hematoma was seen only in 2.5% cases in the spinal hemangioblastoma. However, the rate of incomplete tumor removal was 20% with only one case receiving radiotherapy for symptomatic recurrence. Symptomatic recurrence was observed in 20% cases of the extradural hemangioblastoma while 32% in the intradural lesions. Majority of the recurrences were managed symptomatically with radiation therapy given only in one patient (15%) with extradural lesion and 37 patients (28%) with intradural hemangioblastoma. VHL syndrome was associated with up to 36% of extradural hemangioblastoma and 30% of intradural hemangioblastoma.

Case-report

A 39-year-old female presented with complaints of dull aching upper back pain for 6 months associated with paresthesias and numbness and progressive asymmetric weakness and stiffness of both lower limbs for the 6 months. On examination, her functional status was Modified McCormick Grade 3 motor power and tone being normal in upper limbs and Modified Ashworth Grade 2 spasticity in lower limbs with the power of 3/5 on the right side and 2/5 on the left side in

all groups. She had graded sensory loss below the T8 spinal level to all sensory modalities and exaggerated deep tendon reflexes in lower limbs. Babinski's reflex was positive and the patient did not have any symptoms of bladder or bowel incontinence. There were no symptoms in the upper limbs or lower cranial nerve involvement. The ophthalmological evaluation showed juxtapapillary hemangioma in the left eye fundus with no deficits in the visual field or acuity. Ultrasound abdomen showed multiple pancreatic cysts with no evidence of pheochromocytomas. Serum metanephrine and urinary vanillylmandelic acid were negative thus ruling out the possibility of a pheochromocytoma.

Magnetic resonance imaging showed a 32 mm (length) × 18 mm (breadth) T2 heterogeneously hypointense lesion at the level of T8–T9 level extending into widened left neural foramina causing compression and displacement of cord to the right side with intense postcontrast enhancement [Figure 2]. There was another enhancing nodule at C4 with syrinx up to the T2 level [Figure 3]. DSA showed that the T7–8 lesion was filling from the T7–T9 intercostal artery from the left side with common feeders to the anterior spinal artery.

As the patients' symptoms were localized to the T8 lesion, it was decided to operate on the same lesion and continue surveillance for the remaining ones. She underwent T7, T8 laminectomy with left T7 facet removal and excision of the lesion. Intraoperatively, the tumor was pinkish and highly vascular tumor attached to the dorsal nerve root extending into the neural foramen and was completely extradural. The surgical strategy was to remain outside the tumor at all times with and separate it from the involved nerve root so that an *en bloc* excision can be achieved [Figure 4]. Coagulation of the tumor surface and pericapsular dissection allows shrinking of

the tumor and resection in toto. Since the lesion was in the thoracic spine and away from the transition zones fixation of the spine was not considered prudent. Postoperatively, she recovered well with immediate improvement in motor power of both lower limbs to 4/5 and no sensory loss in the T7 or T8 dermatomes. The postoperative magnetic resonance image (MRI) scan showed complete resection of the tumor and she was asked to be on follow-up for the cervical lesion. The histopathology of the lesion was WHO grade I hemangioblastoma composed of several thin-walled vascular channels separated by stromal cells [Figure 4].

Table 3: Comparison of parameters between extradural and intradural hemangioblastoma

Parameter	Extradural hemangioblastoma	Intradural hemangioblastoma
Mean age in years	45.6 years	36.5 years
Sex distribution	67% males, 33% females	51% males, 49% female
Location	Thoracic most common level-54% Lumbar-33% Cervical-13%	Cervical most common-50% Thoracic-42%, Lumbar-8%
Treatment primary modality	Gross total resection in 80% patient Subtotal resection-20%	Gross total resection-92% Subtotal resection-8%
Outcome	91% Improved, 9% Sensory deficit	37% Improved, 59% stable and 14% deteriorated
Complication requiring re-exploration	2.5% hematoma (1 patient)	0.3% hematoma (2 patients)
Recurrence rate	20% recurrence	32% recurrence
Preoperative embolization	20% underwent preoperative embolization	12% Underwent preoperative embolization
RT	1 recurrence treated with radiotherapy	28% (37) recurrences treated with radiotherapy

RT: Radiotherapy

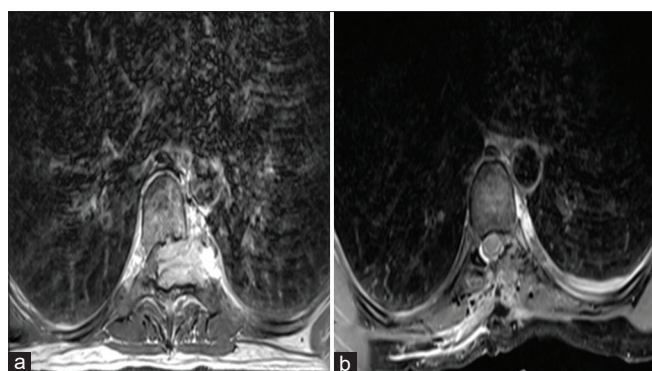


Figure 2: (a) Gadolinium-enhanced axial magnetic resonance image showing a brilliantly enhancing lesion at the T8 level that is extradural (black line forming the inner margin is the dura mater) with severe compression of the cord and preserved rib surface. (b) Gadolinium-enhanced axial magnetic resonance image taken on postoperative day 1 showing complete resection of the lesion with resolution of the compression on the spinal cord and preserved rib and pleural surface

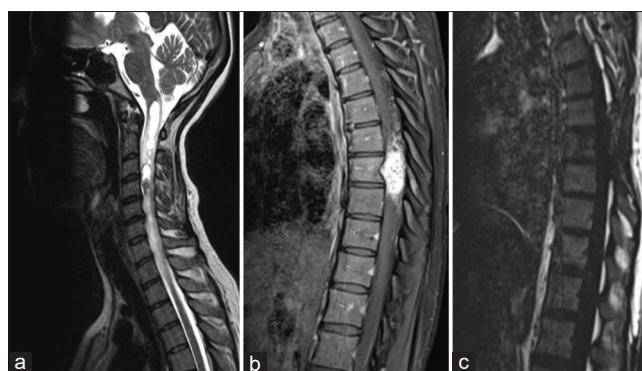


Figure 3: (a) T2-sagittal magnetic resonance image of the cervical spine with a nodule at the C4 level with syrinx extending up to the medullary region level. (b) Gadolinium-enhanced sagittal Magnetic resonance image showing a brilliantly enhancing lesion at the T8 level with scalloping of the T8 vertebral body. (c) Gadolinium-enhanced sagittal Magnetic resonance image taken on postoperative day 1 showing complete excision of the lesion with no residual enhancement

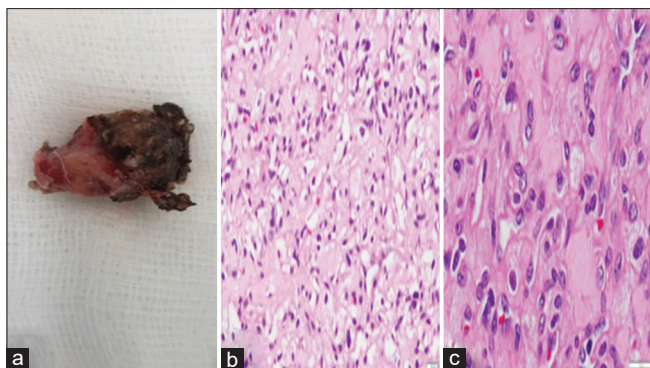


Figure 4: (a) Picture of *en bloc* excision of the lesion with coagulated surface visible. (b and c): Histopathology sequence showing the hemangioblastoma composed of many vascular channels (b, H and E, $\times 100$) separated by vacuolated stromal cells (c, H and E, $\times 200$)

She has been on regular 3 months' follow-up for the past 12 months and has had complete recovery of motor power. On serial MRI, there is no change in the cervical lesion and she has no symptoms of the same. Hence, she has been asked to be on regular surveillance for the same and other extra-cranial manifestations.

DISCUSSION

Hemangioblastomas are rare tumors and comprise about 2%–6% of the spinal cord neoplasms.^[23,26-30] The majority of the hemangioblastomas are located in the intramedullary location, in the cervical cord.^[24] The spine nerve root hemangioblastomas are rare and most of them have both intradural and extradural components^[26] with pure extradural being rare.^[4-6] There have been only 40 cases of extradural hemangioblastoma reported to date including our case.

The presence of pure extradural tumors raises the question of the origin of these tumors. Vortmeyer and Alomari^[27] suggested that the tumor arises from the mesenchymal tumor lets around the nerve root tissue which induce angiogenic response contributing to the vascularity of the tumor. This hypothesis can be validated with the recent concept of hemangioblastoma origin from the embryological arrested hemangioblasts derived both from neuroectoderm and mesenchyme.^[26,27] In our systematic review, the median age was 44 years and associated with VHL syndrome in up to 36% of individuals. Since the reporting of these cases has been done since 1947 genetic verification of cases of VHL was not possible in each case. Furthermore, in many recent reported cases, genetic testing was not done which may be due to financial- or consent-related constraints.^[22] In our case too, the patient did not give consent for the same and hence testing for VHL could not be done. Clinically, it did not fit the criteria for Type 1 VHL as there was no family history of

VHL and for an individual with no known family history of VHL syndrome the diagnosis can be made with two or more characteristic lesions:

- Two or more hemangioblastomas of the retina, spine, or brain or a single hemangioblastoma in association with a visceral manifestation (e.g., multiple kidney or pancreatic cysts) - Our case fulfilled this criteria only
- Renal cell carcinoma
- Adrenal or extra-adrenal pheochromocytomas
- Less commonly, endolymphatic sac tumors, papillary cystadenomas of the epididymis or broad ligament, or neuroendocrine tumors of the pancreas.

Imaging of these tumors is challenging if are not associated with VHL syndrome. They are iso-hypointense on T1 and isointense solid tumors on T2 within homogeneity due to flow voids in them.^[5] This is in contrast to cranial hemangioblastomas, the majority of which have a cystic tumor with a solid enhancing nodule. The spinal hemangioblastomas enhance intensely on contrast similar to the majority of schwannomas and both of them produce scalloping of vertebral bodies.^[11] The prominent vasculature in subarachnoid space if present is diagnostic of hemangioblastoma.^[12,13] The other differential diagnosis, especially in the thoracic region, includes metastasis from the renal cell carcinoma and malignant nerve sheath tumors which generally invade the bone. Suspicion to vascular neoplasm such as hemangioblastoma warrants preoperative spinal angiography and embolization if feasible. The majority of preoperative embolization were performed in hemangioblastomas located in the cervical and lumbar region^[7,14,16,22,29,30] In a review by Ampie *et al.*^[29] for intradural hemangioblastoma, embolization reported to decrease in intraoperative blood loss and surgery was performed within 6 days to prevent edema associated neurological deterioration. However, the procedure is not feasible in all cases due to thin and irregular caliber of the vessels supplying the tumor as reported by Joaquim *et al.*^[23] or due to common blood supply to the anterior spinal artery and tumor, especially in the thoracic region. Saliou *et al.*^[30] in their case series have reported complications of extravasation of embolic particle and hardening of tumor making it unfeasible for surgery in two cases. The majority of the large microsurgical case series^[24] report a similar amount of blood loss when compared with those done with preoperative embolization. In the review by Ampie *et al.*,^[29] the extent of resection was similar to that reported in the systematic review of microsurgical series of spinal hemangioblastoma.^[25] Thus, preoperative embolization did not provide any added advantage to microsurgery alone, and it must be reserved only to high-risk cases with intraoperative bleeding, though randomized studies are required to validate this.

In comparison, intradural hemangioblastomas [Table 3] presented in younger populations probably due to early presentation of intramedullary symptoms and were equally distributed among males and females.^[23,24] Cervical cord was the most common location of these lesions and they had a poorer recovery profile with 14% cases deteriorated after surgery. They had a lower rate of embolization because of the smaller size at presentation and shared blood supply to the spinal cord. Recurrence rates were higher (32%) and were more likely to be treated with radiotherapy (28%) when compared to extradural lesions.^[23-25]

Thus, in any hemangioblastoma, complete surgical excision is the treatment of choice which is associated with minimal deficits if the plane of the lesion is respected. Preoperative diagnosis is critical as prepares the surgeon to completely resect the lesion by remaining peritumoral along with the capsule and thus reduces recurrence.^[14] In particular, extradural lesions should be approached aggressively after screening for VHL and other similar lesions.

CONCLUSION

Pure extradural hemangioblastoma though rare must be considered as a differential diagnosis of extradural spinal tumors especially in a case with suspected VHL disease. Complete surgical excision using circumferential dissection is the treatment of choice. Prognosis is excellent in completely excised cases and embolization can be used in selected cases after the exclusion of a common feeder to the lesion and the spinal cord.

Declaration of patient consent

The authors certify that they have obtained all appropriate patient consent forms. In the form, the patient has given her consent for her images and other clinical information to be reported in the journal. The patient understand that name and initials will not be published and due efforts will be made to conceal identity, but anonymity cannot be guaranteed.

Financial support and sponsorship

Nil.

Conflicts of interest

There are no conflicts of interest.

REFERENCES

- Tarlov IM. Spinal extradural hemangioblastoma roentgenographically visualized with diodrast at operation and successfully removed. *Radiology* 1947;49:717-23.
- Smith RA, Estridge MN. Extradural spinal hemangioblastomas. Review of the literature and report of a case. *Bull Los Angel Neuro Soc* 1963;28:79-84.
- Murota T, Symon L. Surgical management of hemangioblastoma of the spinal cord: A report of 18 cases. *Neurosurgery* 1989;25:699-707.
- Higgins JN, Lammie GA, Savy LE, Taylor WJ, Stevens JM. Intraosseous vertebral haemangioblastoma: MRI. *Neuroradiology* 1996;38 Suppl 1:S107-10.
- Chazono M, Shiba R, Funasaki H, Soshi S, Hattori A, Fujii K. Hemangioblastoma of the L-5 nerve root. Case illustration. *J Neurosurg* 1999;90:160.
- Chu BC, Terae S, Hida K, Furukawa M, Abe S, Miyasaka K. MR findings in spinal hemangioblastoma: Correlation with symptoms and with angiographic and surgical findings. *AJNR Am J Neuroradiol* 2001;22:206-17.
- Hermier M, Cotton F, Saint-Pierre G, Jouvet A, Ongolo-Zogo P, Fischer G, et al. Myelopathy and sciatica induced by an extradural S1 root haemangioblastoma. *Neuroradiology* 2002;44:494-8.
- Lee DK, Choe WJ, Chung CK, Kim HJ. Spinal cord hemangioblastoma: Surgical strategy and clinical outcome. *J Neurooncol* 2003;61:27-34.
- Escott EJ, Kleinschmidt-DeMasters BK, Brega K, Lillehei KO. Proximal nerve root spinal hemangioblastomas: Presentation of three cases, MR appearance, and literature review. *Surg Neurol* 2004;61:262-73.
- Gläsker S, Berlis A, Pagenstecher A, Vougioukas VI, Van Velthoven V. Characterization of hemangioblastomas of spinal nerves. *Neurosurgery* 2005;56:503-9.
- Kern M, Naeini R, Lehmann TN, Benndorf G. Imaging of a thoracic spinal nerve haemangioblastoma by three-dimensional digital angiography. *J Clin Neurosci* 2006;13:929-32.
- Purandare HR, Misra BK. Thoracic nerve root hemangioblastoma: A rare cause of posterior mediastinal mass. *World Neurosurg* 2012;78:192.E1-3.
- Choudhury T, Jahan S, Kamal M, Hossain MM, Khan ZR. Von Hippel-Lindau disease in a pregnant lady. *Mymensingh Med J* 2012;21:184-7.
- Mitchell A, Scheithauer BW, Wharen RE, Franck J, Chan K. Hemangioblastoma of spinal nerve: A report of six cases. *Clin Neuropathol* 2013;32:91-9.
- Sun HI, Özduman K, Usseli MI, Özgen S, Pamir MN. Sporadic spinal hemangioblastomas can be effectively treated by microsurgery alone. *World Neurosurg* 2014;82:836-47.
- Law EK, Lee RK, Griffith JF, Siu DY, Ng HK. Spinal nerve root haemangioblastoma associated with reactive polycythemia. *Case Rep Radiol* 2014;2014:798620.
- Román-de Aragón M, Márquez T, Isla A, Gómez-de la Riva A. Hemangioblastoma of the right L4 nerve root with radicular extraforaminal involvement. *Neurocirugia (Astur)* 2014;25:286-9.
- Zakaria R, Crooks D, Osman-Farah J. Reply to: Clinical Neuropathology 2013;32:91-9. Spinal nerve root hemangioblastoma may be predominantly extradural. *Clin Neuropathol* 2014;33:157-9.
- Doyle LA, Fletcher CD. Peripheral hemangioblastoma: Clinicopathologic characterization in a series of 22 cases. *Am J Surg Pathol* 2014;38:119-27.
- Laviv Y, Rappaport ZH. Cord compression due to extradural thoracic nerve root hemangioblastoma. *Br J Neurosurg* 2015;29:281-4.
- Aytar MH, Yener U, Ekşi MŞ, Kaya B, Özgen S, Sav A, Alanay A. Purely extradural spinal nerve root hemangioblastomas. *J Craniovertebr Junction Spine* 2016;4:197-200.
- Leung HS, Lee RK, Law EK, Mak WK, Griffith JF, Yu SC. Percutaneous embolization of sporadic lumbar nerve root haemangioblastoma under local anaesthesia. *BJR Case Rep* 2020;6:20190037.
- Joaquim AF, Ghizoni E, dos Santos MJ, Valadares MG, da Silva FS, Tedeschi H. Intramedullary hemangioblastomas: Surgical results in 16 patients. *Neurosurg Focus* 2015;39:E18.
- Deng X, Wang K, Wu L, Yang C, Yang T, Zhao L. Intraspinous hemangioblastomas: Analysis of 92 cases in a single institution.

- J Neurosurg Spine 2014;21:260-9.
25. Bridges KJ, Jaboin JJ, Kubicky CD, Than KD. Stereotactic radiosurgery versus surgical resection for spinal hemangioblastoma: A systematic review. *Clin Neurol Neurosurg* 2017;154:59-66.
 26. Senjaya F, Midha R. Thoracic nerve root hemangioblastoma – A diagnostic rarity. *World Neurosurg* 2012;78:88-9.
 27. Vortmeyer AO, Alomari AK. Pathology of the nervous system in Von Hippel-Lindau disease. *J Kidney Cancer VHL* 2015;2:114-29.
 28. Lonser RR, Glenn GM, Walther M, Chew EY, Libutti SK, Linehan WM, *et al.* von Hippel-Lindau disease. *Lancet* 2003;361:2059-67.
 29. Ampie L, Choy W, Khanna R, Smith ZA, Dahdaleh NS, Parsa AT, *et al.* Role of preoperative embolization for intradural spinal hemangioblastomas. *J Clin Neuroscience* 2016;24:83-7.
 30. Saliou G, Giammattei L, Ozanne A, Messerer M. Role of preoperative embolization of intramedullary hemangioblastoma. *Neurochirurgie* 2017;63:372-5.