



# The $\pi$ -Circuit Technique in Coronary Surgery: Analysis of 1359 Consecutive Cases

Sotirios N Prapas<sup>1</sup>, Ioannis A Pangiopoulos<sup>1</sup>, Vasileios N Leivaditis<sup>2</sup> , Konstantinos P Katsavrias<sup>1</sup>, Vasiliki S Prapa<sup>3</sup>, Ioannis N Linardakis<sup>1</sup>, Efstratios N Koletsis<sup>4</sup> and Konstantinos Grapatsas<sup>5</sup>

<sup>1</sup>1st Department of Cardiac Surgery, Henry Dunant Hospital Center, Athens, Greece. <sup>2</sup>Department of Cardiothoracic and Vascular Surgery, Westpfalz-Klinikum, Kaiserslautern, Germany. <sup>3</sup>Department of Anesthesiology, Henry Dunant Hospital Center, Athens, Greece. <sup>4</sup>Department of Cardiothoracic Surgery, General University Hospital of Patras, Patras, Greece. <sup>5</sup>Department of Thoracic Surgery, Medical Center – University of Freiburg, Freiburg, Germany.

Open Journal of Cardiovascular Surgery  
Volume 11: 1–13  
© The Author(s) 2019  
Article reuse guidelines:  
sagepub.com/journals-permissions  
DOI: 10.1177/1179065219871948  


**ABSTRACT:** Coronary artery bypass surgery still has its unique role in the treatment of coronary artery disease. It faces, however, the continuous challenge of becoming even less invasive and more effective as cases become more complex. We here present the results of 1359 cases treated with the  $\pi$ -circuit technique which consists of an off-pump total myocardial revascularization using composite arterial grafts. The results demonstrate that it is a safe technique providing low mortality, stroke, renal failure, wound infection, and other complication rates. We suggest the application of this technique, as well as of other similar techniques regarding similar principles, especially in high-risk patients.

**KEYWORDS:** Coronary artery bypass graft, composite grafts, arterial grafts, arteria revascularization, off-pump coronary surgery, non-touch aortic technique

**RECEIVED:** July 28, 2019. **ACCEPTED:** August 1, 2019.

**TYPE:** Original Research

**FUNDING:** The author(s) received no financial support for the research, authorship, and/or publication of this article.

**DECLARATION OF CONFLICTING INTERESTS:** The author(s) declared no potential conflicts of interest with respect to the research, authorship, and/or publication of this article.

**CORRESPONDING AUTHOR:** Vasileios N Leivaditis, Department of Cardiothoracic and Vascular Surgery, Westpfalz-Klinikum, Blumenstr. 9, 67655 Kaiserslautern, Germany. Email: vnleivaditis@gmail.com

## Introduction

The history of coronary surgery is marked by the constant effort to seek the safest method and the most suitable grafts. The classic coronary artery bypass grafting (CABG) and the exclusive use of venous grafts have, however, not fully met expectations for a perioperative outcome free of complications and for the satisfactory long-term functioning of the grafts.<sup>1,2</sup>

Whether the CABG procedure should be performed with or without the use of cardiopulmonary bypass (CPB) still remains a matter of large debate. However, a large number of studies have shown that the revascularization of the myocardium with the heart beating and without CPB support can be superior to classic myocardial revascularization regarding the reduction of postoperative complications and favourable results, especially in high-risk individuals.<sup>3–6</sup> Trials performed in centres with a high-structured experience in off-pump coronary artery bypass surgery (OPCAB) were mostly able to show a benefit of the OPCAB over the on-pump strategy of morbidity and survival.<sup>7</sup>

Partial clamping of the pulsating ascending aorta for central anastomoses, however, particularly in the case of an atheromatous aorta harbours the risk of neurological complications and increases the possibility of dissection of the ascending aorta.<sup>8,9</sup> At the same time, positive results from the use of arterial grafts have been demonstrated, as survival has increased and cardiac episodes have decreased in the long term.<sup>10,11</sup> Efforts to maximize left internal mammary artery (LIMA) and right internal

mammary artery (RIMA) use have led to sequential use and to composite grafts, whereas the need to increase length has led to the use of skeletonized internal mammary artery (IMA). Coronary artery operations exclusively with bilateral internal mammary artery (BIMA) are associated with better long-term survival than grafting with single LIMA plus other types of conduits.<sup>12</sup>

We thus decided to apply a technique that would avoid the limitations or complications entailed in techniques already applied and would use the positive experience of the OPCAB technique, in conjunction with the exclusive use of arterial grafts without manipulation of the ascending aorta. In this study, we present the results of the first 5 years of application of this method.

## Materials and Methods

This is a retrospective study and regards patients who underwent isolated coronary bypass in the Cardiac Surgery Department of the ‘Henry Dunant’ Hospital, Athens, from February 2001 to November 2005. The study included 1359 patients with surgical coronary disease, who were treated with the ‘ $\pi$ ’ arterial circuit method, which consists of coronary revascularization with the following features: (1) beating heart, (2) no use of CPB, (3) no aortic manipulations, (4) use of composite arterial grafts, and (5) total arterial revascularization.

Each operation was performed after the candidate patient was given full information about the type of surgery, risks,



possible complications, and favourable results and once the patient had given written consent.

### *Surgical technique*

The operations were performed through classic median sternotomy. In all cases, skeletonized internal mammary arteries were harvested. The internal mammary arteries (ITAs) were harvested as skeletonized vessels.<sup>9,10</sup> Special care was taken to keep well away from the ITA when using the cautery, even in the low setting. We always tried to prevent an injury of the internal thoracic vein to provide optimal healing conditions of the sternum. However, in some cases to obtain maximal ITA length, diameter, and flow, it might be necessary to divide the internal thoracic vein for satisfactory exposure of the most proximal collateral branches. Heparin was in all cases administered before distal ITA division. The skeletonized vessel was maintained in papaverine environment to prevent or minimize vasospasm. In situ grafts were covered with a papaverine-soaked gauze and free grafts were put in a 1:30 papaverine saline solution bath. This bath of warm papaverine is good enough to relax any spasm produced during dissection without the risk of endothelial damage caused by other antispastic manoeuvres, such as intraluminal papaverine injection or mechanical dilatation. Radial artery was also used as a third alternative arterial graft or as a second graft when the bilateral IMA harvesting was not indicated. As a general rule, we tried to avoid harvesting both IMAs in obese patients with body mass index (BMI) > 30, in diabetic patients, in cases of chronic obstructive lung disease, in patients with fragile sternum, as from osteoporosis, and in cases of patients under immunosuppressant/steroid therapy. Exposure of the surgical field without disturbing heart function and with the appropriate manipulations for suspension of the pericardium and placement of the heart is of chief importance for the operation's success. The pericardium is suspended by placing deep silk sutures and then drawing the pericardium upwards between the left inferior pulmonary vein and the inferior vena cava. This can be combined with pinning down the midsection of the open gauze folded appropriately so as to form a band with its 2 ends pulled in the respective directions in each case (towards the surgeon's contralateral or ipsilateral side or towards the patient's head) to keep the heart in the right place for the anastomoses to be made in the anterior, lateral, and inferior walls, respectively. Opening the right pleural cavity makes it easier to turn the heart during the anastomoses in the lateral wall. Better exposure can be achieved by tilting the surgical table to the right and in the Trendelenburg position.

To stabilize the target vessel, we used all the commercial stabilizers, either compression devices, such as the metal rest-erilized CHORUS stabilizer, GUIDANT's disposable Axius stabilizer, and GENZYME's disposable Immobilizer,

or suction devices such as Octopus II, II plus, III, and IV manufactured by MEDTRONIC, as well as with ESTECH's Synergy stabilizers. We preferred to use the last ones in acute cases owing to the fact that these cause less haemodynamic burden to the myocardium. At the same time, 2 Prolene 5-0 tractile myocardial sutures placed on either side of the anastomosis proved to be particularly helpful in all cases.

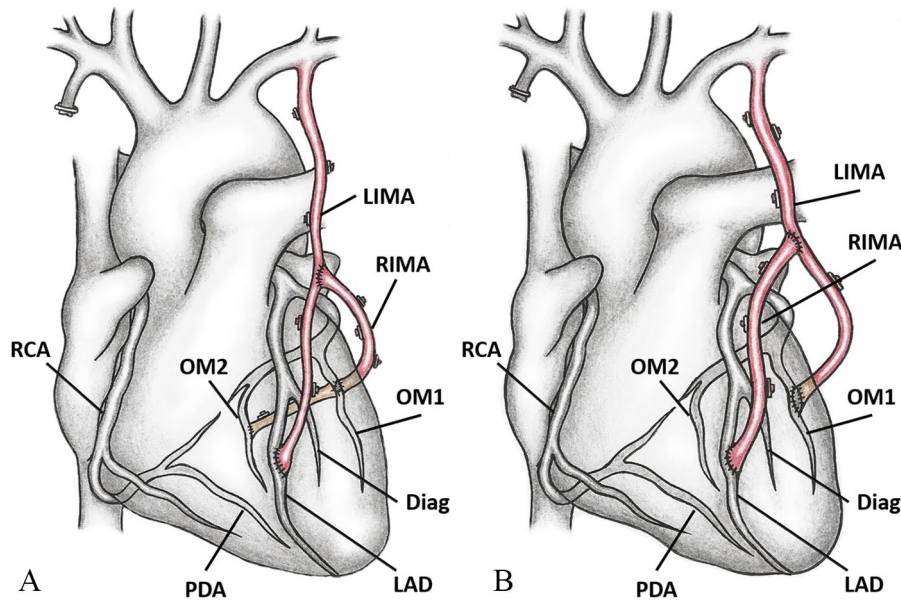
A bloodless surgical field was secured with the use of intraluminal coronary shunts and with a CO<sub>2</sub> blower, in conjunction with moisturization around the arteriotomy site.

The active cooperation of surgical and anaesthesiological team is a crucial requirement to provide a stable haemodynamic condition. The first concern was to maintain the patient's normothermia by keeping the room temperature at 22°C-24°C, using an undermattress heated to 37°C, minimizing blood loss and the wound surface and using intravenous (IV) fluids at body temperature. The increase in the preload of the right ventricle during the anastomoses was achieved by administering IV fluids and the appropriate positioning of the operating table (Trendelenburg position). Finally, in all cases the perfusionist and the CPB were standby during the procedure.

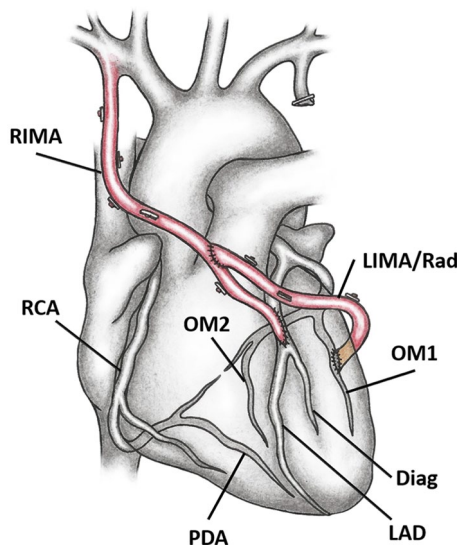
### *Composite grafts*

The cornerstone for achieving full arterial revascularization without manipulation of the aorta was the creation and use of composite arterial grafts. The following compositions were used:

1. *T and Y grafts.* End-to-side anastomosis of the arterial graft, respectively, towards the pedunculated mammary artery. The trunk comprised mainly the in situ LIMA, whereas the limb of the compound graft was the RIMA-free graft (FRIMA), the distal part (4-5 cm) of the LIMA for the short T/Y graft and the radial artery (T/Y radial on LIMA). Left internal mammary artery was in such cases distally anastomosed to the left anterior descending (LAD) and the RIMA or radial artery for the lateral and the posterior wall (Figure 1A). Despite the extra length obtained with skeletonized IMA harvesting, the LIMA may sometimes not reach the distally located anastomotic site on the LAD. In this case, the in situ LIMA is connected to a marginal branch of the circumflex, a free RIMA is anastomosed end-to-side to the LIMA, and its distal end is connected to the LAD (Figure 1B). With the pedunculated RIMA as base, the Y graft was made with the radial artery (Y-radial on RIMA) and the free LIMA (Y-LIMA). Left internal mammary artery was in this case anastomosed to an obtuse marginal branch and a composite RIMA as a free graft to the LAD. Such a reverse composite graft can be used if the proximal LIMA is injured and can no longer be used as an in situ graft. This arrangement of free LIMA on in situ



**Figure 1.** The T or Y technique for arterial composite grafting using the LIMA as in situ graft and the RIMA anastomosed end-to-side to the LIMA as free graft. (A) LIMA is used to revascularize the anterior wall and the RIMA the lateral and posterior walls. (B) LIMA is here anastomosed to the marginal branch of Cx and the RIMA to the LAD. Diag indicates diagonal branch; LAD, left anterior descending; LIMA, left internal mammary artery; OM, obtuse marginal branch; PDA, posterior descending artery; RCA, right coronary artery; RIMA, right internal mammary artery.



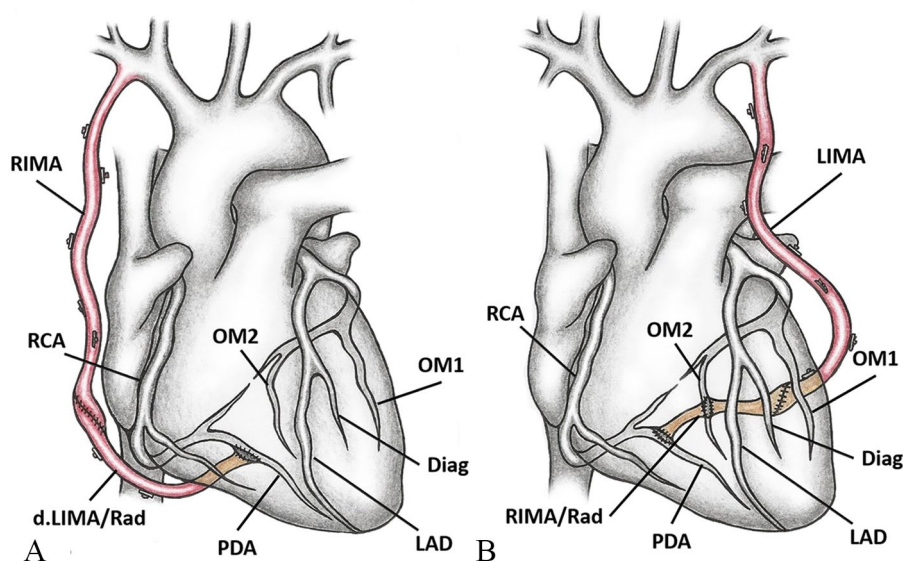
**Figure 2.** The reverse T/Y-graft. The pedunculated RIMA is here used as a base and the T/Y-graft is made using the radial artery or the free LIMA. Diag indicates diagonal branch; LAD, left anterior descending; LIMA, left internal mammary artery; OM, obtuse marginal branch; PDA, posterior descending artery; RAD, radial artery; RCA, right coronary artery; RIMA, right internal mammary artery.

RIMA can also be used when the spontaneous free flow of the LIMA is inadequate. The major advantage is its technical simplicity, highly for off-pump surgery. It is technically less challenging than bringing the RIMA from the lateral wall of the LIMA to the obtuse marginal system. Furthermore, it only requires harvest

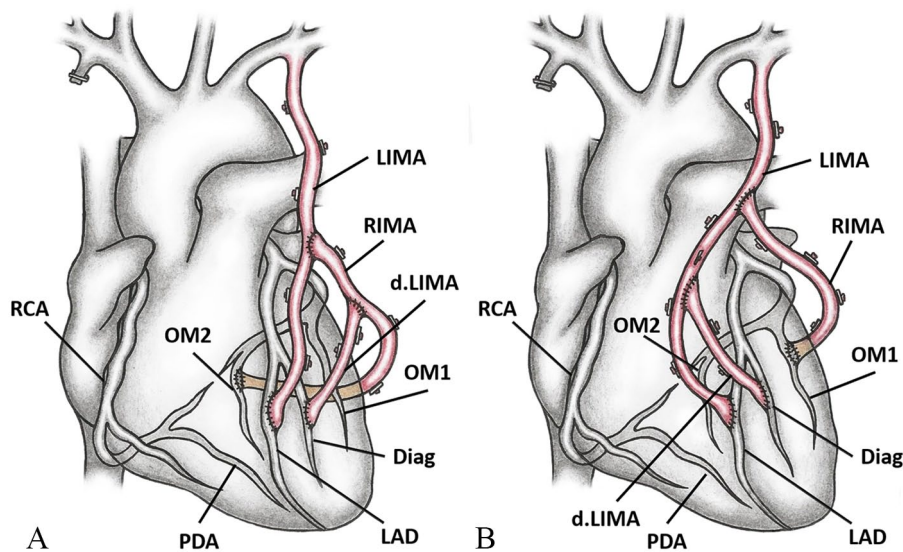
of the proximal two-thirds of the RIMA (Figure 2). When constructing composite grafts, a ‘T’ anastomosis is less likely to kink than a ‘Y’ anastomosis, especially on the lateral wall of the heart.

2. *I graft.* The RIMA grafted to the RCA has a low patency rate,<sup>11,12</sup> especially if the stenosis is less than 80%. Arterial anastomosis on this calcified or fibrotic vessel tends to close, and the more distally located posterior descending artery (PDA) should be preferred for IMA anastomoses. The RIMA may not be long enough to reach the PDA. End-to-end anastomosis of the pedunculated RIMA (on the whole or on the initial pedunculated section) towards the radial artery (I-radial) or the distal section of the LIMA (I-d. LIMA) always with the objective of lengthening the RIMA. A similar elongation of the LIMA with the FRIMA (I-FRIMA) and the radial artery (I-LIMA-radial) was also performed (Figure 3A). This technique may also be in rare cases applied to increase the length of the LIMA to bypass the vessels of the lateral and posterior walls when the LAD does not need to be bypassed (Figure 3B).
3. *II (Pi) graft.* A composite trifurcated graft of our own creation. It is made up of 2 end-to-side anastomoses, either of the FRIMA towards the LIMA (classic T graft) and of the distal free section of the LIMA 4 to 6 cm in length (d.LIMA) towards the T graft (T on T anastomosis; Figure 4A) or alternately both free grafts (FRIMA, d.LIMA) as end-to-side anastomoses





**Figure 3.** The I-graft. The aim of this technique is to increase the length of an in situ arterial graft. (A) Distal LIMA or radial artery is end-to-end anastomosed to the in situ RIMA. (B) RIMA or radial artery is anastomosed to the LIMA. Diag indicates diagonal branch; LAD, left anterior descending; LIMA, left internal mammary artery; OM, obtuse marginal branch; PDA, posterior descending artery; RAD, radial artery; RCA, right coronary artery; RIMA, right internal mammary artery.



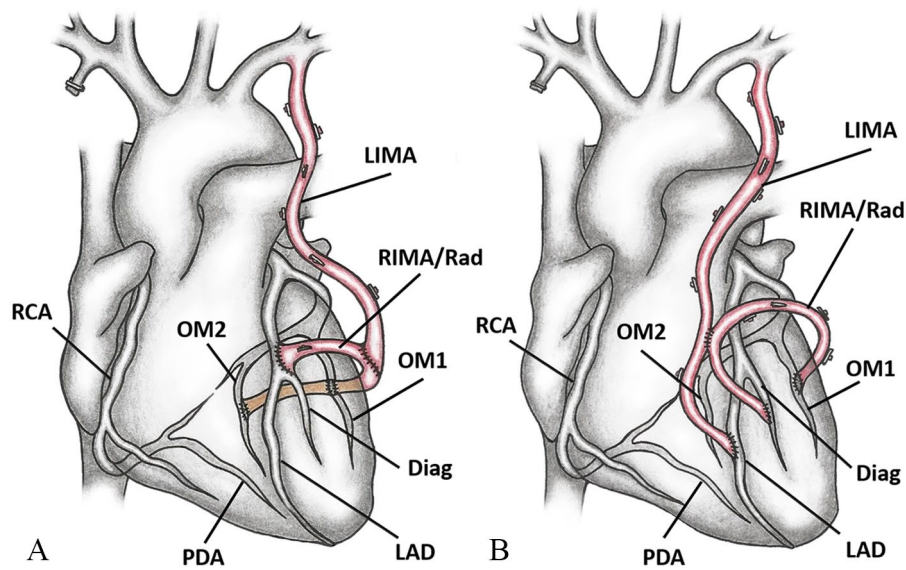
**Figure 4.** The II graft. This composite graft has the shape of the Greek letter 'II'. (A) RIMA is end-to-side anastomosed towards the LIMA (classic T-graft) and the distal-free section of the LIMA (d.LIMA) towards the T graft (T on T anastomosis). (B) Both free grafts (RIMA, d.LIMA) are end-to-side anastomosed towards the LIMA. Diag indicates diagonal branch; d.LIMA, distal left internal mammary artery; LAD, left anterior descending; LIMA, left internal mammary artery; OM, obtuse marginal branch; PDA, posterior descending artery; RCA, right coronary artery; RIMA, right internal mammary artery.

towards the LIMA (Figure 4B). In addition, the technique may use another graft extending the proximal third of the in situ right IMA with the free radial artery for right-sided revascularization.<sup>13</sup>

4.  $\Psi$  (*Psi*) graft. A composition based on the flow of 1 of the 2 pedunculated IMAs. The other, as a free graft, is

anastomatized end-to-side towards the feeder IMA and distally its limbs bridge 2 to 4 target vessels (Figure 5A).

5. *K* graft. Similar to the  $\Psi$  graft, but here the free graft (usually RIMA or radial artery) is anastomosed side-to-side to the feeder graft (usually LIMA), whose distal end can also be anastomosed to a target vessel (Figure 5B).



**Figure 5.** (A) The  $\Psi$  graft. LIMA is used as in situ graft and the free RIMA or radial artery is anastomosed end-to-side to the LIMA. Both distal limbs of the free RIMA or radial artery are anastomosed end-to-side to the target vessels. Sequential side-to-side anastomoses can also be performed. IMAs can be reversed using LIMA as free graft and RIMA in situ. (B) The K graft. The free graft is anastomosed side-to-side to the feeder graft, whose distal end can also be anastomosed to a target vessel. Diag indicates diagonal branch; LAD, left anterior descending; LIMA, left internal mammary artery; OM, obtuse marginal branch; PDA, posterior descending artery; RAD, radial artery; RCA, right coronary artery; RIMA, right internal mammary artery.

### Data collection and analysis

The preoperative baseline characteristics of the patients, operative data, and overall postoperative events were recorded. All statistical tests were performed as a 2-tailed test. Fisher's exact test and chi-square test were used for the data analysis. A  $P$  value  $< .05$  was considered to be statistically significant. Statistical analysis was performed using commercially available statistical software package (SPSS for windows ver. 13).

### Results

A total of 1359 patients who underwent isolated coronary bypass with the use of arterial ' $\pi$ ' circuit were studied. Of them, 1159 patients were men and 200 were women with a mean age  $\pm$  SD of  $64.85 \pm 9.87$  years. The preoperative data are summarized in Table 1.

A mean of  $2.75 \pm 0.92$  distal anastomoses were made per patient, including isolated coronary bypasses. Most of the patients underwent triple coronary bypass grafting (41.4%), whereas 4 patients received 6 distal anastomoses. Bilateral internal mammary artery was used in the overwhelming majority (87.7%) of cases. Furthermore, sequential anastomoses were made in 30.4% of the patients. All surgical data are summarized in Table 2.

In Table 3, the early postoperative complications are described, ranging from very low incidence (psychological disturbances: 0.6%, reexploration for bleeding: 0.7%, and the sternal wound infection: 1%) all the way to the fairly frequent appearance of atrial fibrillation (20%), which was the most frequent complication in our material.

Table 4 shows the overall mortality rates as well as mortality per high-risk patient group during the first postoperative week, the entire hospital stay, and during the 3- to 60-month follow-up period. In-hospital mortality including all subgroups of high-risk patients was 1.5%. The highest in-hospital mortality rates were observed in patients with seriously affected left ventricular function (8.2%) as well as in emergency cases (5.2%).

To analyze the mortality due to cardiac cause during the follow-up period (3-60 months), we made uni- and multivariate analyses of the data. In the univariate analysis, we recognized the following preoperative factors (Tables 5 and 6): female gender, advanced age, Redo operation, renal failure, preoperative heart failure with left ventricular ejection fraction  $\leq 35\%$ , dyslipidaemia, preoperative use of intra-aortic balloon pump (IABP), emergent surgery, as well as lower patient's height, weight, irregular BMI, and body surface area (BSA), as being risk factors for midterm mortality.

The multivariate analysis (Table 7) highlighted the factors of female gender, emergent surgery for coronary revascularization, left ventricular ejection fraction  $\leq 35\%$ , and preoperative use of the intra-aortic balloon as constituting risk factors for middle-term mortality caused by cardiac reasons following surgery for coronary revascularization with the arterial  $\pi$ -circuit method.

### Discussion

Approximately 20% of the coronary revascularization operations are nowadays performed without the use of extracorporeal circulation. There is an increasing number of reports from various international centres highlighting the comparative advantages of such operations.<sup>1,13-21</sup>

**Table 1.** Baseline characteristics of the patients.

VARIABLE	VALUE
Patients, N	1359
Age, mean (SD), years	64.85 (9.87)
Octogenarians, N (%)	62 (4.6)
Female gender, N (%)	200 (14.7)
Diabetes, N (%)	437 (32.2)
Obesity, N (%)	295 (21.7)
Cholesterol > 250mg/dL, N (%)	510 (37.5)
Stroke, N (%)	41 (3)
PVD, N (%)	85 (6.3)
TIA, N (%)	23 (1.7)
GIT disease, N (%)	65 (4.8)
COPD, N (%)	68 (5)
Renal failure, N (%)	109 (8)
Renal dialysis, N (%)	19 (1.4)
Hypertensive patients, N (%)	584 (43)
EF ≤ 30%, N (%)	98 (7.2)
Emergency, N (%)	212 (15.6)
Preoperative IABP, N (%)	27 (2)
First operation, N (%)	1281 (94.3)
Redo operation, N (%)	78 (5.7)

Abbreviations: COPD, chronic obstructive pulmonary diseases; EF, ejection fraction; GIT, gastrointestinal tract; IABP, intra-aortic balloon pump; PVD, peripheral vascular disease; TIA, transient ischaemic attacks.

The application of OPCAB, avoiding the use of heart-lung machine, seems to offer safer revascularization of the myocardium, particularly in high-risk patients: the elderly, those having previously undergone an aortocoronary bypass (Redo), those with acute myocardial infarction, or in cases of impaired heart function.<sup>22,23</sup>

Once surgical coronary revascularization without the use of extracorporeal circulation became feasible, safe, and effective, there was strong questioning and concern over the need to implant grafts in the aorta, as no other manipulation of the aorta was necessary. Atheromatic lesions (moderate or excessive) of the ascending aorta are observed in approximately 13%<sup>24</sup> of the coronary patients. Detachment and embolism of atheromatic matter from surgical manipulations constitute the main cause of perioperative stroke.<sup>25,26</sup> This means that the incidence of such episodes is related to the degree of atheromatosis of the ascending aorta and to the manipulations made during the operation. Moreover, the fact that the presence of aortic atheromatosis shows a linear increase as age

**Table 2.** Operative data of the study population.

OPERATIVE DATA	VALUE
Distal anastomoses, mean ± SD	2.75 ± 0.92
One distal anastomosis, N (%)	105 (7.7)
Two distal anastomoses, N (%)	433 (31.9)
Three distal anastomoses, N (%)	562 (41.4)
Four distal anastomoses, N (%)	221 (16.3)
Five distal anastomoses, N (%)	34 (2.5)
Six distal anastomoses, N (%)	4 (0.6)
One IMA, N (%)	167 (12.3)
Two IMAs, N (%)	1192 (87.7)
Grafts on LIMA, mean ± SD	1.78 ± 0.76
One graft on LIMA, N (%)	535 (39.4)
Two grafts on LIMA, N (%)	616 (45.3)
Three grafts on LIMA, N (%)	181 (13.3)
Four grafts on LIMA, N (%)	21 (1.5)
Five grafts on LIMA, N (%)	6 (0.6)
Sequential anastomoses, N (%)	413 (30.4)
One sequential anastomosis, N (%)	10 (0.7)
Two sequential anastomoses, N (%)	325 (23.9)
Three sequential anastomoses, N (%)	19 (1.4)
Four sequential anastomoses, N (%)	50 (3.7)
Five sequential anastomoses, N (%)	9 (0.7)
Anastomoses on the anterior wall, mean ± SD	1.3 ± 0.56
Anastomoses on the intermittent artery, mean ± SD	0.2 ± 0.4
Anastomoses on the lateral wall, mean ± SD	0.71 ± 0.62
Anastomoses on the inferior wall, mean ± SD	0.51 ± 0.51

Abbreviations: IMA, internal mammary artery; LIMA, left internal mammary artery.

advances<sup>24</sup> and that 1/3 of the patients who undergo coronary bypass today are >70 years of age and rising<sup>27</sup> leads to the conclusion that the problem of atheromatic ascending aorta will continue to grow. In the past, several techniques had been proposed to reduce the risks entailed in manipulating the ascending aorta, such as cannulation of the aortic arch, the innominate, subclavian, or femoral arteries,<sup>28,29</sup> the use of deep hypothermia to prevent aortic occlusion,<sup>30</sup> or even a combined replacement of the ascending aorta and making central anastomoses on the graft.<sup>31,32</sup>

None of the techniques mentioned, however, have proven capable of precluding stroke during surgery. Some of them, in

fact, have been linked to greater morbidity and mortality than usual. Coronary artery bypass grafting on beating heart presents the advantage that no cannula needs to be placed in the aorta, although its partial clamping is required for central anastomoses to be made. Therefore, an OPCAB technique with avoidance of any aortic manipulation is an effective tool to minimize the risk of early strokes.<sup>1,33,34</sup> Off-pump coronary artery bypass surgery

combined with total arterial revascularization can reduce the rate of cerebrovascular accidents up to 75%.<sup>35</sup>

In our material, the absence of neurological complications even in high-risk patients confirmed our conviction that OPCAB arterial revascularization constitutes the safest method regarding the danger of stroke mainly due to the absence of manipulation of the ascending aorta. In this study, we had 3 cases of stroke in the midterm (3-, 9-, and 15 months postoperatively) follow-up, all associated with the coexisting carotid artery disease.

The theoretical advantages of the 'π' circuit are its application without CPB, avoiding any manipulation of the ascending aorta and that purely arterial revascularization of the myocardium can be achieved. At the same time, it is a completely self-regulated circuit, as it is directly connected to systemic circulation through the pedunculated IMA and, as a closed circuit, is subject to the laws of vascular flow regulation. Finally, for the same reasons, it irrigates each branch of the coronary system based on distal outflow.

The technique described is based on the use of both internal mammary arteries. A skeletonized IMA, carefully separated from the accompanying veins and use of metal clips, as described by Cunningham et al<sup>36</sup> in 1992, offers the advantages of the greater length and increased automatic flow of the specific grafts. These main advantages of using a skeletonized IMA are as follows:

1. The option of not using the entire distal portion of the IMA, in which the muscular elements of the tunica media vasorum clearly prevail and the probability of spasm is greater.
2. The fact that a fairly long section of the left IMA is left over after its anastomosis in the middle section of the

**Table 3.** Postoperative events of the study population.

EVENT	VALUE, N (%)
Hospital deaths	21 (1.5)
7-day deaths	3 (0.2)
Stroke	3 (0.2)
Renal failure	30 (2.2)
Pulmonary complications	81 (6)
Prolonged mechanical ventilation (>48 hours)	39 (2.9)
Sternal wound infection	13 (1)
Atrial fibrillation	173 (20)
Reexploration	9 (0.7)
Postoperative IABP	21 (1.5)
Psychological changes	8 (0.6)
GIT complications	36 (2.6)
Recatheterization	32 (2.4)
Reintervention	8 (0.6)
Mid-term mortality	65 (4.8)

Abbreviations: GIT, gastrointestinal tract; IABP, intra-aortic balloon pump.

**Table 4.** Overall mortality rates and mortality per high-risk patient group during the first postoperative week, the hospitalization, and during the 3- to 60-month follow-up period.

	IN-HOSPITAL MORTALITY (%)	7-DAY MORTALITY (%)	MIDTERM (3-60-MONTH) MORTALITY (%)
Total	1.5	0.2	4.8
Octogenarians	3.2	1.6	12.9
Women	4	0.0	9.5
Diabetics	2.3	0.0	4.6
Renal failure	3.7	0.9	13.8
COPD	2.9	1.5	5.9
Redo	2.6	0.0	7.7
Obese patients	1.4	0.3	4.7
Emergencies	5.2	0.0	12.7
EF ≤ 35%	8.2	0.0	17.3

Abbreviations: COPD, chronic obstructive pulmonary diseases; EF, ejection fraction.



**Table 5.** Univariate analysis of preoperative risk factors for midterm mortality after cardiac revascularization with the  $\pi$ -circuit method.

VARIABLE	MORTALITY (%)	OR	95% CI	P VALUE
Female gender	6	3.29	1.60-6.77	.002
Emergencies	9.4	8.43	4.18-16.97	<.0005
Octogenarians	4.8	2.07	0.61-6.98	.20
EF $\leq$ 35%	10.2	0.17	0.079-0.368	<.0005
Diabetes	3.2	1.49	0.74-2.98	.267
Redo	7.7	3.72	1.49-9.29	.011
PVD	3.5	1.46	0.43-4.90	.467
No hyperlipidaemia	3.2	0.42	0.183-0.980	.047
Obesity	1.7	0.61	0.236-1.604	.402
Hypertasis	2.1	0.71	0.35-1.46	.388
Renal failure	5.5	2.54	1.02-6.28	.05
Preoperative stroke	7.3	3.27	0.96-11.19	.085
COPD	1.5	0.56	0.07-4.22	.562
Preoperative IABP	25.9	16.91	6.59-43.36	<.0005
Preoperative GI diseases	1.5	0.59	0.080-4.43	1.00
Use of single IMA	5.4	0.37	0.17-0.82	.094

Abbreviations: CI, confidence interval; COPD, chronic obstructive pulmonary diseases; GI, gastrointestinal; IABP, intra-aortic balloon pump; IMA, internal mammary artery; OR, odds ratio; PVD, peripheral vascular disease.

anterior descending branch and can be used in compositions (to lengthen RIMA, make a ' $\pi$ ' graft, etc.).

3. The approach to the most distal points of the anterior descending branch in cases of sequential anastomosis, to the middle and distal sections of the vessel. Similarly, the easy approach even to the second obtuse marginal branch for direct implantation of the LIMA in cases of crossed revascularization.
4. The option of using pedunculated IMA in patients with emphysema.
5. A safer way to immediately meet the needs of the ischaemic coronary system, especially in cases of multiple revascularization due to the increased automatic flow in the skeletonized IMA.<sup>37</sup>

The aforementioned advantages were obvious in our patients. We did not have a single case of postoperative ischaemia due to spasm of the arterial graft. We believe that besides the more rational use made of the elastic sections of the IMA, the avoidance of extracorporeal circulation, cardioplegia, and hypothermia was significant, as these are factors proven to cause vasospasm. Up to 6 coronary bypasses were made with only 3 arterial grafts—the 2 IMAs and the radial artery—thanks to the increased length of the skeletonized

IMA, the option of making compositions by using the distal third of the LIMA and, finally, the safe and easy application of the technique of sequential anastomosis. The uneventful clinical outcome of these cases demonstrates, at the same time, the sufficient irrigation of up to 6 distal objectives by the natural flow of the 2 skeletonized IMA, confirming the increased reserve IMA flow according to distal needs. Finally, bypasses could be made on the second obtuse marginal branch with direct implantation of the pedunculated LIMA and then jumping the middle and distal sections of the posterior descending branch, due to the sufficient length of the skeletonized LIMA.

Maintenance of the collateral flow to the sternum in skeletonized IMA reduced the likelihood of complications from the surgical wound and thus made it possible to use both IMAs in high-risk patients such as diabetics, patients with chronic obstructive pulmonary disease (COPD), the elderly, and so on. A total of 13 cases of superficial wound infection (0.96%) were observed in this study in, including patients with COPD or diabetes mellitus, patients more than 80 years of age and those chronically on cortisone therapy. Finally, one more advantage we noted during the skeletonization of mammary arteries was the possibility of more precise direct visualization, resulting in the safe management of haemostasis and microtrauma as well



**Table 6.** Univariate analysis of preoperative and intraoperative continuous variables as risk factors for midterm mortality after cardiac revascularization with the  $\pi$ -circuit method.

	CARDIAC MORTALITY	N	MEAN	SD	P VALUE
Age (years)	No	1325	64.7034	9.85255	.001
	Yes	34	70.4706	9.15931	
BSA (m <sup>2</sup> )	No	1325	1.8815	0.16917	<.0005
	Yes	34	1.7621	0.19762	
Height (m)	No	1325	1.6854	0.07865	.001
	Yes	34	1.6391	0.11066	
Weight (kg)	No	1325	78.9547	11.99866	<.0005
	Yes	34	71.1471	11.01826	
BMI	No	1325	27.7679	3.60868	.037
	Yes	34	26.4604	3.19206	
Distal anastomoses	No	1325	2.7600	0.92207	.004
	Yes	34	2.2941	0.90552	
Grafts on LIMA	No	1325	1.7909	0.76513	.028
	Yes	34	1.5000	0.61546	
Grafts on RIMA	No	1325	0.9766	0.67781	.193
	Yes	34	0.8235	0.62622	
Anterior wall anastomoses	No	1325	1.3283	0.56201	.207
	Yes	34	1.2059	0.41043	
Intermittent territory anastomoses	No	1325	0.1977	0.39844	.759
	Yes	34	0.1765	0.38695	
Lateral wall anastomoses	No	1325	0.7132	0.62004	.119
	Yes	34	0.5294	0.66220	
Inferior wall anastomoses	No	1325	0.5094	0.50908	.151
	Yes	34	0.3824	0.49327	

Abbreviations: BMI, body mass index; BSA, body surface area; LIMA, left internal mammary artery; RIMA, right internal mammary artery.

as in the determination of the grafts course, so as to avoid turning or bending, particularly in composite grafts.

In this study, 9 patients (0.7%) were revised for control of postoperative bleeding. Only one of them presented bleeding at the distal anastomosis site. The low rate of postoperative re-sternotomy due to postoperative haemorrhage is, in our opinion, related to: (1) the absence of coagulation disorders associated with CPB, (2) limitation of the surgical trauma while harvesting the IMA, and (3) facilitating the immediate control of haemostasis in the skeletonized grafts and distal anastomoses with the end of the suturing and the flow recovery of the vessel and graft.

The preoperative ingestion of aspirin until the date of surgery in operations using CPB was studied in various patient

series. Sustained ingestion until the day of surgery in elective can result in excessive bleeding, increased rate of reexploration, and need for more transfusions.<sup>38</sup> A recent comparative study of patients undergoing surgery without the use of extracorporeal circulation with or without discontinuing aspirin preoperatively showed a similar incidence of complications associated with haemorrhage.<sup>39</sup> Interruption of aspirin administration is no longer suggested.

In urgent cases or elective cases with the indication to continue aspirin until the day of surgery, no comparative increase in blood loss or in frequency of the need to reopen patients was observed, a fact attributed to the absence of coagulation disturbances such as those seen with the classical method.

**Table 7.** Multivariate analysis of preoperative risk factors and intraoperative variables for midterm mortality after coronary revascularization with the  $\pi$ -circuit method.

VARIABLE	OR	95% CI	P VALUE	
Female gender	2.403	1.050	5.498	.038
Emergency	5.733	2.602	12.632	.000
EF	0.420	0.175	1.010	.053
Obesity	1.493	0.390	5.705	.558
Diabetes	1.524	0.721	3.222	.270
PVD	2.280	0.653	7.955	.196
Cholesterol	0.882	0.350	2.226	.791
Arterial hypertension	0.853	0.378	1.923	.701
Renal failure	1.479	0.556	3.938	.433
Preoperative IABP	6.298	2.055	19.305	.001
Redo	2.350	0.775	7.129	.131
Single IMA	0.610	0.196	1.894	.392
Age	0.039	0.995	1.085	.084
BMI	0.954	0.838	1.086	.476
Distal anastomoses	1.025	0.148	7.119	.980
Grafts on LIMA	0.481	0.110	2.112	.332
Grafts on RIMA	0.595	0.166	2.133	.426
Anterior wall anastomoses	1.224	0.216	6.919	.819
Intermittent territory anastomoses	0.962	0.160	5.790	.967
Lateral wall anastomoses	0.946	0.148	6.066	.954
Inferior wall anastomoses	1.099	0.193	6.272	.915

Abbreviations: BMI, body mass index; CI, confidence interval; EF, ejection fraction; IABP, intra-aortic balloon pump; IMA, internal mammary artery; LIMA, left internal mammary artery; OR, odds ratio; PVD, peripheral vascular disease; RIMA, right internal mammary artery.

The use of the IMA offers excellent long-term clinical results. It has now been substantiated that patients who receive both IMA have a more favourable middle- and long-term result.<sup>12,40</sup>

Theoretically, the harvesting of both IMAs increases the risk of complications from the sternotomy wound.<sup>41,42</sup> However, the skeletonized IMA in conjunction with the maintenance of the glycosylated haemoglobin at normal levels during the postoperative phase<sup>43</sup> showed a minimization of the incidence of sternotomy infection. Sternal wound infection has been observed in patients in whom both IMAs were used as well as in type II diabetic patients in whom both IMAs were used. Diabetics are, on one hand, more prone to inflammation and, on the other hand, present difficulty in wound healing. For this reason, many surgeons avoid using both internal thoracic arteries to avoid the dangers this could entail, even in insulin-dependent patients in whom the results of the use of both thoracic arteries are positive in the long term.<sup>44</sup> The increased risk

of complications from the sternotomy wound is due to the fact that sternal perfusion is mainly provided by branches of the mammary artery. With the classical method, the possibility of perioperative wound-related complications is 6.9% to 8.5% and is associated with other factors, such as diabetes, obesity, chronic obstructive pulmonary disease, extended length of the operation, number of transfusions, and duration of respiratory support.<sup>45</sup> In this study, sternal wound complications were minimal, despite the fact that some of the patients were at high risk. We attribute the low incidence of wound infection in our patients to: (1) matters regarding surgical technique, such as the preparation of skeletonized mammary arteries without use of diathermy, sternal closure with 'figure of 8' sutures alternated with isolated sutures, and the closure of soft tissues in diabetic and obese patients with single interrupted sutures; (2) the absence of extracorporeal circulation, which indirectly results in the prevention of intracellular tissue oedema, less respiratory burdening, a shorter stay in the intensive care unit (ICU), and

less time on mechanical respiratory support. In our series, 84% of the patients spent 24 hours in the ICU, 13% spent 48 hours, and only 3% spent more than 2 days; (3) minimal or, as a rule, no administration of blood or blood products; (4) the absence of extensive haemostasis with diathermy in the mammary arterial beds; (5) the careful regulation of preoperative glucose levels in diabetic patients; (6) the adjustment of prophylactic antibiotic doses to the body weight of obese patients; and (7) the earlier extubation of patients with acute respiratory problems.

The preferred 'diversion' of the IMA was bilateral direct implantation, which was, however, feasible in only a few cases. The end-to-end anastomosis of the surplus distal section of the LIMA towards the pedunculated RIMA to elongate it made it possible to circumvent more distal branches, whereas its end-to-side anastomosis towards the main IMA trunk (short 'T' graft) allowed us to bypass an oblique or intervening branch. The classical use of the free RIMA to bypass marginal branches means that a central anastomosis of the graft must be made in the aorta. But the description of the technique comprising its end-to-side anastomosis towards the pedunculated LIMA ('T' graft) by Mills<sup>46</sup> and Sauvage<sup>47</sup> at the beginning of the eighties was combined with better results noted in the long term. Thus, we preferred to make a long 'T' graft when required. Finally, the ascertainment that a free IMA segment implanted in the *in situ* IMA has the same long-term patency and that the reserve flow of a pedunculated IMA is commensurate to the distal outflow and approaches 3 times the flow required for full myocardial revascularization led us to make composite grafts, such as our own ' $\pi$ ' graft and then sequential anastomoses from some limb of the composite graft.

At this point, it should be stressed that sequential anastomoses on beating are performed in the most reliable way, as the measurements are made based on the heart's natural size and volume. The same holds for calculation of the suitable length of the graft and for determination of the exact site for the 'T' anastomosis to be made. Moreover, normothermia in the beating heart technique prevents spasms in arterial grafts. We should also mention that when the graft is of borderline length for the lateral wall of the heart (pedunculated LIMA or free limb 'T' graft), we made the end-to-side distal anastomosis, not lengthwise as usual, but rather with the graft perpendicular to the arteriotomy. Thus, we could achieve optimal orientation of the graft and avoid turning it at the distal anastomosis site, as its lengthwise implantation requires sufficient length for it to be able to follow the course of the atrioventricular sulcus and run parallel with the natural vessel to the implantation site. We followed the same rule, that is, the perpendicular distal anastomosis, when making sequential anastomoses in the intervening and marginal branches or in 2 marginal branches of the circumflex, believing that this minimizes the likelihood of the graft torsion or twisting, as its straight course is set between 3 points (the origin, side-to-side, and end-to-side anastomosis).

Regarding the right coronary system, in those cases in which we did not use isolated or elongated RIMA, we preferred to create a composite arterioarterial graft with an end-to-end anastomosis of the free left radial artery towards the central part of the pedunculated RIMA. In these cases, we used the free RIMA to make a 'T' graft in the left system, owing to (1) the better 'match' of the vascular sulci, (2) the proven good long-term results of the 'T' graft with the use of mammary arteries, and (3) their proven better long-term patency. As third graft we used the radial artery. Its superiority against venous grafts is already well experienced.<sup>48</sup> Our preference for a radial artery rather than a gastro-epiploic artery is due to the ease with which the former can be prepared, the fact that its use is free of complications and the very good results shown in long-term studies.<sup>49</sup>

Taking the patient off the mechanical ventilation quickly, the maintaining of closed hemithoraces while harvesting IMA and the rapid ambulation of patients, given the absence of surgical wounds in the lower extremities, greatly limited respiratory complications. Thus, we were able to apply the method safely in patients afflicted with chronic respiratory failure.<sup>50</sup>

The gastrointestinal tract (GIT) is one of the first systems to suffer ischaemic damage under conditions of haemodynamic collapse. The main factor, however, that makes any GIT complication one of the most serious in the field of cardiac surgery is that any disturbance of the intestinal barrier leads to systemic inflammation and multi-system organ failure. For this reason, gastrointestinal complications, although rare, are associated with very high mortality.<sup>51,52</sup> The OPCAB procedure is associated with lower gastrointestinal ischaemia-related mortality rates.<sup>53</sup> This was confirmed in our research: we had death of 1 patient due to multisystem organ failure following a GIT complication against a background of acute distal angiopathy. Moreover, GIT dysphagia along with atrial fibrillation constituted the 2 minor complications that were of concern to us during the postoperative period.

A considerable part of the analysis regarded the recognition of factors involved in mid-term mortality. After multivariate analysis of middle-term (3-60 months) mortality due to cardiac causes in patients who had undergone coronary revascularization surgery with the use of the arterial  $\pi$ -circuit, we recognized the following factors: (1) gender, as women have greater probability (odds ratio [OR]=2.4, confidence interval [CI]=1.05-5.49) of dying from cardiac causes than men; (2) emergent surgery, as individuals undergoing such operations are more likely to die of cardiac causes than are those undergoing elective surgery (OR=5.73, CI=2.60-12.63); (3) the ejection fraction, as patients with a low EF are more likely to die from cardiac reasons than patients with a good or moderate EF (OR=0.42, CI=0.17-1.01); and, finally, (4) preoperative use of an IABP, as patients with an IABP are 6.3 times more prone to die of cardiac causes than are those without an IABP (OR=6.29, CI=2.05-19.30) following coronary revascularization with the use of the arterial  $\pi$ -circuit.

## Conclusions

Conclusively, we could say that application of the  $\pi$ -circuit has proven to be a safe and effective choice in the management of coronary disease patients. Patients from all-risk groups underwent surgery and were included in the study. Thus, the overall results reflect the method's effectiveness for the population as a whole. We believe that it can now constitute the method of choice for the management of all patients with surgical coronary disease.

## Author Contributions

SNP conceived the idea, was the surgeon who performed all the operations, wrote the first draft and led the project from beginning to end. IAP took part in all cases, co-wrote the first draft, assisted designing the study, contributed to data collection and provided expert opinion. VNL assisted the study in data collection, literature review, draft revision, figure design and coordinating with all co-authors. INL took part in many of the operations and offered expert opinion on this issue. KPK, VSP, and KG helped with discussions about the topic and assistance in manuscript writing. All authors critically read, discussed and approved the final draft of the manuscript.

## ORCID iD

Vasileios N Leivaditis  <https://orcid.org/0000-0001-8692-0059>

## REFERENCES

- Lytle BW, Loop FD, Cosgrove DM, Ratliff NB, Easley K, Taylor PC. Long-term (5 to 12 years) serial studies of internal mammary artery and saphenous vein coronary bypass grafts. *J Thorac Cardiovasc Surg.* 1985;89:248-258.
- Campeau L, Enjalbert M, Lespérance J, et al. The relation of risk factors to the development of atherosclerosis in saphenous-vein bypass grafts and the progression of disease in the native circulation: a study 10 years after aortocoronary bypass surgery. *N Engl J Med.* 1984;311:1329-1332.
- Ascione R, Angelini GD. OPCAB surgery: a voyage of discovery back to the future. *Eur Heart J.* 2003;24:121-124.
- Buffolo E, Andrade JC, Succi J, Leão LE, Gallucci C. Direct myocardial revascularization without cardiopulmonary bypass. *Thorac Cardiovasc Surg.* 1985;33:26-29.
- Benetti FJ, Naselli G, Wood M, Geffner L. Direct myocardial revascularization without extracorporeal circulation. Experience in 700 patients. *Chest.* 1991;100:312-316.
- Moller CH, Steinbruechel DA. Off-pump versus on-pump coronary artery bypass grafting. *Curr Cardiol Per.* 2014;16:455.
- Urso S, Sadaba JR, Pettinari M. Impact of off-pump to on-pump conversion rate on post-operative results in patients undergoing off-pump coronary artery bypass. *Interact Cardiovasc Thorac Surg.* 2012;14:188-193.
- Demaria RG, Carrier M, Fortier S, et al. Reduced mortality and strokes with off-pump coronary artery bypass grafting surgery in octogenarians. *Circulation.* 2002;106:15-110.
- Chamberlain MH, Ascione R, Reeves BC, Angelini GD. Evaluation of the effectiveness of off-pump coronary artery bypass grafting in high-risk patients: an observational study. *Ann Thorac Surg.* 2002;73:1866-1873.
- Lytle BW, Blackstone EH, Loop FD, et al. Two internal thoracic artery grafts are better than one. *J Thorac Cardiovasc Surg.* 1999;117:855-872.
- Endo M, Nishida H, Tomizawa Y, Kasanuki H. Benefit of bilateral over single internal mammary artery grafts for multiple coronary artery bypass grafting. *Circulation.* 2001;104:2164-2170.
- Navia DO, Vrancic M, Piccinini F, et al. Myocardial revascularization exclusively with bilateral internal thoracic arteries in T-graft configuration: effects on late survival. *Ann Thorac Surg.* 2016;101:1775-1781.
- Prapas SN, Anagnostopoulos CE, Kotsis VN, et al. A new pattern for using both thoracic arteries to revascularize the entire heart: the pi-graft. *Ann Thorac Surg.* 2002;73:1990-1992.
- Sabik JF, Gillinov AM, Blackston EH, et al. Does off-pump coronary surgery reduce morbidity and mortality? *J Thorac Cardiovasc Surg.* 2002;124:698-707.
- Boening A, Friedrich C, Hedderich J, Schoettler J, Fraund S, Cremer JT. Early and medium-term results after on-pump and off-pump coronary artery surgery: a propensity score analysis. *Ann Thorac Surg.* 2003;76:2000-2006.
- Khan NE, De Souza A, Mister R, et al. A randomized comparison of off-pump and on-pump multivessel coronary-artery bypass surgery. *N Engl J Med.* 2004;350:21-28.
- Mack MJ, Pfister A, Bachand D, et al. Comparison of coronary bypass surgery with and without cardiopulmonary bypass in patients with multivessel disease. *J Thorac Cardiovasc Surg.* 2004;127:167-173.
- Puskas JD, Williams WH, Mahoney EM, et al. Off-pump vs conventional coronary artery bypass grafting: early and 1-year graft patency, cost, and quality-of-life outcomes: a randomized trial. *JAMA.* 2004;291:1841-1849.
- Racz MJ, Hannan EL, Isom OW, et al. A comparison of short- and long-term outcomes after off-pump and on-pump coronary artery bypass graft surgery with sternotomy. *J Am Coll Cardiol.* 2004;43:557-564.
- Dato GA, Picichè M. Off-pump techniques of surgical myocardial revascularization. *Rev Recent Clin Trials.* 2019;14:116-119.
- Puskas JD, Kilgo PD, Lattouf OM, et al. Off-pump coronary bypass provides reduced mortality and morbidity and equivalent 10-year survival. *Ann Thorac Surg.* 2008;86:1139-1146; discussion 1146.
- Stamou SC, Corso PJ. Coronary revascularization without cardiopulmonary bypass in high-risk patients: a route to the future. *Ann Thorac Surg.* 2001;71:1056-1061.
- Fattouch K, Guccione F, Dioguardi P, et al. Off-pump versus on-pump myocardial revascularization in patients with ST-segment elevation myocardial infarction: a randomized trial. *J Thorac Cardiovasc Surg.* 2009;137:650-656; discussion 656-667.
- Wareing TH, Davila-Roman DJ, Barzilai B, Murphy SF, Kouchoukos NT. Management of the severely atherosclerotic ascending aorta during cardiac operations. A strategy for detection and treatment. *J Thorac Cardiovasc Surg.* 1992;103:453-462.
- Roach GW, Kanchuger M, Mangano CM, et al. Adverse cerebral outcomes after coronary bypass surgery. *N Engl J Med.* 1996;335:1857-1863.
- Murkin JM. Etiology and incidence of brain dysfunction after cardiac surgery. *J Cardiothorac Vasc Anesth.* 1999;13:12-7; discussion 36-37.
- Grover FL. The Society of Thoracic Surgeons National Database: current status and future directions. *Ann Thorac Surg.* 1999;68:367-373; discussion 374-376.
- Leyh RG, Bartels C, Nötzold A, Sievers HH. Management of porcelain aorta during coronary artery bypass grafting. *Ann Thorac Surg.* 1999;67:986-988.
- Sabik JF, Lytle BW, McCarthy PM, Cosgrove DM. Axillary artery: an alternative site of arterial cannulation for patients with extensive aortic and peripheral vascular disease. *J Thorac Cardiovasc Surg.* 1995;885-890; discussion 890-891.
- Mills NL, Everson CT. Atherosclerosis of the ascending aorta and coronary artery bypass. Pathology, clinical correlates, and operative management. *J Thorac Cardiovasc Surg.* 1991;102:546-553.
- Stern A, Tunick PA, Culliford AT, et al. Protruding aortic arch atheromas: risk of stroke during heart surgery with and without aortic arch endarterectomy. *Am Heart J.* 1999;138:746-752.
- Calafiore AM, Di Mauro M, Teodori G, et al. Impact of aortic manipulation on incidence of cerebrovascular accidents after surgical myocardial revascularization. *Ann Thorac Surg.* 2002;73:1387-1393.
- Albert A, Ennker J, Hegazy Y, et al. Implementation of the aortic no-touch technique to reduce stroke after off-pump coronary surgery. *J Thorac Cardiovasc Surg.* 2018;156:544-554.e4.
- Head SJ, Milojevic M, Taggart DP, Puskas JD. Current practice of state-of-the-art surgical coronary revascularization. *Circulation.* 2017;136:1331-1345.
- Prapas S, Calafiore AM, Katsavrias KP, et al. Anaortic coronary surgery using the II-circuit is associated with a low incidence of perioperative neurological complications. *Eur J Cardiothorac Surg.* 2018;154:884-888.
- Cunningham JM, Charavi MA, Fardin R, Meek RA. Considerations in the skeletonization technique of internal mammary artery dissection. *Ann Thorac Surg.* 1992;54:947-950.
- Choi JB, Lee SY. Skeletonized and pedicled internal thoracic artery grafts: effect on free flow during bypass. *Ann Thorac Surg.* 1996;61:909-913.
- Sharifi M, Kamali A, Ghandi Y. Effect of sustained use of aspirin until the time of surgery on outcomes following coronary artery bypass grafting: a randomized clinical trial. *Thorac Cardiovasc Surg.* 2018;66:442-451.
- Srinivasan AK, Grayson AD, Pullan DM, Fabri BM, Dihmis WC. Effect of preoperative aspirin use in off-pump coronary artery bypass operations. *Ann Thorac Surg.* 2003;76:41-45.
- Kurlansky PA, Traad EA, Galbut DL, Singer S, Zucker M, Ebra G. Coronary bypass surgery in women: a long-term comparative study of quality of life after



- bilateral internal mammary artery grafting in men and women. *Ann Thorac Surg.* 2002;74:1517-1525.
41. Calafiore AM, Di Mauro M, Di Giammarco G, et al. Single versus bilateral internal mammary artery for isolated first myocardial revascularization in multi-vessel disease: long-term clinical results in medically treated diabetic patients. *Ann Thorac Surg.* 2005;80:888-895.
  42. Matsa M, Paz Y, Gurevitch J, et al. Bilateral skeletonized internal thoracic artery grafts in patients with diabetes mellitus. *J Thorac Cardiovasc Surg.* 2001;121:668-674.
  43. Furnary AP, Zerr KJ, Grunkemeier GL, Starr A. A continuous intravenous insulin infusion reduces the incidence of deep sternal wound infection diabetic patients after cardiac surgical procedures. *Ann Thorac Surg.* 1999;67:352-360.
  44. Momin AU, Deshpande R, Potts J, et al. Incidence of sternal infection in diabetic patients undergoing bilateral thoracic artery grafting. *Ann Thorac Surg.* 2005;80:1765-1772.
  45. Culliford AT, Cunningham JN, Zeff RH, Isom OW, Teiko P, Spencer FC. Sternal and costochondral infections following open-heart surgery: a review of 2,594 cases. *J Thorac Cardiovasc Surg.* 1976;72:714-726.
  46. Mills NL. Physiologic and technical aspects of internal mammary artery coronary artery bypass grafts. In: Cohn LH, ed. *Modern Techniques in Surgery. Cardio-Thoracic Surgery.* Vol 48. Mt. Kisco, NY: Futura; 1982:1-19.
  47. Sauvage LR. Extensive myocardial revascularization using only internal thoracic arteries for grafting the anterior descending, circumflex and right systems. In: Meyens WO, ed. *CABG Update. Part 11. Cardiac Surgery State of the Art Reviews.* Vol. 6. Philadelphia, PA: Hanky and Belfus; 1992:397-419.
  48. Virk HUH, Lakhter V, Ahmed M, O'Murchu B, Chatterjee S. Radial artery versus saphenous vein grafts in coronary artery bypass surgery: a literature review. *Curr Cardiol Rep.* 2019;21:36.
  49. Tatoulis J, Royse AG, Buxton BF, et al. The radial artery in coronary surgery: a 5-year experience – clinical and angiographic results. *Ann Thorac Surg.* 2002;73:143-147; discussion 147-148.
  50. Prapas SN, Panagiotopoulos IA, Hamed Abdelsalam A, et al. Predictors of prolonged mechanical ventilation following aorta no-touch off-pump coronary artery bypass surgery. *Eur J Cardiothorac Surg.* 2007;32:488-492.
  51. Ohri SK, Desai JB, Gaer JA, et al. Intraabdominal complications after cardiopulmonary bypass. *Ann Thorac Surg.* 1991;52:826-831.
  52. Zacharias A, Schwann TA, Paranteau GL, et al. Predictors of gastrointestinal complications in cardiac surgery. *Tex Heart Inst J.* 2000;27:93-99.
  53. Emmiler M, Yaveri A, Koçoğullari CU, et al. Gastrointestinal ischemia related mortality in patients undergoing off- or on-pump coronary artery bypass grafting. *Heart Surg Forum.* 2009;12:E79-E84.