

Epiretinal Membrane Peeling as the Treatment for Macular Edema Associated with Isolated Retinal Astrocytic Hamartoma

Carlos Cuadros Sánchez¹, Beatriz de Luis Eguileor¹, Cristina Sacristán Eguén¹, Ana Arce Soto¹, Nerea Martínez Alday¹

¹Retina Unit, Department of Ophthalmology, Cruces University Hospital, Barakaldo, Vizcaya, Spain

Abstract

Purpose: To report a case of macular edema and an epiretinal membrane in an isolated astrocytic hamartoma treated surgically.

Methods: Case report.

Results: We describe the case of a 37-year-old woman whose first symptoms were blurred vision and metamorphopsia. Optical coherence tomography revealed macular edema together with an epiretinal membrane secondary to an isolated retinal astrocytic hamartoma. We performed a pars plana vitrectomy (PPV) with membrane peeling. Both visual and structural outcomes were satisfactory. Complete resolution of symptoms was obtained, and visual acuity was preserved after a 7-month follow-up.

Conclusion: Although rare, epiretinal membrane may be present in isolated retinal astrocytic hamartomas, PPV and epiretinal membrane peeling may be a good treatment option in glial tumors with macular edema associated with an epiretinal membrane.

Keywords: Epiretinal membrane, Macular edema, Pars plana vitrectomy, Retinal astrocytic hamartoma

Address for correspondence: Carlos Cuadros Sánchez, Plaza de Cruces S/N, 48903, Barakaldo, Spain.

E-mail: cuadrosc_s@hotmail.com

Submitted: 08-Feb-2021; **Revised:** 27-Apr-2021; **Accepted:** 08-May-2021; **Published:** 06-Jan-2022

INTRODUCTION

Isolated retinal astrocytic hamartomas are glial tumors that are generally benign, relatively uncommon, and very often asymptomatic.¹ To obtain an adequate diagnosis, it is essential to use imaging, such as optical coherence tomography (OCT), multimodal imaging, and fluorescein angiography.²

Complications associated with this type of tumor have been described, but no specific treatment has been established given the variable presentation.^{1,3} Treatment options include pars plana vitrectomy (PPV), photodynamic therapy, argon laser photocoagulation, or even close observation.^{3,4} Studies published to date have not established an association between retinal astrocytic hamartomas and epiretinal membrane.

CASE REPORT

We report the case of a 37-year-old woman with a history of inflammatory bowel disease. She sought medical attention due to a 2-month history of blurred vision in the upper hemifield of the right eye together with metamorphopsia. No previous events of uveitis or painful red eye had ever been reported by the patient.

The ophthalmologic examination revealed distance visual acuity (VA) of 20/20 and an abnormal Amsler grid referred as metamorphopsia in the upper area. There was no relative afferent pupillary defect, inflammation of the anterior chamber, or dyschromatopsia, and the patient's left eye was completely normal. At the level of the posterior pole, the only relevant finding was a juxtapapillary retinal lesion with a mulberry-like appearance and intratumoral calcifications [Figure 1]. In a

This is an open access journal, and articles are distributed under the terms of the Creative Commons Attribution-NonCommercial-ShareAlike 4.0 License, which allows others to remix, tweak, and build upon the work non-commercially, as long as appropriate credit is given and the new creations are licensed under the identical terms.

For reprints contact: WKHLRPMedknow_reprints@wolterskluwer.com

How to cite this article: Cuadros Sánchez C, de Luis Eguileor B, Sacristán Eguén C, Arce Soto A, Martínez Alday N, Soto AA. Epiretinal membrane peeling as the treatment for macular edema associated with isolated retinal astrocytic hamartoma. *J Curr Ophthalmol* 2021;33:496-8.

Access this article online

Quick Response Code:



Website:
www.jcurrophthalmol.org

DOI:
10.4103/joco.joco_49_21

24-2 Humphrey visual-field test, an enlarged blind spot was observed, corresponding to the lesion in the fundus of the eye. OCT showed a hyperreflective lesion in the inner retinal layers with complete retinal disorganization and internal moth-eaten spaces [Figure 2]. All these findings are strongly suggestive of isolated retinal astrocytic hamartoma. At the macular level, the epiretinal membrane was observed together with intraretinal fluid [Figure 3a], which was responsible for the patient's symptoms. Brain imaging and genetic tests were performed to investigate potential previously undiagnosed tuberous sclerosis, neurofibromatosis, and other types of systemic disease, but the results of all these tests were negative.

After an 8-month follow-up of observation (no medical treatment was used), given the persistence of the symptoms, the presence of the macular edema, and despite the good VA (20/20), we decided to perform three-port 23-gauge PPV with epiretinal membrane peeling using double staining and air–fluid exchange. Unfortunately, no anatomopathological or immunohistochemical study of the epiretinal membrane was possible due to technical issues. Topical steroids were tapered at the most recent follow-up. Seven months after surgery, the patient was totally asymptomatic with no metamorphopsia (although no objective test was performed beside an Amsler grid). Her distance VA was 20/20, and we observed that the retinal fluid had completely disappeared and the foveal contour was in a better condition [Figure 3b]. The visual field defect remained completely stable, given that the enlargement of the blind spot corresponded anatomically to the intraretinal portion of the tumor that was not touched in the surgery.

DISCUSSION

Retinal astrocytic tumors are a group of tumors derived from the same cell lineage.¹ They are generally benign but may be a source of confusion given their variability and the range of names used to describe them; factors that have hindered their recording and analysis. The most studied are retinal

astrocytic hamartomas, also known as retinal astrocytomas, associated with systemic diseases, such as tuberous sclerosis and neurofibromatosis.² Their diagnosis may be difficult, but with the help of OCT, it has been shown that they have very characteristic patterns, as described in several studies. Specifically, various types of astrocytic hamartomas have been identified with an abnormal retinal structure that may involve some or all retinal layers, lesions with a moth-eaten appearance, and intraretinal calcifications in older patients.^{2,5,6} These tumors are benign and self-limiting, although complications have been described, including vitreous hemorrhage, exudative retinal detachments, and neovascularization, for which several types of treatment have been proposed, even though spontaneous resolution has been described in patients with macular edema and exudative detachment of the retina.^{3,7}

In contrast, the type of tumor in our patient, an astrocytic tumor, is not associated with any phakomatoses. Ophthalmoscopy, OCT, and multimodal imaging yielded very similar findings to that in tuberous sclerosis.² When such tumors are not associated with tuberous sclerosis, there is much greater variability in terminology, with several names for the same condition. However, a single name has been proposed, namely, isolated retinal astrocytic hamartoma.² The rate of complications associated with these tumors is much lower than that associated with tuberous sclerosis, and their growth and dissemination are generally much slower,² though some studies have reported completely the opposite.⁸

Shields *et al.*⁵ found astrocytic hamartomas in combination with macular edema, intraretinal edema, and retinal traction on the surface of the tumor in 20%, 27%, and 27% of cases, respectively. No studies have observed an association with the presence of epiretinal membrane or metamorphopsia as observed in our case. Some authors have reported spontaneous resolution of the macular edema in retinal astrocytic hamartomas associated with tuberous sclerosis.^{3,9} In our patient, however, the condition was unlikely to resolve

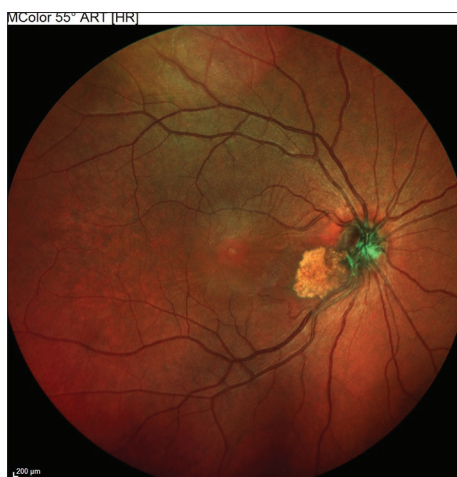

Figure 1: Retinography image, fundus of the eye showing juxtapapillary tumor lesion

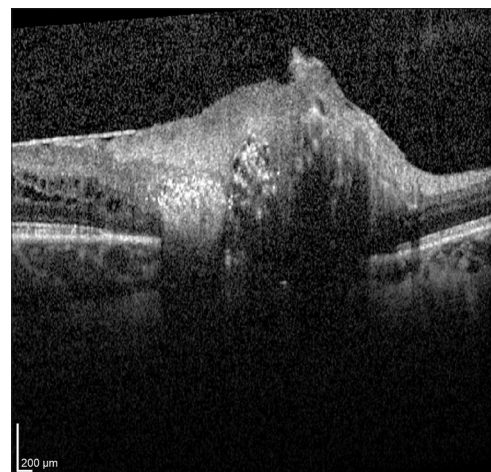


Figure 2: Optical coherence tomography image of the tumor, complete retinal disorganization, intratumoral calcified lesions, and internal moth-eaten spaces

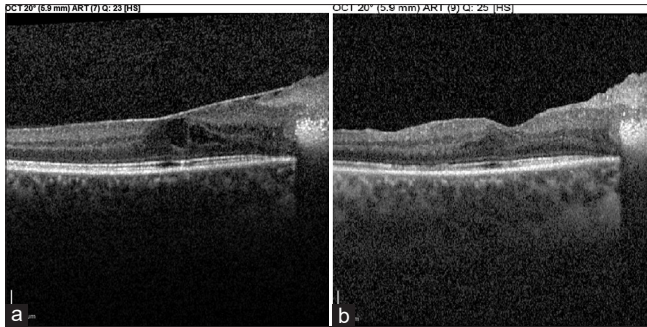


Figure 3: Macular optical coherence tomography, (a) Epiretinal membrane with subfoveal intraretinal fluid prior to surgery, (b) intact foveal contour with resolution of the subfoveal edema after surgery with no epiretinal membrane

spontaneously due to the anatomical changes caused by the epiretinal membrane, and for this reason, she was treated surgically after an 8-month follow-up. In our research of the literature, we have not found any similar procedures used to treat metamorphopsia or macular edema in this type of tumor. We have not even found any association between an isolated retinal astrocytic hamartoma and an epiretinal membrane.

The use of epiretinal membrane peeling has been reported in other types of tumors with significant vitreoretinal traction, as is the case in combined hamartoma of the retina and retinal pigment epithelium, seeking to avoid a retinal tear or detachment.¹⁰ In our case, the treatment was relatively successful, achieving resolution of the macular edema and the epiretinal membrane, and most importantly, complete resolution of the metamorphopsia, while the patient maintained her excellent VA.

For this reason, PPV plus an epiretinal membrane peeling could be considered as a potential treatment for macular edema associated with an epiretinal membrane in intraretinal tumors. However, it will be necessary to wait for a higher number of cases to be reported or for further studies before more definite conclusions can be drawn.

Patient consent

Consent to publish this case report has been obtained from the patient.

Declaration of patient consent

The authors certify that they have obtained all appropriate patient consent forms. In the form, the patient has given her consent for her images and other clinical information to be reported in the journal. The patient understand that name and initials will not be published and due efforts will be made to conceal identity, but anonymity cannot be guaranteed.

Financial support and sponsorship

Nil.

Conflicts of interest

There are no conflicts of interest.

REFERENCES

1. Shields J, Shields CL. Intraocular Tumors an Atlas and Textbook. In: Shields JA, Shields CL, editors. 2nd ed. Philadelphia, PA: Lippincott Williams and Wilkins; 2009.
2. Stacey AW, Pefkianaki M, Ilginis T, Michaelides M, Hykin P, Webster A, *et al.* Clinical features and multi-modality imaging of isolated retinal astrocytic hamartoma. *Ophthalmic Surg Lasers Imaging Retina* 2019;50:e1-9.
3. Mennel S, Meyer CH, Peter S, Schmidt JC, Kroll P. Current treatment modalities for exudative retinal hamartomas secondary to tuberous sclerosis: Review of the literature. *Acta Ophthalmol Scand* 2007;85:127-32.
4. Shields JA, Shields CL. Glial tumors of the retina. The 2009 King Khaled Memorial Lecture. *Saudi J Ophthalmol* 2009;23:197-201.
5. Shields CL, Benevides R, Materin MA, Shields JA. Optical coherence tomography of retinal astrocytic hamartoma in 15 cases. *Ophthalmology* 2006;113:1553-7.
6. Pichi F, Massaro D, Serafino M, Carrai P, Giuliari GP, Shields CL, *et al.* Retinal astrocytic hamartoma: Optical coherence tomography classification and correlation with tuberous sclerosis complex. *Retina* 2016;36:1199-208.
7. Shields JA, Eagle RC Jr, Shields CL, Marr BP. Aggressive retinal astrocytomas in four patients with tuberous sclerosis complex. *Trans Am Ophthalmol Soc* 2004;102:139-47.
8. Shields CL, Shields JA, Eagle RC Jr, Cangemi F. Progressive enlargement of acquired retinal astrocytoma in 2 cases. *Ophthalmology* 2004;111:363-8.
9. Iaccheri B, Fiore T, Cagini C, Giansanti F, Androudi S, Brazitikos PD. Retinal astrocytic hamartoma with associated macular edema: Report of spontaneous resolution of macular edema as a result of increasing hamartoma calcification. *Semin Ophthalmol* 2007;22:171-3.
10. Stallman JB. Visual improvement after pars plana vitrectomy and membrane peeling for vitreoretinal traction associated with combined hamartoma of the retina and retinal pigment epithelium. *Retina* 2002;22:101-4.