

ORIGINAL ARTICLE

Equine infectious keratitis in Finland: Associated microbial isolates and susceptibility profiles

Minna P. Mustikka  | Thomas S. C. Grönthal  | Elina M. Pietilä 

Department of Equine and Small Animal Medicine, University of Helsinki, Helsinki, Finland

Correspondence

Minna P. Mustikka, Department of Equine and Small Animal Medicine, University of Helsinki, P.O. Box 57, Helsinki, FI-00014 Finland.

Email: minna.mustikka@helsinki.fi

Abstract

Objective: To retrospectively describe laboratory findings, treatment, and outcome associated with equine infectious keratitis in Finland.

Animals and procedures: Medical records of horses diagnosed with infectious keratitis in University of Helsinki Equine Hospital from January 2007 to June 2018 were reviewed.

Results: Forty-seven cases were included. Keratomycosis was diagnosed in 27 eyes and bacterial keratitis in 20 eyes. *Aspergillus flavus* was the most frequent fungal isolate (9/17, 53%), followed by *Cylindrocarpon* sp. (3/17, 18%) and *Aspergillus fumigatus* (2/17, 12%). Susceptibility was tested for 10/11 *Aspergillus* sp. isolates; all were susceptible to voriconazole while only two were susceptible to amphotericin B. *Cylindrocarpon* sp. isolates were resistant to both agents. *Streptococcus equi* subsp. *zooepidemicus* was the most frequent bacterial isolate (9/19, 47%), followed by other streptococci (4/19, 21%). All 13 *Streptococcus* sp. isolates were susceptible to penicillin, and all tested isolates (n = 11) were also susceptible to chloramphenicol. Mean duration of medical treatment was longer in fungal keratitis (38 days) than in bacterial keratitis (25 days) ($P < .001$). Twenty-six of the eyes underwent globe-sparing surgery in addition to medical therapy. Recovery was achieved in 66% (31/47) of all cases and in 59% (16/27) and 75% (15/20) ($P = .264$) of cases with keratomycosis and bacterial keratitis, respectively.

Conclusions: Although *Aspergillus* sp. and *S. zooepidemicus* were the most frequently encountered isolates, cytology, culture, and susceptibility testing are essential to differentiate bacterial and fungal keratitis and guide the clinician to choose the most efficient treatment.

KEYWORDS

bacterial keratitis, cornea, equine, fungal keratitis, isolates, susceptibility

1 | INTRODUCTION

Horses are predisposed to corneal trauma due to their lateral globe position, exposed corneas, prey behavior, and, often,

their living environment.¹⁻³ Potentially pathogenic bacterial and fungal organisms, for example, *Streptococcus* spp., *Staphylococcus* spp., *Pseudomonas* spp., Enterobacteriaceae, *Aspergillus* spp., and *Penicillium* spp., are ubiquitous in the

This is an open access article under the terms of the Creative Commons Attribution-NonCommercial License, which permits use, distribution and reproduction in any medium, provided the original work is properly cited and is not used for commercial purposes.

© 2019 The Authors. *Veterinary Ophthalmology* published by Wiley Periodicals, Inc. on behalf of American College of Veterinary Ophthalmologists

The copyright line for this article was changed on August 18, 2019 after original online publication.

equine living environment in dust and vegetative material, and thus, horses are considered more susceptible to corneal infections than other species.^{1,2,4,5} Infectious corneal disease is a vision-threatening process with a potential risk of loss of the globe; it thus requires appropriate, aggressive intervention.^{1,2,6} Corneal infections can be classified as ulcerative or nonulcerative, the former being more common.¹⁻³ Most often, the corneal infection originates from contamination of a traumatic ulcer, or the access of microorganisms from the environment or the ocular microflora into the corneal stroma by traumatic micropuncture. However, epithelial nonulcerative keratomycosis associated with precorneal tear film instability occurs without predisposing corneal injury, and thus, a cornea infected with fungi may not in all cases initially stain with fluorescein.^{1,2,7,8} Equine ocular normal microflora consists of a mixture of opportunistic Gram-positive and Gram-negative bacteria as well as fungal organisms.^{1,9-14} Regional and geographical differences in the susceptibility patterns of both normal equine conjunctival microflora and organisms associated with disease exist.⁹⁻¹⁵ Topical antimicrobial and steroidal medications are considered a predisposing factor, particularly for corneal fungal infections, due to the altered microenvironment and suppressed immune response.^{1,2,6,12,16,17}

Equine fungal keratitis is a common condition, especially in warm and humid climate regions.^{1,2,8,16,18,19} However, several recent publications have raised awareness of its prevalence also in geographic areas of more temperate climates, including European countries, particularly during summer and autumn months with sufficient temperature and precipitation.^{6,15,19-24} Finland is mostly situated in the north temperate zone with a subarctic climate. Due to the latitude of the country, the southernmost parts have a cool summer and humid continental climate. The University of Helsinki Equine Hospital is the only referral hospital in Finland providing emergency service around-the-clock for equine patients, and thus, it receives patients from the entire country. To the authors' knowledge, only a single case report²⁵ has previously been published addressing equine corneal infections in the Nordic countries. The purpose of this study was to retrospectively describe diagnosis, associated pathogens, possible predisposing factors, treatment, and overall success rates of both bacterial and fungal keratitis in different climate conditions than those reported in previous publications internationally, thus raising awareness of the disease and contributing to the direction of future research.

2 | MATERIALS AND METHODS

Medical records of horses diagnosed with fungal or bacterial keratitis from January 2007 to June 2018 were extracted from the University of Helsinki Equine Hospital patient database (Provet Net, Finnish Net Solutions Oy). All cases included

in the study were reported to present with clinical signs and response to treatment compatible with infectious keratitis. Cases with fungal hyphae or bacteria detected in corneal cytology and/or histology samples or significant fungal or bacterial isolates yielded in culture or both were included and subsequently classified into fungal or bacterial keratitis. Seven cases with diagnosis of bacterial keratitis based on clinical findings and neutrophilia without indications of the causative pathogen in cytology and with negative or missing culture result were discarded from the material. Twenty-two cases diagnosed with corneal stromal abscess without a representative cytology, biopsy, or culture sample or with the absence of pathogens in the samples obtained were also discarded.

Each case was individually reviewed and the following information collected: age, sex, breed, eye affected, date of admission, topical medication prior to presentation, clinical diagnosis, findings in cytology and/or histopathology, results of bacterial and/or fungal culture and susceptibility testing, medications administered, surgical procedures performed, duration of treatment, and outcome. Recovery was defined as a spared visual, cosmetically acceptable, and comfortable globe at the time of the final control examination. The season of presentation was determined based on the month of initial presentation in the hospital. Seasons were classified as spring (March, April, May), summer (June, July, August), autumn (September, October, November), and winter (December, January, February).

Corneal samples were routinely collected under sedation and often using periocular nerve blocks. Specimens for bacterial or fungal culture were obtained by first administering one drop of oxybuprocaine or tetracaine onto the cornea of the affected eye and then brushing the affected area with a cotton-tipped transport swab (M40 Transystem, Copan Diagnostics Inc). Cytology specimens were obtained by brushing the affected corneal area with a sterile swab or cytobrush (Cytobrush Plus, Medscan AB), or gently scraping with the blunt tip of the scalpel blade. Collected material was then rolled or spread onto a glass slide.

Cytology samples were routinely stained with May-Grünwald Giemsa and/or occasionally with Diff-Quik or Gram's stain. Surgical specimens for histopathological examination were fixed in 10% formalin (containing ~4% formaldehyde), cut, and stained with hematoxylin and eosin (HE) and periodic acid-schiff (PAS).

Transport swabs for bacterial and fungal culture were referred to the Finnish Food Authority until summer 2010, after which bacterial specimens were referred to the Laboratory of Clinical Microbiology of the Faculty of Veterinary Medicine, University of Helsinki, and fungal swabs were referred to the Hospital District of Helsinki and Uusimaa Laboratory (HUSLAB). Aerobic bacterial culture was performed by plating the swab samples onto tryptic soy agar with 5% sheep

blood (TSA-SB, Oxoid Ltd.), chocolate agar (Oxoid Ltd.), and Dixon agar (Tammertutkan Maljat OY). Five percent CO₂ was added to the atmosphere of TSA-SB and chocolate agar, and they were incubated for up to four days at 35 ± 2°C. Dixon agar was incubated at 35 ± 2°C in regular atmosphere. Bacterial isolates were identified using biochemical methods²⁶ until January 2016, after which isolates were identified using matrix-assisted light desorption/ionization-time-of-flight (MALDI-TOF) mass spectrometry (microflex LT, Bruker GmbH). Susceptibility testing was performed according to the Clinical & Laboratory Standards Institute (CLSI) guidelines using systemic breakpoints, as specific breakpoints for topical antimicrobials are not available.²⁷ Antimicrobials to which the bacterial species was intrinsically resistant were not tested, with the exception of fusidic acid and streptococci. For the purpose of reporting, intermediate and resistant results were pooled as “nonsusceptible.” Antimicrobials investigated were chosen based on the bacterial species isolated and topical ocular preparation availability.

For fungal culture, specimens were cultured onto Sabouraud glucose plates (Lab M Ltd., Lancashire, UK) at 28 and 37°C for up to 4 weeks. Plates were checked for growth daily. Fungal growth was transferred to potato dextrose plates (Difco™, VWR International) for easier identification of spore structures and incubated in the same conditions. Antifungal susceptibility testing was performed using gradient diffusion strips (E-TEST®, bioMérieux SA) on Roswell Park Memorial Institute (RPMI, VWR International Oy and Sigma-Aldrich Finland Oy) agar at 37°C. For filamentous fungi, susceptibility was tested to amphotericin B, itraconazole, posaconazole, and voriconazole. For yeast-like fungi, susceptibility was tested to amphotericin B, voriconazole, caspofungin, and fluconazole. Minimal inhibitory concentrations (MICs) were interpreted using breakpoints provided by European Committee on Antimicrobial Susceptibility Testing (EUCAST).²⁸ When specific breakpoints were lacking, the MICs were interpreted based on the most conservative breakpoint available for the fungal group observed.

Descriptive statistics of the study variables were calculated by diagnosis of fungal or bacterial keratitis. To identify risk factors, the associations of the studied variables with fungal keratitis were investigated with univariable logistic regression models. The effect of the duration of symptoms prior to referral on the duration of medical treatment after diagnosis was investigated using linear regression analysis. Odds ratios (ORs) with 95% profile likelihood confidence intervals (CIs) were calculated to quantify the results. *P* values < .05 were considered significant. All statistical analyses were done using IBM SPSS Statistics v. 25 (IBM Corp.).

3 | RESULTS

During the observed time period of 11.5 years, a total of 47 cases of unilateral corneal infections were found to match the inclusion criteria. Twenty-two of the horses were mares, 19 were geldings, and 6 were stallions. The majority of horses were warmbloods (*n* = 29, 62%), followed by Standardbreds (*n* = 7, 15%). Other breeds represented were Finnhorses (*n* = 3), Cross-bred ponies (*n* = 3), and one each of Quarter horse, Icelandic horse, Welsh pony, Shetland pony, and American Miniature horse. The age of the horses varied from 3 months to 25 years, with an average age of 9 years and a median age of 8 years.

The right eye was affected in 24 cases and the left in 23 cases. Only six cases (13%) were first opinion cases, the rest were referrals. In 39 cases (83%), the owner and/or referring veterinarian reported recent topical antimicrobial medication (duration of more than one day) of the affected eye, most often chloramphenicol (*n* = 28, 60%). Previous topical steroid medication (with last dose given within a week) was reported in 12 cases (26%). Twenty-seven cases (57%) were diagnosed with fungal keratitis, of which 4 had a stromal abscess and 23 an ulcerative keratomycosis. In 18 of 27 cases of fungal keratitis, the patient was male (14 geldings and 4 stallions), and thus, male horses were significantly (*P* = .035,

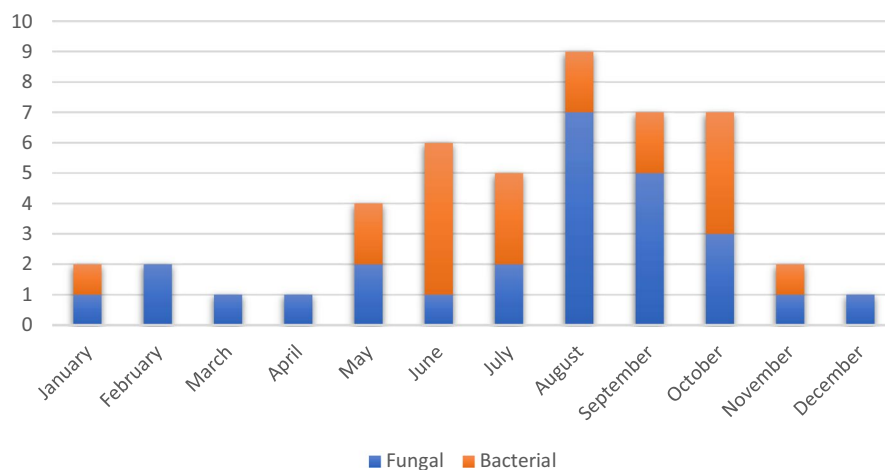


FIGURE 1 Seasonal distribution of equine cases diagnosed with fungal or bacterial keratitis in Finland from January 2007 to June 2018

OR 3.70, CI_{95%} 1.10-12.5) more likely to have fungal keratitis than mares. Bacterial keratitis was diagnosed in 20 eyes (43%); two were stromal abscesses and 18 ulcerative lesions. Seasonal distribution of cases is presented in Figure 1, and a strong tendency of infectious keratitis to present during summer (n = 20, 43%) and autumn (n = 16, 34%) months was found. However, the season (compared to winter) did not impact the diagnosis (bacterial vs. fungal) (spring $P = .624$, OR 2.00, CI_{95%} 0.13-31.98; summer $P = .250$, OR 4.00, CI_{95%} 0.38-42.37; autumn $P = .355$, OR 3.11, CI_{95%} 0.28-34.42). Distribution of cases over the study period is presented in Figure 2.

3.1 | Cytology, histopathology, isolated pathogens, and susceptibility patterns

Bacterial (n = 35) and/or fungal (n = 27) culture was performed in 39 cases (83%). Of these, 19 yielded positive bacterial culture and 16 positive fungal culture, with one being positive for both. In one case, based on the pathologist's report, a primary fungal and secondary bacterial infection was diagnosed by histopathology, but only the bacterial culture result was available. A pathogen was identified by culture in 72% (n = 34) of the cases. In 26 cases, a unanimous culture and cytology and/or histopathology result was available. Thirteen cases (28%) were diagnosed solely based on findings in cytology or histopathology. Observation of fungal hyphae in cytology was strongly correlated ($P = .004$ OR 45.5, CI_{95%} 3.48-594.68) with a positive result in fungal culture.

Bacterial isolates diagnosed are presented in Table 1. The most frequent isolate was *Streptococcus equi* subsp. *zooepidemicus* (9/19, 47%). Susceptibility results were available for 18/19 (95%) bacterial isolates (Table 2). Results were missing for a single case of *Corynebacterium* sp. isolate. All tested bacterial isolates were susceptible to penicillin G (n = 16), chloramphenicol (n = 12), gentamycin (n = 7), and trimethoprim sulfadiazine (n = 15). All of the tested *S zooepidemicus*

(n = 6) and *Streptococcus* sp. isolates (n = 4) were resistant to fusidic acid, as expected. Susceptibility to tetracycline was variable, as 4/7 *S zooepidemicus* and 2/2 *Streptococcus* sp. isolates were susceptible.

Of the 17 fungal isolates, the most frequently found organism was *Aspergillus flavus* (53%) (Table 3). In one case, both *A flavus* and *Cryptococcus laurentii* were isolated. Among the 12 cases where topical steroid medication had been administered prior to presentation, seven horses were diagnosed with fungal keratitis and five with bacterial keratitis. *A flavus* was isolated from three patients with fungal keratitis and previous steroid treatment. The other two yielded *Lichtheimia corymbifera* or *Paecilomyces* sp. In two of the cases, fungal culture was not available. Previous steroid medication was not found to have a significant influence on the type of causative pathogen (bacterial vs fungal, $P = .883$, OR 0.91, CI_{95%} 0.24-3.43) or the outcome ($P = .902$, OR 1.09, CI_{95%} 0.27-4.39). Eyes previously treated with chloramphenicol (n = 28) were less likely to be diagnosed with bacterial keratitis ($P = .003$, OR 0.13, CI_{95%} 0.03-0.49). However, a similar effect was not seen for topical antimicrobials as a whole ($P = .057$, OR 0.19, CI_{95%} 0.03-1.05). Topical antimicrobial treatment prior to referral did not influence the outcome ($P = .821$, OR 1.20, CI_{95%} 0.253-5.82). Nor did previous steroid ($P = .747$, OR 1.24, CI_{95%} 0.33-4.71) or

TABLE 1 Bacterial organisms isolated from equine cases of bacterial keratitis in Finland from January 2007 to June 2018

Organism	No. of isolates
<i>Streptococcus equi</i> subsp. <i>zooepidemicus</i>	9
<i>Streptococcus</i> sp.	4
<i>Corynebacterium</i> sp.	2
Coagulase-negative staphylococci	1
<i>Moraxella</i> sp.	1
<i>Serratia marcescens</i>	1
<i>Staphylococcus aureus</i>	1

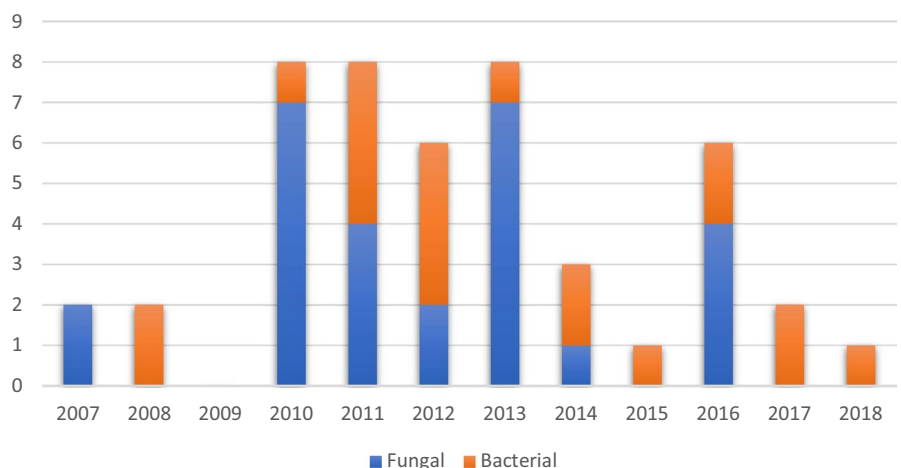


FIGURE 2 Annual distribution of equine cases diagnosed with fungal or bacterial keratitis in Finland from January 2007 to June 2018

TABLE 2 Antimicrobial susceptibility results of *Streptococcus equi* subsp. *zooepidemicus* isolates diagnosed in cases of equine bacterial keratitis in Finland from January 2007 to June 2018

N	PCG	TMPS	ERY	CLI	TC	CHL	CIP	FUS	GEN	MOX
Resistant	0	0	0	2	3	0	3	6	0	0
Susceptible	9	8	3	1	4	8	2	0	2	1
Total	9	8	3	3	7	8	5	6	2	1
% Susceptible	100.0	100.0	100.0	33.3	57.1	100.0	40.0	0.0	100.0	100.0

Abbreviations: CHL, chloramphenicol; CIP, ciprofloxacin; CLI, clindamycin; ERY, erythromycin; FUS, fusidic acid; GEN, gentamicin; MOX, moxifloxacin; PCG, penicillin G; TC, tetracycline; TMPS, trimethoprim sulfadiazine.

TABLE 3 Fungal organisms isolated from cases of equine fungal keratitis in Finland from January 2007 to June 2018

Organism	No. of isolates
<i>Aspergillus flavus</i>	9
<i>Aspergillus fumigatus</i>	2
<i>Cylindrocarpon lichenicola</i> (<i>Fusarium lichenicola</i>)	2
<i>Cylindrocarpon</i> sp.	1
<i>Cryptococcus laurentii</i>	1
<i>Lichtheimia corymbifera</i>	1
<i>Paecilomyces</i> sp.	1

antimicrobial treatment ($P = .075$, OR 4.80, $CI_{95\%}$ 0.86-27.95) increase the odds for globe-sparing surgery.

Susceptibility was tested for 88% (15/17) of isolates: 14 filamentous fungal isolates and a single isolate of yeast-like fungi *Cryptococcus laurentii*. The susceptibility of *Aspergillus flavus* and *Cylindrocarpon* sp. is shown in Table 4. Susceptibility results were not available for single isolates of *Lichtheimia corymbifera* and *A fumigatus*. All tested *A flavus* isolates and the one *A fumigatus* isolate (MIC 0.19 mg/L) were susceptible to voriconazole. Only one of the nine *A flavus* isolates and the single isolate of *A fumigatus* (MIC 1 mg/L) were sensitive to amphotericin B. Six of the nine *A flavus* isolates and the one *A fumigatus* isolate (MIC 0.75 mg/L) showed sensitivity to itraconazole. None of the *A flavus* isolates showed sensitivity to posaconazole, but the one *A fumigatus* (MIC 0.125 mg/L) did.

Neither EUCAST nor CLSI has yet provided clinical breakpoints for interpreting MICs for *Fusarium* sp. or *Paecilomyces* sp. When interpreted based on MIC breakpoints given for *A fumigatus* (Table 5), the single *Paecilomyces* sp. isolate (MIC in mg/L: amphotericin B 24; itraconazole 2; posaconazole 0.5; voriconazole 32) was resistant to all tested antifungal agents. All three *Cylindrocarpon* sp. isolates were resistant to all tested antifungal agents, when interpreted using MIC breakpoints for *A fumigatus* (Table 5) and sequence-based in vitro MIC profile for *C lichenicola*/*F lichenicola*.²⁹ The *Cryptococcus laurentii* isolate showed sensitivity

only to amphotericin B (MIC in mg/L: amphotericin B 0.047; voriconazole 0.125; caspofungin > 32; fluconazole 6).

3.2 | Treatment and outcome

The mean duration and median duration of symptoms prior to referral were 10 and 7 days, respectively. In cases with fungal keratitis, the duration was significantly ($P = .018$, OR 8.85, $CI_{95\%}$ 0.80-0.98) longer, mean 13 days, than in cases of bacterial keratitis, mean 6.5 days. Two of the 47 cases of infectious keratitis underwent enucleation on the day of presentation, and thus, 45 patients received medical treatment for the ophthalmic condition. Systemic nonsteroidal anti-inflammatory drugs, most frequently flunixin meglumine, were standardly used. Omeprazole and/or sucralfate was administered when required based on the clinician's judgment. All cases going through globe-sparing surgery received intravenous penicillin G 22 000 IU/kg and gentamicin 6.6 mg/kg. Other topical, oral, and subconjunctival medications used, their dosages, and the frequency of administration are listed in Table 6. In the majority of cases, topical ocular medication was administered via the subpalpebral lavage system.

Recovery was achieved in 66% (31/47) of cases with an average duration of topical medication of 32 days. The period of topical medication was significantly ($P = .007$, OR 1.15, $CI_{95\%}$ 1.04-1.27) longer (mean 38 and median 39.5 days) for fungal keratitis than for bacterial keratitis (mean and median 25 days). Twenty-six of the 47 eyes (55%) underwent surgery to save the globe, two of them twice. Ten (38%) of these suffered from bacterial keratitis and 16 (62%) from fungal keratitis. The odds for having globe-sparing surgery did not differ significantly between the groups of bacterial and fungal keratitis ($P = .529$, OR 1.46, $CI_{95\%}$ 0.45-4.66). Keratectomy and conjunctival graft was performed in 23 surgeries (22 cases) and keratectomy only in five surgeries (five cases). Twenty-three of 26 eyes (88%) treated surgically recovered. The period of medical treatment was significantly longer ($P = .012$, OR 1.28, $CI_{95\%}$ 1.06-1.56) in cases having globe-sparing surgery (mean 36 days) than in cases treated medically (mean 20 days). The duration of symptoms prior to referral did not have a significant impact on the outcome

TABLE 4 Minimal inhibitory concentrations in mg/L for *Aspergillus flavus* and *Cylindrocarpon* sp. isolates in cases of equine fungal keratitis in Finland from January 2007 to June 2018

	Amphotericin B	Itraconazole	Posaconazole	Voriconazole
<i>Aspergillus flavus</i>				
1	1	1	0.25	0.38
2	16	1.5	0.25	0.19
3	2	0.75	0.38	0.19
4	3	1	0.25	0.5
5	1.5	1.5	0.38	0.19
6	2	0.38	0.19	0.19
7	4	1.5	0.25	0.19
8	12	1	0.19	0.125
9	3	1	0.25	0.19
<i>Cylindrocarpon</i> sp.				
1	8	>32	>32	4
2	2	32	32	3
3	24	>32	>32	8

TABLE 5 Breakpoints in mg/L for interpretation of minimal inhibitory concentrations of *Aspergillus fumigatus* according to the European Committee on Antimicrobial Susceptibility Testing (EUCAST) Antifungal Clinical Breakpoint Table v. 9.0²⁸

	Sensitive	Resistant
Amphotericin B	≤1	≥2
Itraconazole	≤1	>2
Posaconazole	≤0.125	>0.25
Voriconazole	≤1	>2

($P = .755$, OR 0.99, CI_{95%} 0.93-1.06) or the duration of topical medication ($F(1, 29) = 2.258$, $P = .144$, $R^2 = 0.072$). The season (compared to winter) did not impact the outcome (spring $P = .819$, OR 1.33, CI_{95%} 0.11-15.70; summer $P = .835$, OR 1.23, CI_{95%} 0.17-9.25; autumn $P = .718$, OR 1.47, CI_{95%} 0.18-11.72).

Fifteen of 20 eyes (75%) with bacterial keratitis recovered. One horse was euthanized at the owner's request, and four horses were enucleated for prognostic and/or financial reasons. Ten eyes with bacterial keratitis were treated surgically and nine of these (90%) recovered. Surgical treatment did not statistically influence the outcome in bacterial keratitis ($P = .147$, OR 6.00, CI_{95%} 0.53-67.65). Sixteen of 27 eyes (59%) with fungal keratitis recovered. One horse died during recovery from general anesthesia performed for globe-sparing surgery, one horse was euthanized at the owner's request, and nine horses were enucleated for prognostic and/or financial reasons. Sixteen eyes with fungal keratitis were treated surgically and 14 of these (88%) recovered. Surgical treatment significantly ($P = .002$, OR 31.50, CI_{95%} 3.74-265.43) increased the odds for recovery in fungal keratitis cases (88% vs 18%). The diagnosis (fungal vs bacterial) did not have a

significant impact on the outcome ($P = .264$, OR 2.06, CI_{95%} 0.58-7.35).

4 | DISCUSSION

Recent findings regarding the incidence, causative microorganisms, and susceptibility patterns of equine infectious keratitis have raised new questions and increased the need for knowledge from different geographical locations to facilitate targeted, efficient treatment, while concurrently avoiding misuse of antimicrobials. To the authors' knowledge, this is the first comprehensive report discussing equine infectious keratitis in Northern Europe.

A mixed infection of bacteria and fungi was diagnosed in only 4% of cases ($n = 2$), far less frequently than the 15%-50% that has been previously published.^{6,16,24,30,31} This may be attributable to the high rate of previous antimicrobial medication or even to the antimicrobial metabolites produced by certain fungal species, as discussed by Sherman et al.³¹ The breed distribution in our study was roughly consistent with the patient population at the University of Helsinki Equine Hospital during the observation period (data not shown). The median age of 8 years was quite similar to earlier reports.^{16,20,32} Male horses were diagnosed with fungal keratitis significantly more often than mares, in contrast to other studies.^{6,13,16,30} The reason for this finding could not be identified.

Most of the patients had been referred and had received treatment with topical antimicrobials. Bacterial keratitis was diagnosed in less than half of the cases. *S. zooepidemicus* was the most frequent bacterial isolate, and this was in agreement with previous results from Tennessee (USA) and Switzerland.^{34,35} In contrast, *Pseudomonas* sp. has been the

TABLE 6 Medical therapy of 45 cases with infectious keratitis diagnosed in Finland from January 2007 to June 2018

Medication	Route	Dose	No. of cases	% of cases
Antimicrobial				
Trimethoprim sulfadiazine	Oral	30 mg/kg BID	17	38
Doxycycline	Oral	10 mg/kg BID	1	2
Chloramphenicol 5 mg/mL	Topical	Q 2-6 h	40	89
Ofloxacin 3 mg/mL	Topical	Q 2-6 h	27	60
Tobramycin 3 mg/mL	Topical	Q 12 h	3	7
Neomycin-Polymyxin B-Gramicidin	Topical	Q 2-6 h	2	4
Fusidic acid 10 mg/mL	Topical	Q 12 h	2	4
Moxifloxacin 5 mg/mL	Topical	Q 2-6 h	1	2
Tetracycline 10 mg/mL	Topical	Q 8 h	1	2
Cefazolin	Subconjunctival	100 mg	1	2
Antifungal				
Fluconazole	Oral	14 mg/kg loading dose followed by 5 mg/kg SID	7	16
Voriconazole 10 mg/mL	Topical	Q 2-6 h	33	73
Fluconazole 2 mg/mL	Topical	Q 2-6 h	13	29
Amphotericin B 2.5-5 mg/mL	Topical	Q 4-6 h	5	11
Miconazole 2%	Topical	Q 8 h	1	2
Amphotericin B	Subconjunctival	1 mg	3	7
Proteinase inhibition				
Serum	Topical	Q 2-6 h	26	58
EDTA 2%	Topical	Q 2-6 h	4	9
Mydriatics				
Atropine 1%	Topical	Q 6-24 h	45	100
Phenylephrine 10%	Topical	Q 8 h	1	2

Abbreviations: BID, twice a day; SID, once a day.

most common isolate in studies from Pennsylvania (USA), Florida (USA), and Japan.^{15,36,37} Other studies have reported *Pseudomonas* sp. to account for 5%-12% of isolates.^{30,34,35} Although *Pseudomonas* sp. is considered a very virulent corneal pathogen,² it has been repeatedly described as an occasional finding in conjunctival samples from healthy horses.^{9,12,14,17} Interestingly, *Pseudomonas* sp. was not isolated in the current data, although chloramphenicol was commonly used prior to referral and, in theory, has the potential to alter the microbial population balance in favor of *Pseudomonas* sp.^{1,2,17} All tested isolates were susceptible to penicillin G and chloramphenicol. The result indicates good national status regarding antimicrobial resistance. It was in line with results from Switzerland,³⁵ Japan,¹⁵ and Florida (USA),³⁶ but contrary to those from Missouri (USA), where 67% of Gram-positive bacteria were susceptible to penicillin and 48% to chloramphenicol, respectively.³⁰ All tested isolates were also susceptible to trimethoprim sulfadiazine. Tested *Streptococcus* sp. isolates were moderately susceptible to tetracycline, comparable with results from

Switzerland³⁵ and Japan.¹⁵ At the University of Helsinki Equine Hospital, the first-choice topical antimicrobial for uncomplicated corneal ulcers has been chloramphenicol since an ophthalmic solution containing neomycin, polymyxin B, and gramicidin became unavailable in 2012. With the current results, this protocol seems reasonable. Based on the resistance of streptococci to fusidic acid, it is not recommended as an empirical first-line topical antimicrobial.

Geographical differences and climate conditions have been demonstrated to have an effect not only on the normal microbial flora of the equine conjunctival surface, but also on the occurrence of different fungal and bacterial pathogens causing infectious keratitis.⁹⁻¹⁵ In the current data, 77% of all cases presented during summer and autumn months. Many reports from the Northern Hemisphere have provided similar results regarding seasonal effects on the incidence of keratomycosis,^{6,20,21,31,33} albeit reports from subtropical Florida have repeatedly presented contradictory results.^{8,9,19} It has been contemplated whether the finding is related to decreasing temperature and changes in humidity providing

favorable circumstances for fungi^{16,31} or only secondary to changes in management such as increasing periods of time that the horses are kept stabled.^{1,2,38} The increasing effect of housing on the number of fungi isolated from conjunctiva of healthy horses has previously been noted in some studies, whereas others have observed few differences between the fungal species isolated.^{10,14,20} On the other hand, the majority of tested donkeys living outdoors in rural areas were found to harbor fungi in one study.¹¹ Overall in Finland, horses are usually kept outdoors most of the daytime throughout the year. Due to the subarctic climate conditions, it is compulsory by law to provide a stable or a walk-in/walkout shelter. Also, for example, peat moss is often used as a bedding material, offering a suitable microenvironment for proliferation of filamentous fungi. Research is needed on the influence of different bedding materials and types of soil in the pastures on the fungal species isolated from both healthy and diseased equine eyes.

Corneal cytology was found to predict the positive fungal culture well in cases of fungal keratitis, supporting previous results.^{18,39,40} Although corneal confocal microscopy has been described as a useful noninvasive diagnostic method in equine keratomycosis,⁴¹ to date it is readily available in very few locations. Moreover, it may take several days to isolate filamentous fungi in culture, rendering prompt diagnosis with cytology essential for recognizing the immediate need for antifungal therapy.⁴² However, culture is regarded as the golden standard in diagnosis of keratomycosis,⁴⁰ and susceptibility testing is critical for modifying the optimal treatment due to geographic variation in prevalence and susceptibility patterns of isolates.^{6,16,20,30,33,42-45}

In the current study, *Aspergillus* sp. was the predominant fungal species isolated (65%). A similar observation has been made in earlier studies of both fungal keratitis and conjunctival fungal flora in healthy equids worldwide.^{6,11,16,18,20,24,32,33,37,43} In global reports, *Fusarium* sp. has been the second most common fungal species isolated, accounting for 4%-14% of isolates.^{6,24,30,32,33,43} Florida is a striking exception to this, with *Fusarium* sp. described in 26%-32% of the cases,^{16,46} and this geographical difference can be speculated to be linked to the warm and humid climate conditions, similar to the occurrence of *Fusarium*-associated keratitis in human patients.^{16,19,29,46} To the authors' knowledge, *Fusarium* sp.-associated equine fungal keratitis has been reported only in a single case in Europe.²⁴ Owing to recent information gathered from DNA sequencing, *Cylindrocarpon lichenicola* has been identified as a part of the "*Fusarium solani* species complex," in contrast to other *Cylindrocarpon* species, and consequently has been renamed as *Fusarium lichenicola*.⁴⁷ In our data, two isolates of *Cylindrocarpon lichenicola*/*Fusarium lichenicola* and a single isolate of *Cylindrocarpon* sp. were reported. After the study period, *Fusarium* sp. was isolated from four additional

cases of fungal keratitis at the University of Helsinki Equine Hospital. The global change in climate conditions could be speculated to underlie the increasing incidence of keratomycosis caused by *Fusarium* sp., as the average temperature from May to August 2018 was the highest ever in Finnish measurement history.⁴⁸ However, this subject requires extensive further investigation.

All tested *Aspergillus* sp. isolates were susceptible to voriconazole, in agreement with several previous results.^{6,20,44,45} Nevertheless, in a study from Mid-Atlantic, USA, the authors found only 4/10 *Aspergillus* sp. isolates to be sensitive to voriconazole.⁴⁹ Variable results for the susceptibility of *Aspergillus* sp. to itraconazole have been presented, ranging from 25% to 100%, compared with 80% in our study.^{6,43,46,49} Only 20% (n = 2) of *Aspergillus* isolates were susceptible to amphotericin B, while Ledbetter et al⁴³ found 86% to be susceptible. All three *Cylindrocarpon* sp. isolates were resistant to all tested agents, in contrast to Ledbetter et al reporting 43% of *Fusarium* sp. isolates to be sensitive to amphotericin B and Pearce et al finding voriconazole to be the second most effective antifungal agent for *Fusarium* sp.^{43,44} Itraconazole has previously been found to have poor efficacy for *Fusarium* sp.,^{43,46} in agreement with our results. Poor overall efficacy of antifungal agents can be explained by intrinsic resistance associated with azoles in many *Fusarium* species and a high level of cross-resistance, and, on the other hand, with recently identified paths to secondary resistance.²⁹ Treatment of *Fusarium*-associated keratitis is considered a challenge also in human medicine, where topical natamycin, amphotericin B, and voriconazole, and preferably combinations of these, are currently considered the first-line treatment.²⁹ Nevertheless, frequent topical ocular administration of a drug with good corneal penetration is likely to result in concentrations higher than the studied effective serum concentrations, thus achieving some clinical response also in cases with pathogens expressing in vitro resistance.⁴² In the current data, all of the cases with *Cylindrocarpon* sp. were clinically challenging and underwent globe-sparing surgery. Two of the eyes recovered, but one of the horses did not survive the recovery after general anesthesia for corneal surgery.

Unlike natamycin, voriconazole solution suitable for ophthalmic use is readily available in Finland. Based on the adequate effect on *Aspergillus* sp. in addition to evidence of good corneal penetration and therapeutic concentrations in aqueous humor with topical administration,⁵⁰ voriconazole can be considered a primary choice for initial antifungal medication in this geographic area. Before voriconazole became readily available in 2007-2008, topical fluconazole or in some cases miconazole was used. Injectable amphotericin B solution is available in Finland and used in combination with voriconazole in selected cases, but itraconazole and posaconazole are currently available only as peroral formulations. In

contrast to oral fluconazole, itraconazole has not been proven to result in detectable concentrations in equine aqueous humor,^{51,52} and thus, fluconazole has been chosen as an additional therapy in challenging cases of keratomycosis, despite reports of poor efficacy on *Aspergillus* sp.^{43,44,46}

Inconsistent results in susceptibility testing among studies from different decades and geographical locations emphasize the importance of testing in clinical cases. However, interpreting MICs and comparing susceptibility results between different publications in the area of equine keratomycosis is challenging, as comprehensive information regarding clinically established MIC breakpoints for filamentous fungi is mostly unavailable. Available information, provided by CLSI and EUCAST, is based on the use of broth dilution susceptibility testing methods and systemic use of antifungal agents in human patients. Over 90% essential agreement has been found between the broth microdilution technique and ETEST[®] regarding susceptibility testing among various species of filamentous fungi, including *Aspergillus* sp., *Fusarium* sp., and *Paecilomyces* sp., with the exception of testing posaconazole among *Aspergillus* sp. (64%-89% essential agreement).⁵³ Using a less time-consuming and technically challenging commercial agar diffusion test is thus acceptable, but interpretation of MICs must be done with caution, as the specific clinical breakpoints are lacking and epidemiological cut-off values based on wild-type distribution are specific for the method used.

Median duration of topical medical treatment was 25 days in bacterial keratitis and 39.5 days in fungal keratitis. In previous reports, duration of treatment has been reported to be 29-45 days in bacterial^{54,55} and 37-73 days in fungal keratitis.^{6,16,24,33} In contrast to the results of Utter et al,³⁷ the period of medical treatment was significantly longer in cases demanding globe-sparing surgery than in cases treated only medically. These differences are likely related to the severity of the disease in selected cases. In our study, a visual, cosmetically acceptable, comfortable globe was retained in 66% of all cases treated, in 75% of cases with bacterial keratitis, and in 59% of cases with fungal keratitis, but no significant difference regarding the diagnosis was found. The rate for favorable results was similar or somewhat lower than in previous reports, as Utter et al³⁷ reported 85% and Andrew et al¹⁶ 95% overall success rate for intact globe in infectious keratitis, while rates for preserving a visual globe in bacterial keratitis have been reported to be 73%-76%.^{54,55} For fungal keratitis, reported rates for similar success have been quite variable, from 50% by Galan et al²⁴ up to 97% by Utter et al³² Undoubtedly, the severity of cases has a major effect on the success rates, and plausibly, the lack of awareness of the referring veterinarian may postpone the referral, especially in countries with little or no previously published data concerning infectious keratitis, particularly fungal keratitis. Furthermore, the long geographic distances in Finland with only a single referral center with a full-time emergency

service probably delays the referrals. In these data, the cases with fungal keratitis were referred significantly later in the course of the disease compared to the ones with bacterial keratitis. Nevertheless, the duration of symptoms prior to referral did not have a significant impact on the period of topical medication, or the outcome. In some cases, the owner chose enucleation or euthanasia for the horse for financial or personal reasons more so than for prognostic reasons.

Earlier treatment with topical or subconjunctival steroids has been suggested in numerous studies to predispose to fungal infections and to enhance fungal replication.^{6,16,21,24,31,44} In these data, 26% of the horses had received previous steroid medication, but the odds for them to have fungal rather than bacterial keratitis were not significantly higher. Although, overall, previous topical antimicrobial use was not associated with fungal keratitis, a history of topical chloramphenicol treatment was found to significantly increase the odds for fungal keratitis. Similar findings regarding earlier antimicrobial treatment have been reported elsewhere, and the phenomenon has been thought to be related to the altered microbial population balance by lowering the relative number of nonpathogenic microbes, thus also reducing the effect of antimicrobial enzymes secreted by selected nonpathogenic species.^{1,16,17,46} The suppressing effect of chloramphenicol on natamycin-producing *Streptomyces natalensis* in the equine conjunctival microenvironment is a potential factor.^{38,56} Nevertheless, concurrent antimicrobial use in fungal keratitis is deemed necessary, as co-infections of fungi and bacteria occur and are considered difficult due to their severity.^{16,40} Neither previous steroid nor antimicrobial medication had an effect on the odds for surgical treatment or the outcome. This result is in agreement with previous findings,^{6,20,24,31,57} but even combined numbers of cases from different studies are too low for comprehensive and fully reliable evaluation of the issue. Sherman et al³¹ reported *Aspergillus* sp. in 6/6 horses with a history of steroid treatment and diagnosis of fungal keratitis. In our data, *Aspergillus flavus* was isolated in three such cases, in contrast to two other isolates and two cases without culture result. As *Aspergillus flavus* was the most frequent fungal isolate detected and the total number of comparable cases was low, conclusions regarding the relation of steroids and the fungal species isolated cannot be drawn. In addition to limitations arising from the retrospective study design, the low number of cases and cultured isolates also limits the possibilities for other statistical analyses and does not allow investigation of the association between the cultured organism and the outcome. In other studies conducted to date, the species of the fungal isolate has not been found to have an impact on disease severity or outcome.^{31,32,45} Also, it is worth noting that the standard culture techniques used in this study may not have revealed all possible pathogens, either due to previous medication administered or due to unfulfilled growth requirements.

Fungal organisms are considered to be the most common cause of stromal abscesses, but are rarely cultured or even detected in histopathology of such cases.^{2,18,19,58,59} In this study, cases of infectious keratitis were included only when the causative microorganism could be identified in the samples. Thus, only six cases diagnosed with stromal abscess were included, and a high number of cases ($n = 22$) were excluded. For the same reason, numerous cases with clinical presentation and response to therapy suggestive of bacterial keratitis were excluded. The inclusion criteria create some bias in the study material considering the relationship of the incidence between bacterial and fungal keratitis in Finland. In most excluded cases of suspected bacterial keratitis with neutrophilia detected in cytology, bacterial culture was performed with a negative result. Often the cases with bacterial keratitis showed improvement with topical broad spectrum antimicrobial medication initiated upon referral, and due to financial matters, topical antifungals were initiated only with an apparent suspicion or proof of fungal keratitis. This leads to repeated sampling occurring more often in cases with fungal keratitis with slow clinical response or more severe clinical presentation, and hence higher likelihood of identifying the causative agent.

A great annual variation could be seen in the distribution of the number of included cases. The reason for this is not known, but, for example, the impact of weather conditions should be further investigated. As abovementioned, the summer of 2018 was exceptionally warm in Finland, and a record number of 14 cases of fungal keratitis and only two cases of bacterial keratitis were seen in the last half of 2018 (data not shown). The national incidence of infectious keratitis cannot be reliably estimated, as only a portion of cases are referred to the University of Helsinki Equine Hospital.

Our findings provide new information about commonly cultured species and susceptibility patterns of microorganisms associated with equine corneal infections in Northern Europe, assisting clinicians to choose the empirically most efficient treatment available while the culture and susceptibility test results are pending. As the incidence of equine keratomycosis seems to be on the rise, further studies are warranted to gain a better understanding of the geographical differences in the causative pathogens.

ACKNOWLEDGMENTS

The authors thank Simo Miettinen for providing detailed information regarding methods used in fungal isolation and susceptibility testing performed in HUSLAB.

ORCID

Minna P. Mustikka  <https://orcid.org/0000-0002-7180-1660>
 Thomas S. C. Grönthal  <https://orcid.org/0000-0001-8339-5818>
 Elina M. Pietilä  <https://orcid.org/0000-0002-6281-163X>

REFERENCES

- Brooks DE, Matthews A, Clode AB. Diseases of the cornea. In: Gilger BC, ed. *Equine Ophthalmology* 3rd edn. Ames, Iowa: John Wiley & Sons Inc; 2017;252-368.
- Gilger BC. Equine ophthalmology. In: Gelatt KN, Gilger BC, Kern TJ, eds. *Veterinary Ophthalmology*. 5th edn. Ames, Iowa, John Wiley & Sons Inc; 2013;1561-1609.
- Plummer CE. Corneal response to injury and infection in the horse. *Vet Clin North Am Equine Pract*. 2017;33:439-463.
- Lassaline M. Equine Ophthalmology. In: Maggs DJ, Miller PE, Ofri R, eds. *Slatter's Fundamentals of Veterinary Ophthalmology*. 6th edn. St. Louis, Missouri: Elsevier, Inc; 2018;442-470.
- Brooks DE. Equine keratomycosis: An international problem. *Equine Vet Educ*. 2009;21:243-246.
- Reed Z, Thomasy SM, Good KL, et al. Equine keratomycosis in California from 1987 to 2010 (47 cases). *Equine Vet J*. 2013;45:361-366.
- Brooks DE, Andrew SE, Denis HM, et al. Rose Bengal positive epithelial microerosions as a manifestation of equine keratomycosis. *Vet Ophthalmol*. 2000;3:83-86.
- Proietto LR, Plummer CE, Maxwell KM, Lamb KE, Brooks DE. A Retrospective analysis of environmental risk factors for the diagnosis of deep stromal abscess in 390 horses in North Central Florida from 1991 to 2013. *Vet Ophthalmol*. 2016;19:291-296.
- Andrew SE, Nguyen AN, Jones GL, Brooks DE. Seasonal effects on the aerobic bacterial and fungal conjunctival flora of normal thoroughbred brood mares in Florida. *Vet Ophthalmol*. 2003;6:45-50.
- Rosa M, Cardozo LM, da Silva Pereira J, et al. Fungal flora of normal eyes of healthy horses from the state of Rio de Janeiro, Brazil. *Vet Ophthalmol*. 2003;6:51-55.
- Nardoni S, Sgorbini M, Barsotti G, Corazza M, Mancianti F. Conjunctival fungal flora in healthy donkeys. *Vet Ophthalmol*. 2007;10:207-210.
- Johns IC, Baxter K, Booter H, Hicks C, Menzies-Gow N. Conjunctival bacterial and fungal flora in healthy horses in the UK. *Vet Ophthalmol*. 2011;14:195-199.
- Voelter-Ratson K, Monod M, Unger L, Spiess BM, Pot SA. Evaluation of the conjunctival fungal flora and its susceptibility to antifungal agents in healthy horses in Switzerland. *Vet Ophthalmol*. 2014;17:31-36.
- Hampson ECGM, Gibson JS, Barot M, Shapter FM, Greer RM. Identification of bacteria and fungi sampled from the conjunctival surface of normal horses in South-East Queensland, Australia. *Vet Ophthalmol*. 2018;22(3):265-275.
- Wada S, Hobo S, Hidekazu N. Ulcerative keratitis in thoroughbred racehorses in Japan from 1997 to 2008. *Vet Ophthalmol*. 2010;13:99-105.
- Andrew SE, Brooks DE, Smith PJ, Gelatt KN, Chmielewski NT, Whittaker CJG. Equine ulcerative Keratomycosis: Visual outcome and ocular survival in 39 cases (1987–1996). *Equine Vet J*. 1998;30:109-116.
- Gemensky-Metzler AJ, Wilkie DA, Kowalski JJ, Schmall LM, Willis AM, Yamagata M. Changes in bacterial and fungal ocular flora of clinically normal horses following experimental application of topical antimicrobial or antimicrobial-corticosteroid ophthalmic preparations. *Am J Vet Res*. 2005;66:800-811.
- Hamilton HL, McLaughlin SA, Whitley EM, Gilger BC, Whitley RD. Histological findings in corneal stromal abscesses of 11

- horses: correlation with cultures and cytology. *Equine Vet J.* 1994;26:448-453.
19. Henriksen M, Andersen PH, Thomsen PD, et al. Equine deep stromal abscess (51 cases – 2004–2009) – Part 1: the clinical aspects with attention to the duration of the corneal disease, treatment history, clinical appearance and microbiology results. *Vet Ophthalmol.* 2014;17:6-13.
 20. Voelter-Ratson K, Pot SA, Florin M, Spiess BM. Equine Keratomycosis in Switzerland: A retrospective evaluation of 35 horses (January 2000-August 2011). *Equine Vet J.* 2013;45:608-612.
 21. Grahn B, Wolfer J, Keller C, et al. Equine keratomycosis: Clinical and laboratory findings in 23 cases. *Prog Vet Comp Ophthalmol.* 1993;3:3-7.
 22. Moore PA, Dietrich UM, Barton MH, et al. The influence of rainfall and temperature on the frequency of equine fungal keratitis. *Assoc Res Vis Ophthalmol Abstracts.* 2005;46:5067.
 23. Sansom J, Featherstone H, Barnett KC. Keratomycosis in six horses in the United Kingdom. *Vet Rec.* 2005;156:13-17.
 24. Galán A, Martín-Suárez EM, Gallardo JM, Molleda JM. Clinical findings and progression of 10 cases of equine ulcerative keratomycosis (2004–2007). *Equine Vet Educ.* 2009;21:236-242.
 25. Aho R, Tala M, Kivalo M. Mycotic keratitis in a horse caused by *Aspergillus fumigatus*. The first reported case in Finland. *Acta Vet Scand.* 1991;32:373-376.
 26. Versalovic M, Carroll KC, Funke G. et al, editors. *Manual of Clinical Microbiology*, 10th edn. Washington: ASM Press, 2011; 2630.
 27. CLSI. *Performance standards for antimicrobial disk and dilution susceptibility tests for bacteria isolated from animals: Approved standard VET01-A4*. 4th edn. Wayne, PA, USA: Clinical and Laboratory Standards Institute; 2013.
 28. European Committee on Antimicrobial Susceptibility Testing. *Antifungal agents: Breakpoint tables for interpretation of MICs*. Version 9.0, valid from 2018-02-12. Switzerland: EUCAST; 2018. www.eucast.org/fileadmin/src/media/PDFs/EUCAST_files/AFST/Clinical_breakpoints/Antifungal_breakpoints_v_9_0_180212.pdf
 29. Al-Hatmi A, Meis JF, de Hoog GS. *Fusarium*: molecular diversity and intrinsic drug resistance. *PLoS Pathog.* 2016;12:e1005464.
 30. Moore CP, Collins BK, Fales WH. Antibacterial susceptibility patterns for microbial isolates associated with infectious keratitis in horses: 63 cases (1986–1994). *J Am Vet Med Assoc.* 1995;207:928-933.
 31. Sherman AB, Clode AB, Gilger BC. Impact of fungal species cultured on outcome in horses with fungal keratitis. *Vet Ophthalmol.* 2017;20:140-146.
 32. Utter ME, Wotman KL, Armour M, Bagel J. Clinical findings and outcomes of ulcerative keratomycosis in 30 horses in the mid-Atlantic United States (2006–2007). *Equine Vet Educ.* 2010;22:31-39.
 33. Wada S, Hobo S, Ode H, Niwa H, Moriyama H. Equine keratomycosis in Japan. *Vet Ophthalmol.* 2013;16:1-9.
 34. Keller RL, Hendrix VH. Bacterial isolates and antimicrobial susceptibilities in equine bacterial ulcerative keratitis (1993–2004). *Equine Vet J.* 2005;37:207-211.
 35. Suter A, Voelter K, Hartnack S, Spiess BM, Pot SA. Septic keratitis in dogs, cats and horses in Switzerland: associated bacteria and antibiotic susceptibility. *Vet Ophthalmol.* 2017;21:66-75.
 36. Sauer P, Andrew SE, Lassaline M, Gelatt KN, Denis HM. Changes in antibiotic resistance in equine bacterial ulcerative keratitis (1991–2000): 65 horses. *Vet Ophthalmol.* 2003;6:309-313.
 37. Utter ME, Davidson EJ, Wotman KL. Clinical features and outcomes of severe ulcerative keratitis with medical and surgical management in 41 horses (2000–2006). *Equine Vet Educ.* 2009;21:321-327.
 38. Moore C, Heller N, Majors L, et al. Prevalence of ocular microorganisms in hospitalised and stabled horses. *Am J Vet Res.* 1988;49:773-777.
 39. Massa KL, Murphy CJ, Hartmann FA, et al. Usefulness of aerobic microbial culture and cytologic evaluation of corneal specimens in the diagnosis of infectious ulcerative keratitis in animals. *J Am Vet Med Assoc.* 1999;215:1671-1674.
 40. Zeiss C, Neaderland M, Yang F-C, Terwilliger G, Compton S. Fungal polymerase chain reaction testing in equine ulcerative keratitis. *Vet Ophthalmol.* 2013;16:341-351.
 41. Ledbetter EC, Irby NL, Kim SG. *In vivo* confocal microscopy of equine fungal keratitis. *Vet Ophthalmol.* 2011;14:1-9.
 42. Ledbetter EC. Antifungal therapy in equine ocular mycotic infections. *Vet Clin North Am Equine Pract.* 2017;33:583-605.
 43. Ledbetter EC, Patten VH, Scarlett JM, Vermeylen FM. *In vitro* susceptibility patterns of fungi associated with keratomycosis in horses of the northeastern United States: 68 cases (1987–2006). *J Am Vet Med Assoc.* 2007;231:1086-1091.
 44. Pearce JW, Giuliano EA, Moore CP. *In vitro* susceptibility patterns of *Aspergillus* and *Fusarium* species isolated from equine ulcerative keratomycosis cases in the midwestern and southern United States with inclusion of the new antifungal agent voriconazole. *Vet Ophthalmol.* 2009;12:318-324.
 45. Gilger B, Vander Schel IQ, Cotter H, et al. *Associations among anti-fungal susceptibility, multi-locus sequence analysis and clinical outcome in equine fungal keratitis (abstract)*. 10th Annual Symposium of the International Equine Ophthalmology Consortium 2018; 33.
 46. Brooks DE, Andrew SE, Dillavou CL, et al. Antimicrobial susceptibility patterns of fungi isolated from horses with ulcerative keratomycosis. *Am J Vet Res.* 1998;59:138-142.
 47. Summerbell RC, Schroers H-J. Analysis of phylogenetic relationship of *Cylindrocarpon lichenicola* and *Acremonium falciforme* to the *Fusarium solani* species complex and a review of similarities in the spectrum of opportunistic infections caused by these fungi. *J Clin Microbiol.* 2002;40:2866-2875.
 48. Finnish Meteorological Institute (FMI). *Touko-elokuu oli mittaushistorian lämpimin*. Helsinki: FMI; 2018. https://ilmatieteenlaitos.fi/tiedotearkisto/-/journal_content/56/30106/656560294
 49. Wotman KL, Utter ME, Rankin SC. Antifungal susceptibility testing of *Aspergillus* species isolated from horses with keratomycosis in Southeast Pennsylvania: 10 cases (2006–2007) (abstract). *Vet Ophthalmol.* 2008;11:413-429.
 50. Clode AB, Davis JL, Salmon J, Michau TM, Gilger BC. Evaluation of concentration of voriconazole in aqueous humor after topical and oral administration in horses. *Am J Vet Res.* 2006;67:296-301.
 51. Latimer FG, Colitz CMH, Campbell NB, Papich MG. Pharmacokinetics of fluconazole following intravenous and oral administration and body fluid concentrations of fluconazole following repeated oral dosing in horses. *Am J Vet Res.* 2001;62:1606-1611.

52. Davis JL, Salmon JH, Papich MG. Pharmacokinetics and tissue distribution of itraconazole after oral and intravenous administration to horses. *Am J Vet Res.* 2001;62:1606-1611.
53. Lamoth F, Alexander BD. Comparing Etest and broth microdilution for antifungal susceptibility testing of the most-relevant pathogenic molds. *J Clin Microbiol.* 2015;53:3176-3181.
54. Brooks DE, Andrew SE, Biros DJ, et al. Ulcerative keratitis caused by beta-hemolytic *Streptococcus equi* in 11 horses. *Vet Ophthalmol.* 2000;3:121-125.
55. Sweeney CR, Irby NL. Topical treatment of *Pseudomonas* sp- infected corneal ulcers in horses: 70 cases (1977–1994). *J Am Vet Med Assoc.* 1996;209:954-957.
56. Brooks DE. Inflammatory stromal keratopathies: Medical management of stromal keratomalacia, stromal abscesses, eosinophilic keratitis, and band keratopathy in the horse. *Vet Clin North Am Equine Pract.* 2004;20:345-360.
57. Hendrix DVH, Brooks DE, Smith PJ, et al. Corneal stromal abscesses in the horse: a review of 24 cases. *Equine Vet J.* 1995;27:440-447.
58. Henriksen M, Andersen PH, Mietelka K, et al. Equine deep stromal abscess (51 cases – 2004–2009) – Part 2: the histopathology and immunohistochemical aspect with attention to the histopathologic diagnosis, vascular response, and infectious agents. *Vet Ophthalmol.* 2014;17:14-22.
59. Henriksen MDL, Andersen PH, Plummer CE, Mangan B, Brooks DE. Equine corneal stromal abscesses: An evolution in the understanding of pathogenesis and treatment during the past 30 years. *Equine Vet Educ.* 2013;25:315-323.

How to cite this article: Mustikka MP, Grönthal TSC, Pietilä EM. Equine infectious keratitis in Finland: Associated microbial isolates and susceptibility profiles. *Vet Ophthalmol.* 2020;23:148–159. <https://doi.org/10.1111/vop.12701>