




Contents lists available at ScienceDirect

## Acta Orthopaedica et Traumatologica Turcica

journal homepage: <https://www.elsevier.com/locate/aott>

## “Kissing Nail Technique” for the exchange of intramedullary implants in adjacent peri-implant fractures<sup>☆</sup>



Carolin Melcher<sup>a, \*</sup>, Patrick R. Delhey<sup>b, c</sup>, Christof Birkenmaier<sup>a</sup>, Peter H. Thaller<sup>b</sup>

<sup>a</sup> Department of Orthopaedic Surgery, Ludwig-Maximilians-University, Campus Großhadern, Munich, Germany

<sup>b</sup> Department of Surgery, Ludwig-Maximilians-University, Campus Innenstadt, Munich, Germany

### ARTICLE INFO

#### Article history:

Received 6 November 2016

Received in revised form

21 July 2017

Accepted 21 August 2017

Available online 3 October 2017

#### Keywords:

Management

Adjacent fracture

Osteoporosis

Elderly

Exchange nailing

### ABSTRACT

One third of the people aged 65 years and over fall every year, and 1–5% of these falls result in a fracture. For these people, history of fracture and surgery become a risk factor for recurrent falls. In osteoporotic patients, repeated fractures often require several osteosynthetic procedures within a short time frame. Despite the lack of biomechanical studies, clinical experience suggests that additional fractures adjacent to implants occur because of the difference in stiffness between the metallic implant and the osteoporotic bone. This requires customized fixation techniques to ensure stability.

The technique was first performed in an 81-year old female patient presenting with a dislocated proximal femoral fracture at the tip of a previously implanted distal femoral nail (DFN), and non-union of the old fracture. For this technique, the DFN was advanced until it passed the proximal fracture, thereby reducing both fractures, while a lateral femoral nail (LFN), extra-long and 3 mm thicker than the DFN, was introduced and advanced distally. The LFN was implanted in a “kissing nail technique,” meaning the tips of the two nails were touching each other, and all fracture fragments were held in functional reduction. The DFN was slowly pulled backwards and fragment stability was maintained, while both nails passed the distal non-union.

The Kissing Nail Technique allows simple, safe and fast reduction of all instable fragments, precise and easy positioning of the proximal entry point by the retrograde guide wire, a minimally invasive procedure, and stable fixation of a periprosthetic fracture.

We found this new customized procedure accommodating to the unique anatomical features of a single patient, that can be applied as a strategy especially for osteoporotic patients with periprosthetic fractures.

© 2017 Publishing services by Elsevier B.V. on behalf of Turkish Association of Orthopaedics and Traumatology. This is an open access article under the CC BY-NC-ND license (<http://creativecommons.org/licenses/by-nc-nd/4.0/>).

### Introduction

In elderly and frail adults, most of whom also suffer from osteoporosis, repeated falls are the leading cause of both emergency

department visits for trauma and death from injury, especially when these persons are institutionalized<sup>1–3</sup> One third of the people aged 65 years and over fall every year, and in one to five percent the fall results in a fracture<sup>4–6</sup>; most commonly hip fractures, vertebral fractures and wrist fractures. The prevalence of these falls increases with stage of frailty, age, number of previous falls and fractures, hospital admission, muscle weakness, low bone mineral density, and are more common in women than in men.<sup>7–10</sup> With population in the western world aging, it is expected that the number of falls and fractures will increase in coming years. These patients may then require multiple osteosynthetic procedures within a short time frame. Management requires stable fixation that allows early mobilization, as unstable fractures are associated with high rates of complications. Optimal fixation of proximal femoral fractures is still controversial. There is no evidence in the literature demonstrating

<sup>☆</sup> The work was performed at Department of Surgery, Nussbaumstr. 20 and Department of Orthopaedic Surgery Marchioninstr. 15, Munich.

\* Corresponding author. University Hospital Munich, Department of Orthopaedic Surgery, Marchioninstr. 15, 81377 Munich, Germany. Fax: +49 89 7095 5614.

E-mail addresses: [Carolin.Melcher@med.uni-muenchen.de](mailto:Carolin.Melcher@med.uni-muenchen.de) (C. Melcher), [Patrick.Delhey@mri.tum.de](mailto:Patrick.Delhey@mri.tum.de) (P.R. Delhey), [Christof.Birkenmaier@med.uni-muenchen.de](mailto:Christof.Birkenmaier@med.uni-muenchen.de) (C. Birkenmaier), [Peter.Thaller@med.uni-muenchen.de](mailto:Peter.Thaller@med.uni-muenchen.de) (P.H. Thaller).

Peer review under responsibility of Turkish Association of Orthopaedics and Traumatology.

<sup>c</sup> University Hospital Munich, Department of Surgery, Ismaningerstr. 22, 81675 Munich, Germany.

that an intramedullary nail is superior to extramedullary devices, such as a DHS, when used for stable fracture types.<sup>11,12</sup> Some studies comparing the gamma nail to the DHS show an increased rate of complications in femur fractures with the use of an intramedullary device.<sup>13</sup> Biomechanically, intramedullary devices have been shown to be superior for unstable fracture types.

A recent meta-analysis of commonly used implants for fixation in elderly trochanteric fractures by Arirachakaran, showed that compression plating (PCCP) seems to be favorable due to shorter operative time, and fewer general complications when compared to other techniques. Additionally, PFN was the lowest in blood loss and hospital stay.<sup>14</sup> IF is associated with shorter operating time, less blood loss, and less initial surgical trauma than total hip replacement, but it has a high reoperation rate, typically varying between 10 and 57%.<sup>15,16</sup> Despite the lack of dedicated biomechanical studies, clinical experience clearly suggests that additional fractures adjacent to previously placed implants often occur as a result of the significant difference in stiffness between the metallic implant and the osteoporotic bone weakened by immobilization. In these problematic cases, customized techniques accommodating the unique anatomical features of each individual patient are required to achieve satisfactory solutions.

We report a technique for the successful and safe exchange-implantation of a long proximal femoral nail into a proximally fractured femur that already contained a distal femoral nail, to stabilize an unhealed distal femoral fracture.

### Patient and methods

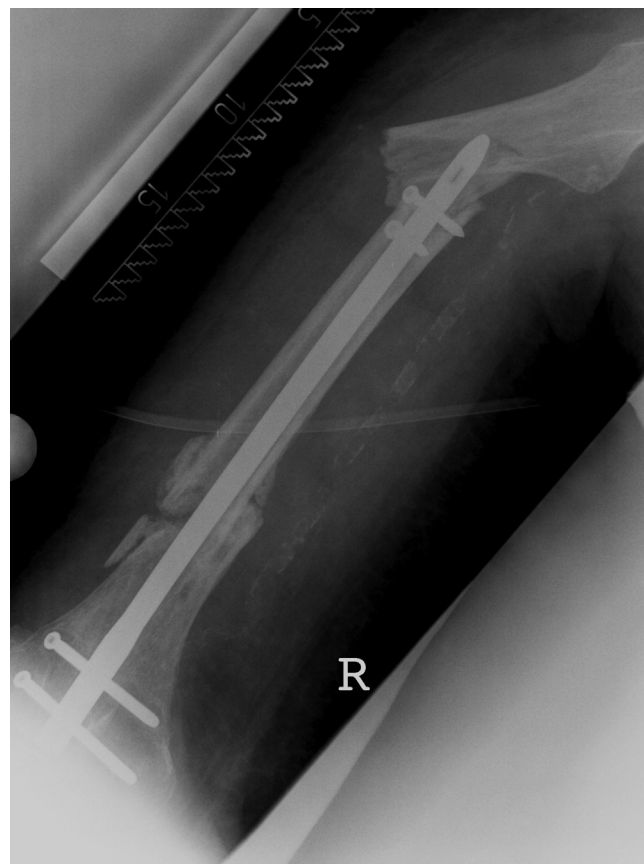An 81-year old female was admitted to our emergency department after a domestic fall. Evaluation of her medical history showed repeated falls due to visual impairment and overall weakness, osteoporosis, severe lymphedema of the right leg (since surgery for an inguinal sarcoma in 1993), phenprocoumon therapy after an unprovoked pulmonary embolism, and a retrograde intramedullary nailing of a distal femoral fracture 7 months prior. Our workup revealed a displaced periprosthetic fracture at the tip of a previously implanted distal femoral nail (DFN) and non-union of the old fracture (Fig. 1), possibly due to a thin unstable nail with progression of the previously known varus deformity.

The ethical committee of the Ludwig Maximilians University (LMU) was contacted before the operation, but we did not need clearance as the technique described didn't match the regulations of research on humans but constitutes a surgical technique.

After carefully weighing the treatment options, we decided to explant the DFN and to implant an extra-long lateral femoral nail (LFN) with a femoral neck component to stabilize both fractures. With two instable fractures, one of them still stabilized by the DFN, we faced the difficulty of having to remove the DFN and proximally insert a new nail into all three long bone fragments while maintaining correct alignment. However, the alternative to implanting a long nail proximally while leaving the DFN in place did not seem feasible either. We therefore decided to perform what we now call the "kissing nail technique".

### Surgical treatment

The patient was placed under general in the supine position on an orthopedic surgical table with mounted traction boots. The non-fractured limb was placed in a flexed and abducted position to provide more room for the C-arm. The patient was monitored for cardiac activity, blood pressure, and oxygen saturation continuously. Moderate traction was then applied to the right leg. In the



**Fig. 1.** Displaced proximal femoral fracture at the tip of the previously implanted distal femoral nail (DFN) and non-union of the old fracture.

first step, all but one interlocking screws of the DFN were removed. The last interlocking screw was left in place to maintain torsional stability. After performing a minimally invasive midline knee arthrotomy, the DFN extraction rod was connected and the last screw of the DFN was removed. Closed reduction of the proximal fracture was then performed under axial traction, and the tip of the DFN was advanced proximally through the medullary canal until it passed the proximal fracture and was positioned above the lesser trochanter. At this point, both the non-union and the acute fracture were reduced. Subsequently, the correct entry point for the LFN was marked by a guide wire under C-arm fluoroscopy and the nail was proximally inserted via the DFN and drilled through the piriformis fossa. After a proximal mini incision using a cannula system, the medullary canal was opened proximally by reaming along the guide wire throughout the first third of the femur. Once the reamer head reached the tip of the DFN, an LFN, extra-long and 3 mm thicker than the DFN, was introduced and advanced distally by the "kissing nail technique," meaning the tips of the two nails were touching each other and all fracture fragments were held in functional reduction. The DFN was slowly pulled backwards and fragment stability was maintained while both nails passed the distal non-union. As anticipated, the old fracture wasn't consolidated and there was still movement between the fragments. The LFN was pushed further into the medullary canal as the DFN was pulled back until it could be extracted completely (Fig. 2). Final positioning was controlled by fluoroscopy in ap and lateral views and the nail was interlocked distally first. In a final step, proximal interlocking was performed under axial compression of the osteosynthesis.

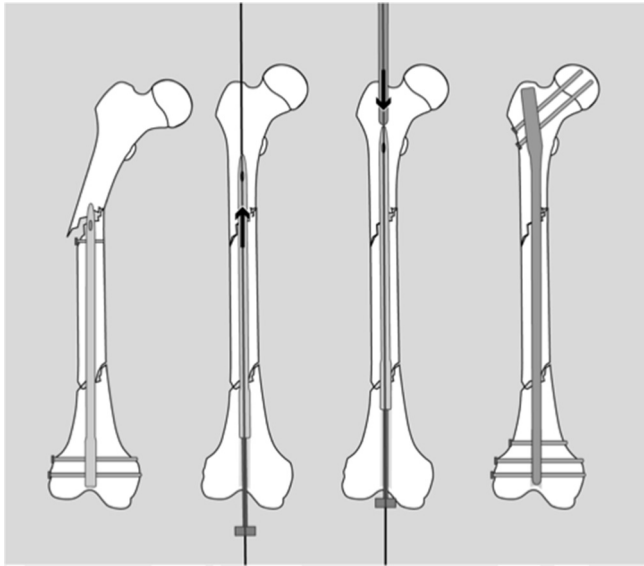


Fig. 2. The different steps of the kissing nail procedure.

## Results

The patient was mobilized by physiotherapy from the first day on, and managed to walk short distances on crutches when discharged. Weight bearing with half body weight was allowed after wound healing and enhanced from week 6 on. At this point, radiographs taken showed correct positioning of the nail, proper reduction, and increasing consolidation of both fractures (Fig. 3).

## Discussion

Treatment options for femoral fractures in elderly patients include total hip replacement (THA), hemiarthroplasty (HA), plating, and internal fixation (ORIF). Each option has proven benefits and potential risks, and evidence that supports each treatment. As no clinical guidelines exist, the surgical procedure is currently determined by the patient's presentation.<sup>17,18</sup> The continuing controversy results from the conflicting findings supporting a specific treatment modality, and there is still no universal surgical treatment suitable for all patients regardless of the physical

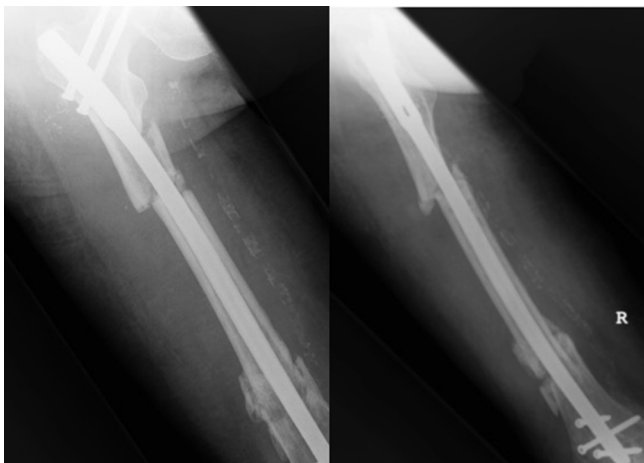


Fig. 3. Radiographs in ap and lateral view show correct positioning of the nail, good reduction, and increasing consolidation of both fractures.

demands and comorbidities. Fisher et al were able to show in a 2013 retrospective study of over 3000 patients that no differences could be found in the 30-d mortality rates among ORIF, HA, and THA in patients aged  $\geq 65$  y. ORIF and HA demonstrated a lower likelihood of developing respiratory complications compared with THA.<sup>15</sup> Concerning internal fixation, a wide variety of options are available. The degree of angulation, rotation, and shortening which can be tolerated while still providing good function is dependent upon fracture type and location. As intramedullary nailing provides certain additional biomechanical advantages compared to fixation with plates,<sup>19</sup> it is currently the treatment of choice when opting for internal fixation.<sup>20–22</sup> Our technique has some limitations. So far it has been used on just 2 patients with the one presented being the first. A small number of case reports have been published on fractures above the tip of intramedullary femoral implants.<sup>23–25</sup> Other authors have suggested that the distal end of the stiff intramedullary nail acts as a stress riser. The effect of this being aggravated local structural weakening as a result of the drill holes for the locking screws. Some fractures, like in our case, appear to derive from these drill holes.<sup>26</sup> Proximal drill holes especially have a substantial stress-riser effect since they are located in the diaphysis which has a smaller circumference and denser cortical bone than the condylar area.<sup>3,23,26,27</sup>

In our patient, the history of a new fall combined with the new onset of pain corroborated the diagnosis of an acute fracture. We hypothesized that the nail tip acted as a localizing area for the new fracture. Given the patient's pre-existing osteoporosis, it is possible that the fracture would have occurred without the presence of the implant. However, the implant may have determined the ultimate fracture geometry and location. Several options for surgical management were considered. Factors contributing to our choice of stabilization included the incomplete union of the femoral shaft, continued stability of the retrograde nail, and the location and geometry of the fracture. Other treatment options considered included removal of the retrograde nail followed by antegrade nailing using a reconstruction or trochanteric nail device. This case illustrates that fractures at the tip of a retrograde nail may still occur despite adequate nail length. Contributing factors may be patient related, such as osteopenia, but may also be associated with the implant and localized stress concentration. A large variety of implants and surgical techniques have been described for exchange nailing because of non-union<sup>28–30</sup> or femoral nail breakage,<sup>30–33</sup> but none has been established as an undisputed gold standard.<sup>34,35</sup> Treatment becomes even more challenging when there is a combination of ipsilateral fractures of the femoral shaft and neck,<sup>22,36</sup> as the preferred implant for one fracture might make reduction and fixation of the other even more difficult.<sup>37,38</sup> As this was the case with our patient, we decided to aim for a customized solution using the resources that were available such as a traction table for reduction. Even though the literature shows that traction tables provides safe and appropriate patient positioning, it can also cause time delays and complications. Decreasing anesthetic exposure and operative time is an important step in surgical treatment of high risk, elderly patients. Even though manual traction seems to be much more rapid with similar outcomes, it didn't seem manageable in a revision.

## Conclusion

In this case of consecutive distal and periprosthetic proximal femoral fracture with severely compromised soft tissue, the Kissing Nail Technique allowed for:

- simple, safe and fast reduction of instable fragments.
- outbalanced biomechanical stress.

- precise and easy positioning of the proximal entry point by the retrograde guide wire.
- a minimally invasive procedure.
- stable fixation.

We hope that this technical note may help others faced with similar problems in the exchange of intramedullary implants in successive long bone fractures of elderly patients.

### Conflicts of interest

None of the authors have any financial and personal relationships with other people or organizations to disclose that could inappropriately influence (bias) their work.

### Authors' contribution

Each author contributed to the work.

### References

1. Davison J, Bond J, Dawson P, Steen IN, Kenny RA. Patients with recurrent falls attending Accident & Emergency benefit from multifactorial intervention—a randomised controlled trial. *Age Ageing*. 2005;34(2):162–168.
2. Masud T, Morris RO. Epidemiology of falls. *Age Ageing*. 2001;30(suppl 4):3–7.
3. Komadina R. The hip fracture is an injury and a disease at the same time. *Zdrav Vestn*. 2008;77(IV):3–10.
4. Nevitt MC, Cummings SR, Kidd S, Black D. Risk factors for recurrent non-syncopal falls. A prospective study. *JAMA*. 1989;261(18):2663–2668.
5. Bloem BR, Boers I, Cramer M, Westendorp RG, Gerschlagler W. Falls in the elderly. I. Identification of risk factors. *Wien Klin Wochenschr*. 2001;113(10):352–362.
6. Tromp AM, Smit JH, Deeg DJ, Bouter LM, Lips P. Predictors for falls and fractures in the longitudinal aging study Amsterdam. *J Bone Min Res*. 1998;13(12):1932–1939.
7. Sri-on J, Tirrell GP, Bean JF, Lipsitz LA, Liu SW. Revisit, subsequent hospitalization, recurrent fall, and death within 6 months after a fall among elderly emergency department patients. *Ann Emerg Med*. 2017;70(4), 516.e2–521.e2.
8. Boonen S, Autier P, Barette M, Vanderschueren D, Lips P, Haentjens P. Functional outcome and quality of life following hip fracture in elderly women: a prospective controlled study. *Osteoporos Int*. 2004;15(2):87–94.
9. Brenneman SK, Barrett-Connor E, Sajjan S, Markson LE, Siris ES. Impact of recent fracture on health-related quality of life in postmenopausal women. *J Bone Miner Res*. 2006;21(6):809–816.
10. Orive M, Aguirre U, García-Gutiérrez S, et al. Changes in health-related quality of life and activities of daily living after hip fracture because of a fall in elderly patients: a prospective cohort study. *Int J Clin Pract*. 2015;69(4):491–500.
11. Baumgaertner MR, Curtin SL, Lindskog DM. Intramedullary versus extramedullary fixation for the treatment of intertrochanteric hip fractures. *Clin Orthop Relat Res*. 1998;(348):87–94.
12. Weiser L, Ruppel AA, Nüchtern JV, et al. Extra- vs. intramedullary treatment of pertrochanteric fractures: a biomechanical in vitro study comparing dynamic hip screw and intramedullary nail. *Arch Orthop Trauma Surg*. 2015;135(8):1101–1106.
13. Zou J, Xu Y, Yang H. A comparison of proximal femoral nail antirotation and dynamic hip screw devices in trochanteric fractures. *J Int Med Res*. 2009;37(4):1057–1064.
14. Arirachakaran A, Amphansap T, Thanindrarn P, et al. Comparative outcome of PFNA, Gamma nails, PCCP, Medoff plate, LISS and dynamic hip screws for fixation in elderly trochanteric fractures: a systematic review and network meta-analysis of randomized controlled trials. *Eur J Orthop Surg Traumatol*. 2017;27(7):937–952.
15. Fisher MA, Matthei JD, Obirieze A, et al. Open reduction internal fixation versus hemiarthroplasty versus total hip arthroplasty in the elderly: a review of the National Surgical Quality Improvement Program database. *J Surg Res*. 2013;181(2):193–198.
16. Wani IH, Sharma S, Latoo I, Salaria AQ, Farooq M, Jan M. Primary total hip arthroplasty versus internal fixation in displaced fracture of femoral neck in sexa- and septuagenarians. *J Orthop Traumatol*. 2014;15(3):209–214.
17. Iorio R, Healy WL, Lemos DW, Appleby D, Lucchesi CA, Saleh KJ. Displaced femoral neck fractures in the elderly: outcomes and cost effectiveness. *Clin Orthop Relat Res*. 2001;(383):229–242.
18. Macaulay W, Yoon RS, Parsley B, Nellans KW, Teeny SM. Displaced femoral neck fractures: is there a standard of care? *Orthopedics*. 2007;30(9):748–749.
19. Bucholtz R. Fractures of the shaft of the femur. In: Rockwood J, Green DP, Bucholtz RW, Heckman JD, eds. *Fractures in Adults*. Philadelphia: Lippincott-Raven; 1996. 1918–1927.
20. Alho A. Concurrent ipsilateral fractures of the hip and shaft of the femur. A systematic review of 722 cases. *Ann Chir Gynaecol*. 1997;86(4):326–336.
21. Alho A. Ipsilateral femoral neck and shaft fractures. *J Am Acad Orthop Surg*. 1999;7(1):76–78.
22. Lambiris E, et al. A new classification and treatment protocol for combined fractures of the femoral shaft with the proximal or distal femur with closed locked intramedullary nailing: clinical experience of 63 fractures. *Orthopedics*. 2003;26(3):305–308.
23. König G, van Bergen P, Suren EG. Femoral shaft fracture and secondary diagnosis of ipsilateral femoral neck fracture. Typical constellation or a complication of the distal femoral nail (DFN)? *Unfallchirurg*. 2002;105(7):656–659.
24. Kreusch-Brinker R. Ermüdungsbruch des Schenkelhalses nach Femurmarknagelung. *Unfallchirurgie*. 1988;14(5):295–298.
25. Leibner ED, et al. Femoral fracture at the proximal end of an intramedullary supracondylar nail: a case report. *Am J Orthop (Belle Mead NJ)*. 1999;28(1):53–55.
26. Radford PJ, Needoff M, Webb JK. A prospective randomised comparison of the dynamic hip screw and the gamma locking nail. *J Bone Jt Surg Br*. 1993;75(5):789–793.
27. Sitthiseriratip K, et al. Finite element study of trochanteric gamma nail for trochanteric fracture. *Med Eng Phys*. 2003;25(2):99–106.
28. Furlong AJ, Giannoudis PV, DeBoer P, Matthews SJ, MacDonald DA, Smith RM. Exchange nailing for femoral shaft aseptic non-union. *Injury*. 1999;30(4):245–249.
29. Webb LX, Winquist RA, Hansen ST. Intramedullary nailing and reaming for delayed union or nonunion of the femoral shaft. A report of 105 consecutive cases. *Clin Orthop Relat Res*. 1986;(212):133–141.
30. Winquist RA, Hansen Jr ST, Clawson DK. Closed intramedullary nailing of femoral fractures. A report of five hundred and twenty cases. 1984. *J Bone Jt Surg Am*. 2001;83-A(12):1912.
31. Brewster NT, Ashcroft GP, Scotland TR. Extraction of broken intramedullary nails—an improvement in technique. *Injury*. 1995;26(4):286.
32. Franklin JL, et al. Broken intramedullary nails. *J Bone Jt Surg Am*. 1988;70(10):1463–1471.
33. Tsidiris E, Narvani AA, Schizas C. Through-the-nail technique. *Acta Orthop Belg*. 2005;71(2):223–226.
34. Bedi A. Accuracy of reduction of ipsilateral femoral neck and shaft fractures—an analysis of various internal fixation strategies. *J Orthop Trauma*. 2009;23(4):249–253.
35. Papadokostakis G, et al. The role and efficacy of retrograding nailing for the treatment of diaphyseal and distal femoral fractures: a systematic review of the literature. *Injury*. 2005;36(7):813–822.
36. Hume E. Ipsilateral neck and shaft fractures of the femur. *Operative Techniques in Orthopaedics*. 1994;4(2):111–115.
37. Barei DP, Schildhauer TA, Nork SE. Noncontiguous fractures of the femoral neck, femoral shaft, and distal femur. *J Trauma*. 2003;55(1):80–86.
38. Wang HQ, et al. Treatment of ipsilateral femoral neck and shaft fractures. *Chin J Traumatol*. 2008;11(3):171–174.