



DOI: 10.14744/SEMB.2020.27448

Med Bull Sisli Etfal Hosp 2020;54(4):469–474

## Original Research

# Factors Influencing the Relationship of the External Branch of the Superior Laryngeal Nerve with the Superior Pole Vessels of the Thyroid Gland

Nurcihan Aygun,<sup>1</sup> Mahmut Kaan Demircioglu,<sup>1</sup> Zeynep Gul Demircioglu,<sup>1</sup> Ismail Ethem Akgun,<sup>1</sup>  
 Adnan Isgor,<sup>2</sup> Mehmet Uludag<sup>1</sup>

<sup>1</sup>Department of General Surgery, University of Health Sciences Turkey, Sisli Hamidiye Etfal Teaching and Research Hospital, Istanbul, Turkey

<sup>2</sup>Department of General Surgery, Bahcesehir University Faculty of Medicine, Istanbul, Turkey

### Abstract

**Objectives:** In a thyroidectomy, the external branch of the superior laryngeal nerve (EBSLN) is a potential risk during the superior pole dissection due to its close anatomical relationship with the superior thyroid artery and its highly variable anatomy. In this study, we aimed to evaluate the relationship of EBSLN with the superior pole considering Cernea classification and the factors affecting this relationship.

**Methods:** The data of thyroidectomized 126 patients (95 female, 31 male) with 200 neck sides (mean age of 45.6±12.1 years) using intraoperative neuromonitoring (IONM) for the EBSLN exploration were evaluated retrospectively. During the superior pole dissection, the EBSLN course was classified according to Cernea classification after being confirmed with IONM. It was defined as a large goiter in the case of the thyroid lobe volume being >50 cc. The factors influencing the presence of type 2b, which has the highest risk of injury, were evaluated using logistic regression analysis.

**Results:** Of the 200 EBSLNs evaluated, 52 (26%) were type 1, 134 (68%) were type 2a, and 14 (7%) were type 2b. The mean volumes of the resected thyroid lobes were 22±25 cc (min-max: 2-136), 23±20 cc (3-163), and 39±24 cc (3-65) in type 1, 2a and 2b, respectively, which was significantly higher in type 2b (p=0.035). Presence of large goiter rates were 5.8% (n=3), 8.2% (n=11), 64.3% (n=9) in type 1, 2a, and 2b, respectively, and was significantly higher in type 2b (p=0.0001). There was no significant difference between EBSLN Cernea types concerning age, sex, nerve side, presence of cancer and hyperthyroidism. In logistic regression analysis, large goiter was the only independent factor associated with Cernea type 2b. In case of a lobe volume greater than 50 cc, the probability of type 2b presence was approximately 25 times higher (p<0.001, odds ratio: 25.262).

**Conclusion:** Type 2b course of EBSLN is more common in large goiters, and it is 25 times more likely to be seen in the presence of a lobe volume over 50 cc. Thus, it should be considered that the probability of this high-risk course is significantly higher in large goiters.

**Keywords:** Cernea classification; external branch of the superior laryngeal nerve; intraoperative neuromonitoring; thyroidectomy.

Please cite this article as "Aygun N, Demircioglu MK, Demircioglu ZG, Akgun IE, Isgor A, Uludag M. Factors Influencing the Relationship of the External Branch of the Superior Laryngeal Nerve with the Superior Pole Vessels of the Thyroid Gland. Med Bull Sisli Etfal Hosp 2020;54(4):469–474".

**Address for correspondence:** Nurcihan Aygun, MD. Saglik Bilimleri Universitesi Sisli Hamidiye Etfal Egitim ve Arastirma Hastanesi, Genel Cerrahi Klinigi, Istanbul, Turkey

**Phone:** +90 553 277 95 78 **E-mail:** nurcihanaygun@hotmail.com

**Submitted Date:** September 21, 2020 **Accepted Date:** October 20, 2020 **Available Online Date:** December 11, 2020

©Copyright 2020 by The Medical Bulletin of Sisli Etfal Hospital - Available online at [www.sislietfaltip.org](http://www.sislietfaltip.org)

**OPEN ACCESS** This is an open access article under the CC BY-NC license (<http://creativecommons.org/licenses/by-nc/4.0/>).



The external branch of the superior laryngeal nerve (EBSLN) is the motor nerve of the cricothyroid muscle (CTM), one of the intrinsic muscles of the vocal cord. This muscle increases the length and tension of the vocal cord, contributing to the production of high pitch sounds. When the EBSLN is injured, it negatively affects the patient's quality of life secondary to deterioration in voice quality by causing a decrease in volume, difficulty in changing the pitch, and different clinical signs of vocal fatigue.<sup>[1-3]</sup>

Although it has been reported that especially voice professionals were affected by EBSLN injuries in the past, with the increasing attention on quality of life, it is a significant complication not only for voice professionals but for all patients, and awareness of the consequences of EBSLN injuries is gradually increasing.<sup>[4-5]</sup>

EBSLN is at potential risk during the superior pole dissection in thyroidectomy due to its close anatomical relationship with the superior thyroid artery and its highly variable anatomy.<sup>[2]</sup> Understanding and identification of the EBSLN anatomy is important for its preservation.<sup>[1-5]</sup> The use of intraoperative nerve monitoring (IONM) during thyroidectomy increases the visual or functional identification of EBSLN.<sup>[1, 6-8]</sup>

Different classifications related to the EBSLN anatomy have been defined. EBSLN was categorized according to the relationship between the superior thyroid vessels and the upper edge of the thyroid superior pole in Cernea and Kierner classifications, according to the relationship between the superior thyroid vessels and the cricoid cartilage in Selvan classification, and according to its relationship with the inferior pharyngeal constrictor muscle in the Friedman classification.<sup>[9-12]</sup>

Cernea classification is the most widely used classification system based on the potential risk of nerve injury during the thyroidectomy.

In the Cernea classification, the EBSLN crosses with superior thyroid vessels at a distance of more than 1 cm above the upper edge of the thyroid superior pole in type 1, at a distance less than 1 cm above the upper edge of the superior pole in type 2a, and below the upper edge of the superior pole in type 2b (Fig. 1).<sup>[9]</sup>

Although both type 2a and type 2b have the risk of injury due to their close course to the thyroid superior pole during dissection and ligation of the upper pole vessels, type 2b has the highest risk.<sup>[9, 13-15]</sup>

In this study, we aimed to evaluate the relationship of EBSLN with the superior pole and its vessels and also the factors influencing this relationship.

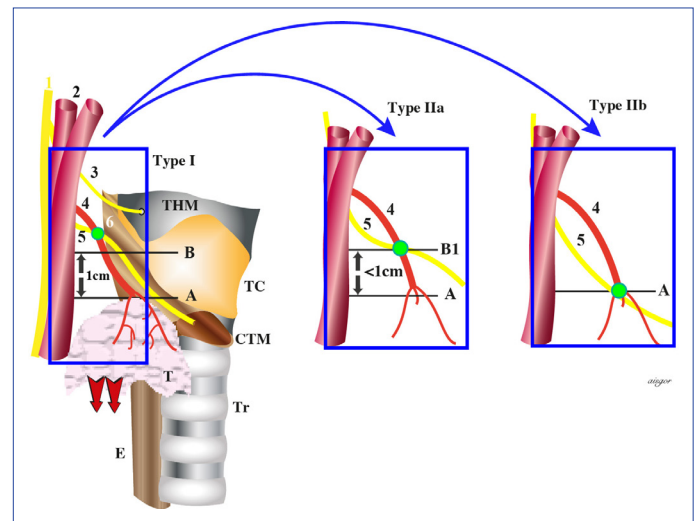


Figure 1. Cernea classification.

## Methods

Prospectively recorded data of patients who underwent intraoperative nerve monitoring (IONM) guided thyroidectomy between January and December 2015 were evaluated retrospectively in this study. Patients with primary thyroid surgery for malignant or benign thyroid disease, whose EBSLNs have been identified with IONM and classified considering Cernea and Friedman classifications, were included in this study. Patients with secondary surgery and unidentified EBSLNs during surgery were excluded from this study.

IONM-guided superior pole dissection technique has been described in detail in previous studies.<sup>[1, 8, 16]</sup> During the dissection of the upper pole, each structure thought to be the nerve was stimulated using IONM and EBSLN was confirmed by observing the contraction of the CTM. If EBSLN was not able to be identified visually, it was searched by stimulating the inferior pharyngeal muscle fibers near the laryngeal head of the sternothyroid muscle with a probe. If the nerve was not found with the probe, the muscle fibers were not dissected to find EBSLN through or under the inferior pharyngeal constrictor muscle fibers.<sup>[1, 16]</sup> After confirming with EBSLN with IONM, it was categorized according to the Cernea classification<sup>[9]</sup> and the data were recorded (Fig. 1).

After the thyroid lobe was resected, its dimensions were measured. Each thyroid lobe volume was calculated separately using the formula: (length x width x depth) x 0.479 (standard WHO correction) = cm<sup>3</sup> (cc).<sup>[17]</sup>

A thyroid lobe having a volume of >50 cc was defined as large goiter, and if its volume was <50 cc, it was defined as small goiter.<sup>[18]</sup>

The effects of age, sex, nerve side, thyroid lobe volume, presence of malignancy and hyperthyroidism were evaluated concerning the relationship between EBSLN and su-

terior pole vessels. The effects of age, sex, hyperthyroidism, cancer, and presence of large goiter regarding the presence of type 2b, which have the highest risk of injury, were evaluated by logistic regression analysis.

### Statistical Analysis

Categorical variables were evaluated using the  $\chi^2$  test. While comparing more than two groups, the Tukey HSD test, which is a single-step multiple comparison procedure, was used to find the difference between the binary groups. Factors influencing the presence of EBSLN type 2b were evaluated using logistic regression analysis. A value of  $p < 0.05$  was considered to be significant.

### Results

In this study, the data of 74 bilateral and 52 unilateral thyroidectomies via IONM in 126 patients (95 female, 31 male) (mean age;  $45.6 \pm 12.1$  years) with 200 EBSLNs were evaluated. The general distribution of the patients is given in Table 1. Of the 200 EBSLNs evaluated, 52 (26%) were

type 1, 134 (68%) were type 2a, and 14 (7%) were type 2b (Table 2). The mean volumes of resected thyroid lobes were  $22 \pm 25$  cc (min-max: 2-136),  $23 \pm 20$  cc (min-max: 3-163) and  $39 \pm 24$  cc (min-max: 3-65) in type 1, 2a and 2b, respectively, and mean thyroid lobe volume was significantly higher in type 2b than in other types ( $p = 0.035$ ). Although lobe volume was similar in type 1 and 2a in paired comparison ( $p = 0.960$ ), lobe volume was higher in type 2b than that was both in type 1 ( $p = 0.021$ ) and in type 2a ( $p = 0.018$ ). Large goiter existed in 23 (11.5%) neck sides, and presence of large goiter rates were 5.8% ( $n = 3$ ), 8.2% ( $n = 11$ ), 64.3% ( $n = 9$ ) in type 1, 2a, and 2b, respectively, and was significantly higher in type 2b than in type 1 and 2a (both:  $p < 0.001$ ). There was no significant difference between EBSLN Cernea types concerning age, sex, neck side, presence or suspicion of cancer, Friedman classification and hyperthyroidism. In logistic regression analysis, large goiter was the only independent factor associated with the Cernea type 2b nerve course. In case of a lobe volume greater than 50 cc, the probability of type 2b presence was approximately 25 times higher ( $p < 0.001$ , odds ratio: 25.262) (Table 3).

### Discussion

EBSLN is potentially at risk during superior pole dissection in thyroidectomy, as its anatomic variations are frequent and are closely related to the upper pole vessels.<sup>[2]</sup>

Cernea classification is based on the potential injury risk of the nerve during thyroidectomy. In our study, the rates of Cernea type 1, 2a, and 2b were 26%, 68%, 7%, respectively, and 75% (the sum of type 2a and 2b) of the EBSLNs crossing the superior pole vessels within 1 cm distance was at potential risk. However, Cernea type 2b is the nerve course

**Table 1.** General distribution of the patients according to their characteristics

Characteristics	n=126
Age	45.6±12.1 (19-91)
Sex (Female/Male), n (%)	95/31 (75.4/24.6)
Preoperative Diagnosis	
MNG, n (%)	59 (46.8)
Toxic MNG, n (%)	8 (6.3)
Graves, n (%)	9 (7.1)
Cancer or Suspicion of Cancer, n (%)	50 (39.8)
Bilateral/Unilateral Surgery, n (%)	74 (58.7)/52 (41.3)

**Table 2.** Factors influencing the relationship of EBSLN with superior pole and vessels

	Cernea 1	Cernea 2a	Cernea 2b	p
n (%)	52 (26)	134 (68)	14 (7)	
Nerve Side (Right/Left), n (%)	22/30 (42.3/57.7)	72/62 (53.7/46.3)	7/7 (50/50)	0.376
Age (Mean±SD) (Min-Max)	46±12.1 (23-75)	45±11.7 (19-91)	45.6±12.3 (26-91)	0.456
Sex F/M (n(%))	37/15 (71.2/28.8)	104/30 (77.6/22.4)	8/6 (57.1/42.9)	0.201
Lobe Vol. (cc) (Mean±SD) (Min-Max)	21.9±24.9 <sup>1</sup> (2-136)	24.9±19.5 <sup>2</sup> (3-163)	39.2±23.6 <sup>3</sup> (3-65)	0.035
Large Goiter (>50 cc), n (%)	3 <sup>4</sup> (5.8)	11 <sup>5</sup> (8.2)	9 <sup>6</sup> (64.3)	<0.001
Hyperthyroidism, n (%)	3 (5.8)	14 (10.4)	1 (7.1)	0.587
Cancer or Suspicion of Cancer, n (%)	21 (40.4)	45 (33.6)	3 (21.4)	0.386
Friedman, n (%)				0.165
1	27 (52.9)	83 (61.9)	10 (71.4)	
2	5 (9.6)	15 (11.2)	3 (21.4)	
3	20 (38.5)	36 (26.9)	1 (7.1)	

p (1 vs 2) = 0.960, p (1 vs 3) = 0.021, p (2 vs 3) = 0.018; p (4 vs 5) = 0.760, p (4 vs 6) < 0.001, p (5 vs 6) < 0.001.

**Table 3.** Evaluation of the factors influencing EBSLN course by logistic regression analysis

Variables	Log Odds Ratio	p	Odds Ratio (95% CI)
Age	-0.055	0.076	0.947 (0.89-1.007)
Hyperthyroidism	-0.256	0.853	0.774 (0.052-11.629)
Sex	0.338	0.692	1.402 (0.263-7.471)
Suspicion of Cancer	-0.602	0.531	0.548 (0.083-3.598)
Large Goiter	3.229	<0.001	25.262 (4.854-131.469)

with the highest risk since it crosses the superior pole vessels below the upper edge of the superior pole.<sup>[9]</sup>

According to our results, there was no difference between the Cernea types concerning age, sex, nerve side, hyperthyroidism, Friedman classification and cancer suspicion or presence of cancer, and no significant relationship was found for Cernea type 2b. Although the thyroid volume was similar in Cernea type 1 and type 2a ( $p=0.960$ ), it was significantly higher in type 2b than both types (type 1 vs 2b,  $p=0.021$ ; type 2a vs 2b,  $p=0.018$ ). In addition, the rate of large goiter ( $>50\text{cc}$ ) was 5.8%, 8.2%, 64.3% in type 1, 2a, 2b, respectively, and was significantly higher in type 2b than both type 1 ( $p<0.001$ ) and type 2a ( $p<0.001$ ). Large goiter was the only factor that showed a significant relationship with type 2b in logistic regression analysis. The probability of type 2b was 25 times higher in large goiters with a lobe volume greater than 50 cc (Odds ratio: 25.262 (95%/CI: 4.854-131.469). We suggest that this is related to the increase in the thyroid volume due to a thyroid disease resulting in the thyroid superior pole growing cranially and getting closer to the EBSLN. The higher prevalence of type 2 nerve course in clinical series than in cadaver series is important evidence supporting this suggestion about thyroid enlargement in thyroid diseases requiring surgery. In addition, the total prevalence of type 2a and 2b in the meta-analysis was 65% in clinical series and 49% in cadaver series.<sup>[19]</sup>

Patients with a high probability of a type 2b nerve course can be predicted by preoperative thyroid volume measurement via ultrasonography.

In the studies conducted by Ravikuvar et al.,<sup>[20]</sup> a significant relationship between the incidence of Cernea type 2b and goiter with a volume greater than 50 cc (Odd ratio: 438.5 (95% CI: 194.63-988.28) and the presence of hyperthyroidism (Odd ratio: 6.425 (95% CI: 2.835-14.562)) was detected, while there was no significant relationship concerning age and sex. 180 of 912 thyroid lobes evaluated in this study were larger than 50 cc in volume (19.7%) and 82.2% of large lobes were toxic. 93% of the nerves at risk were able to be identified visually. All of the Cernea type 1 nerves were identified in small goiters, but not detected

in large goiters. 94.2% of Cernea type 2b nerves were detected in large goiters and 5.2% in small goiters, and the prevalence was 39.2% in toxic goiters and 4.6% in non-toxic goiters. In another study, in the presence of thyroid lobe volume below 20 cc, Cernea type 2a rate was 58%, type 2b rate was 8.5%, and the rate was 66.5% in total, while over 20 cc, it increased to 72%, 15% and 87%, respectively.

In some other studies, the relationship between gland weight and EBSLN type has been investigated. Cernea et al.<sup>[14]</sup> analyzed data on 13 EBSLNs in nine female patients with large goiters. The mean dimensions of the goiter were 10.9 cm x 7.3 cm x 5 cm, mean specimen weight was 430 grams, and the Cernea type 2b course was detected in 54% of EBSLNs.

In the study of Aina and Hisham,<sup>[21]</sup> Cernea type 1 rate was 23.4%, type 2a rate was 65.3%, type 2b rate was 11.3% in the presence of goiter below 100 g; in large goiters over 100 g, it was 7.7% 41% and 51.3% respectively, and the rate of type 2b increased significantly in the presence of goiter larger than 100 g.

Pagedar et al.<sup>[22]</sup> found a significant relationship between the incidence of type 2b nerve and thyroid specimen weight (not lobe weight) resected and thyroid lobe diameters. Type 2b incidence was 72% when thyroid specimen weight was over 50 grams (Odd ratio, 3.24; 95% CI, 1.28-8.24;  $p=0.006$ ), 62% when the superior inferior diameter of the thyroid lobe was greater than 5.5 cm (Odd ratio, 2.13; 95% CI, 1.10-4.13;  $p=0.02$ ), and 79% (Odd ratio, 4.65; 95% CI, 1.48-14.63;  $p=0.005$ ) when anterior-posterior diameter was greater than 3.5 cm.

Furlan et al.<sup>[23]</sup> evaluated intrinsic factors associated with the EBSLN course according to the Cernea classification on 72 neck sides in 36 fresh human cadavers. The researchers found no significant difference in terms of sex, ethnicity, and neck side. They found a significant difference between Cernea types concerning thyroid lobe volume ( $p<0.001$ ) and an individual's height ( $p<0.001$ ). In Cernea type 1, 2a, 2b, the thyroid lobe volume (mean $\pm$ SD) was 7.2 $\pm$ 2.5 cm<sup>3</sup>, 11.5 $\pm$ 5.7 cm<sup>3</sup>, 12.1 $\pm$ 6.9 cm<sup>3</sup>, respectively, and the individual's height was 1.79 $\pm$ 0.07 m, 1.72 $\pm$ 0.07 m, 1.70 $\pm$ 0.10 m, respectively, and they reported that these intrinsic factors (height and thyroid volume) could potentially affect the EBSLN trace. The researchers claimed that the taller the individual, the farther the EBSLN will be from the superior thyroid pole and that it can be explained based on the human body's embryogenesis, growth, development and anatomical features.

Although some studies have reported that the EBSLN position may be related to ethnicity, it is not clear how ethnic-

ity affects the topography of the nerve. Aina and Hisham found the rate of type 2b higher in the Indian population than in Chinese and Malezian patients, although it was not statistically significant in Kuala Lumpur, and stated that it had no association with goiter size.<sup>[21]</sup>

Hurtado-Lopez et al.<sup>[24]</sup> reported that the frequency of risky course of EBSLN (type 2a + 2b) in the Mexican Mestizo population was higher than some reference series in the literature.

Similarly, Chuang et al.<sup>[15]</sup> detected risky Cernea type 2 rate for EBSLN (type 2a+b) as 78% in Chinese and although this rate was similar to the ones found in the studies performed in India and Mexico, they reported that it was higher than the rates reported from Brazil, Italy and Turkey.

Cernea et al.<sup>[13]</sup> reported that the course of type 2b EBSLN with higher risk was more common in non-white individuals (41%) than in white individuals (5%).

Although the effect of ethnicity on the course of the nerve is not clear, these data in the literature suggest that ethnicity may have some effects on the surgical anatomy of EBSLN.<sup>[5]</sup>

The main limitations of our study are that it is a retrospective study and some topographic anatomical features that may be effective in the course of EBSLN were not evaluated.

## Conclusion

Identification and protection of EBSLN in superior pole dissection in thyroidectomy is one of the important steps of safe thyroidectomy. Significant thyroid enlargement is one of the main indications for surgery, and preoperative thyroid volume can be measured by ultrasonography and the growth rate can be determined.

As a result, type 2b course of EBSLN with the highest injury risk is common in large goiters, and it is 25 times more likely to be seen in the presence of lobe volume over 50 cc. The significantly higher rate of this high-risk course of the nerve to occur due to the displacement of the upper pole superiorly, secondary to the enlargement in large goiters, should be taken into account.

## Disclosures

**Ethics Committee Approval:** The study was approved by Sili Hamidiye Etfal Teaching and Research Hospital Ethical Committee.

**Peer-review:** Externally peer-reviewed.

**Conflict of Interest:** None declared.

**Authorship Contributions:** Concept – N.A., M.U.; Design – N.A., A.I., M.U.; Supervision – A.I., M.U.; Data collection &/or processing – N.A., M.K.D., Z.G.D., I.E.A.; Analysis and/or interpretation – A.I., M.U.; Literature search – N.A., A.I., M.U.; Writing – N.A., A.I., M.U.; Critical review – A.I., M.U.

## References

1. Aygün N, Besler E, Celayir F, Bozdağ E, Çitgez B, Gürkan G, et al. The effect of the intraoperative neuromonitoring to the external branch of the superior laryngeal nerve identification and contribution of the nerve to the motor function of the thyroaritenoid muscle. *Med Bull Sisli Etfal Hosp* 2016;50:97–102.
2. Barczyński M, Randolph GW, Cernea CR, Dralle H, Dionigi G, Alesina PF, et al; International Neural Monitoring Study Group. External branch of the superior laryngeal nerve monitoring during thyroid and parathyroid surgery: International Neural Monitoring Study Group standards guideline statement. *Laryngoscope* 2013;123 Suppl 4:S1–14.
3. Uludağ M, Tanal M, İşgör A. A Review of Methods for the Preservation of Laryngeal Nerves During Thyroidectomy. *Sisli Etfal Hastan Tip Bul* 2018;52:79–91.
4. Whitfield P, Morton RP, Al-Ali S. Surgical anatomy of the external branch of the superior laryngeal nerve. *ANZ J Surg* 2010;80:813–6.
5. Potenza AS, Araujo Filho VJF, Cernea CR. Injury of the external branch of the superior laryngeal nerve in thyroid surgery. *Gland Surg* 2017;6:552–62.
6. Naytah M, Ibrahim I, da Silva S. Importance of incorporating intraoperative neuromonitoring of the external branch of the superior laryngeal nerve in thyroidectomy: A review and meta-analysis study. *Head Neck* 2019;41:2034–41.
7. Uludag M, Aygün N, Kartal K, Besler E, Işgör A. Is intraoperative neural monitoring necessary for exploration of the superior laryngeal nerve? *Surgery* 2017;161:1129–38.
8. Uludag M, Aygün N, Kartal K, Çitgez B, Besler E, Yetkin G, et al. Contribution of intraoperative neural monitoring to preservation of the external branch of the superior laryngeal nerve: a randomized prospective clinical trial. *Langenbecks Arch Surg* 2017;402:965–76.
9. Cernea CR, Ferraz AR, Nishio S, Dutra A Jr, Hojaij FC, dos Santos LR. Surgical anatomy of the external branch of the superior laryngeal nerve. *Head Neck* 1992;14:380–3.
10. Kierner AC, Aigner M, Burian M. The external branch of the superior laryngeal nerve: its topographical anatomy as related to surgery of the neck. *Arch Otolaryngol Head Neck Surg* 1998;124:301–3.
11. Friedman M, LoSavio P, Ibrahim H. Superior laryngeal nerve identification and preservation in thyroidectomy. *Arch Otolaryngol Head Neck Surg* 2002;128:296–303.
12. Selvan B, Babu S, Paul MJ, Abraham D, Samuel P, Nair A. Mapping the compound muscle action potentials of cricothyroid muscle using electromyography in thyroid operations: a novel method to clinically type the external branch of the superior laryngeal nerve. *Ann Surg* 2009;250:293–300.
13. Cernea CR, Ferraz AR, Furlani J, Monteiro S, Nishio S, Hojaij FC, et al. Identification of the external branch of the superior laryngeal nerve during thyroidectomy. *Am J Surg* 1992;164:634–9.

14. Cernea CR, Nishio S, Hojaj FC. Identification of the external branch of the superior laryngeal nerve (EBSLN) in large goiters. *Am J Otolaryngol* 1995;16:307–11.
15. Chuang FJ, Chen JY, Shyu JF, Su CH, Shyr YM, Wu CW, et al. Surgical anatomy of the external branch of the superior laryngeal nerve in Chinese adults and its clinical applications. *Head Neck* 2010;32:53–7.
16. Aygün N, Uludağ M, İsgör A. Contribution of intraoperative neuromonitoring to the identification of the external branch of superior laryngeal nerve. *Turk J Surg* 2017;33:169–74.
17. Shabana W, Peeters E, De Maeseneer M. Measuring thyroid gland volume: should we change the correction factor? *AJR Am J Roentgenol* 2006;186:234–6.
18. Ravikumar K, Sadacharan D, Muthukumar S, Mohanpriya G, Hussain Z, Suresh RV. EBSLN and Factors Influencing its Identification and its Safety in Patients Undergoing Total Thyroidectomy: A Study of 456 Cases. *World J Surg* 2016;40:545–50.
19. Cheruiyot I, Kipkorir V, Henry BM, Munguti J, Cirocchi R, Odula P, et al. Surgical anatomy of the external branch of the superior laryngeal nerve: a systematic review and meta-analysis. *Langenbecks Arch Surg* 2018;403:811–23.
20. Menon RR, Murali S, Nair CG, Babu MJC, Jacob P. Correlation between the Cernea Classification of External Branch of Superior Laryngeal Nerve in Relation to the Ultrasound-based Volume of Thyroid Gland. *Indian J Endocrinol Metab* 2017;21:845–7.
21. Aina EN, Hisham AN. External laryngeal nerve in thyroid surgery: recognition and surgical implications. *ANZ J Surg* 2001;71:212–4.
22. Pagedar NA, Freeman JL. Identification of the external branch of the superior laryngeal nerve during thyroidectomy. *Arch Otolaryngol Head Neck Surg* 2009;135:360–2.
23. Furlan JC, Cordeiro AC, Brandão LG. Study of some "intrinsic risk factors" that can enhance an iatrogenic injury of the external branch of the superior laryngeal nerve. *Otolaryngol Head Neck Surg* 2003;128:396–400.
24. Hurtado-Lopez LM, Zaldivar-Ramírez FR. Risk of injury to the external branch of the superior laryngeal nerve in thyroidectomy. *Laryngoscope* 2002;112:626–9.