

Case Report

Visual hallucinations: A novel complication after hemispherectomy

Jonas Vanags^{a,1}, Monisha Sachdev^{b,1}, Gerald Grant^c, Mohamad A. Mikati^{b,*}^a Department of Neurology, Duke University Medical Center, 311 Research Drive, Durham, NC 27710, USA^b Division of Pediatric Neurology, Department of Pediatrics, Duke University Medical Center, T0913 Children's Health Center, DUMC Box 3936, 2301 Erwin Rd, Durham, NC 27710, USA^c Division of Pediatric Neurosurgery, Department of Neurosurgery, 2301 Erwin Road, Durham, NC 27710, USA

ARTICLE INFO

Article history:

Received 25 May 2017

Received in revised form 21 September 2017

Accepted 22 September 2017

Available online 2 October 2017

Keywords:

Epilepsy

Seizure

Epilepsy surgery

Hallucinations

Visual hallucinations

ABSTRACT

Two patients at our center experienced florid visual hallucinations following hemispherectomy. The first patient had drug-resistant left hemispheric focal seizures at 20 months of age from a previous stroke. Following functional hemispherectomy at age 3, he experienced frightening hallucinations 1 month post-operatively lasting 3.5 months. Our second patient underwent subtotal hemispherectomy at age 6 for drug-resistant focal seizures from right hemispheric cortical dysplasia. Eighteen months later he developed scary visual hallucinations during which he would shout and throw things. Hallucinations recurred for 6 months. In our experience in these patients, even though symptoms were florid, they were transient and subsided 3–6 months later.

© 2017 The Authors. Published by Elsevier Inc. This is an open access article under the CC BY-NC-ND license (<http://creativecommons.org/licenses/by-nc-nd/4.0/>).

1. Introduction

To our knowledge visual hallucinations following hemispherectomy have not been reported [1,2]. Visual hallucinations refer to visual images that are not in fact present, and can be either elemental (occipital origin) or formed (temporal origin) representing visual memories. There have been reports of hallucinations in adults following intracranial surgeries, such as musical hallucinations and visual hallucinations associated with Charles-Bonnet syndrome [3,4]. Here we present two pediatric patients out of 24 consecutive patients operated at our center, with visual hallucinations after hemispherectomy. Hemispherectomy was functional in one person and subtotal in another. The hallucinations were disturbing to patients and families, but that eventually proved to be transient.

2. Case report

2.1. Patient 1

At the age of 20 months this previously healthy male developed an infarct of almost the entirety of the left hemisphere and another of the right frontal lobe secondary to non-accidental trauma. The patient was developing normally up to the time he was hospitalized at the age of

20 months. After the injury he lost his speech and his ability to talk. At 3 years of age, he began experiencing seizures lasting 2–10 min, consisting of right upper extremity clonic activity with altered consciousness. These events correlated with left hemispheric electrographic seizure onset and were refractory to numerous medications. He gradually improved and was able to walk with help at the age of 4–1/2 years. His speech also gradually improved and was developmentally normal by the age of 6 years, and quite articulate and talkative. However, at that age he still could not walk independently and needed to use a cane. It was noted that after periods of frequent seizures his motor and cognitive skills would regress. Postictally he slowly regained at least some of his previous abilities. At the age of 7 years, apparently due to the recurrent seizures, he was mildly cognitively delayed, used 3–4 word sentences, and still at times needed a cane to help with his ambulation. He was able to attend first grade in a mainstream classroom, but with a learning aide. Functional MRI 4 months before surgery demonstrated structural changes (as seen previously) as well as a dominant receptive speech area in the posterior right superior temporal gyrus and a possible accessory receptive speech focus in the left postcentral gyrus and inferior parietal lobule.

He underwent functional hemispherectomy at the age of 7 years. The operation consisted of frontal and parieto-occipital disconnections, temporal lobectomy and corpus callostomy to ensure disconnection of the entire hemisphere. He was discharged 9 days later and a few days after that he started reporting complex and vivid hallucinations of snakes. The hallucinations were 15–20 min in duration and occurred 2–3 times per week. These hallucinations were well formed. None of his previous seizure manifestations recurred. All medications were discontinued when he developed hallucinations, except for zonisamide,

* Corresponding author at: Division of Pediatric Neurology, Duke University Medical Center, T0913 Children's Health Center, Duke University Medical Center Box 3936, 2301 Erwin Road, Durham, NC 27710, USA.

E-mail address: mohamad.mikati@duke.edu (M.A. Mikati).

¹ Contributed equally.

polyethylene glycol, and an intrathecal baclofen pump. He had been on the same dose of zonisamide for more than a year prior to surgery. Zonisamide levels were measured several times and found to be within the therapeutic range. Ophthalmology consultation found no abnormalities. Although the hallucinations decreased in frequency, they persisted for 3.5 months and then subsided.

Routine EEG 6 weeks after surgery did not capture any hallucinations. Examination by ophthalmology was normal. Epileptiform discharges were seen only from the disconnected hemisphere. Non-contrasted CT showed complete disconnection of the hemispheres. At a follow up visit 10 months later, he was having no hallucinations and was still seizure free. His development was improved, as he was ambulating well, writing better than before the surgery and reading at a first grade level. His exam showed the expected right homonymous hemianopsia and right spastic hemiparesis (Fig. 1).

2.2. Patient

This patient presented at the age of 3 years with a history of left upper extremity weakness, hyperreflexia and impaired dexterity in that limb, and multiple focal seizures with impaired awareness daily consisting of left upper extremity clonic activity during sleep. He also had one generalized seizure per week. MRI revealed extensive right temporal, parietal and frontal lobe cortical dysplasia. Electrographically he had diffuse right hemisphere onset of his seizures, and frequent interictal right hemisphere 3 Hz spike-and-slow waves while awake that became almost continuous during sleep. The epileptic activity generally spared the right occipital region, which was normal on MRI as well. He failed multiple antiepileptic medications and was thus evaluated for epilepsy surgery.

At 6 years of age he underwent a subtotal hemispherectomy for drug-resistant seizures in which a frontal disconnection and anterior temporal lobectomy were performed. His hospital course was complicated by hydrocephalus requiring an external ventricular drain. Routine EEG one

week after surgery showed only right hemispheric slowing and infrequent right centrotemporal sharp waves and spikes. Eighteen months later, he developed hallucinations during which he would point to “scary” visual hallucinations. These hallucinations, which were not associated with any of his prior seizure symptoms, would last about 20–40 min and would occur 1–2 times per week. He would shout while intermittently pointing to the hallucinations. He would also throw things towards where he was seeing his hallucinations. He could not clearly articulate what he saw. None of his prior seizure manifestations included hallucinations. His fundoscopic examination, performed at 13 months before the surgery and serially at 11 months, 2 years, 2 years 8 months and 3 years 6 months after the surgery was normal. Antiepileptic drug levels were within the therapeutic range. EEG demonstrated bilateral frontotemporal epileptiform activity. MRI showed the corpus callosum to be intact posteriorly connecting both occipital lobes. These hallucinations lasted for six months and then subsided on their own. Since the surgery until his most recent follow-up visit at the age of 17 years, he has been seizure free while on oxcarbazepine and topiramate. He has the expected left homonymous hemianopsia, left hemiparesis and hemiparetic gait.

3. Discussion

Complex visual hallucinations have been described as occurring up to 2 months following various cerebral surgeries in adults. Freiman, et al. described four patients with Charles Bonnet syndrome after intracranial surgery (Table 1) [3]. Charles Bonnet syndrome, a syndrome of complex visual hallucinations in the setting of visual loss, was initially described in the elderly after ocular blindness, but is now recognized in younger individuals with cortical vision loss. It has even been described in children in rare instances, however following medical illnesses and non-surgical procedures [5]. In addition to these cases, there have been reports of adult patients with visual hallucinations following occipital and temporal resections (Table 1) [6,7]. Although Charles Bonnet syndrome is a possible explanation for the phenomenon

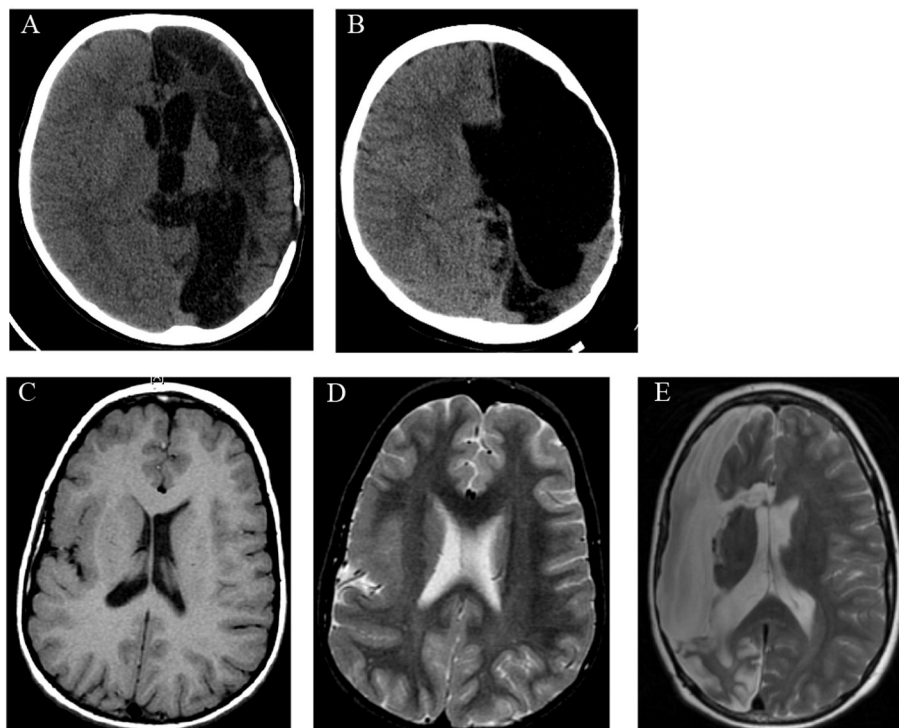


Fig. 1. (A, B) Non-contrast CT brain from the patient described in the first case both before (A) and after (B) hemispherectomy. (C–E) T1 and T2 non-contrast MRI brain from the patient described in the second case before (C, D) and T2 non-contrast MRI brain after (E) hemispherectomy with incomplete disconnection posteriorly.

Table 1

Age, surgery and timing of onset, frequency and duration of visual hallucinations after intracranial surgery in published cases. The last two rows represent the hemispherectomy cases reported in this article.

Reference	Age (years)	Surgery	Hallucination onset	Frequency and duration of hallucinations	Duration of occurrence
Freiman, et al.	40	Amygdalohippocampectomy	Day of surgery	Not described	4 days
Freiman, et al.	29	Amygdalohippocampectomy	After surgery (not otherwise described)	Not described	7 days
Freiman, et al.	38	Left parietal astrocytoma resection	After surgery (not otherwise described)	Not described	6 months
Freiman, et al.	50	Left parieto-occipital glioblastoma resection	After surgery (not otherwise described)	Not described	21 days
Choi, et al.	35	Right occipital cortical dysplasia resection	2 months after surgery	Not described	12 months
Contardi, et al.	49	Left anteromesial temporal resection	3 days after surgery	A few seconds to minutes, frequency not described	2 months
Current report	3	Hemispherectomy	1 month after surgery	15–20 min, 2–3 times per week	3.5 months
Current report	6	Subtotal hemispherectomy	18 months after surgery	20–40 min, 1–2 times per week	6 months

we observed, we do not claim that this is the only possible explanation as discussed below. Whether the hallucinations are due to Charles Bonnet syndrome notwithstanding, it is still important to be aware that visual hallucinations can be observed as a transient phenomenon in patients after hemispherectomy.

We observed visual hallucinations as a complication in 2 out of 24 consecutive patients who underwent hemispherectomy for drug-resistant focal seizures at our institution at the time of writing this report. The hallucinations were clearly formed in the first patient consisting of visions of snakes and were judged to also be formed in the second patient based on his behavior of pointing to them, throwing things at them and acting scared of them. Furthermore, we observed this complication in pediatric patients, a patient population that has not previously been described as experiencing visual hallucinations following intracranial surgery. Many hemispherectomy patients are too cognitively impaired or too young to report hallucinations, which could make detection of such a symptom more difficult. It is important to note that presently we do not have an explanation for the timing of the occurrence of the hallucinations. However, variability in the occurrence of visual hallucinations due to Charles Bonnet syndrome has also been reported in the literature.

Leading theories of Charles Bonnet syndrome pathogenesis suggest that deafferentation causes reorganization and hypersensitivity of remaining neurons in the cerebral cortex, generating visual hallucinations from the visual association areas of the brain [8]. In our patients the hallucinations may thus represent a surgically-induced reaction of the occipital cortex to the loss of connectivity from the resected tissue [8,9]. Another consideration is that these hallucinations could represent focal occipital lobe seizures either from the residual affected hemisphere with incomplete disconnection (Case 1), or from either occipital lobe particularly the non-resected side (Case 2). However, neither case demonstrated any activity consistent with their previous seizure types or other symptoms to support the possibility that these episodes were seizures. We also cannot rule out that the hallucinations may have been drug related, as both zonisamide and topiramate can cause psychosis. However, neither patient was started on any new medications around the time of onset of the hallucination and neither had any other manifestations of psychosis outside the visual hallucinations

described above. Thus, this possibility is similarly not very likely the sole causation.

4. Conclusion

Here we report visual hallucinations following hemispherectomy that were observed in 2 out of 24 consecutive patients raising the possibility that this may be an under-recognized phenomenon. Clinicians should be aware of this phenomenon to help gather more information regarding its nature and prognosis in pediatric patient populations. Although this initially caused distress to the patients and families, the hallucinations were ultimately transient.

Funding

This research did not receive any specific grant from funding agencies in the public, commercial or not-for-profit sectors.

References

- [1] Fountas KN, Smith JR, Robinson JS, Tamburrini G, Pietrini D, DiRocco C. Anatomical hemispherectomy. *Childs Nerv Syst* 2006;22:982–91.
- [2] Basheer SN, Connolly MB, Lautzenhiser A, Sherman EMS, Henderson G, Steinbok P. Hemispheric surgery in children with refractory epilepsy: seizure outcome, complications, and adaptive function. *Epilepsia* 2007;48:133–40.
- [3] Freiman TM, Surges R, Vougioukas VI, et al. Complex visual hallucinations (Charles Bonnet syndrome) in visual field defects following cerebral surgery. Report of four cases. *J Neurosurg* 2004;101:846–53.
- [4] Williams VG, Tremont G, Blum AS. Musical hallucinations after left temporal lobectomy. *Cogn Behav Neurol* 2008;21:38–40.
- [5] Aydin OF, Ince H, Tasdemir HA, Ozyurek H. Charles Bonnet syndrome after herpes simplex encephalitis. *Pediatr Neurol* 2012;46:250–2.
- [6] Choi EJ, Lee JK, Kang JK, Lee SA. Complex visual hallucinations after occipital cortical resection in a patient with epilepsy due to cortical dysplasia. *Arch Neurol* 2005;62:481–4.
- [7] Contardi S, Rubboli G, Giulioni M, et al. Charles Bonnet syndrome in hemianopia, following antero-mesial temporal lobectomy for drug-resistant epilepsy. *Epileptic Disord* 2007;9:271–5.
- [8] Tan CS, Sabel BA. Charles Bonnet syndrome after occipital cortical resection for cortical dysplasia may be related to denervation supersensitivity. *Arch Neurol* 2005;62:1479.
- [9] Guven H, Delibus S, Comoglu S. Transient lesion in the splenium of the corpus callosum due to carbamazepine. *Turk Neurosurg* 2008;18:264–70.