

# A novel method of vein cuff creation for below-knee femoropopliteal bypass with a prosthetic graft

Shun-Ichiro Sakamoto, MD, PhD, Masafumi Shibata, MD, PhD, Ken-Ichiro Takahashi, MD, Motoko Morishima, MD, Atsushi Hiromoto, MD, and Takashi Nitta, MD, PhD, *Tokyo, Japan*

## ABSTRACT

Vein cuff anastomosis is beneficial in cases in which a prosthetic graft is anastomosed to a small and thickened peripheral artery. Various types of vein cuff are currently in use, although their design is insufficient when a size discrepancy exists between the two vessels and the angle of anastomosis requires adjustment. We report a case of a patient who underwent below-knee femoropopliteal bypass using a new design of vein cuff (boat-form vein cuff) that increases the ease of cuff creation and enables surgeons to adjust the anastomotic size and angle. (*J Vasc Surg Cases and Innovative Techniques* 2020;6:165-7.)

**Keywords:** Femoropopliteal bypass; Vein cuff; Miller's cuff

In below-knee (BK) femoropopliteal (F-P) bypass, the quality of the graft is known to affect the outcomes of treatment for critical limb ischemia.<sup>1,2</sup> However, when an appropriate autologous vein cannot be harvested from the patient, the surgeon must perform anastomosis of the prosthetic graft to the atherosclerotic popliteal artery. Various reports have presented techniques for making the vein cuff that may improve patency of the prosthetic graft; one example is the Miller cuff and its modifications.<sup>3-5</sup> The design of vein cuffs mainly focuses on physiologic interposition, with the aim of creating a rectangular angle between the graft and recipient artery. However, a size discrepancy exists between the two vessels used to create the vein cuff, and approaches to overcome this issue are difficult. We report a new technique of making a vein cuff that comprises a trimmed boat-form design fitted to the anastomosis of the prosthetic graft. Written informed consent for publication of case details and images was obtained from the patient before drafting of the manuscript.

## CASE REPORT

We present the case of a 70-year-old man who has been receiving medical treatment for human immunodeficiency virus infection since 2008. The patient was referred to our hospital for

a skin ulcer on the left lower extremity in 2013. Angioplasty and stenting were performed in the external iliac artery and superficial femoral artery (FA), respectively. Superficial FA thrombosis occurred after stenting, and rheolytic thrombectomy and balloon angioplasty were performed twice in early 2014. The patient still complained of rest pain, and the left-side ankle-brachial index was 0.0 in June 2014. Angiography revealed occlusion of the superficial FA for the entire length; the collateral blood supply to the BK popliteal artery originated from the deep FA, and critically calcified lesions were identified in the left common FA. BK F-P bypass with in situ saphenous vein graft was primarily indicated. However, the patient presented with varicose veins in both legs. Both great and small saphenous veins and the accessory veins were deemed unusable as an adequate autogenous vein conduit.

We used a 6-mm polytetrafluoroethylene trilaminar graft (Advanta SST; Maquet, Rastatt, Germany) in BK F-P bypass. Endarterectomy was performed, and the graft was anastomosed to the midportion of the common FA. The BK portion of the popliteal artery was 4 mm in diameter with thick walls. First, we dissected a nonvaricose vein (7 cm in length) as illustrated in Fig 1. A longitudinal arterial incision was made, then side-to-side anastomosis was performed between the vein and popliteal artery. Heparinized saline solution was infused from the branch of the vein to check for suture leakage, after which the vein was incised from the distal side, 3 mm from the anastomotic suture line, toward the proximal side. The vein cuff was shaped like a boat, to which the graft was anastomosed at a sharp angle.

The patient was discharged without any complications. The left leg was free from ischemic symptoms, and its ankle-brachial index recovered to 1.1 postoperatively. The patient had been receiving anticoagulation with warfarin for 2 years in consideration of several risk factors for recurrence, such as dyslipidemia, hypertension, and smoking. No surgical or catheter intervention was needed during the entire postoperative period. At the 5-year follow-up, enhanced three-dimensional computed tomography angiography revealed that the graft was patent, depicting the anastomotic site including the vein cuff and every

---

From the Department of Cardiovascular Surgery, Nippon Medical School.

Author conflict of interest: none.

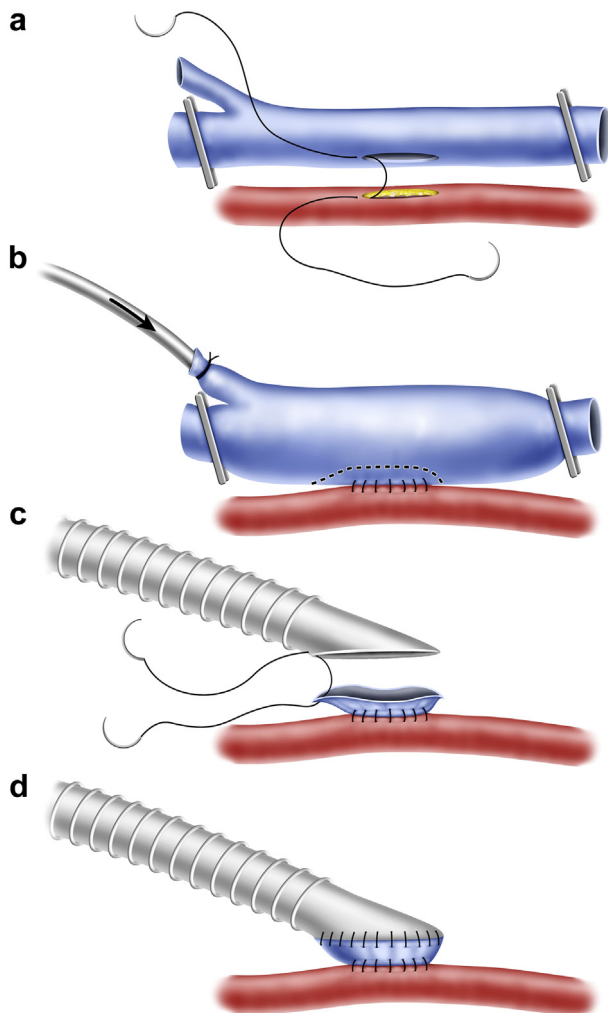
Correspondence: Shun-Ichiro Sakamoto, MD, PhD, Department of Cardiovascular Surgery, Nippon Medical School, 1-1-5 Sendagi, Bunkyo-ku, Tokyo 113-8603 Japan (e-mail: [saka-165@nms.ac.jp](mailto:saka-165@nms.ac.jp)).

The editors and reviewers of this article have no relevant financial relationships to disclose per the Journal policy that requires reviewers to decline review of any manuscript for which they may have a conflict of interest.

2468-4287

© 2020 The Authors. Published by Elsevier Inc. on behalf of Society for Vascular Surgery. This is an open access article under the CC BY-NC-ND license (<http://creativecommons.org/licenses/by-nc-nd/4.0/>).

<https://doi.org/10.1016/j.jvscit.2020.02.002>



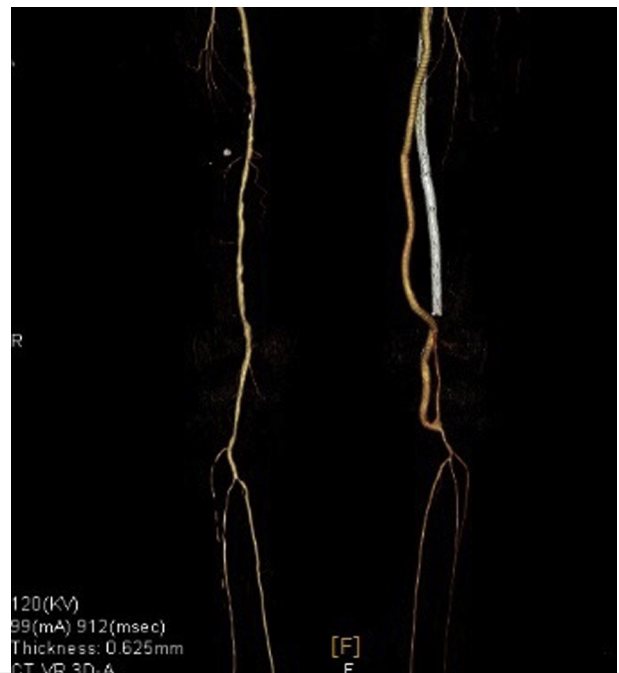**Fig 1.** Illustration of the boat-form vein cuff anastomosis. **a**, Side-to-side anastomosis between the vein and popliteal artery. **b**, Vein distention and selected incision line (dotted line). The arrow indicates the infusion of heparinized saline solution. **c**, Anastomosis between the graft and vein cuff. **d**, Completed boat-form vein cuff anastomosis.

branch of the left lower limb (Fig 2). Color Doppler ultrasound revealed no turbulent flow in the distal anastomosis of the BK F-P bypass.

## DISCUSSION

In the present era of endovascular treatment, BK F-P bypass is a highly important procedure for limb salvage in patients with critical limb ischemia. According to the reports of high-volume studies, autologous veins are superior as graft material for BK F-P bypass in terms of patency and limb salvage.<sup>1,2</sup>

Intimal hyperplasia in the suture line is thought to be the primary cause of restenosis or thromboembolism after vascular anastomosis.<sup>6</sup> Shear stress due to end-to-side anastomosis between two vessels that exhibit a size discrepancy is one potential mechanism.<sup>7</sup> Another mechanism of intimal hyperplasia is compliance mismatch in

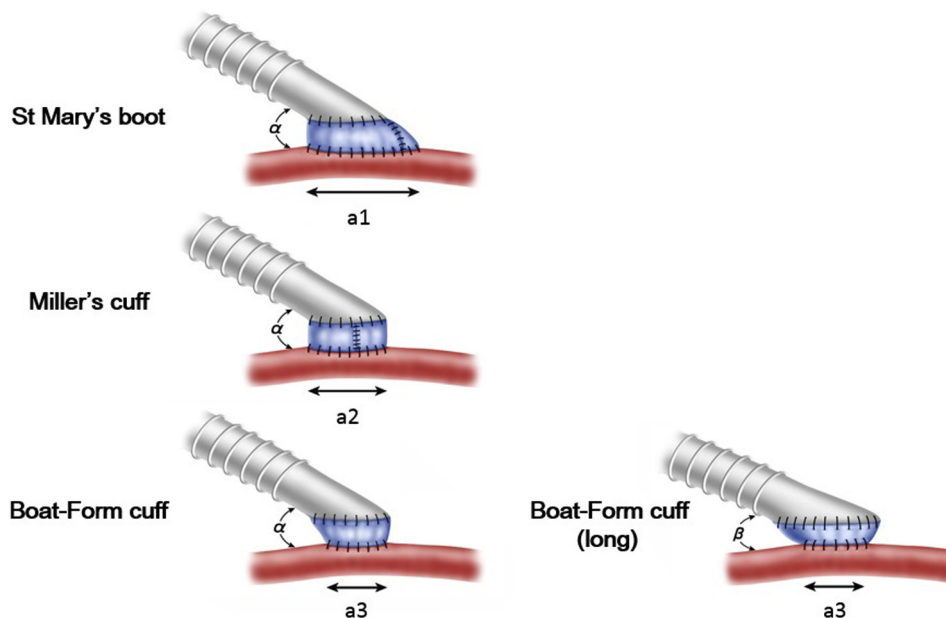


**Fig 2.** Three-dimensional computed tomography reconstruction from images acquired at the 5-year follow-up. Computed tomography data obtained at the 5-year follow-up revealed patency of the polytetrafluoroethylene graft, vein cuff anastomosis, and every branch of the left lower limb.

the suture line; the compliance of the prosthetic graft is lower than that of the vein graft, so flow reversal and the formation of vortices in overall wall shear stress patterns are more pronounced in prosthetic than in vein grafts.<sup>8</sup>

Miller developed a vein cuff technique that attempted to enable anastomosis of the prosthetic graft to a thickened atherosclerotic artery.<sup>3</sup> This involved an approach to reduce compliance mismatch and thus prevent intimal hyperplasia. A randomized study showed that the use of a prosthetic graft with a vein cuff resulted in improved outcomes of BK F-P bypass compared with a prosthetic graft alone.<sup>9</sup> Tyrrell and Wolfe<sup>4</sup> developed a new design of the St. Mary's boot, which provided a smoother hemodynamic transition with the aim of overcoming turbulent flow in the Miller cuff. However, a limitation of both the Miller and St. Mary's boot cuff is that the anastomotic size of the proximal vein cuff is antecedently determined by the size and length of the arteriotomy. Therefore, technical difficulties might be encountered in adjusting the anastomotic size and angle between the prosthetic graft and vein cuff during cuff creation (Fig 3).

The new technique presented here involves creating a vein cuff that is initiated with side-to-side anastomosis. We expect this simple suture to minimize bleeding compared with collar cuff anastomosis, which requires H-shaped sutures. Furthermore, leakage can be easily checked by the injection of fluid into the vein. The



**Fig 3.** A comparison of the types of vein cuff anastomosis.  $a1$ ,  $a2$ ,  $a3$ , Length of arteriotomy,  $\alpha$ ,  $\beta$ , Anastomosis angle. Length of arteriotomy differs in relation to the type of vein cuff creation in the anastomosis of same size and angle of prosthetic graft ( $a1 > a2 > a3$ ). Boat-form vein cuff requires shorter arteriotomy, and trimming of proximal cuff is adjustable to the change of size and angle of prosthetic graft ( $\alpha > \beta$ ).

most important benefit of this technique is that the vein cuff requires a shorter arteriotomy than other types of vein cuff, and trimming of the proximal cuff is adjustable to the change in size of the prosthetic graft or anastomotic angle. Furthermore, the boat-form vein cuff is more widely open than collar types of vein cuff, which may stick close because of the thick and small artery. Thus, this technique may be useful when the popliteal artery is smaller than usual or when the surgical field is deep and narrow.

## CONCLUSIONS

In this case, autologous vein graft was not suitable because of the presence of varicose veins. A similar situation is likely to be experienced in patients who have undergone coronary artery bypass surgery using bilateral saphenous veins. When use of a prosthetic graft for BK F-P bypass is inevitable, as in these situations, we suggest that our new technique will present an alternative option to previous vein cuff creation at the distal anastomosis. We are planning to evaluate the 5-year outcome of consecutive cases of this technique. In addition, further comparative studies about hemodynamics and flow visualization in various vein cuffs are required to assess the efficacy of our technique.

## REFERENCES

1. Dorigo W, Pulli R, Piffaretti G, Castelli P, Griselli F, Dorrucchi V, et al. Results from an Italian multicentric registry comparing heparin-bonded ePTFE graft and autologous saphenous vein in below-knee femoro-popliteal bypasses. *J Cardiovasc Surg (Torino)* 2012;53:187-94.
2. Uhl C, Grosch C, Hock C, Töpel I, Steinbauer M. Comparison of long-term outcomes of heparin bonded polytetrafluoroethylene and autologous vein below knee femoropopliteal bypasses in patients with critical limb ischemia. *Eur J Vasc Endovasc Surg* 2017;54:54203-11.
3. Siegman FA. Use of a venous cuff for graft anastomosis. *Surg Gynecol Obstet* 1979;148:930.
4. Tyrrell MR, Wolfe J. New prosthetic venous collar anastomotic technique: combining the best of other procedures. *Br Surg* 1991;78:1016-7.
5. Batson RC, Sotturrai VS, Craighead CC. Linton patch angioplasty: an adjunct to distal bypass with polytetrafluoroethylene grafts. *Ann Surg* 1984;199:684-93.
6. Lemson MS, Tordoir JH, Daemen MJ, Kitslaar PJ. Intimal hyperplasia in vascular grafts. *Eur J Vasc Endovasc Surg* 2000;19:336-50.
7. Madras P, Ward C, Johnson W, Singh P. Anastomotic hyperplasia. *Surgery* 1981;90:922-3.
8. Wang LC, Guo GX, Tu R, Hwang NH. Graft compliance and anastomotic flow patterns. *ASAIO Trans* 1990;36:90-4.
9. Stonebridge PA, Howlett R, Prescott R, Ruckley CV. Randomised trial comparing polytetrafluoroethylene graft patency with and without a Miller cuff. *Br J Surg* 1995;82:555-6.

Submitted Nov 12, 2019; accepted Feb 9, 2020.