

Case Report

Open Access

## Asymptomatic wide complex tachycardia: a case report

Siddharth Mukerji, Feras Aloka and Atul Khasnis\*

Address: Department of Internal Medicine, Michigan State University, East Lansing, Michigan, USA

Email: Siddharth Mukerji - mukerji@msu.edu; Feras Aloka - feras.aloka@hc.msu.edu; Atul Khasnis\* - khasatul@yahoo.com

\* Corresponding author

Published: 13 January 2009

Received: 13 October 2008

Cases Journal 2009, 2:47 doi:10.1186/1757-1626-2-47

Accepted: 13 January 2009

This article is available from: <http://www.casesjournal.com/content/2/1/47>

© 2009 Mukerji et al; licensee BioMed Central Ltd.

This is an Open Access article distributed under the terms of the Creative Commons Attribution License (<http://creativecommons.org/licenses/by/2.0>), which permits unrestricted use, distribution, and reproduction in any medium, provided the original work is properly cited.

### Abstract

Wide complex tachycardias are a commonly encountered entity in coronary care units, intensive care units and emergency departments. Though, these arrhythmias are potentially fatal, they need to be recognized first and treated appropriately. Associated physical signs are helpful in this. We present a case of a 54-year-old-female who recently underwent placement of an implantable cardioverter-defibrillator for cardiomyopathy and developed tachycardia.

### Case presentation

A 54-year-old female presented with shortness of breath (Class II-III NYHA) for one month. There was no associated chest pain, palpitations or dizziness. Her past history was significant for 3-vessel coronary artery bypass graft 10 years previously. Physical examination did not suggest any significant abnormalities. 2D-echocardiography revealed left ventricular ejection fraction of 28%. She underwent single chamber ICD placement for prevention of sudden cardiac death secondary to ischemic cardiomyopathy. The procedure was uneventful. The next day post-procedure, her telemetry strip showed this rhythm (Figure 1). Her vitals at that time were stable. What is the most likely diagnosis?

### Discussion

This is electrocardiographic (EKG) artifacts. (Table 1) EKG artifacts can be confused with ventricular tachycardia (VT) especially when of sufficient amplitude and duration. [1] This can lead to unnecessary investigations and at times, unindicated therapeutic interventions. Though the presence of a wide complex tachycardia (WCT) could alert one to the presence of VT, the absence of atrioventricular dissociation, fusion/capture beats, hemodynamic compro-

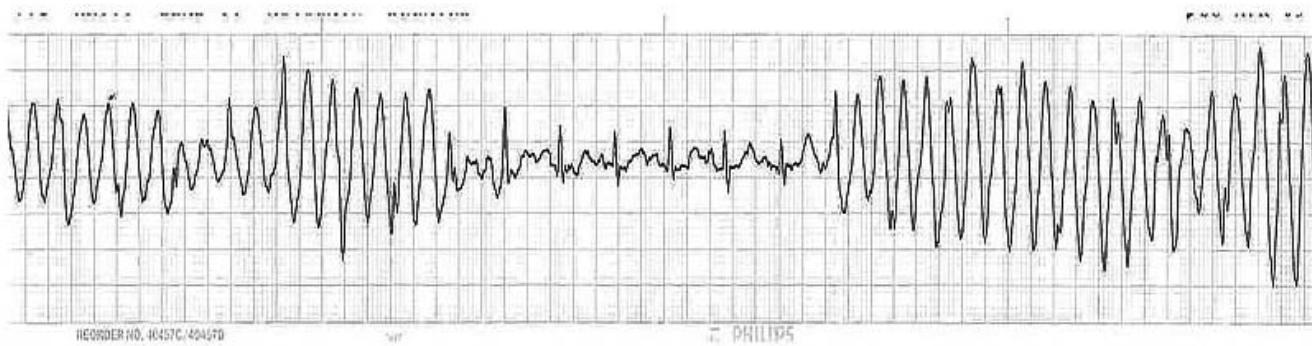
mise (in view of the heart rate) make this possibility less likely.

Characteristics in favor of EKG artifacts include:

- Normal hemodynamic parameters during the event
- Presence of normal QRS complexes (arrows in Figure 2)
- Unstable baseline on the EKG
- Associated body movements [2]

Krasnow et al showed that the most likely causes of EKG artifacts that mimic VT are body movements and a poor skin-electrode contact. [3]

In our patient, the ICD implantation was done a day prior to this event. Routine device interrogation post-implantation did not reveal any abnormal events. In addition, the patient was noticed to have voluntary movements in the form of "shaking her leg" and examination revealed normal hemodynamic parameters. Serum electrolytes were within normal limits too. Hence, the presence of an



**Figure 1**  
Initial telemetry strip showing "wide QRS complexes" with intervening sinus rhythm.

asymptomatic patient with a normally functioning ICD not firing should alert the physician to the possibility of artifacts rather than an abnormal rhythm.

No treatment is indicated for this condition. Therefore, in modern day medicine it is imperative to differentiate artifacts from VT, and thus reduce health costs.

Ventricular tachycardia accounts for 80% of WCT. [4,5] In such patients, a history of structural heart disease, particularly of coronary artery disease or prior myocardial infarction, strongly suggests a diagnosis of VT.

SVT with aberrancy accounts for a relatively small number of patients with WCT. This tachycardia typically originates in atrial tissue and/or AV junction and utilizes the normal atrioventricular (AV) conduction system for ventricular activation. Aberrance occurs when there is delay or block in the His-Purkinje system during antegrade conduction of impulses over the normal AV fascicles. Essentially, all types of SVT with aberrant conduction can present as a WCT. Atrial tachycardias, atrioventricular nodal reentrant tachycardias, orthodromic reciprocating tachycardias are some of the common SVTs which can be associated with aberrance. Termination of WCT by adenosine, digoxin, calcium-channel blockers, beta-blockers or vagal maneuvers is suggests SVT. Grubb, however, showed that VT too could be terminated with carotid sinus stimulation. [6]

In ventricular fibrillation multiple foci take over from the ventricles and produce a disorganized, chaotic rhythm. The patient is considered pulse-less, with no blood pressure, requiring immediate intervention. VF is secondary to coronary artery disease, myocardial ischemia, myocardial infarction, cardiomyopathy, cardiac trauma, drug toxicity, hypoxia, and electrolyte imbalance.

Preexcited tachycardias are conducted antegradely over an accessory pathway (AP). Evidence for the presence of an AP can be manifest of the surface electrocardiogram (EKG) which can show intermittent or continuous presence of a delta wave associated with a short PR interval. The delta wave represents the part of the ventricular myocardium that is depolarized through the AP.

**Conclusion**

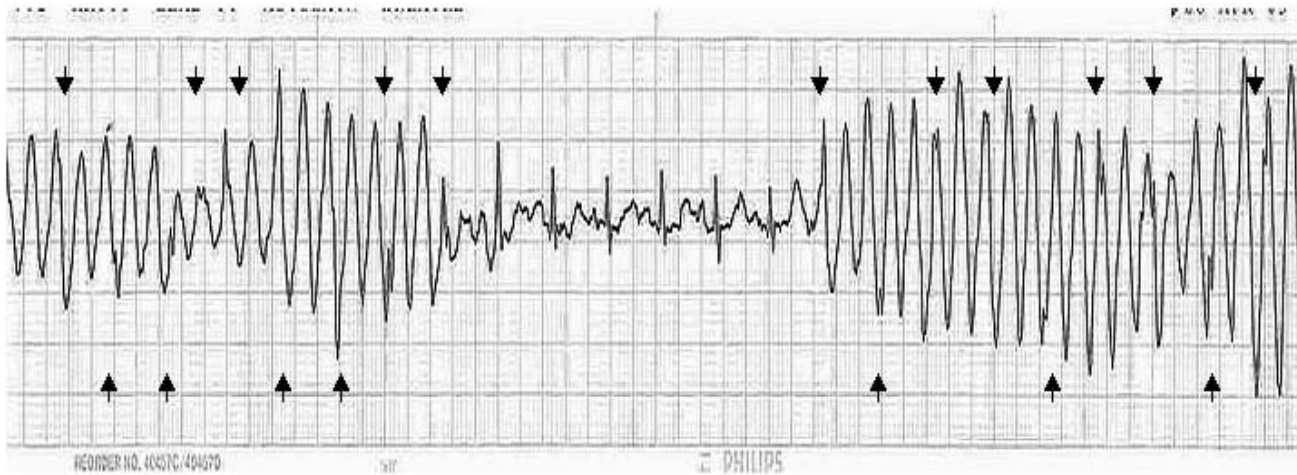
Thus, it is imperative for a clinician to recognize an EKG artifact and differentiate it from other causes of WCT. This would prevent unwarranted interventions and minimize unnecessary procedures.

**Consent**

Written informed consent was obtained from the patient for publication of this case report and accompanying images. A copy of the written consent is available for review by the Editor-in-Chief of this journal.

**Table 1: Selected differential diagnosis of wide complex tachycardia**

Condition	Characteristics
Ventricular tachycardia (VT)	Presence of AV dissociation with more ventricular than atrial events, QRS duration more than 140 ms, fusion beats, capture beats
Supraventricular tachycardia with aberrancy	QRS duration of not more than 140 ms [7]
EKG artifacts	Hemodynamically stable, normal QRS complexes, "precipitating" cause viz. movements
Pre-excitation tachycardia	Presence of "delta wave", short PR interval
Ventricular fibrillation	No apparent rate, fibrillatory waves, absent pulse, unrecordable BP



**Figure 2**  
True narrow QRS complexes amidst the "wide QRS rhythm".

### Competing interests

The authors declare that they have no competing interests.

### Authors' contributions

All authors contributed equally in collecting patient data, chart review, and editing medical images. All authors read and approved the final manuscript.

### References

1. Knight BP, Pelosi F, Michaud GF, Strickberger SA, Morady F: **Clinical Consequences of Electrocardiographic Artifact Mimicking Ventricular Tachycardia.** *N Engl J Med* 1999, **341**:1270-1274. Oct 21, 1999
2. Lin SL, Wang SP, Kong CW, Chang MS: **Artifact simulating ventricular and atrial arrhythmia.** *Jpn Heart J* 1991, **32**:847-851.
3. Krasnow AZ, Bloomfield DK: **Artifacts in portable electrocardiographic monitoring.** *Am Heart J* 1976, **91**:349-357.
4. Stewart RB, Bardy GH, Greene HL: **Wide complex tachycardia: misdiagnosed and outcome after emergency therapy.** *Ann Intern Med* 1986, **104**:766-771.
5. Steinman RT, Herra C, Scuger CD, et al.: **Wide complex tachycardia in the conscious adult: Ventricular tachycardia is the most common cause.** *JAMA* 1989, **261**:1013-1016.
6. Grubb BP: **Termination of ventricular tachycardia by carotid sinus stimulation.** *Int J Cardiol* 1989, **23**:397-399.
7. Drew B, Scheinman M: **ECG criteria to distinguish between aberrantly conducted supraventricular tachycardia and ventricular tachycardia.** *Pacing Clinical Electrophysiol* 1995, **18**:2194-2208.

Publish with **BioMed Central** and every scientist can read your work free of charge

"BioMed Central will be the most significant development for disseminating the results of biomedical research in our lifetime."

Sir Paul Nurse, Cancer Research UK

Your research papers will be:

- available free of charge to the entire biomedical community
- peer reviewed and published immediately upon acceptance
- cited in PubMed and archived on PubMed Central
- yours — you keep the copyright

Submit your manuscript here:  
[http://www.biomedcentral.com/info/publishing\\_adv.asp](http://www.biomedcentral.com/info/publishing_adv.asp)

