

Eosinophilic granuloma/Langerhans cell histiocytosis: Pediatric neurosurgery update

Sandi Lam, Gaddum D. Reddy, Rory Mayer, Yimo Lin, Andrew Jea

Department of Neurosurgery, Baylor College of Medicine, Texas Children's Hospital, Houston, TX 77030, USA

E-mail: *Sandi Lam - sklam@texaschildrens.org; Gaddum D. Reddy - gdreddy@bcm.edu; Rory Mayer - rrmayer@bcm.edu; Yimo Lin - yimolin@gmail.com; Andrew Jea - ahjea@texaschildrens.org

*Corresponding author

Received: 14 May 15 Accepted: 16 June 15 Published: 07 October 15

This article may be cited as:

Lam S, Reddy GD, Mayer R, Lin Y, Jea A. Eosinophilic granuloma/Langerhans cell histiocytosis: Pediatric neurosurgery update. *Surg Neurol Int* 2015;6:S435-9.
<http://surgicalneurologyint.com/Eosinophilic-granuloma/Langerhans-cell-histiocytosis:-Pediatric-neurosurgery-update/>

Copyright: © 2015 Lam S. This is an open-access article distributed under the terms of the Creative Commons Attribution License, which permits unrestricted use, distribution, and reproduction in any medium, provided the original author and source are credited.

Key Words: Eosinophilic granuloma, histiocytosis, Langerhans cell, lytic spine lesion, skull lesion

ILLUSTRATIVE CASES

Case 1

A 23-month-old female was admitted to the neurosurgery service with a 3-month history of a progressively enlarging neck mass. There was associated redness, swelling, and tenderness to palpation, but no neurological deficits on examination. A noncontrast computed tomography (CT) scan of the neck and magnetic resonance imaging (MRI) with contrast showed an osteolytic contrast-enhancing lesion primarily involving the C2 posterior elements, with a compressive circumferential epidural component extending from C2 to C5 [Figure 1]. A skeletal survey was negative for any other osseous lesions. She underwent C2 to C5 laminectomy with partial resection of the lesion without complication. Pathology was consistent with Langerhans cell (LC) histiocytosis (LCH). She was discharged home several days after her operation and subsequently started outpatient chemotherapy with cytarabine.

Case 2

A 17-year-old male was admitted to the neurosurgery service with a 6-week history of a progressively enlarging scalp mass. There were tenderness and intermittent bleeding from the ulcerated lesion, with no focal neurologic deficits on examination. A noncontrast CT scan of the head and MRI brain, with and without contrast, showed a large transosseous contrast-enhancing lesion of the right frontal bone [Figure 2]. CT venography

showed compression of the adjacent superior sagittal sinus. Surgery with gross total resection of the lesion was performed. Pathology was consistent with LCH. The patient was discharged home the day after his operation. He subsequently started outpatient chemotherapy with cytarabine.

REVIEW

Overview and nosology of Langerhans cell histiocytosis

LCH is a rare heterogeneous illness characterized by the proliferation of dendritic cells with LCH morphology. LCH refers to a spectrum of diseases, from a localized lesion to a diffuse multiorgan pathology.^[10,27,43] It can affect any organ system, but most commonly involves the skeletal system (80%). Other commonly affected sites include the skin (33%), pituitary gland (25%), liver, spleen, lungs, and brain.^[23] The most common named subtype, eosinophilic granuloma (EG), refers to a benign localized LCH, most commonly of the bone.^[43] Other named subtypes

Access this article online

Quick Response Code:



Website:

www.surgicalneurologyint.com

DOI:

10.4103/2152-7806.166761

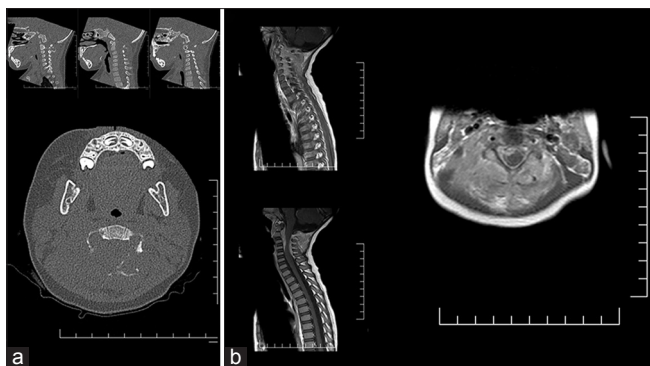


Figure 1: Images for the patient in case 1. (a) Computed tomography of the cervical spine without contrast. Sagittal (top) and axial (bottom) images. (b) Magnetic resonance imaging of the upper spine with contrast. Sagittal (left) and axial (right) images

include Hand–Schüller–Christian disease, a multifocal LCH classically characterized by exophthalmos, diabetes insipidus, and osteolytic skull lesions, and Letterer–Siwe disease, a diffuse systemic LCH clinically manifested by skin rash, hepatosplenomegaly, and pancytopenia with an acute fulminant course. A congenital self-limited form, named Hashimoto–Pritzker disease, has also been described.^[24,29] In 1953, Lichtenstein grouped all of these diseases under the name “histiocytosis X,” a term that has since been replaced by LCH.^[24,34]

Etiology and pathophysiology

As mentioned above, the proliferation of a myeloid-derived precursor dendritic cell with the characteristics of a LC is what characterizes LCH.^[11,19] One theory on the pathophysiology of LCH is based on recently published data that LCH cells express CD40 at high levels, leading to the overactivation of CD40L + T-lymphocytes. The subsequent release of cytokines leads to further recruitment of LC progenitor cells, as well as to the local destruction of bone, fibrosis, and necrosis.^[1,13,18]

The central debate on the pathogenesis of LCH is whether it is a reactive immune response or a neoplasm. Support for the neoplastic theory includes the monoclonality of the pathologic cells (though this also can be seen with reactive immune processes),^[1,49] the up-regulation of pro-cell proliferation and anti-apoptotic proteins (c-Myc, H-ras, Bcl-2) in LCH samples,^[47] the up-regulation of Ki-67 (a marker of proliferation),^[5,47] the finding of activated BRAF mutations in a majority of samples, and the clinical response of BRAF (V600E) disease to vemurafenib.^[4,22] Support for the theory that LCH represents a dysfunctional immune response includes data showing the up-regulation of genes that lead to T-cell activation and recruitment in LCH lesions,^[2] an increase of T-regulatory cells in the blood of LCH patients in comparison with controls,^[48] and a lack of evidence of gross genomic or karyotypic aberration in LCH biopsy samples.^[9] Of note, no antigenic trigger

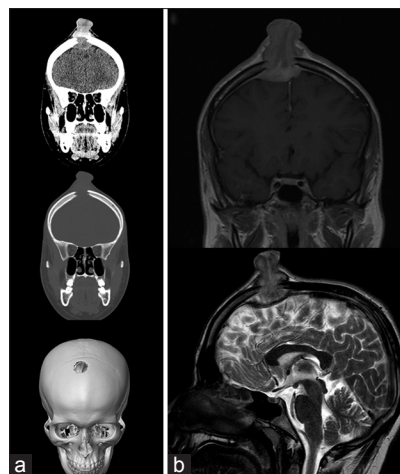


Figure 2: Images for the patient in case 2. (a) Computed tomography head without contrast. Coronal brain window (top), coronal bone window (middle), and three-dimensional skull reconstruction (bottom) images. (b) Magnetic resonance imaging brain. Coronal postcontrast T1-weighted image (top) and sagittal T2-weighted (bottom) images

has been identified, and evidence points against a viral etiology.^[26,36]

Epidemiology

EG that affects the bone is the most common subtype of LCH, representing an estimated 60–80% of cases. EG can be single or multifocal; it most commonly affects the calvarium, but can also present in the vertebrae, ribs, long bones, and mandible.^[12,29,37] EG primarily affects children under the age of 15, with an estimated incidence of <1 per 100,000.^[10,27]

Clinical presentation, workup, and diagnosis

Radiography demonstrates a sharply demarcated osteolytic lesion of the underlying bone.^[37,43] EG of the skull presents as a gradually enlarging scalp mass.^[43] EG of the vertebral body in children most commonly presents with pain. A neurologic deficit is uncommon even in cases of progression to vertebra plana.^[6,20] EG of the orbital bone may present as proptosis with an accompanying mass mimicking malignancy.^[15] EG may also occur intracranially, typically in the hypothalamic-pituitary axis with associated endocrinopathies.^[25] Radiographically, LCH lesions avidly enhance with contrast on both CT and MR and demonstrate increased uptake in fluorine-18-labeled fluorodeoxyglucose (FDG)-positron emission tomography (PET).^[33] They appear hypointense on T1-weighted MRI sequences and iso- to hyperintense on T2.^[10,21]

The differential for an osteolytic mass is broad and includes neoplastic processes such as metastatic lesions, primary bone tumors, including osteosarcoma or Ewing’s sarcoma, neuroblastoma, rhabdomyosarcoma, lymphoma and primitive neuroectodermal tumors. It also includes infections such as osteomyelitis or abscesses, fibrous

dysplasia, and cystic lesions such as aneurysmal bone cysts or dermoid cysts. Vascular processes, such as venous lakes, hemangiomas, and angiomatosis, are also in the differential, as well as developmental anomalies such as neurenteric cysts and encephaloceles. Tissue biopsy is necessary for definitive diagnosis. The classic radiographic presentation of vertebra plana (not shown in our more dramatic Case 1) is not considered pathognomonic of LCH, as complete vertebral collapse can be seen with other diagnoses such as Ewing's sarcoma and infection.

Histopathologically, LCH lesions show a proliferation of LC-type cells in a milieu of lymphocytes, macrophages, and eosinophils. In 1987, the Histiocyte Society established the diagnostic criteria for a diagnosis of LCH, which required the identification of CD1a on immunohistochemistry or Birbeck granules on electron microscopy.^[24] Immunohistochemistry for Langerin, a protein enriched in and necessary for the formation of Birbeck granules, is an acceptable modern alternative to electron microscopy.^[1,23] Recent work suggests Birbeck granules are part of the endosomal recycling system and may be involved with loading CD1a (a protein similar to major histocompatibility complex-I) with glycoprotein antigens for presentation to T-cells.^[35]

Workup should include a systemic survey to identify any other potential sites of involvement, as management recommendations and prognosis vary depending on the number and type of organs involved in LCH.^[17] The Euro Histi network published guidelines for the workup of LCH in 2013 based on the available review of the literature and recommends the following laboratory tests: Complete blood count with differential, complete metabolic panel (electrolytes, [blood urea nitrogen] BUN/creatinine and liver function tests), erythrocyte sedimentation rate, coagulation studies (prothrombin time/international normalization ratio, partial thromboplastin time, fibrinogen), chest X-ray, and radiographic skeletal survey.^[23] The Histiocyte Society recommends the same laboratory workup, with the addition of urine specific gravity and abdominal ultrasound.^[38] Endocrine labs (follicle-stimulating hormone/luteinizing hormone, thyroid stimulating hormone, growth hormone, cortisol) are indicated if there is any suspicion of pituitary involvement. MRI is useful for the detection of bone marrow or soft-tissue involvement, and a fast whole-body T2-STIR protocol is a possible screening test.^[30,44] PET has been shown to be superior to bone scans for lesion detection, but it exposes children to higher radiation doses.^[44] Mueller *et al.* found MRI had high sensitivity (81%), but FDG-PET had a higher specificity (76%) for the detection of LCH lesions.^[40]

Treatment

LCH of the spine is rare. Treatment patterns in the literature include observation, complete surgical excision

with fixation, and radiotherapy. Bertram *et al.* reviewed the literature of spine EG ($n = 53$) and found that most cases resolved without treatment. Immobilization and observation are recommended in cases without spinal instability or neurological deficit.^[6] Similar findings have been reported by Raab *et al.* ($n = 14$) and Yeom *et al.* ($n = 23$).^[46,50] LCH spares the endochondral plates; thus, recovery of vertebral heights is possible if the endochondral tissues are not disturbed with surgery or radiation.^[28,46] Surgical excision, followed by segmental fusion and internal fixation, is indicated in cases of spinal instability, a neurological deficit from compression of the spinal cord or spinal nerves, or marked noncompliance with immobilization/external bracing.^[28] Radiotherapy is no longer recommended for spine LCH, except in emergent cases of spinal cord compression.^[1,23]

Solitary EG of the calvarial vault without invasion into neurological structures has a favorable prognosis. These lesions typically are managed with surgical curettage or excision.^[11,23,28] Small case series reported by Oliveira *et al.* ($n = 4$) and by De Angulo *et al.* ($n = 8$) found that these lesions fully resolved without intervention after 6–19 months;^[11,42] however, a major limitation of these reports is the lack of diagnostic certainty in the absence of tissue analysis. There is no Class I evidence for the management of these lesions, and treatment decisions typically are made on a case-by-case basis. On one hand, overly aggressive surgical excision may be associated with prolonged healing and deformity, particularly with large lesions. For this reason, the European Histiocyte Society recommends avoidance of surgical excision in lesions >5 cm in children.^[23] On the other hand, observation alone also carries risk, since the differential diagnosis of LCH includes aggressive cancers and infection and the disease may progress to pathologic fracture or encroachment on neurological structures.^[3] One option is to perform a biopsy or partial resection for definitive diagnosis, followed by observation or a conservative treatment option, such as an intralésional injection of steroids or interferon, or systemic treatments with indomethacin or bisphosphonates. These treatments have been shown to be efficacious in the literature;^[14,16,41] however, the results must be interpreted in the context of a disease that potentially is self-resolving.

The Histiocyte Society recommends more aggressive treatment in cases of multifocal bone disease or disease that involves “CNS-risk” sites (odontoid, vertebrae with intraspinal soft-tissue extension, facial bones, skull base, orbit, oral cavity).^[1,38] In these types of LCH, the risk of recurrence is high (30–50%), as is the risk of invasion into neurological tissue or development of neurologic sequelae (40%) such as endocrinopathies, diabetes insipidus, and parenchymal brain disease.^[38] For LCH of this type, the Histiocyte Society recommends systemic treatment with prednisone and vinblastine for

12 months.^[38] Recent studies, however, have shown less toxicity and lower recurrence rates in patients treated with cytarabine.^[8] There is no Class I evidence or guidelines regarding surgical treatment for these lesions. Historically, lesions that invade the dura or compress neurological tissues and are located in accessible sites have undergone surgical excision.^[7,29,31] In cases where surgical excision would be impossible or excessively morbid, systemic chemotherapy and/or injections of steroids or interferon may be a preferential alternative.^[3] In the past, radiation therapy was used as an adjunctive treatment; however, it is no longer recommended due to concerns over the possible long-term effects of radiotherapy on the developing brain and spine.^[1,23]

Prognosis

In a large study from South Korea ($n = 603$), 5-year overall survival was 99.8% in those with single-system LCH, 98.4% for multisystem LCH without risk organ involvement, and 77% for multisystem LCH with risk organ involvement.^[32] Similar findings have been found by other groups in Japan ($n = 91$) and Italy ($n = 121$).^[39,45] In a large study from the Mayo Clinic ($n = 263$), recurrence rates in those with single-bone LCH was 7%, and the appearance of new bone lesions was 14%.^[31] As mentioned above, the Histiocyte Society reports a high rate of recurrence (30–50%) among those with “CNS-risk” lesions.^[38]

CONCLUSION

LCH describes a heterogeneous mixture of pathologies and should be on the differential for any osteolytic soft-tissue mass. Definitive diagnosis requires tissue biopsy, and treatment options vary from observation to resection and chemotherapy. Prognosis is good, and recurrence rates are low, particularly for patients with single bone lesions.

REFERENCES

1. Abła O, Egeler RM, Weitzman S. Langerhans cell histiocytosis: Current concepts and treatments. *Cancer Treat Rev* 2010;36:354-9.
2. Allen CE, Li L, Peters TL, Leung HC, Yu A, Man TK et al. Cell-specific gene expression in Langerhans cell histiocytosis lesions reveals a distinct profile compared to epidermal Langerhans cells. *J Immunol* 2010;184:4557-67.
3. Azouz EM, Saigal G, Rodriguez MM, Podda A. Langerhans' cell histiocytosis: Pathology, imaging and treatment of skeletal involvement. *Pediatr Radiol* 2005;35:103-15.
4. Badalian-Very G, Vergilio JA, Degar BA, MacConaill LE, Brandner B, Calicchio ML, et al. Recurrent BRAF mutations in Langerhans cell histiocytosis. *Blood* 2010;116:1919-23.
5. Bank MI, Rengtved P, Carstensen H, Petersen BL. Langerhans cell histiocytosis: An evaluation of histopathological parameters, demonstration of proliferation by Ki-67 and mitotic bodies. *APMIS* 2003;111:300-8.
6. Bertram C, Madert J, Eggers C. Eosinophilic granuloma of the cervical spine. *Spine (Phila Pa 1976)* 2002;27:1408-13.
7. Binning MJ, Brockmeyer DL. Novel multidisciplinary approach for treatment of Langerhans cell histiocytosis of the skull base. *Skull Base* 2008;18:53-8.

8. Cantu MA, Lupo PJ, Bilgi M, Hicks MJ, Allen CE, McClain KL. Optimal therapy for adults with Langerhans cell histiocytosis bone lesions. *PLoS One* 2012;7:e43257.
9. da Costa CE, Szuhai K, van Eijk R, Hoogeboom M, Sciort R, Mertens F, et al. No genomic aberrations in Langerhans cell histiocytosis as assessed by diverse molecular technologies. *Genes Chromosomes Cancer* 2009;48:239-49.
10. D'Ambrosio N, Soohoo S, Warshall C, Johnson A, Karimi S. Craniofacial and intracranial manifestations of Langerhans cell histiocytosis: Report of findings in 100 patients. *AJR Am J Roentgenol* 2008;191:589-97.
11. De Angulo G, Nair S, Lee V, Khatib Z, Ragheb J, Sandberg DI. Nonoperative management of solitary eosinophilic granulomas of the calvaria. *J Neurosurg Pediatr* 2013;12:1-5.
12. Denaro L, Longo UG, Papalia R, Di Martino A, Maffulli N, Denaro V. Eosinophilic granuloma of the pediatric cervical spine. *Spine (Phila Pa 1976)* 2008;33:E936-41.
13. Egeler RM, Favara BE, van Meurs M, Laman JD, Claassen E. Differential *in situ* cytokine profiles of Langerhans-like cells and T cells in Langerhans cell histiocytosis: Abundant expression of cytokines relevant to disease and treatment. *Blood* 1999;94:4195-201.
14. Egeler RM, Thompson RC Jr, Voûte PA, Nesbit ME Jr. Intralesional infiltration of corticosteroids in localized Langerhans' cell histiocytosis. *J Pediatr Orthop* 1992;12:811-4.
15. Erly WK, Carmody RF, Dryden RM. Orbital histiocytosis X. *AJNR Am J Neuroradiol* 1995;16:1258-61.
16. Farran RP, Zaretski E, Egeler RM. Treatment of Langerhans cell histiocytosis with pamidronate. *J Pediatr Hematol Oncol* 2001;23:54-6.
17. Gardner H, Minkov M, Grois N, Pötschger U, Thiem E, Aricò M, et al. Therapy prolongation improves outcome in multisystem Langerhans cell histiocytosis. *Blood* 2013;121:5006-14.
18. Geissmann F, Lepelletier Y, Freitag S, Valladeau J, Bodemer C, Debré M, et al. Differentiation of Langerhans cells in Langerhans cell histiocytosis. *Blood* 2001;97:1241-8.
19. Geissmann F. Histiocytosis and the Mononuclear Phagocyte System. Proceedings of the 24th Annual Meeting of the Histiocyte Society, October 1-3, Berlin, Germany; 2008.
20. Greenlee JD, Fenoy AJ, Donovan KA, Menezes AH. Eosinophilic granuloma in the pediatric spine. *Pediatr Neurosurg* 2007;43:285-92.
21. Gunny R, Clifton A, Al-Memar A. Spontaneous regression of supratentorial intracerebral Langerhans' cell histiocytosis. *Br J Radiol* 2004;77:685-7.
22. Haroche J, Cohen-Aubart F, Emile JF, Arnaud L, Maksud P, Charlotte F, et al. Dramatic efficacy of vemurafenib in both multisystemic and refractory Erdheim-Chester disease and Langerhans cell histiocytosis harboring the BRAFV600E mutation. *Blood* 2013;121:1495-500.
23. Haupt R, Minkov M, Astigarraga I, Schäfer E, Nanduri V, Jubran R, et al. Langerhans cell histiocytosis (LCH): Guidelines for diagnosis, clinical work-up, and treatment for patients till the age of 18 years. *Pediatr Blood Cancer* 2013;60:175-84.
24. Histiocytosis syndromes in children. Writing Group of the Histiocyte Society. *Lancet* 1987;1:208-9.
25. Howarth DM, Gilchrist GS, Mullan BP, Wiseman GA, Edmonson JH, Schomberg PJ. Langerhans cell histiocytosis: Diagnosis, natural history, management, and outcome. *Cancer* 1999;85:2278-90.
26. Jeziorski E, Senechal B, Molina TJ, Deveze F, Lueruez-Ville M, Morand P, et al. Herpes-virus infection in patients with Langerhans cell histiocytosis: A case-controlled sero-epidemiological study, and *in situ* analysis. *PLoS One* 2008;3:e3262.
27. Jubran RF, Marcheliani A, Dorey F, Malogolowkin M. Predictors of outcome in children with Langerhans cell histiocytosis. *Pediatr Blood Cancer* 2005;45:37-42.
28. Karagoz Guzey F, Bas NS, Emel E, Alatas I, Kebudi R. Polyostotic monosystemic calvarial and spinal Langerhans' cell histiocytosis treated by surgery and chemotherapy. *Pediatr Neurosurg* 2003;38:206-11.
29. Kasper EM, Aguirre-Padilla DH, Alter RY, Anderson M. Histiocytosis X: Characteristics, behavior, and treatments as illustrated in a case series. *Surg Neurol Int* 2011;2:57.
30. Kellenberger CJ, Epelman M, Miller SF, Babyn PS. Fast STIR whole-body MR imaging in children. *Radiographics* 2004;24:1317-30.
31. Kilpatrick SE, Wenger DE, Gilchrist GS, Shives TC, Wollan PC, Unni KK.

- Langerhans' cell histiocytosis (histiocytosis X) of bone. A clinicopathologic analysis of 263 pediatric and adult cases. *Cancer* 1995;76:2471-84.
32. Kim BE, Koh KN, Suh JK, Im HJ, Song JS, Lee JW, et al. Clinical features and treatment outcomes of Langerhans cell histiocytosis: A nationwide survey from Korea histiocytosis working party. *J Pediatr Hematol Oncol* 2014;36:125-33.
 33. Lee HJ, Ahn BC, Lee SW, Lee J. The usefulness of F-18 fluorodeoxyglucose positron emission tomography/computed tomography in patients with Langerhans cell histiocytosis. *Ann Nucl Med* 2012;26:730-7.
 34. Lichtenstein L. Histiocytosis X; integration of eosinophilic granuloma of bone, Letterer-Siwe disease, and Schüller-Christian disease as related manifestations of a single nosologic entity. *AMA Arch Pathol* 1953;56:84-102.
 35. Mc Dermott R, Ziylan U, Spehner D, Bausinger H, Lipsker D, Mommaas M, et al. Birbeck granules are subdomains of endosomal recycling compartment in human epidermal Langerhans cells, which form where Langerin accumulates. *Mol Biol Cell* 2002;13:317-35.
 36. McClain K, Jin H, Gresik V, Favara B. Langerhans cell histiocytosis: Lack of a viral etiology. *Am J Hematol* 1994;47:16-20.
 37. Meyer JS, De Camargo B. The role of radiology in the diagnosis and follow-up of Langerhans cell histiocytosis. *Hematol Oncol Clin North Am* 1998;12:307-26.
 38. Minkov M, Grois N, McClain K, Nanduri V, Rodriguez-Galindo C, Simonitsch-Klupp I, et al. Langerhans Cell Histiocytosis: Histiocyte Society Evaluation and Treatment Guidelines; 2009. Available from: <http://www.histiocytesociety.org/document.doc?id=290>. [Last accessed on 2015 Apr 01].
 39. Morimoto A, Ikushima S, Kinugawa N, Ishii E, Kohdera U, Sako M, et al. Improved outcome in the treatment of pediatric multifocal Langerhans cell histiocytosis: Results from the Japan Langerhans Cell Histiocytosis Study Group-96 protocol study. *Cancer* 2006;107:613-9.
 40. Mueller WP, Melzer HI, Schmid I, Coppenrath E, Bartenstein P, Pfluger T. The diagnostic value of 18F-FDG PET and MRI in paediatric histiocytosis. *Eur J Nucl Med Mol Imaging* 2013;40:356-63.
 41. Munn SE, Olliver L, Broadbent V, Pritchard J. Use of indomethacin in Langerhans cell histiocytosis. *Med Pediatr Oncol* 1999;32:247-9.
 42. Oliveira M, Steinbok P, Wu J, Heran N, Cochrane D. Spontaneous resolution of calvarial eosinophilic granuloma in children. *Pediatr Neurosurg* 2003;38:247-52.
 43. Park SH, Park J, Hwang JH, Hwang SK, Hamm IS, Park YM. Eosinophilic granuloma of the skull: A retrospective analysis. *Pediatr Neurosurg* 2007;43:97-101.
 44. Phillips M, Allen C, Gerson P, McClain K. Comparison of FDG-PET scans to conventional radiography and bone scans in management of Langerhans cell histiocytosis. *Pediatr Blood Cancer* 2009;52:97-101.
 45. Postini AM, Andreatchio A, Boffano M, Pagano M, Brach Del Prever A, Fagioli F. Langerhans cell histiocytosis of bone in children: A long-term retrospective study. *J Pediatr Orthop B* 2012;21:457-62.
 46. Raab P, Hohmann F, Kühl J, Krauspe R. Vertebral remodeling in eosinophilic granuloma of the spine. A long-term follow-up. *Spine (Phila Pa 1976)* 1998;23:1351-4.
 47. Schouten B, Egeler RM, Leenen PJ, Taminiau AH, van den Broek LJ, Hogendoorn PC. Expression of cell cycle-related gene products in Langerhans cell histiocytosis. *J Pediatr Hematol Oncol* 2002;24:727-32.
 48. Senechal B, Elain G, Jeziorski E, Grondin V, Patey-Mariaud de Serre N, Jaubert F, et al. Expansion of regulatory T cells in patients with Langerhans cell histiocytosis. *PLoS Med* 2007;4:e253.
 49. Willman CL, Busque L, Griffith BB, Favara BE, McClain KL, Duncan MH, et al. Langerhans'-cell histiocytosis (histiocytosis X) – A clonal proliferative disease. *N Engl J Med* 1994;331:154-60.
 50. Yeom JS, Lee CK, Shin HY, Lee CS, Han CS, Chang H. Langerhans' cell histiocytosis of the spine. Analysis of twenty-three cases. *Spine (Phila Pa 1976)* 1999;24:1740-9.