



Review Article

Ventricular septal pacing: Optimum method to position the lead

Asit Das^{a,*}, Dhiman Kahali^b^a Department of Cardiology, IPGME&R and SSKM Hospital, Kolkata, India^b B. M. Birla Heart Research Centre, Kolkata, India

ARTICLE INFO

Article history:

Received 24 May 2017

Accepted 10 January 2018

Available online 11 January 2018

ABSTRACT

Adverse hemodynamics of right ventricular (RV) pacing is known for years. Several studies have revealed that adverse outcomes of RV apical pacing are directly linked to cumulative percentage of ventricular pacing. Algorithms to minimize ventricular pacing are only effective if there is good atrioventricular (AV) conduction. A need for an alternate site for ventricular pacing is evident in patients with high presumed ventricular pacing burden. Most studied alternate site for ventricular pacing is ventricular septum (outflow tract septum and mid-septum). Conventionally septal position of the ventricular pacing lead is confirmed by fluoroscopic appearance of the lead and characteristics electrocardiographic (ECG) features. However, several recent studies have challenged these fluoroscopic and ECG features as to be inadequate. So, there is need for a systematic approach for septal positioning of the ventricular lead.

© 2018 Published by Elsevier B.V. on behalf of Cardiological Society of India. This is an open access article under the CC BY-NC-ND license (<http://creativecommons.org/licenses/by-nc-nd/4.0/>).

1. Introduction

Pacing from the right ventricular (RV) apex induces a differential muscle strain and fiber shortening resulting from an abnormal late activation of the lateral wall of the left ventricle (LV) which in turn increases myocardial work and oxygen consumption. This changes in cardiac hemodynamics cause left ventricular (LV) cellular abnormalities (both at a gross and ultrastructural level) may lead to ventricular remodeling which is associated with a higher risk of development of LV systolic dysfunction, heart failure, and atrial fibrillation.¹ Retrospective analysis of the Mode Selection Trial (MOST) suggests that the risks of heart failure hospitalization and atrial fibrillation can be directly linked to RV pacing burden (cumulative percent ventricular pacing) regardless of pacing mode.² Although pacemaker manufacturers have developed several successful pacing algorithms designed to minimize unnecessary ventricular pacing, it nevertheless frequently cannot be avoided in pacemaker-dependent patients. So, in patients with high presumed ventricular pacing burden (when ventricular pacing cannot be avoided and/or abnormal ventricular conduction is already present) pacing at alternate ventricular site(s) to attenuate the adverse effects imposed by ventricular desynchronization should be employed. Direct His bundle pacing or Para-Hisian pacing is supposed to be the most physiological pacing site

for patients with atrio-ventricular nodal disease or intra-His bundle disease which is technically difficult.³ The most studied right ventricular alternate site for pacing is ventricular septum (mid-septum or out-flow tract septum). However, achieving “true” ventricular septal pacing is critical for its beneficial effect.

2. RV anatomy

Anatomically, the RV has three main regions: the smooth outflow tract, the rough inflow tract, and the apex. The inlet and outlet components of the right ventricle are separated in the roof of the ventricle by the prominent thick, muscular supraventricular crest (crista supraventricularis). The posterolateral aspect of the crest provides a principal attachment for the anterosuperior cusp of the tricuspid valve. The septal limb of the crest may be continuous with, or embraced by, the septal limbs of the septomarginal trabecula. The septomarginal trabecula or septal band reinforces the septal surface where, at the base, it divides into limbs that embrace the supraventricular crest. Towards the apex, it supports the anterior papillary muscle of the tricuspid valve and, from this point, crosses to the parietal wall of the ventricle as the “moderator band”. A further series of prominent trabeculae, the septoparietal trabeculations, extend from its anterior surface and run onto the parietal ventricular wall (Fig. 1). Below the level of the supraventricular crest (crista supraventricularis) lies the inferior portion of the septum, which, to the left of the septomarginal trabeculation, is a cul-de-sac filled with the septoparietal trabeculations and is ideal for pacing lead attachment as it is

* Corresponding author at: Flat - B1, GB - 43, Narayantala (west), DB Nagar, Kolkata 700059, India.

E-mail address: dradascard@rediffmail.com (A. Das).

truly septal.^{4–6} The RV inflow tract (which corresponds to the mid part of the RV) is bordered posteriorly and to the left by the mid interventricular septum and anteriorly and to the right by the mid part of the RV free wall. The RV apex is the region where all the walls converge and is adjacent to the left ventricular apex. The anterior segment of the RV outflow tract (RVOT), particularly the junction with the septum, where the anterior descending coronary artery lies, is a transition zone.

3. Clinical studies with RV septal pacing

Studies comparing RV septal with RV apical pacing have been available for more than two decades. Both acute and chronic human studies had been undertaken utilizing a variety of alternate RV sites as well as patients with or without atrial fibrillation and LV dysfunction.^{7–13} Despite theoretical superiority of RV septal pacing over apical pacing, the study results are heterogeneous. Moreno and colleagues in a double-blind prospective randomized study have shown that after 1-year follow-up in persistently pacemaker-dependent patients, with no clinical evidence of severe congestive heart failure, midseptal ventricular lead placement is superior to the apical location. They observed significant improvements in both clinical (6-min walk) and functional parameters (LV ejection fraction).¹⁴ However, there is no robust study confirming septal pacing to be superior to apical pacing in preventing pacing induced LV dysfunction. A recent multicenter study searched for optimal pacing site in children and found that LV apex/LV lateral wall pacing had the greatest potential to prevent pacing-induced

reduction of cardiac pump function, whereas RVOT/lateral RV wall pacing was associated with a high risk of LV dysfunction and RV apical pacing was well tolerated in the majority, although it is associated with a mild decrease in LV ejection fraction in approximately one half of the patients.¹⁵ Several other studies failed to prove the superiority of the RV septal pacing over the apical pacing and this could be due to lack of true septal positioning.^{16–20} So, we need more definitive, long term follow up with conclusive evidence to suggest superiority of RV septal pacing over apical pacing. One recent meta-analysis of randomized-controlled trials has been suggested that the term “RV septal pacing be replaced by the broader, ‘RV nonapical pacing’”.²¹ Even then, the detrimental effects of long-term RV apical pacing are significant enough to suggest that it is high time to adopt RV ‘nonapical’ pacing.

4. Lead placement on the RV septum

A pacing lead implanted via the superior vena cava traverses the tricuspid valve and with a simple curved stylet will pass superiorly towards the pulmonary valve. Unless the tip of the lead is arching posterior at the time of screw deployment, the lead tip will more likely become attached to the anterior or free wall. In order to consistently position a lead on the septal aspect, the prepared stylet requires posterior angulation.

Mond has developed a specially shaped stylet (Mond’s stylet) for easier implantation of the lead into the inter-ventricular septum.²² Mond’s stylet has firstly, a generous curve in the distal

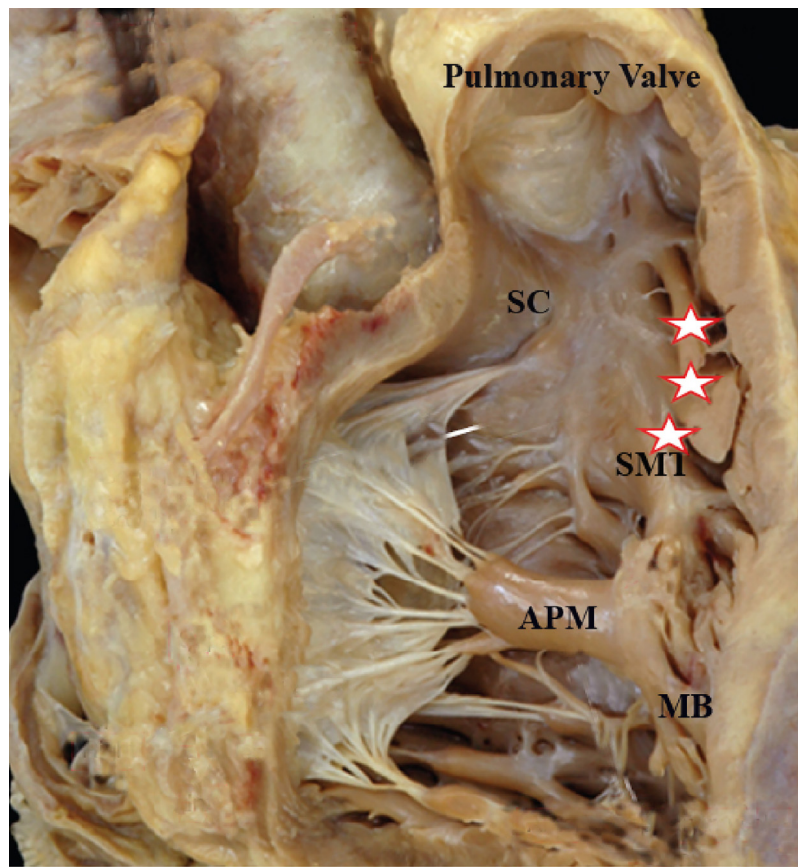


Fig. 1. Illustration of the heart highlighting the RV septal anatomy. The right ventricle has been opened from the front with the heart orientated anatomically. The RVOT is bordered by the pulmonary valve above and the superior aspect of the tricuspid apparatus below. The upper part of the septal wall is the conus arteriosus, bordered below by the supraventricular crest. To the anatomical left of the septomarginal trabeculation, this continues into the moderator band. The septoparietal trabeculations are shown with stars (Target site for septal lead position). SC = Supraventricular crest, SMT = Septomarginal trabeculation, APM = Anterior papillary muscle of Tricuspid valve, MB = Moderator band.

5–6 cm of stylet (primary curve). Then the terminal 2 cm is bent with 90° angle to primary curve to create a swan neck shape (secondary curve) (Fig. 2A). Mond's stylet is available commercially. He has described ECG features, radiological appearances, and implantation techniques of ventricular septal pacing in several studies.²³ Burri et al have studied the high success rate of a 3D stylet for mid septal attachment of the ventricular pacing lead.²⁴ They have reported a success rate of 89% in achieving a septal position of the RV lead. They first gave a smooth large curve in a single plane over the distal 20 cm with the barrel of a 10 cc syringe followed by an additional posterior 90° curve in the distal most 3 cm with the help of a 2cc syringe (Fig. 2B). This shape seems to be the larger version of Mond's stylet. Recently, Srivatsa has suggested another alternative technique of septal pacing which involves modification of Mond's stylet with more acute primary curve and less acute secondary curve and right ventriculogram in RAO projection with Swan-Ganz catheter during lead positioning (Fig. 2C).²⁵ But, this technique requires additional instrumentation. However, in none of these studies so called "RV septal" location of the pacing lead was confirmed with additional imaging technique (i.e., Computed tomography angiography or 3-dimensional echocardiography). Osmanick used a stylet with generous curve in distal 5–6 cm with a slight posterior bent on the distal most 2 cm to reach the RV septum (Fig. 2D).²⁶ However, the described stylet shapes again is another modification of Mond's stylet.

5. Fluoroscopic approach

Fluoroscopic postero-anterior (PA) view is the initial view to work with and best for guiding the lead into the RVOT and mid-RV. Differentiation between the septal, anterior, and free wall aspects of the RV can be best defined by the left anterior oblique (LAO) view. Interventricular septum is an oblique structure and is situated posteriorly. So, in LAO view the septal lead points towards the spine, while the free wall positioning is associated with anteriorly facing lead tip and upward facing lead indicates anterior wall placement of the lead (Fig. 3).

Mond et al suggested left lateral (LL) view as the specific view (100% specific) for confirmation of the septal location of the RV lead.²¹ A posterior projection of the lead tip indicates septal

placement, whereas a lead on the free wall passes anteriorly toward the sternum. Chen et al also have emphasized the importance of fluoroscopic LL view.²⁷ Using post-implant trans-thoracic echocardiogram as confirmatory imaging modality they have shown conventional fluoroscopic LAO angulation has only 68% specificity whereas LL has specificity of 83% in predicting septal location of the RV pacing lead.

However, achieving routine LL view during pacemaker implantation is not always possible because of sterility reason. But, upto 40° LAO view can easily be performed during lead implantation without compromising the sterile field. In another study, Mond indicated that lead tip angulation (between horizontal plane and the axis of the distal part of the lead) between 0 and 60° in 40° LAO view is highly suggestive of septal attachment of the lead.²⁸ Angulation of 80 to 100° suggests anterior wall location and 120 to 140° indicates free wall location of the RV lead. Sixty to eighty degree suggests transition zone between septal and anterior wall location. Hundred to hundred and twenty degree is the transition between anterior and free wall location of the RV lead (Fig. 4).

Recently, several studies have indicated the inadequacy of the LAO view alone in predicting septal location of the RV lead.^{21,26,29} In 50 patients, Margulescu et al have studied RV lead positions using fluoroscopic 40° LAO projection to differentiate between septal and free wall and fluoroscopic RAO 40° view to define the lead position in RVOT, mid-ventricular or RV apex.²¹ The exact anatomic position of the RV lead was documented using 3-dimensional *trans*-thoracic echocardiography. The result of this study indicates that current fluoroscopic and ECG criteria are only moderately accurate in discriminating between RV septal and free wall pacing sites and may not be adequate techniques for correct documentation of RV pacing lead position for routine clinical practice or research purposes. Similarly, Sharma and his co-workers also have shown the inadequacy of fluoroscopic criteria in LAO view for septal lead location using contrast enhanced cardiac computed tomographic (CT) as confirmatory diagnostic test.²⁹ However, in both these 2 studies septal lead location was defined by any angulation of the lead tip posteriorly towards the spine in LAO view. One can argue that lead tip angulation of more than 60° in 40° LAO view may not really indicate septal position. But, then again Osmanick et al used fluoroscopic 40° LAO view criteria

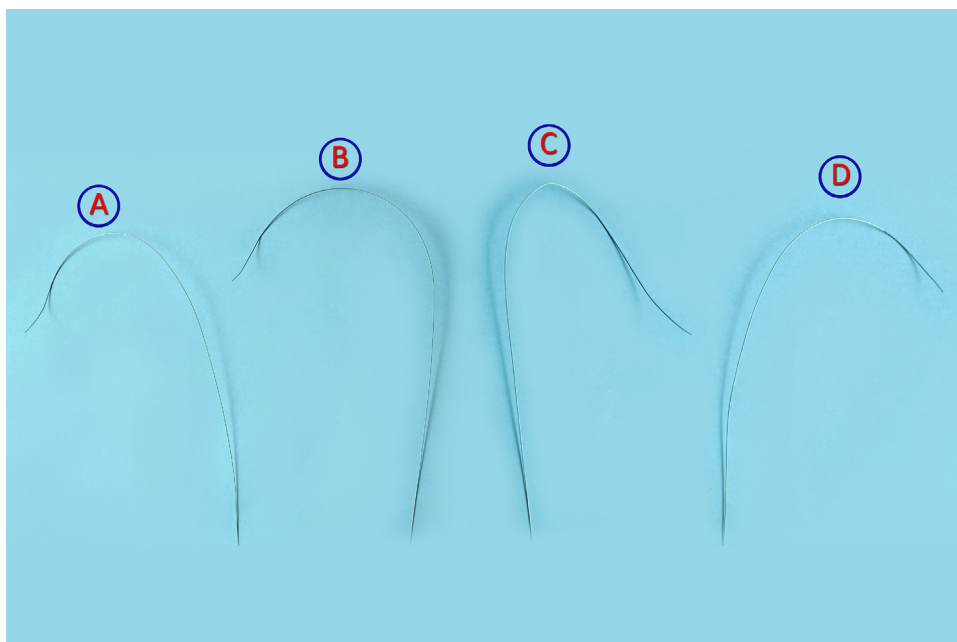


Fig. 2. A. Mond's stylet, B; Burri's 3D stylet, C. Srivatsa's stylet, D. Osmanick's stylet.

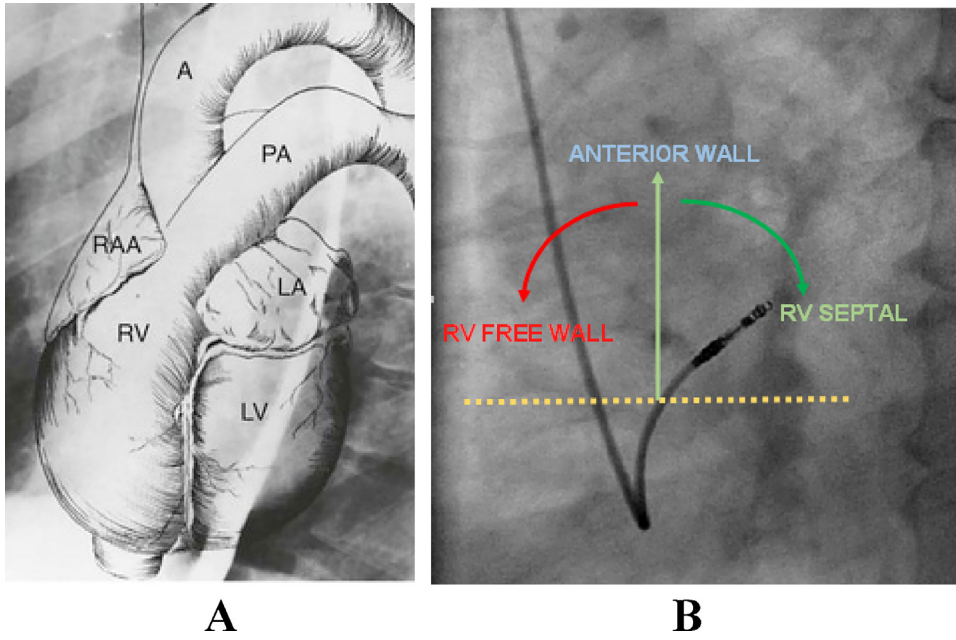


Fig. 3. A. Anatomy of different cardiac chambers in Left Anterior Oblique view. Note the orientation of inter-ventricular septum, B. Fluoroscopic 40° Left Anterior Oblique view showing different lead tip angulations and different zones of right ventricle.

(typical shape with lead tip facing toward the spine with angle between the horizontal plane and the lead between 0° and 60°) for septal location of the lead and confirmed the position with contrast enhanced cardiac CT scan and have shown that LAO view alone still remain inadequate in predicting the lead location in RV septum.²⁶ They have suggested some fluoroscopic RAO view criteria. They have divided the cardiac shadow in the RAO 30° view into 4 quadrants perpendicular to the cardiac silhouette at the spot, where the tip of the lead was anchored. 2nd and 3rd quadrant locations are suggestive of mid septal location.

Protect Pace and Optimize RV studies used 10° RAO view in predicting septal location of the RV lead tip.³⁰ Burri et al used 30°

RAO fluoroscopic view for this purpose and used same 9 quadrant model for septal location of the RV lead.²⁴ In the RAO view, the cardiac silhouette is divided into thirds from the external border of the heart to the spinal column using an imaginary grid, which results in 9 squares. The target position of the lead tip is the central sector (i.e. centre of the cardiac silhouette) for mid septal location. The middle square in the top row indicates the probable lead location at RVOT septum and the outermost square in the bottom row indicates lead position at the RV apex (Fig. 5). Rosso et al have shown that there is no significant difference between septal pacing from RVOT and mid-RV level in respect to acute lead performance or paced QRS duration.³¹ Moore et al compared right ventricular

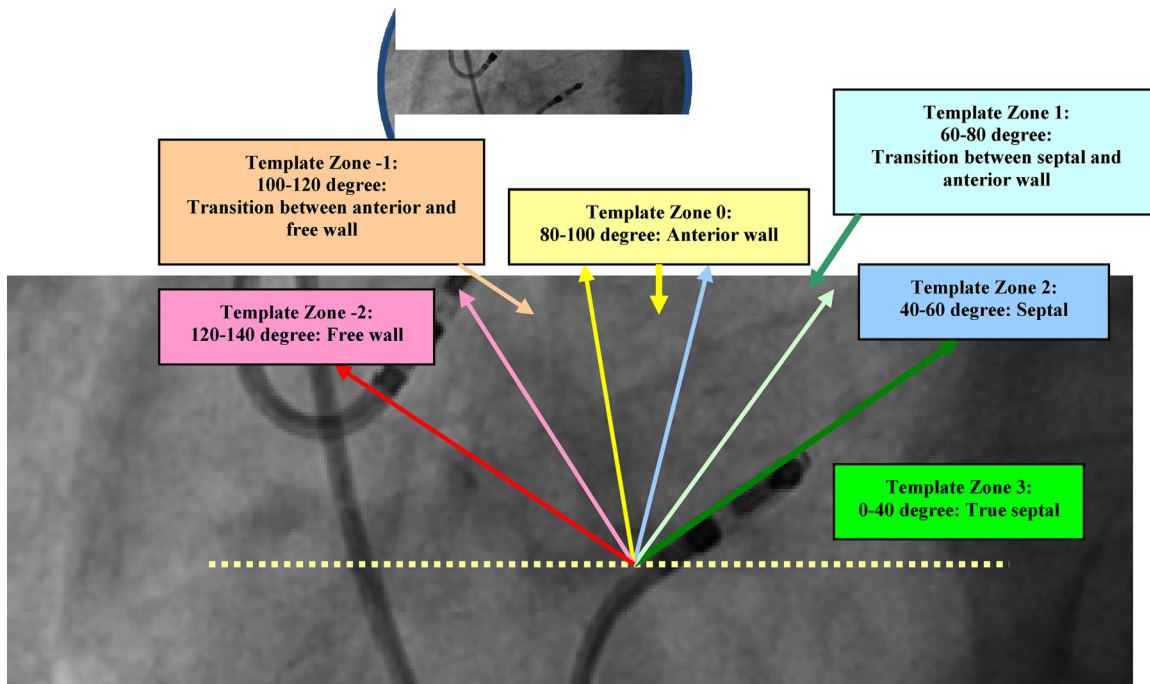


Fig. 4. Fluoroscopic 40° Left Anterior Oblique view: Different lead tip angulations and different template zones.

pacing lead position by CT angiogram, MRI, and Echocardiography and have observed marked heterogeneity between all modalities in defining exact lead tip position, particularly RV nonapical positions. Contrast CT appeared to provide more precise assessment of final lead position.³² Using cardiac CT angiography as “gold standard” Pang et al validated conventional fluoroscopic and electrocardiographic (ECG) criteria for right ventricular pacing lead position.³³ They found only minority of RV leads were implanted on the true RV septum using conventional LAO fluoroscopic criteria alone. They have proposed that aiming for the middle part of the cardiac silhouette in the RAO view, confirming LAO fluoroscopic criteria with a paced QRS duration of less than 140 msec may allow the implanting physician to achieve a more accurate method to achieve true septal lead position. CT overlay during fluoroscopy to guide lead implantation in routine cases is hard to justify. Table 1 summarizes the different methodology of RV septal pacing.

In our practice, we first introduce the pacing lead to RVOT in fluoroscopic PA view. Then, we aim to position the RV pacing lead at the central square or middle square of the top row (in a 9 square model) in RAO fluoroscopic view using any of the pre-shaped stylet (discussed earlier). Once achieved we move to fluoroscopic LAO view and observe the lead tip angulation. The posterior facing lead angulation in LAO view should be less than 60° with the horizontal line. If both LAO and RAO fluoroscopic criteria fulfilled, now it is time to carefully observe without compromising the sterile field the lead tip in LL fluoroscopic view. In LL view, if the lead tip faces posteriorly towards the spine we can expect the certainty of septal location of the ventricular pacing lead. Finally, if paced QRS duration is narrow (less than 140 msec) we can be certain to a great extent that our pacing lead is on the ventricular septum.³³ However, in patients with severe infra-Hisian disease QRS may not get narrowed appreciably with septal pacing in all cases.³¹ In such cases we rely on fluoroscopic appearance only. Fig. 6 shows the step-wise approach in a patient to achieve RV septal positioning of the pacing lead.

6. ECG markers

RV apical pacing produces ECG features of left bundle branch block (LBBB) (Fig. 7A) RV septal pacing produces monophasic tall and narrow R wave in inferior leads (smaller amplitude and wider QRS with notching in R wave indicates free wall location of the pacing lead) with early precordial transition (at or before V4) (Fig. 7B).^{34,35} Pacing from mid-septal region in comparison to RVOT septal region results in narrower QRS complexes. The QRS morphologic appearance in lead I (for both the free-wall and septal), pacing from rightward and posterior location results in a positive QRS polarity (r waves) and pacing from leftward and anterior demonstrate a negative polarity (qs pattern). Sites midway between the anterior and posterior locations results in either biphasic or multiphasic QRS morphology in lead I (qr/rs pattern) or an isoelectric segment preceding the q or r wave with a net polarity that was isoelectric. Pacing from anterior wall (transition zone between septum and free wall) also produces narrow paced QRS complex. But, it causes late precordial transition with lesser leftwards axis. Pacing from RVOT free wall results in notched and wide QRS complex in inferior leads with late precordial transition (Fig. 7C). However, there is great deal of overlap between paced ECG features between true RV septal, anterior wall and free wall pacing.^{24,36,37}

7. Echocardiographic correlates

The exact locations of the RV lead using more precise anatomic methods has only been verified in a few recent studies (all by echocardiography). Domenichini et al verified the exact location of the RV lead using echocardiography and have seen a true mid-septal position in 54% and anterior position in the remaining 46% of patients.³⁷ Ng et al confirmed the lead position by echocardiography and reported about 70% success rate.³⁸ However, the antero-parietal trabeculation was considered a valid septal position for the RV lead (which is in fact adjacent to the anterior wall near the

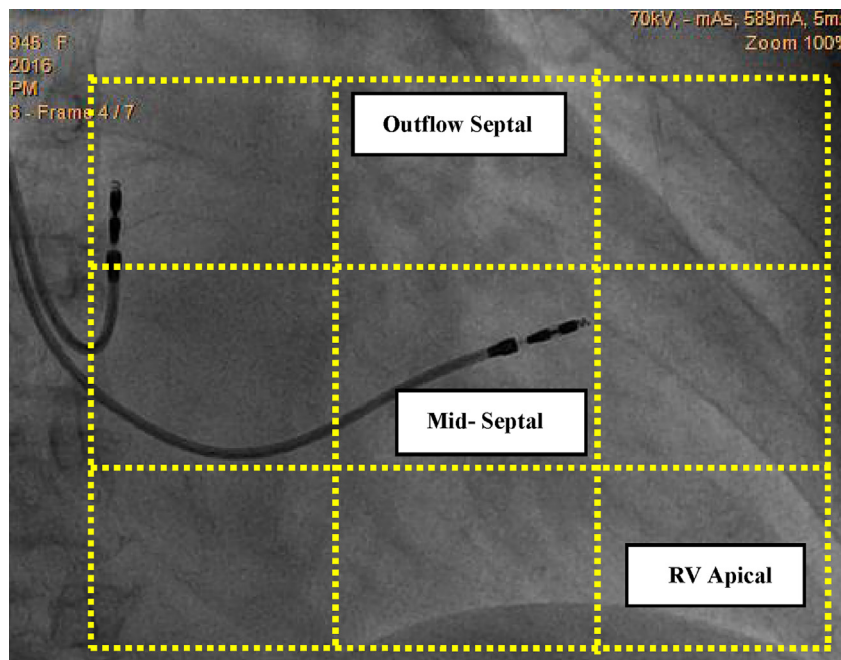


Fig. 5. Fluoroscopic landmarks for mid-septal lead placement using RAO views. In the RAO 30° view, the cardiac Silhouette is divided into thirds from the external border of the heart to the spinal column using an imaginary grid, with the target position of the lead tip being the central third sector (i.e. centre of the cardiac silhouette).

Table 1
Different studies of septal pacing.

Study/reference	year	No. of patients	Styler used	Fluoroscopic projection used	Confirmatory imaging used	Success rate	Advantages/Limitations
Rosso et al ³⁵	2010	100	Mond's styler	PA, LAO,RAO	Electrocardiography	90%	Limitations of ECG for localizing septal position of the RV lead demonstrated in several subsequent studies
Mond et al ²²	2012	113	2D styler was compared with 3D styler	PA, LAO,RAO	Echocardiography	Inclusion of RAO fluoroscopy and 3D styler lead to success rate of 97%	Echocardiography is very much angle and operator dependent
McGavigan et al ²³	2014		Modified Mond's styler	PA, LAO,RAO			Proposed technique requires right ventriculogram during lead implantation and the method was not validated with any confirmatory imaging. CT angiography is gold standard
Burri et al ²⁴	2013	51	Modified Mond's styler	LAO, RAO	CT angiography	Combining RAO fluoroscopy increased the success rate from 41 to 96.4% success rate of 97%	
Chen et al ²⁷	2016	143	Mond's styler	PA, LAO, RAO, LL	Echocardiography	LL view increased the specificity than conventional 3 views (68% vs. 83%)	Very much angle and operator dependent
Pang et al ³³	2014	35	Mond's styler	PA, LAO, RAO, LL	CT angiography	Only 21% lead were attached to true septum using conventional fluoroscopic view and developed a schema to define septal position in fluoroscopic RAO view	Needs more no of patients to confirm the postulated schema

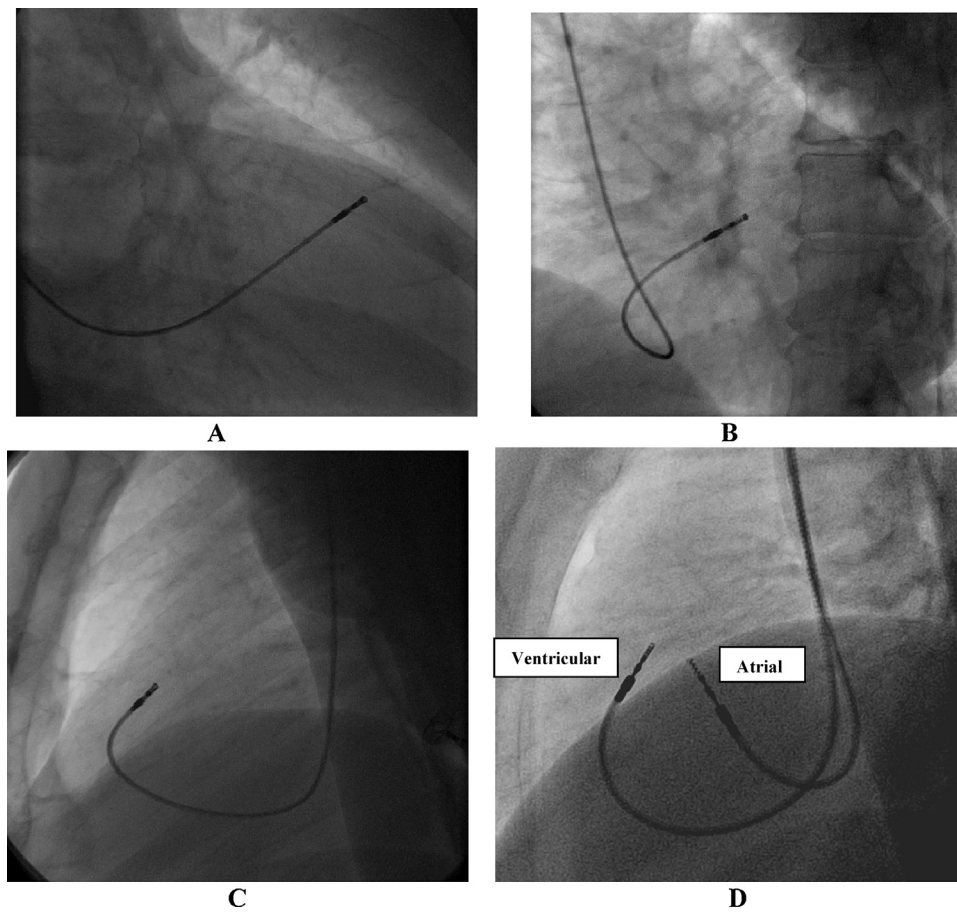


Fig. 6. A, RAO 30° view shows RV lead positioned at the middle square of the top row in imaginary 9 square model; B, LAO 40° shows posteriorly facing lead tip angulation with the horizontal line of less than 60° (Template zone 3); C, Left lateral fluoroscopic view shows posteriorly facing lead tip; D, Final appearance of the lead in LL view after atrial lead positioned in right atrial appendage.

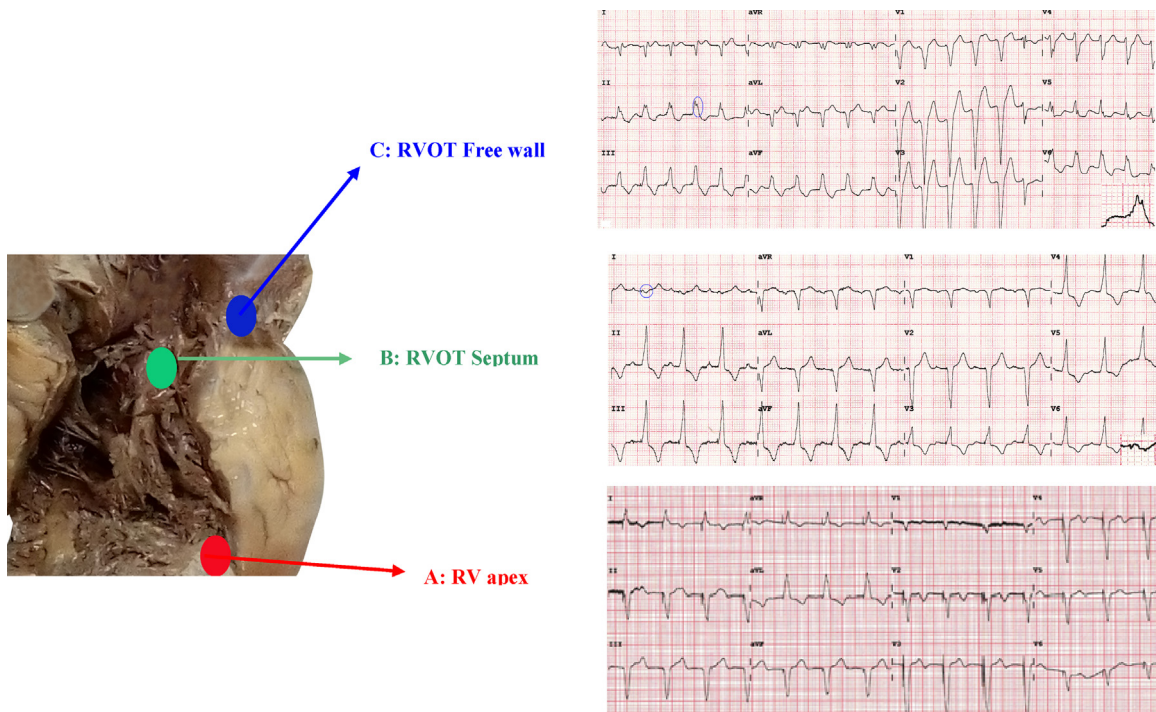


Fig. 7. Pacing from various sites: A; RV apex: Pacing from RV apex results in LBBB pattern. But, the mechanical activation pattern significantly differs from intrinsic LBBB. In pacing induced LBBB the mid and apico-septal region of LV is the earliest and one of the lateral segments (apico, mid, or basal) is the latest activated region with an activation vector directed apical to basal and from right to left. Whereas in intrinsic LBBB, basal septum is the earliest activated region and lateral wall is latest activated in only one third of the patients with activation vector directed from basal to apical and from septal to lateral. B; RVOT septal (Anterior part): Dominant R wave in inferior leads indicate RVOT location of the lead. Narrow paced QRS complex with early precordial transition (at V3) and lack of notching of R wave in inferior leads confirm septal position of the lead. Morphology in lead I suggest location of the pacing lead in the anterior part of the inter-ventricular septum, C; RVOT free wall (Anterior part): Dominant R wave in inferior leads indicate RVOT location of the lead.

Notched and wide paced QRS complex in inferior leads with late precordial transition (at V5) suggest free wall location of the lead.

septum or the anteroseptal groove) and cannot be considered as the true septal area. However, these techniques are not always reliable or accurate as it is highly operator and angle dependent. Moreover, performing per-operative trans thoracic echocardiography is not possible because of sterility reason.

8. Conclusion

Pacing from the RV apex produces abnormal and prolonged electrical activation of LV which results in mechanical dyssynchrony and dysfunction which finally in some patients induce LV dysfunction, atrial fibrillation, heart failure, may be death. Several studies have revealed that adverse outcomes of RV apical pacing are directly linked to cumulative percentage of ventricular pacing. Despite different algorithms to minimize ventricular pacing there is a need for an alternate site for ventricular pacing in patients with high presumed ventricular pacing burden. Most studied alternate site for ventricular pacing is ventricular septum. The RV septum is a complex structure. Conventionally septal position of the ventricular pacing lead is confirmed by fluoroscopic appearance of the lead and characteristics ECG features. But, several recent studies have challenged the use of single fluoroscopic view in predicting septal location of the RV pacing lead as to be inadequate. Although multiple fluoroscopic views enable us to reach the ventricular septum in majority with great precision, it is not 100% specific. The use of combined LAO and RAO fluoroscopic view and finally confirmation in LL view may enable implanting physician to achieve RV septal position of the pacing lead with greater precision to achieve a narrow paced QRS complex as depicted in Fig. 5. However, this approach needs to be validated by large prospective

study using CT angiography for confirmation of the septal location of the lead tip.

Financial support

We have not taken any financial support from anyone for this study.

References

1. Tops LF, Schalij MJ, Bax JJ. The effects of right ventricular apical pacing on ventricular function and dyssynchrony. *J Am Coll Cardiol.* 2009;54:764–776.
2. Lamas GA, Lee KL, Sweeney MO, et al. Ventricular pacing or dual chamber pacing for sinus node dysfunction. *N Engl J Med.* 2002;346:1854–1862.
3. Catanzariti D, Maines M, Cemin C, et al. Permanent direct His bundle pacing does not induce ventricular dyssynchrony unlike conventional right ventricular apical pacing. An intra-patient acute comparison study. *J Interv Card Electrophysiol.* 2006;16:81–92.
4. Ho SY, Nihoyannopoulos P. Anatomy, echocardiography, and normal right ventricular dimensions. *Heart.* 2006;92:i2–13.
5. www.cardiac-device-implantation.nl/chapters/chapter-4-alternative-rv-sites.html.
6. Mărgulescu Andrei D, Suran Berenice M, et al. Accuracy of fluoroscopic and electrocardiographic criteria for pacemaker lead implantation by comparison with three-dimensional echocardiography. *J Am Soc Echocardiogr.* 2010;23:566–574.
7. Blanc JJ, Etienne Y, Gilard M, et al. Evaluation of different ventricular pacing sites in patients with severe heart failure. *Circulation.* 1997;96:3273–3277.
8. Buckingham TA, Candinas R, Duru F, et al. Acute hemodynamic effects of alternate and combined site pacing in patients after cardiac surgery. *Pacing Clin Electrophysiol.* 1999;22:887–893.
9. Pastore G, Zanon F, Noventa F, et al. Variability of left ventricular electromechanical activation during right ventricular pacing: implications for the selection of the optimal pacing site. *Pacing Clin Electrophysiol.* 2010;33:566–574.
10. Victor F, Leclercq C, Mabo P, et al. Optimal right ventricular pacing site in chronically implanted patients. *J Am Coll Cardiol.* 1999;33:311–316.

11. Tse HF, Yu C, Wong KK, et al. Functional abnormalities in patients with permanent right ventricular pacing. The effect of sites of electrical stimulation. *J Am Coll Cardiol.* 2002;40:1451–1458.
12. Kypta A, Steinwender C, Kammler J, et al. Long-term outcomes in patients with atrioventricular block undergoing septal ventricular lead implantation compared with standard apical pacing. *Europace.* 2008;10:574–579.
13. Vanerio G, Vidal JL, Banizl PF, et al. Medium- and long-term survival after pacemaker implant: improved survival with right ventricular outflow tract pacing. *J Int Cardiac Electrophysiol.* 2008;21:195–201.
14. Molina Luis, Sutton Richard, Moreno Gabriela, et al. Medium-term effects of septal and apical pacing in pacemaker-dependent patients: a double-Blind prospective randomized study. *PACE.* 2014;37:207–214.
15. Janoušek Jan, van Geldorp Irene E, Krupičková Sylvia, et al. Permanent cardiac pacing in children: choosing the optimal pacing site a multicenter study. *Circulation.* 2013;127:613–623.
16. Mera F, DeLurgio DB, Patterson RE, et al. A comparison of ventricular function during high right ventricular septal and apical pacing after his-bundle ablation for refractory atrial fibrillation. *Pacing Clin Electrophysiol.* 1999;22:1234–1239.
17. Victor F, Mabo P, Mansour H, et al. A randomized comparison of permanent septal versus apical right ventricular pacing: short-term results. *J Cardiovasc Electrophysiol.* 2006;17:238–242.
18. Stambler BS, Ellenbogen KA, Zhang X, et al. Right ventricular outflow versus apical pacing in paced patients with congestive heart failure and atrial fibrillation. *J Cardiovasc Electrophysiol.* 2003;14:1180–1186.
19. Gong X, Su Y, Pan W, Cui J, Liu S, Shu X. Is right ventricular outflow tract pacing superior to right ventricular apex pacing in patients with normal cardiac function? *Clin Cardiol.* 2009;32:695–699.
20. Yoon HJ, Jin SW, Her SH, et al. Acute changes in cardiac synchrony and output according to RV pacing sites in Koreans with normal cardiac function. *Echocardiography.* 2009;26:665–674.
21. Shimony Avi, Eisenberg Mark J, Filion KB, et al. Beneficial effects of right ventricular non-apical vs. apical pacing: a systematic review and meta-analysis of randomized-controlled trials. *Europace.* 2012;14(1):1–91.
22. Mond HG, Hillock RJ, Stevenson IH, et al. The right ventricular outflow tract: the road to septal pacing. *Pacing Clin Electrophysiol.* 2007;30:482–491.
23. McGavigan AD, Roberts-Thompson KC, Mond HG, et al. Right ventricular outflow tract pacing: radiographic and electrocardiographic correlates of lead position. *Pacing Clin Electrophysiol.* 2006;29:1063–1068.
24. Burri Haran, Domenichini Giulia, Sunthorn Henri, et al. Comparison of tools and techniques for implanting pacemaker leads on the ventricular mid-septum. *Europace.* 2012;14:847–852.
25. Srivatsa SS. Finding the sweet spot for non-apical RV pacing. *J Invasive Cardiol.* 2014;26(3):140–147.
26. Osmancik Pavel, Stros Petr, Herman Dalibor, et al. The insufficiency of left anterior oblique and the usefulness of right anterior oblique projection for correct localization of a computed tomography-verified right ventricular lead into the mid-septum. *Circ Arrhythm Electrophysiol.* 2013;6:719–725.
27. Chen Dongli, Wei Huiqiang, Tang Jiaojiao, et al. A randomized comparison of fluoroscopic techniques for implanting pacemaker lead on the right ventricular outflow tract septum. *Int J Cardiovasc Imaging.* 2016;32:721–728.
28. Mond Harry G, Feldman Alexander, Kumar Saurabh, et al. Alternate site right ventricular pacing: defining template scoring. *PACE.* 2011;34:1080–1086.
29. Sharma Goutam, Salahuddin Salman, Sanders Prashanthan, et al. Inadequacy of fluoroscopy and electrocardiogram in predicting septal position in RVOT pacing – validation with cardiac computed tomography. *Indian Heart J.* 2016;68(2):174–180.
31. Rosso Raphael, Medi Caroline, Mond Harry G, et al. Right ventricular septal pacing: a comparative study of outflow tract and mid-ventricular site. *PACE.* 2010;33(10):1169–1177.
32. Moore Peter, Coucher John, Ngai Stanley, et al. Imaging and right ventricular pacing lead position: a comparison of CT, MRI, and Echocardiography. *PACE.* 2016;39:382–392.
33. Pang Benjamin J, Joshi Subodh B, Lui Elaine H, et al. Validation on conventional fluoroscopic and ECG criteria for right ventricular pacemaker lead position using cardiac computed tomography. *PACE.* 2014;37:495–504.
34. Dixit S, Gerstenfeld EP, Callans DJ, Marchlinski FE. Electrocardiographic patterns of superior right ventricular outflow tract tachycardias: distinguishing septal and free-wall sites of origin. *J Cardiovasc Electrophysiol.* 2003;14:1–7.
35. Rosso Raphael, Teh Andrew W, Medi Caroline, et al. Right ventricular septal pacing: the success of stylet-driven active-fixation leads. *PACE.* 2010;33(1) 10.1111/j.1540-8159.2009.02580.x.
36. Burri H, Park CI, Zimmermann M, et al. Utility of the surface electrocardiogram for confirming right ventricular septal pacing: validation using electroanatomical mapping. *Europace.* 2011;13:82–86.
37. Domenichini G, Sunthorn H, Fleury E, et al. Pacing of the interventricular septum versus the right ventricular apex: a prospective, randomized study. *Eur J Intern Med.* 2012;23:621–627.
38. Ng AC, Allman C, Vidaic J, et al. Long-term impact of right ventricular septal versus apical pacing on left ventricular synchrony and function in patients with second- or third-degree heart block. *Am J Cardiol.* 2009;103:1096–1101.