

# Stroke in a patient with pulmonary arteriovenous fistula: A case report study

Noushin Mehrbod, Ahmad Chitsaz<sup>1</sup>, Mohammad Saadatnia<sup>1</sup>, Navid Manouchehri<sup>2</sup>

Resident of Neurology, Isfahan University of medical sciences, <sup>1</sup>Assistance Professor, Isfahan Neurosciences research center, <sup>2</sup>Medical students' research center, Isfahan University of medical sciences, Isfahan, Iran

## Abstract

Pulmonary arteriovenous fistula (PAVF) is a venous malformation that permits right to left shunting of blood, bypassing the pulmonary capillary bed. Often PAVFs are seen in association with hereditary conditions. On the other hand, isolated PAVFs are rare and asymptomatic. There have been few reports of isolated PAVF related complications. A patient was referred to us with dysarthria and diplopia and history of surgically-treated PAVF. Further evaluations revealed a stroke in thalamic region. We found an open PAVF in a case of thalamic stroke.

**Key Words:** Arteriovenous malformation, pulmonary fistula, stroke

## Address for correspondence:

Dr. Navid Manouchehri, Medical Student Research Center, Isfahan University of Medical Sciences, Hezar Jarib Avenue, Isfahan, Iran.

E-mail: dr.navid.manouchehri@gmail.com

Received: 14.01.2013, Accepted: 09.02.2013

## INTRODUCTION

Pulmonary arteriovenous fistula (PAVF) is a congenital or acquired vascular malformation that is associated with several neurological complications including, strokes, transient ischemic attacks, seizures, and migraines. PAVFs are considered to be associated with hereditary hemorrhagic telangiectasia (HHT) (also known as Rendu-Osler-Weber disease) that manifest with recurrent bleeding and paradoxical brain emboli.<sup>[1]</sup> There have been few reports of symptoms in a case of PAVF without HHT. Here we present a 40-year-old male with thalamic stroke and isolated PAVF.

## CASE REPORT

A 40-year-old male was presented to neurology department (Alzahra Hospital, Isfahan, Iran) with chief complaint of sudden diplopia and dysarthria accompanied by facial palsy. The symptoms had started 48 h earlier and recovered within hours after admission; however, patient's diplopia and facial paresis continued. During his childhood he was treated with Phenobarbital after he was diagnosed with seizures because of recurrent cyanotic attacks and syncope. He had a therapeutic open-thorax surgery after a PAVF was found in an exploratory angiography 13 years ago. Although, the PAVF was closed in the surgery, he has been experiencing episodes of fatigue and shortness of breath during the last 13 years. He had no history of smoking or thrombotic vascular diseases. In physical exam the patient had normal vital signs. He had left-side facial palsy and hemiparesis. He was dysarthric and complained of diplopia when looking to the right side. His electrocardiogram was normal with no arrhythmias. In chest X-ray,

Access this article online	
Quick Response Code:	Website: www.advbiores.net
	DOI: 10.4103/2277-9175.122499

Copyright: © 2013 Manouchehri. This is an open-access article distributed under the terms of the Creative Commons Attribution License, which permits unrestricted use, distribution, and reproduction in any medium, provided the original author and source are credited.

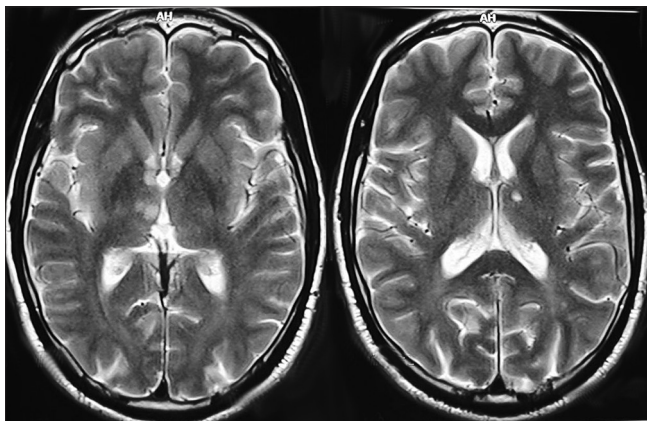
**How to cite this article:** Mehrbod N, Chitsaz A, Saadatnia M, Manouchehri N. Stroke in a patient with pulmonary arteriovenous fistula: A case report study. Adv Biomed Res 2013;2:84.

there were no signs of cardiomegaly, structural abnormalities, increased pulmonary vascular markings or mass-related findings. Arterial blood gas test indicated normal levels of arterial Oxygen. Both laboratory tests for hypercoagulable states and vasculitis panel were negative. In computed tomography (CT-scan) no lesions were found however, in the T2-magnetic resonance imaging (MRI) images, a hyper-signal lesion in the right thalamic region of his brain was seen [Figure 1]. Based on the history, we tested the patient for vascular anomalies. A trans-cranial Doppler [Figure 2] with positive bubble test discovered an open arteriovenous shunt, which was confirmed with a trans-esophageal echocardiogram. The patient had an open PAVF. We put the patient on proper anti-coagulants to prevent further damages. Angiographic images were used to determine the site of fistula. The fistula was closed through surgery and further examinations showed proper blood circulation in higher areas of his lungs, which previously had been bypassed by the AVF. He was put on anticoagulant for 6 months. In 1-month follow-up, he had no complaints of fatigue or shortness of breath, and neurological symptoms were minimized.

## DISCUSSION

We presented a case of new onset stroke in a patient with previously diagnosed and treated isolated PAVF. PAVFs are vascular malformations, characterized by various degrees of right-to-left shunt.<sup>[1]</sup> Based on the severity of the shunt arterial blood-oxygen desaturation may be present.<sup>[2]</sup> Our patient had an open PAVF that had cut-off the circulation to the upmost parts of his lungs.

PAVFs may be acquired secondarily to trauma, infection and metastatic diseases as well as mitral valve stenosis or systemic amyloidosis.<sup>[2]</sup> Primary



**Figure 1:** Hyper-signal lesion in the right thalamic region

PAVFs are associated with hereditary conditions like HHT.<sup>[1,3]</sup> In this case, there was no history of related genetic background in the patient.

Unless the PAVFs have reached the size of at least 2 cm in diameter, they usually remain asymptomatic;<sup>[2]</sup> however, they are responsible for nervous complications, including abscesses and ischemic damages such as strokes or transient ischemic attacks in genetically pre-disposed patients.<sup>[2,4]</sup> Neurological symptoms in this case were caused by a thalamic stroke; however a cerebral infarction due to a pulmonary arterio-venous fistula is a rare condition which has been proven through retrospective studies.<sup>[5]</sup>

Other symptoms include, dyspnea on exertion, palpitation, clubbing and episodes of cyanosis.<sup>[2,6]</sup> Our patient had episodes of fatigue and shortness of breath and in history he mentioned cyanotic attacks and syncope during his childhood.

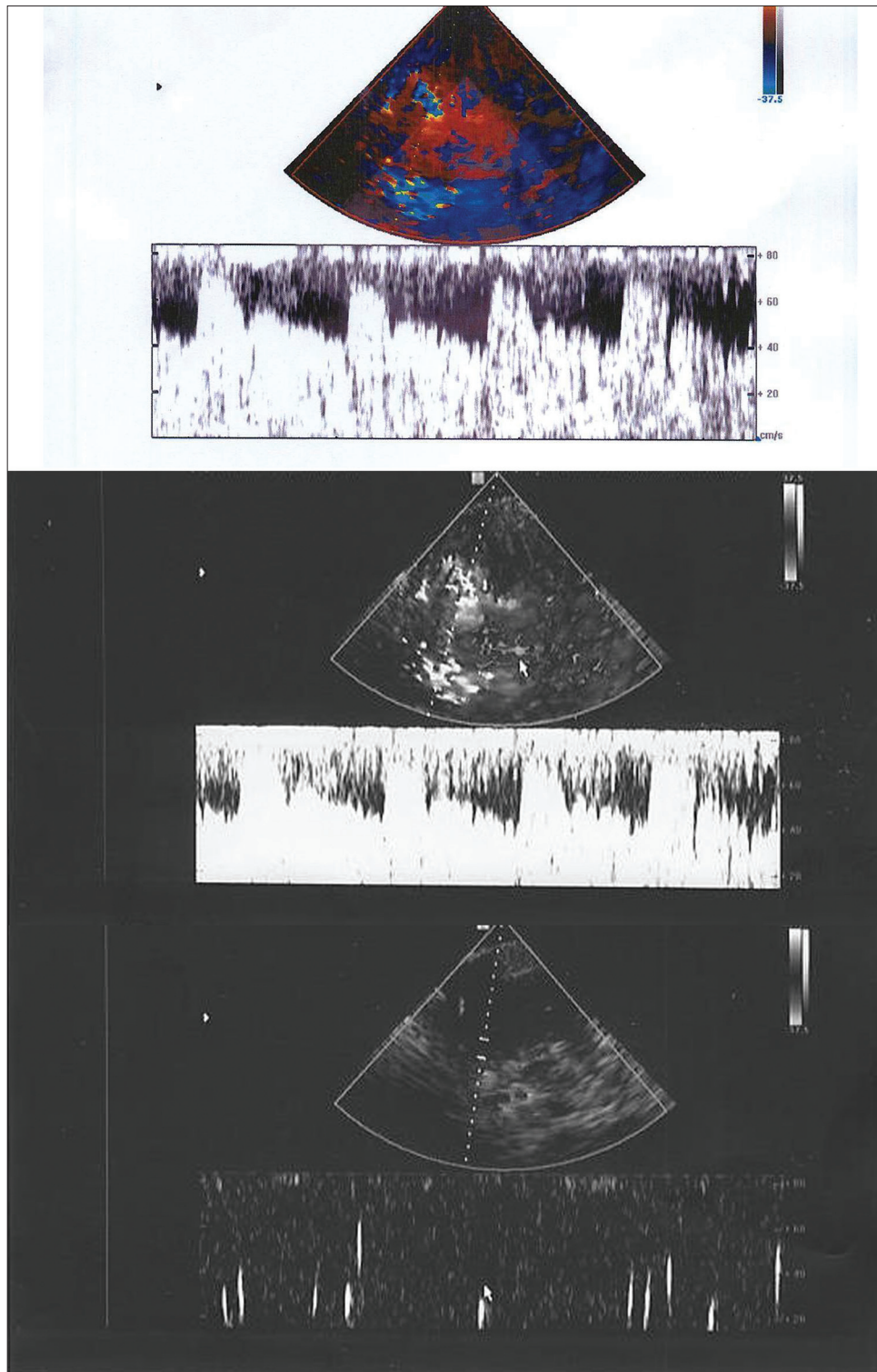
To this date there have been few reports of symptomatic PAVFs and fistula-related complications in non-genetic cases of PAVF. Kimura *et al.* reported four cases of isolated PAVF in patients with cryptogenic strokes.<sup>[6]</sup> Unlike their study our patient did not have venous thrombosis or pulmonary embolism; still, paradoxical emboli were the cause of his stroke. In another study Peters *et al.* reported recurrent ischemic strokes after a successful surgical closure of patent foramen ovale, which led them to the diagnosis of an underlying isolated PAVF.<sup>[7]</sup> Our patient was diagnosed with PAVF 13 years ago and surgical repair was performed, however, bubble study showed that the fistula was still open.

Diagnosis can be achieved through simple chest X-rays, spiral or 3 dimensional CT-scans, and also with the use of diagnostic bubble test. Contrast angiography is also a precise method to diagnose PAVFs. Treatments mainly involve removing the fistula. Trans-catheter closure with angiographic intervention is performed through either occlusion balloons or metallic coils.

In certain cases like fistula in the hilar vasculature of the lungs, active bleeding of a ruptured fistula and failure or contraindication of angiographic methods, surgical treatment to eliminate the lesions is suggested.<sup>[2]</sup>

## CONCLUSION

In conclusion, structural and vascular malformations such as patent foramen ovale and AVFs are potentially capable of causing nervous damages and it is suggested to check them out while approaching to high-risk cases.



**Figure 2:** Trans-cranial Doppler with positive bubble test

## REFERENCES

1. Husain Z, Vuppali M, Hussain K, Khan MN, Patel K, Forbes T, *et al.* An isolated fistula between the right pulmonary artery and the right pulmonary vein: An unusual cause of stroke in a young female. *Cardiol J* 2011;18:73-6.
2. Pick A, Deschamps C, Stanson AW. Pulmonary arteriovenous fistula: Presentation, diagnosis, and treatment. *World J Surg* 1999;23:1118-22.
3. Cohen R, Cabanes L, Burckel C, Duboc D, Touzé E. Pulmonary arteriovenous fistulae thrombosis responsible for recurrent stroke. *J Neurol Neurosurg Psychiatry* 2006;77:707-8.
4. Dines DE, Seward JB, Bernatz PE. Pulmonary arteriovenous fistulas. *Mayo Clin Proc* 1983;58:176-81.
5. Reguera JM, Colmenero JD, Guerrero M, Pastor M, Martín-Palanca A.

- Paradoxical cerebral embolism secondary to pulmonary arteriovenous fistula. *Stroke* 1990;21:504-5.
6. Kimura K, Minematsu K, Nakajima M. Isolated pulmonary arteriovenous fistula without Rendu-Osler-Weber disease as a cause of cryptogenic stroke. *J Neurol Neurosurg Psychiatry* 2004;75:311-3.
  7. Peters B, Ewert P, Schubert S, Abdul-Khaliq H, Lange PE. Rare case of pulmonary arteriovenous fistula simulating residual defect after transcatheter closure of patent foramen ovale for recurrent paradoxical embolism. *Catheter Cardiovasc Interv* 2005;64:348-51.

**Source of Support:** Nil, **Conflict of Interest:** None declared.