

## Case Report

# Adenoma Malignum Diagnosed Postoperatively in a Case of Fibroid Uterus: Case Report with Review of Literature

Garima Yadav, Meenakshi Rao<sup>1</sup>, Meenakshi Gothwal, Pratibha Singh

Departments of Obstetrics and Gynaecology and <sup>1</sup>Pathology, All India Institute of Medical Sciences, Jodhpur, Rajasthan, India

ABSTRACT

"Minimal deviation adenocarcinoma" of the uterine cervix (MDA), historically known as Adenoma Malignum, is a rare variant of cervical adenocarcinoma. Both the clinicians and pathologists must be vigilant about this entity as it could be mistaken for a benign pathology both clinically and microscopically, which can prove disastrous to the patient as these tumors behave like adenocarcinomas. We hereby report an incidentally detected case of AM which was diagnosed in a postmenopausal female postoperatively. We discuss the intraoperative complications, histopathological diagnosis, post-operative management and follow up.

**KEYWORDS:** Adenoma malignum, extremely well-differentiated adenocarcinoma of the cervix (mucinous, gastric type), minimal deviation adenocarcinoma of the cervix

## INTRODUCTION

Minimal deviation adenocarcinoma (MDA) of the uterine cervix, also known as extremely well-differentiated adenocarcinoma of the cervix (WHO 2014 Nomenclature), is a rare variant of cervical adenocarcinoma with an incidence of only 1%–3%.<sup>[1,2]</sup> It was first described by Gusserow<sup>[3]</sup> as malignant adenoma of the cervix referring to a lesion with increased number of endocervical glands situated deep in the cervical stroma as compared to normal cervix, later on, Silverberg and Hurt<sup>[4]</sup> proposed the term "MDA" for this tumor as microscopically, it resembles benign lesion like adenoma but clinically behaves aggressively like malignant adenocarcinomas of the cervix. The interesting fact about adenoma malignum (AM) is that these lesions are usually completely missed on preoperative clinical evaluation, imaging, and cytology of the endocervix. Since the first case was described, only a handful of cases have been described in literature with varying presentations clinically, therefore, the preoperative diagnostic strategy to increase the detection rates, appropriate surgical management, and postoperative management of accidentally diagnosed cases still poses a clinical challenge to the treating physician.

## CASE REPORT

A 50-year-old postmenopausal female, P3 L3, presented

with chief complaints of pain lower abdomen along with pressure symptoms such as difficulty in passing urine. She had no associated complaints of any profuse vaginal discharge, mass descending per vaginum, low backache, or postcoital bleeding. Her past menstrual cycles were regular with no history of heavy menstrual flow, and the perimenopausal transition was normal. She had three normal vaginal deliveries which were uneventful and was menopausal for the past 10 years. She had no medical or surgical comorbidities. Clinical examination revealed a suprapubic lump of around 16 weeks' gravid uterus size. On per speculum examination, cervix and vagina were found to be grossly normal with no abnormal lesion on the ectocervix. A cytological smear of ectocervix and endocervix was taken using sure path technique as the patient was never screened in the past. Per vaginal examination revealed a normal cervix with 16 weeks size uterus which was firm in consistency, freely mobile, with a right lateral bulge of around 6 cm × 6 cm and bilateral fornices were free. A transvaginal scan was done which revealed a hypoechoic lesion of around

**Address for correspondence:** Dr. Garima Yadav, Department of Obstetrics and Gynaecology, All India Institute of Medical Sciences, Jodhpur, Rajasthan, India. E-mail: garimapunein@gmail.com

This is an open access journal, and articles are distributed under the terms of the Creative Commons Attribution-NonCommercial-ShareAlike 4.0 License, which allows others to remix, tweak, and build upon the work non-commercially, as long as appropriate credit is given and the new creations are licensed under the identical terms.

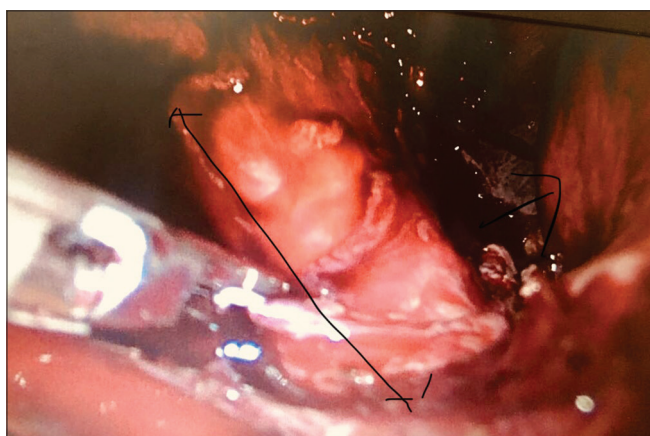
For reprints contact: reprints@medknow.com

**How to cite this article:** Yadav G, Rao M, Gothwal M, Singh P. Adenoma malignum diagnosed postoperatively in a case of fibroid uterus: Case report with review of literature. J Mid-life Health 2018;9:219-21.

Access this article online	
Quick Response Code: 	Website: <a href="http://www.jmidlifehealth.org">www.jmidlifehealth.org</a>
	DOI: 10.4103/jmh.JMH_102_18

6.2 cm × 6.1 cm × 5.8 cm arising from the right lateral wall of the uterus, there was no abnormality detected in the cervix or bilateral adnexa, and the endometrium was thin. The liquid-based cytology report was negative for intraepithelial lesion or malignancy.

The patient was planned for a total laparoscopic hysterectomy, intraoperatively, a 16-week size uterus was found with a laterally bulging intramural fibroid. Fundal structures were coagulated and cut followed by dissection of the bladder. The cervix was found to be around 8 cm which was thin and cord like [Figure 1]. Following coagulation of left-sided uterine, the corpus of the uterus was difficult to manipulate as it rotated over the thin cord like cervix. With the corpus falling on the right side, the right uterine artery was coagulated with difficulty, and excessive bleeding was encountered. Laparoscopy was abandoned, and hysterectomy was completed by open technique. Postoperative period was uneventful and the patient was discharged on the 3<sup>rd</sup> postoperative day. The histopathology report revealed endocervical glands extending deeply (extending to a depth of >7 mm) with variation in shape, ranging from small glands to mildly tortuous glands, with irregular outlines and haphazard arrangement. The cells lining the glands showed minimal to mild atypia, containing abundant clear to eosinophilic cytoplasm with intracytoplasmic mucin, and an occasional gland showing stratification of the lining epithelium. A lot of stromal reaction was noted around many of the glands. On immunohistochemical (IHC), the cells were positive for carcinoembryonic antigen (CEA), and the final diagnosis of extremely well-differentiated mucinous carcinoma of gastric type (MDA/AM) was made [Figure 2]. Bilateral parametria were free of tumor with no lymphovascular invasion or perineural invasion. Leiomyoma was confirmed histologically, and myometrium also revealed evidence of adenomyosis. Since the diagnosis of malignancy was

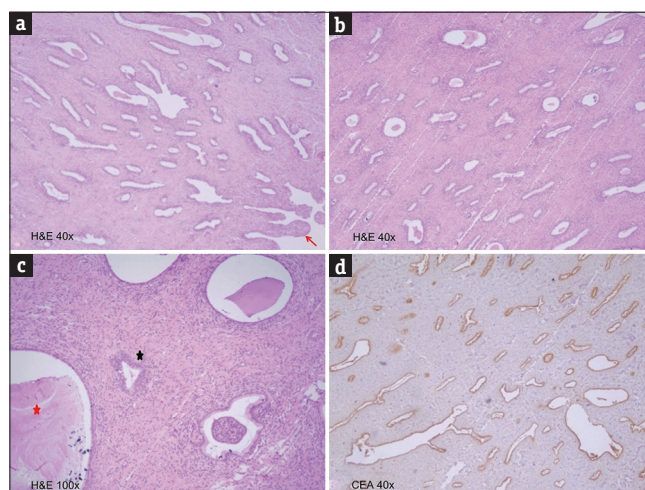


**Figure 1:** Laparoscopic view of the thin long cervix with overhanging fibroid (marked by arrow)

made postoperatively, a contrast-enhanced computed tomography of the abdomen and thorax was advised to rule out any parametrial invasion or distant metastasis, which came out to be normal with no lymphadenopathy. After a joint consultation with our radiation oncology team, decision for adjuvant radiotherapy was taken and the patient was referred for the same. After 3 months of follow-up, the patient remains disease free and symptom free and is planned for follow-up every 3 months for internal examination.

## DISCUSSION

AM is a rare variant of mucinous adenocarcinoma of the cervix also labeled as “MDA” due to the fact that these tumors appear deceptively innocuous but behave aggressively. The tumor is very rare and difficult to diagnose preoperatively, therefore, the usual clinical course approaches to improve diagnosis and postdiagnosis management are still not standardized. Most of the reported cases prove that this tumor is usually diagnosed postoperatively on histopathology following hysterectomy done for benign pathologies. These tumors might not present with classical symptoms of cervical cancer such as abnormal vaginal discharge, intermenstrual bleeding, or postcoital bleeding. Per speculum examination may either reveal a grossly normal looking cervix or multiple nabothian cysts, and on per-vaginal examination, the cervix may appear ballooned up if there is a large endocervical growth.<sup>[5]</sup> These tumors are not found to be associated with HPV, but 10% of cases are found in association with Peutz–Jeghers syndrome.<sup>[6]</sup>



**Figure 2:** (a) Deeply invasive endocervical glands of varying shape and size, ranging from small glands to mildly tortuous and dilated glands with irregular outlines. The lining endocervical epithelium is also noted in the panel (red arrow) (H and E, ×40). (b) Another focus of deeply infiltrating glands (H and E, ×40). (c) Extremely small glands (black asterisk) to dilated glands (red asterisk) lined by minimal to mildly pleomorphic cells (H and E, ×100). (d) Immunohistochemistry for carcinoembryonic antigen showing positivity in the glandular cells (CEA, ×40)

In a recent case series of 18 patients of AM by Lim *et al.*,<sup>[7]</sup> almost all the patients were symptomatic with profuse vaginal discharge or abnormal vaginal bleeding, but a preoperative diagnosis was made on cytology in 22.2% of cases only. Many studies have proven that a papanicolaou smear is not efficient in diagnosing this tumor because of subtle cytological abnormalities and endophytic nature of the growth.<sup>[8,9]</sup>

On imaging, a transvaginal scan may reveal cystic or heterogeneous lesions in the cervical canal, but magnetic resonance imaging (MRI) are found to be most helpful. MRI may reveal a multicystic lesion along with echogenic component involving the cervical stroma along with hyperintensity on T2-weighted images.<sup>[10]</sup> AM resembles a benign pathology on microscopic assessment with subtle features of malignancy picked up only when the pathologist is vigilant about it. The confirmation of this pathology can be done with various IHC markers such as CEA, MIB-1, and p53.

In the present case, the diagnosis of AM was only made postoperatively in a patient with no typical symptoms, a negative cytology and no evidence of any endocervical lesion or growth on a transvaginal scan.

The most appropriate surgeries in preoperatively diagnosed patients of AM are still a matter of debate with most reported cases supporting similar management as that of adenocarcinoma limited to the cervix. In cases which are diagnosed postoperatively, usually, these patients have undergone a simple hysterectomy, and more cases need to be reported regarding any difference in terms of overall outcome in women who have undergone a radical hysterectomy as against those who underwent a simple hysterectomy. Adjuvant treatment in AM is also not yet standardized, but evidence supports adjuvant radiation in these women although laying down the most effective protocol would need more evidence on these lines.

#### **Declaration of patient consent**

The authors certify that they have obtained all

appropriate patient consent forms. In the form the patient(s) has/have given his/her/their consent for his/her/their images and other clinical information to be reported in the journal. The patients understand that their names and initials will not be published and due efforts will be made to conceal their identity, but anonymity cannot be guaranteed.

#### **Financial support and sponsorship**

Nil.

#### **Conflicts of interest**

There are no conflicts of interest.

#### **REFERENCES**

1. Gotoh T, Kikuchi Y, Takano M, Kita T, Ogata S, Aida S, *et al.* An extremely rare case of adenoma malignum with large cystic tumor which resulted in urinary obstruction. *Gynecol Oncol* 2002;84:339-43.
2. Ishii K, Katsuyama T, Ota H, Watanabe T, Matsuyama I, Tsuchiya S, *et al.* Cytologic and cytochemical features of adenoma malignum of the uterine cervix. *Cancer Cytopathol* 1999;87:245-53.
3. Gusserow AL. About sarcoma of the uterus. *Arch Gynecol.* 1870;1:240-51.
4. Silverberg SG, Hurt WG. Minimal deviation adenocarcinoma ("adenoma malignum") of the cervix: A reappraisal. *Am J Obstet Gynecol* 1975;121:971-5.
5. Kamath GD, Bhatt A, Ramaswamy V. A rare case of adenoma malignum: Preparing for the unforeseen. *J Obstet Gynaecol India* 2017;67:70-3.
6. McGowan L, Young RH, Scully RE. Peutz-jeghers syndrome with "adenoma malignum" of the cervix. A report of two cases. *Gynecol Oncol* 1980;10:125-33.
7. Lim KT, Lee IH, Kim TJ, Kwon YS, Jeong JG, Shin SJ. Adenoma malignum of the uterine cervix: Clinicopathologic analysis of 18 cases. *Kaohsiung J Med Sci* 2012;28:161-4.
8. Kaminski PF, Norris HJ. Minimal deviation carcinoma (adenoma malignum) of the cervix. *Int J Gynecol Pathol* 1983;2:141-52.
9. Gilks CB, Young RH, Aguirre P, DeLellis RA, Scully RE. Adenoma malignum (minimal deviation adenocarcinoma) of the uterine cervix. A clinicopathological and immunohistochemical analysis of 26 cases. *Am J Surg Pathol* 1989;13:717-29.
10. Okamoto Y, Tanaka YO, Nishida M, Tsunoda H, Yoshikawa H. Pelvic imaging: Multicystic uterine cervical lesions. Can magnetic resonance imaging differentiate benignancy from malignancy? *Acta Radiol* 2004;45:102-8.