

Pulse Wave Morphology Changes in Aortic Valve Stenosis Detected with Cardio-Ankle Vascular Index

Oscar Plunde ^{1,2}, Anders Franco-Cereceda^{3,4}, Magnus Bäck ^{1,4}

¹Department of Medicine, Solna, Karolinska Institutet, Stockholm, Sweden; ²Novo Nordisk A/S, Medical & Science, Copenhagen, Denmark;

³Department of Molecular Medicine and Surgery, Karolinska Institutet, Stockholm, Sweden; ⁴Heart and Vascular Center, Karolinska University Hospital, Stockholm, Sweden

Correspondence: Oscar Plunde, Department of Medicine, Solna, Karolinska Institutet, 17164 Stockholm, Sweden, Tel +46 8-524 800 00, Email oscar.persson@ki.se

Background: Cardio-ankle vascular index (CAVI) is a measure of systemic arterial stiffness and has been shown to increase after aortic valve surgery. However, change in CAVI-derived pulse wave morphology has not previously been addressed.

Case Study: A 72-year-old female was transferred to a large center for heart valve interventions for evaluation of her aortic stenosis. Few co-morbidities were detected on medical history, other than previous radiation treatment for breast cancer, and no signs of other concomitant cardiovascular disease. The patient was accepted for surgical aortic valve replacement due to severe aortic valve stenosis and arterial stiffness was assessed with CAVI, as part of an ongoing clinical study. The pre-operative CAVI was 4.7 which after surgery increased almost 100% to 9.35. In tandem, the slope of systolic upstroke pulse morphology captured from brachial cuffs was changed from a prolonged flattened pattern to a steeper.

Conclusion: After aortic valve replacement surgery due to aortic valve stenosis, in addition to increased CAVI-derived measures of arterial stiffness, the slope of the CAVI-derived upstroke pulse wave morphology changes to a steeper slope. This finding could have implications in the future of aortic valve stenosis screening and utilization of CAVI.

Keywords: arterial stiffness, cardio-ankle vascular index, pulse wave morphology, aortic valve stenosis

Introduction

Aortic valve stenosis (AVS) is a serious, common cardiovascular disease (CVD) among elderly and the prevalence is expected to rise globally with longevity. Common CVD risk factors also apply to AVS although the role of arterial stiffness is yet not fully elucidated.¹ Increased arterial stiffness in tandem with a stenotic aortic valve, collectively contribute to the increased left ventricular load, which is associated with poor prognosis. Standardized protocols to measure the effective aortic valve orifice area by echocardiography is routine practice, although no method to assess the vascular component of the left ventricular load has been routinely implemented. Cardio-ankle vascular index (CAVI) incorporates data from a phonocardiogram and pulse wave analysis from ankle and brachial cuffs to yield a relatively blood pressure independent measure of systemic arterial stiffness. Intriguingly, the classical finding of *pulsus parvus et tardus* in aortic AVS also reflects prolonged propagation of the forward systolic wave and thereby systolic time intervals and the backward wave stemming from peripheral branching points, all measurable concomitantly when obtaining CAVI.² However, to our understanding, little attention has been given the pulse wave morphology captured concomitantly with CAVI.

Case

A 72-year-old female patient with severe AVS was referred to a cardiology unit for detailed examination and multi-disciplinary treatment decision. The medical history revealed previous chest radiation treatment for a malignancy from

which the patient had been in remission for several years. The patient was a previous smoker without co-morbidities. No diabetes, obesity, hypertension, or chronic kidney disease (CKD) were noted and no history of rheumatic fever. Blood work showed sign of a low-grade systemic inflammation with a C-reactive protein of 2 mg/L, normal estimated glomerular filtration rate of 73 mL/min/1.73m², normal HbA1c, and normal whole blood cell count. Preoperative invasive coronary angiography only showed mild local atherosclerosis without any significant stenosis. On preoperative transthoracic echocardiography (TTE), severe AVS was evident with a peak transaortic jet velocity (Vmax) of 4.8 m/s without concomitant aortic regurgitation, mean pressure gradient (Pmean) 58 mmHg, Doppler velocity index (DVI) 0.22 and left ventricular ejection fraction (LVEF) of 55%. The valve was tricuspid and the valve morphology did not indicate rheumatic valve disease. Preoperative TTE revealed normal ascending aortic dimensions (29 mm in diameter). The patients was offered and accepted surgical aortic valve replacement (SAVR) and was included in the Disease of the Aortic Valve Ascending Aorta and Coronary Arteries (DAVAACA) study with written informed consent.²

One day before and 3 days after SAVR, CAVI was obtained using Va-Sera 1500 (Fukuda Denshi) as part of the DAVAACA study. Before surgery, CAVI was 4.7 (average of left and right CAVI) with an ejection time of 386ms (Figure 1). During surgery, a severely calcified tricuspid aortic valve was replaced with a biological valve prosthesis. The patient suffered a postoperative stroke but quickly recovered with minor sequel. After 3 days, the average CAVI increased to 9.35, and the blood pressure increased 148/63 mmHg to 163/78 mmHg. TTE 6 days after surgery demonstrated relief of the aortic valve obstruction with a Vmax of 2.5 m/s, Pmean 14 mmHg, DVI-index 0.54, a minor paravalvular leakage and an unchanged LVEF at 55%. The left ventricular ejection fraction remained at 55% on the pre- and post-operative examinations. The heart rate moderately increased from 69 bpm to 75 bpm. In tandem, the ejection time decreased to 271ms, and the pre-ejection period increased from 34ms to 112ms. Finally, the morphology of the brachial pulse wave changed after the relief of the left ventricular obstruction to a steeper upstroke signal compared to a prolonged and flattened pattern before (Figure 1). TTE after 1, 3 and 5 years demonstrated normal trans aortic flow

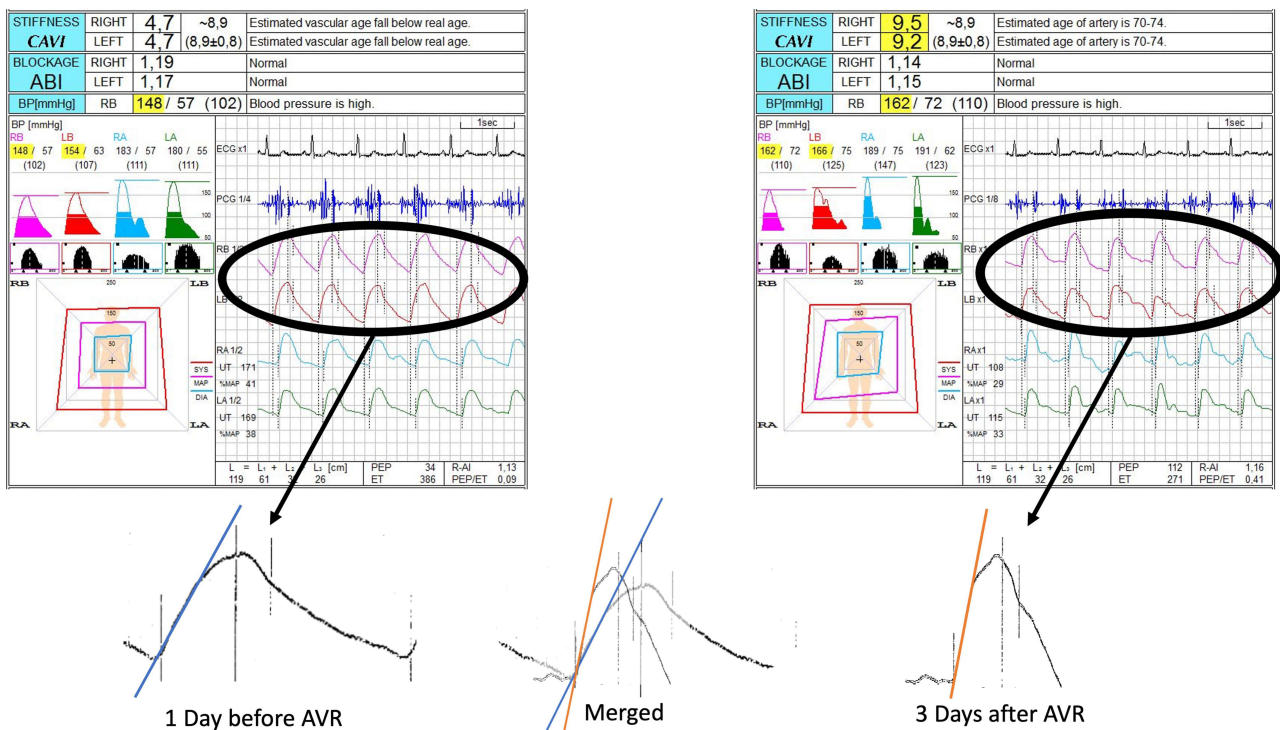


Figure 1 Cardio Ankle Vascular Index and its derived pulse wave morphology in aortic valve stenosis. A print of the original cardio ankle vascular index (CAVI) measurement, before and after surgical valve replacement (AVR). The pulse wave morphology was enlarged without changing the ratio of the picture. To highlight the change of the slope of the upstroke of the pulse, a blue line was inserted for the upstroke angle before AVR, and an Orange line was inserted for the upstroke angle after AVR. **Abbreviations:** ABI, ankle brachial index; BP, blood pressure; DIA, diastolic; ECG, electrocardiogram; LA, left ankle; LB, left brachial; MAP, mean arterial pressure; PCR, phonocardiogram; RA, right ankle; RB, right brachial; SYS, systolic.

velocities with a Vmax of 1.5 m/s after 5 years and normal LVEF. The patient was without any clinical cardiovascular symptoms 5 years after surgery.

Discussion

This case extends the recently reported significantly decreased pulse upstroke time after surgical AVR² by illustrating the change in pulse wave morphology and systolic time intervals, obtained with concomitant CAVI measurement. This case is of particular interest since the patient lacked several hallmark risk factors for AVS, such as hypertension,³ obesity,⁴ diabetes⁵ and CKD.⁶ This might be a partial explanation to the remarkably low CAVI before surgery but also signifies that patients with concomitant co-morbidities and risk factors for arterial stiffness are likely to present with falsely low CAVI in patients with severe AVS, as suggested previously.¹ Previous thoracic radiotherapy has been associated with late development of coronary artery disease and AVS,⁷ whereas this case presents severe radiotherapy associated AVS in the absence of significant coronary stenosis. The normalization of CAVI after SAVR indicates a lack of direct peripheral artery affection. These findings point to the importance of valvular evaluation as part of cardio-oncology assessment of arterial pulse wave abnormalities.

Indeed, both heart rate and blood pressure increased after surgery, although it is highly unlikely to be responsible for the observed increase in CAVI since it is largely blood pressure independent. In this case, we may also appreciate the change of the pulse wave morphology with the decrease in left ventricular ejection time. The difference between postoperative right and left CAVI was reflected by a slight difference in the waveform, in support of an association of the waveform with CAVI. Adding to support the importance of ejection time, Takahashi et al emphasized the correlation between blood flow velocity and ejection time which could explain the decrease in CAVI derived from aortic-ankle PWV in tandem with a prolonged ejection time.^{8,9} Another explanation, physical in nature, was provided by the raised notion of dynamic elastic modulus. By having muscular arteries included in the CAVI measurement, it would theoretically be more sensitive to change in pulse wave morphology or pulse wave frequency compared with cfPWV only incorporating elastic arteries.¹⁰ Lastly, Takahashi et al also raised questions regarding CAVI's ability to correctly determine the timing of the aortic valve closure from the phonocardiogram when AVS causes a significant heart murmur. In the measurement before AVR, the CAVI device was not able to correctly detect the closing of the aortic valve, in the fourth QRS-complex (Figure 1). Although of importance, other heart beats are correctly timed and the tb times appears correct and the VaSera device did not indicate any problem with the measurement (++/++). Nevertheless, the operator of the VaSera device should be aware of this possible problem when determining CAVI in AVS patients.

In contrast to the gold standard arterial stiffness method (carotid-femoral pulse wave velocity), CAVI is an easy examination that does not necessitate on high-quality pulse detection from the carotid artery. In the end of 20th century, systolic time intervals were intensely studied, and showed correlation with AVS.¹¹ However, since the uprise in imaging technology and better availability, the importance of these findings has decreased. With increased CVD burden globally, especially in low-income countries, the need for an easier assessment of AVS increase. Also, the use of telemedicine is expected to increase globally, calling for an AVS assessment method that can be carried out by untrained personnel or the patient themselves. In these settings, CAVI, pulse wave morphology analysis and systolic time intervals may serve as important tools in the future of AVS diagnostics and treatment decision.

Consent

The patient was included in the ongoing, single-centre study DAVAACA (Disease of the Aortic Valve Ascending Aorta and Coronary Arteries), which was approved by the local ethics committee "Regionala etikprövningsnämnden i Stockholm" with reference 2012/1633-31/4. An amendment with reference 2016/2346-32 was approved for measurement and reporting of results for arterial stiffness. Institutional approval is not required to publish case reports. Written informed consent was provided by the patient to report examination results, on the condition that Personal Data are not disclosed.

Acknowledgments

A.F.-C. was supported by donations from Mr Fredrik Lundberg.

Disclosure

Dr Oscar Plunde reports he is employed by Novo Nordisk as International Medical Manager, Medical and Science, outside the submitted work. The authors report no other conflicts of interest in this work.

References

1. Plunde O, Bäck M. Arterial stiffness in aortic stenosis and the impact of aortic valve replacement. *Vasc Health Risk Manag.* 2022;18:117–122. doi:10.2147/vhrm.S358741
2. Plunde O, Franco-Cereceda A, Bäck M. Cardiovascular risk factors and hemodynamic measures as determinants of increased arterial stiffness following surgical aortic valve replacement. Original research. *Front Cardiovasc Med.* 2021;2021:8. doi:10.3389/fcvm.2021.754371
3. Stewart BF, Siscovick D, Lind BK, et al. Clinical factors associated with calcific aortic valve disease. Cardiovascular Health Study. *J Am Coll Cardiol.* 1997;29(3):630–634. doi:10.1016/s0735-1097(96)00563-3
4. Plunde O, Bäck M. Fatty acids and aortic valve stenosis. *Kardiol Pol.* 2021;79(6):614–621. doi:10.33963/KP.a2021.0003
5. Larsson SC, Bäck M, Rees JMB, Mason AM, Burgess S. Body mass index and body composition in relation to 14 cardiovascular conditions in UK Biobank: a Mendelian randomization study. *Eur Heart J.* 2020;41(2):221–226. doi:10.1093/eurheartj/ehz388
6. Vavilis G, Back M, Occhino G, et al. Kidney dysfunction and the risk of developing aortic stenosis. *J Am Coll Cardiol.* 2019;73(3):305–314. doi:10.1016/j.jacc.2018.10.068
7. Herrmann J, Yang EH, Iliescu CA, et al. Vascular toxicities of cancer therapies: the old and the new--an evolving avenue. *Circulation.* 2016;133(13):1272–1289. doi:10.1161/circulationaha.115.018347
8. Takahashi K, Yamamoto T, Shirai K. Reasons for the decline of Cardio-Ankle Vascular Index (CAVI) in Aortic Valve Stenosis (AVS) [letter]. *Vasc Health Risk Manag.* 2022;18:887–888. doi:10.2147/vhrm.S399737
9. Lillie JS, Liberson AS, Mix D, et al. Pulse wave velocity prediction and compliance assessment in elastic arterial segments. *Cardiovasc Eng Technol.* 2015;6(1):49–58. doi:10.1007/s13239-014-0202-x
10. Bergel DH. The dynamic elastic properties of the arterial wall. *J Physiol.* 1961;156(3):458–469. doi:10.1113/jphysiol.1961.sp006687
11. Nesje OA. Severity of aortic stenosis assessed by carotid pulse recordings and phonocardiography. *Acta Med Scand.* 1978;204(4):321–330. doi:10.1111/j.0954-6820.1978.tb08447.x

Vascular Health and Risk Management

Dovepress

Publish your work in this journal

Vascular Health and Risk Management is an international, peer-reviewed journal of therapeutics and risk management, focusing on concise rapid reporting of clinical studies on the processes involved in the maintenance of vascular health; the monitoring, prevention and treatment of vascular disease and its sequelae; and the involvement of metabolic disorders, particularly diabetes. This journal is indexed on PubMed Central and MedLine. The manuscript management system is completely online and includes a very quick and fair peer-review system, which is all easy to use. Visit <http://www.dovepress.com/testimonials.php> to read real quotes from published authors.

Submit your manuscript here: <https://www.dovepress.com/vascular-health-and-risk-management-journal>