

# The treatment of mitral insufficiency in refractory heart failure

Federico Cammertoni, Piergiorgio Bruno, Andrea Mazza, and Massimo Massetti\*

Fondazione Policlinico Universitario Agostino Gemelli IRCCS, Roma, Italy

## KEYWORDS

Secondary mitral insufficiency;  
MitraClip;  
Heart failure;  
Transcatheter therapies

Secondary mitral insufficiency (SMI) is caused by dilatation and left ventricular dysfunction and is a frequent finding in patients with heart failure (HF). It is associated with a mortality of between 40% and 50% at 3 years. The first-line treatment is represented by medical therapy, possibly associated, when indicated, with cardiac resynchronization. If the patient remains symptomatic, corrective action should be considered. Surgery is indicated in cases of severe SMI with ejection fraction >30% and the need for myocardial revascularization. The management of patients in whom revascularization is not an option remains extremely complex and the evidence in this field is extremely limited. Percutaneous transcatheter therapies, reparative or replacement, are rapidly emerging as valid alternatives in cases of patients at high surgical risk. In particular, edge-to-edge repair (MitraClip) has proven effective in improving symptoms and reducing hospitalizations for HF. However, neither transcatheter nor surgical mitral repair or replacement has been shown to significantly improve prognosis, with mortality remaining high (14-20% at 1 year). Randomized trials aimed at assessing the effect of these treatments and establishing their long-term outcomes are urgently required.

## Introduction

Secondary mitral insufficiency (SMI; also known as ‘functional’) is defined as a mitral insufficiency caused by a dysfunction of the left ventricle (LV) in the presence of a normal mitral valve apparatus (*Figure 1*). It is a frequent finding in patients with heart failure (HF) where it is estimated to have a prevalence between 6% and 29% for moderate to severe forms.<sup>1</sup> The causes that can underlie LV dysfunction are multiple but, as far as the purpose of this treatment is concerned, they are distinguishable in ischaemic and non-ischaemic. A correct framework of aetiology, injuries, and the type of dysfunction is an essential prerequisite for the correct management of patients with SMI.

Since it is a heart muscle disease, the primary purpose of the treatment is to correct LV dysfunction through medical therapy and, when indicated, cardiac re-synchronization therapy.<sup>2</sup> However, a not negligible share of patients with

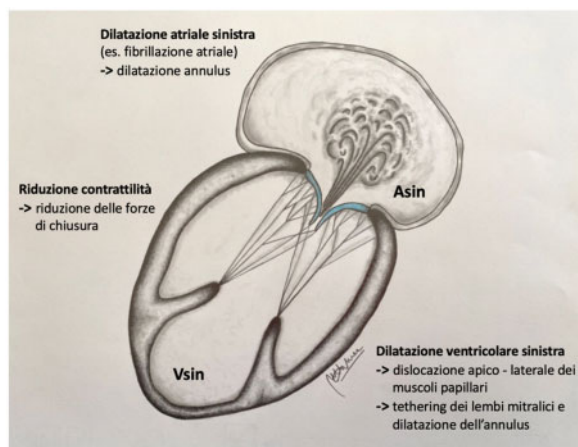
SMI remains symptomatic and it is necessary to evaluate the possibility of further invasive treatment. This field of cardiovascular medicine is still extremely controversial: beyond the cases of ischaemic SMI with the possibility of revascularization, the results of mitral surgery have given results that are not always in agreement.<sup>2</sup> Furthermore, if the advent of percutaneous transcatheter therapies has expanded enormously the pool of potentially treatable patients, on the other hand the results of these techniques, especially in the field of functional forms, have not been univocal.

## Percutaneous treatment of secondary mitral insufficiency

### MitraClip

To date, the MitraClip (Abbott Vascular, Santa Rosa, CA, USA) is the most used device for the transcatheter repair of the mitral valve with over 70 000 implants. Although it was initially approved for primary forms of mitral

\*Corresponding author. Email: Massimo.Massetti@unicatt.it



**Figure 1** Pathophysiology of secondary mitral insufficiency. Remodelling of the left ventricle causes an apical and lateral dislocation of one or both papillary muscles resulting in tethering on one or both mitral flaps. The dilation of the mitral ring is common in the dilation of the left ventricle but it can also occur in the context of an isolated left atrial dilation. Finally, the reduced contractility of left ventricle leads to a reduction of the mitral valve closing forces. Tethering, the reduction of closing forces, and the dilation of the mitral ring are the main determinants of secondary mitral insufficiency.

incompetence, it soon moved to the ‘off-label’ treatment of SMI patients. The mechanism of action with which it acts is attributable to the ‘edge-to-edge’ technique described by Alfieri for the surgical repair of the mitral valve. It consists in ‘clipping’ the anterior and posterior leaflets, thus creating a double mitral orifice. The EVEREST II study compared surgical mitral valve vs. percutaneous repair with MitraClip. In the subgroup of patients with SMI (27% of the total population), the primary endpoint (a composite of freedom from death, reoperation, and mitral insufficiency 3+ or 4+) was not significantly different between the two groups at 4 years of follow-up.<sup>3</sup> More recently, two randomized trials have investigated the effectiveness of MitraClip vs. optimal medical therapy in patients with SMI. The COAPT<sup>4</sup> study enrolled 614 symptomatic patients despite optimal medical therapy, with moderate-severe to severe SMI and depressed ejection fraction (EF) (20-50%). At 24 months, patients in the MitraClip group had a significant reduction in re-hospitalizations for HF (primary endpoint) (35.8% vs. 67.9% patient-year,  $P < 0.001$ ) and mortality (29.1% vs. 46.1%,  $P < 0.001$ ) compared to patients on medical therapy only. Only 5% of patients had an SMI  $>2+$  at 1 year. The smallest MITRA-FR<sup>5</sup> study randomized 304 symptomatic patients, with severe SMI and depressed EF (15-40%), to MitraClip vs. optimal medical therapy. The most interesting finding was that at 12 months there was no significant difference between the two groups as far as the primary endpoint, a composite of death and re-hospitalizations for HF (54.6% vs. 51.3% for the MitraClip group and the control group, respectively;  $P = 0.53$ ). The relapse rate of mitral insufficiency at 1 year was higher than reported in the COAPT (17%). These differences can be partly explained by the fact that the COAPT trial included a greater number of patients, had a longer follow-up and, on average, the patients had a higher degree SMI and a lower degree ventricular dilation than those of the

MITRA-FR trial. Precisely with regard to these last two points: in a recent study,<sup>6</sup> the authors proposed a subdivision of the SMI into two subgroups on the basis of the mutual interdependence between the severity of the mitral defect and the extent of ventricular remodelling: those in which it exists a linear relationship between the extent of ventricular remodelling and the severity of mitral insufficiency (‘proportionate’ group) and those in whom dysfunction rather than ventricular dilation causes the valve defect (‘disproportionate’ group). Interpreting the results of the COAPT and MITRA-FR trials in light of this observation, it can be assumed that ‘proportionate’ patients (as they were predominantly those enrolled in MITRA-FR) could benefit more from interventions aimed at correcting ventricular volume, while ‘disproportionate’ patients (such as those of COAPT) would be more responsive to treatments aimed at restoring correct mitral valve function. Ultimately, this substantial difference in the results of the COAPT and MITRA-FR studies underlines the importance of arriving at a correct definition and selection of the patient with SMI who will benefit most from the procedure. The results of the two studies are to be considered more complementary than opposed.

#### Other transcatheter solutions for valve repair

The Carillon Mitral Contour System (Cardiac Dimension Inc., Kirkland, WA, USA) is a device that allows indirect transcatheter annuloplasty. It is housed in the coronary sinus, in close proximity to the posterior mitral annulus. Thanks to its double anchor (proximal and distal), it allows the reduction of mitral insufficiency through a septal-lateral compression of the posterior annulus. The main limits are represented by the great anatomical variability of the coronary sinus and by the fact that the device acts on the annulus only indirectly. Although few studies still exist and the clinical impact is still largely unknown, the Carillon has demonstrated good ease of implantation, a limited adverse event rate at 30 days (between 1.9% and 13%), and a stable reduction in mitral insufficiency at 12 months.<sup>7,8</sup> The Cardioband MV Reconstruction System (Edwards Lifesciences, Irvine, CA, USA) and Mitralign (Mitralign Inc., Tewksbury, MA, USA) are two transcatheter devices that allow direct annuloplasty: the first is positioned transectally on the atrial side of the posterior mitral annulus in a concept that is not different from a surgical annuloplasty; the second consists in positioning retrograde arterially two sutures with pledget on each commissure, also in this case creating a restrictive annuloplasty. Although early studies have provided promising results, there is still no conclusive evidence of short- and long-term clinical outcomes.

#### Transcatheter mitral valve replacement

To date, numerous biological prostheses are being developed. The main difficulties in their design lie in the complexity of the mitral valve apparatus, in the non-rigidity and dimensional variability of the valve ring and in the risk of obstruction of the outflow tract of the LV. The available evidence is the result of observational studies on a small number of SMI patients followed for a period of ~2 years. According to data in the literature, the implantation of

these devices has a success rate of between 76% and 93%, conversion to cardiac surgery between 0% and 15%, and 30-day mortality between 3% and 53%. At follow-up, the reduction of mitral insufficiency was stable and the symptoms improved for all devices.<sup>9</sup> However, further studies are necessary to be able to consider these procedures a valid option for patients with SMI.

### Surgical treatment of secondary mitral insufficiency

In patients with ischaemic SMI there is, in some cases, the possibility of acting on the cause responsible for ventricular dysfunction and, therefore, mitral insufficiency. Revascularization could favour a positive remodelling of LV which, in turn, could lead to a reduction in SMI: however, the success of revascularization depends strictly on the size of the vital myocardium. Whether the addition of a procedure on the valve at the time of coronary artery bypass graft (CABG) could improve the prognosis has been the subject of divergences and, still today, much remains undefined. However, current European guidelines recommend (IM Class I, level of evidence C) severe SMI correction in CABG candidates and EF >30% and suggest considering it (Class IIa, level of evidence C) in symptomatic patients with EF <30% but with the possibility of revascularization and evidence of myocardial viability.<sup>2</sup> Outside the areas in which there is the possibility of revascularization, the evidence becomes weak. In fact, isolated mitral valve surgery is associated with a high perioperative mortality and a high risk of recurrence. If we add to this the absence of evidence to support a survival benefit, we understand why the indications are so restrictive.<sup>2,10</sup> In any case, the diagnosis and treatment of patients with HF and SMI requires systematically a Heart Team and the involvement of specialists in the field of HF and electrophysiology. Another topic on which there has been controversy is the management of patients with moderate SMI candidates for CABG. A subgroup of the STICH<sup>11</sup> study showed that mitral repair in association with CABG in patients with EF <35% led to a reduction in mortality compared to CABG alone. A subsequent trial conducted on 301 patients with moderate ischaemic SMI randomized to CABG or CABG plus mitral valve repair instead documented similar mortality, rehospitalizations and degree of ventricular remodelling at 2 years. In addition, patients undergoing the combined procedure had a postoperative complication rate (neurological: stroke, TIA, metabolic encephalopathy; supra-ventricular arrhythmias) and longer hospital stays than those who had received only CABG.<sup>12</sup> Two other randomized studies are of particular interest: the RIME<sup>13</sup> and the POINT trial.<sup>14</sup> In both of these studies, the authors showed that adding valve repair to CABG led to positive ventricular remodelling, improvement of EF, improvement of symptoms, and degree of mitral insufficiency but not to substantial mortality benefits. To date, the treatment of moderate SMI in CABG candidate patients is no longer recommended.<sup>2</sup> However, there is likely to be a subset of patients whose survival, symptoms, and functional status may improve after valve repair, but this subset still needs to be identified. In addition to the indication, the choice of the

type of surgical treatment remains the subject of intense debate. While for primary forms of mitral insufficiency, valve repair is the first-choice treatment,<sup>2</sup> in the cases of SMI the evidence is controversial. In fact, restrictive annuloplasty is burdened with a relapse rate from 30% to 40% at 12 months and up to 60% at 5 years after surgery.<sup>15</sup> Preoperative echocardiography is able to identify numerous factors associated with risk of mitral insufficiency residual or recurrence after repair (symmetrical tethering of the flaps, tethering angle of the posterior flap >45°, tenting height >11 mm, presence of a basal A/dyskinetic area, severe dilation of the LV or high spherical index of the LV, etc.) and it is reasonable, in the presence of these risk factors, to proceed with a valve replacement. In a randomized study of 251 patients with severe ischaemic SMI assigned to repair vs. valve replacement, the authors achieved similar results in terms of mortality, ventricular remodelling, and major adverse events between the two groups at 2 years. Patients undergoing valve repair, however, had a significantly higher recurrence rate of mitral insufficiency (58.8% vs. 3.8%,  $P < 0.001$ ) resulting in a higher frequency of rehospitalizations (48.3% vs. 42.2%,  $P = 0.01$ ).<sup>15</sup>

### Conclusions

Secondary mitral insufficiency represents a challenge in the field of cardiovascular medicine. Its presence in the context of HF is associated with an unfavourable prognosis. When, despite optimal medical therapy and possibly the use of cardiac re-synchronization, the patient remains symptomatic, the problem arises whether to proceed with a corrective intervention. Surgery is indicated in severe forms of SMI with the possibility of revascularization. In high-risk patients, percutaneous solutions are a valid alternative. To date, however, the most concrete option to offer our patient is that of the MitraClip. Regardless of the strategy used, the long-term prognostic impact of the correction of the SMI remains to be clarified and further randomized studies are urgently required.

**Conflict of interest:** none declared.

### References

1. Varadarajan P, Sharma S, Heywood JT, Pai RG. High prevalence of clinically silent severe mitral regurgitation in patients with heart failure: role for echocardiography. *J Am Soc Echocardiogr* 2006;**19**: 1458-1461.
2. Baumgartner H, Falk V, Bax JJ, De Bonis M, Hamm C, Holm PJ, Jung B, Lancellotti P, Lansac E, Rodriguez Muñoz D, Rosenhek R, Sjögren J, Tornos Mas P, Vahanian A, Walther T, Wendler O, Windecker S, Zamorano JL; ESC Scientific Document Group. 2017 ESC/EACTS guidelines for the management of valvular heart disease. *Eur Heart J* 2017;**38**:2739-2791.
3. Mauri L, Foster E, Glower DD, Apruzzese P, Massaro JM, Herrmann HC, Hermiller J, Gray W, Wang A, Pedersen WR, Bajwa T, Lasala J, Low R, Grayburn P, Feldman T. Four-year results of a randomized controlled trial of percutaneous repair vs. surgery for mitral regurgitation. *J Am Coll Cardiol* 2013;**62**:317-328.
4. Stone GW, Lindenfeld JA, Abraham WT, Kar S, Lim DS, Mishell JM, Whisenant B, Grayburn PA, Rinaldi M, Kapadia SR, Rajagopal V, Sarembock IJ, Brieke A, Marx SO, Cohen DJ, Weissman NJ, Mack MJ. Transcatheter mitral-valve repair in patients with heart failure. *N Engl J Med* 2018;**379**:2307-2318.

5. Obadia J-F, Messika-Zeitoun D, Leurent G, Lung B, Bonnet G, Piriou N, Lefèvre T, Piot C, Rouleau F, Carrié D, Nejari M, Ohlmann P, Leclercq F, Saint Etienne C, Teiger E, Leroux L, Karam N, Michel N, Gilard M, Donal E, Trochu J-N, Cormier B, Armoiry X, Boutitie F, Maucort-Boulch D, Barnet C, Samson G, Guerin P, Vahanian A, Mewton N. Percutaneous repair or medical treatment for secondary mitral regurgitation. *N Engl J Med* 2018;**379**:2297-2306.
6. Packer M, Grayburn PA. Contrasting effects of pharmacological, procedural and surgical interventions on proportionate and disproportionate functional mitral regurgitation in chronic heart failure. *Circulation* 2019;**140**:779-789.
7. Schofer J, Siminiak T, Haude M, Herrman JP, Vainer J, Wu JC, Levy WC, Mauri L, Feldman T, Kwong RY, Kaye DM, Duffy SJ, Tübler T, Degen H, Brandt MC, Van Bibber R, Goldberg S, Reuter DG, Hoppe UC. Percutaneous mitral annuloplasty for functional mitral regurgitation: results of the CARILLON Mitral Annuloplasty Device European Union Study. *Circulation* 2009;**120**:326-333.
8. Siminiak T, Wu JC, Haude M, Hoppe UC, Sadowski J, Lipiecki J, Fajadet J, Shah AM, Feldman T, Kaye DM, Goldberg SL, Levy WC, Solomon SD, Reuter DG. Treatment of functional mitral regurgitation by percutaneous annuloplasty: results of the TITAN trial. *Eur J Heart Fail* 2012;**14**:931-938.
9. Regueiro A, Granada JF, Dagenais F, Rodes-Cabau J. Transcatheter mitral valve replacement: insights from early clinical experience and future challenges. *J Am Coll Cardiol* 2017;**69**:2175-2192.
10. Wu AH, Aaronson KD, Bolling SF, Pagani FD, Welch K, Koelling TM. Impact of mitral valve annuloplasty on mortality risk in patients with mitral regurgitation and left ventricular systolic dysfunction. *J Am Coll Cardiol* 2005;**45**:381-387.
11. Deja MA, Grayburn PA, Sun B, Rao V, She L, Krejca M, Jain AR, Leng Chua Y, Daly R, Senni M, Mokrzycki K, Menicanti L, Oh JK, Michler R, Wróbel K, Lamy A, Velazquez EJ, Lee KL, Jones RH. Influence of mitral regurgitation repair on survival in the surgical treatment for ischemic heart failure trial. *Circulation* 2012;**125**:2639-2648.
12. Michler RE, Smith PK, Parides MK, Ailawadi G, Thourani V, Moskowitz AJ, Acker MA, Hung JW, Chang HL, Perrault LP, Gillinov AM, Argenziano M, Bagiella E, Overbey JR, Moquete EG, Gupta LN, Miller MA, Taddei-Peters WC, Jeffries N, Weisel RD, Rose EA, Gammie JS, DeRose JJ, Puskas JD, Dagenais F, Burks SG, El-Hamamsy I, Milano CA, Atluri P, Voisine P, O'Gara PT, Gelijns AC. Two-year outcomes of surgical treatment of moderate ischemic mitral regurgitation. *N Engl J Med* 2016;**374**:1932-1941.
13. Chan KMJ, Punjabi PP, Flather M, Wage R, Symmonds K, Roussin I, Rahman-Haley S, Pennell DJ, Kilner PJ, Dreyfus GD, Pepper JR. Coronary artery bypass surgery with or without mitral valve annuloplasty in moderate functional ischemic mitral regurgitation: final results of the Randomized Ischemic Mitral Evaluation (RIME) trial. *Circulation* 2012;**126**:2502-2510.
14. Fattouch K, Guccione F, Sampognaro R, Panzarella G, Corrado E, Navarra E, Calvaruso D, Ruvolo G. POINT: efficacy of adding mitral valve restrictive annuloplasty to coronary artery bypass grafting in patients with moderate ischemic mitral valve regurgitation: a randomized trial. *J Thorac Cardiovasc Surg* 2009;**138**:278-285.
15. Goldstein D, Moskowitz AJ, Gelijns AC, Ailawadi G, Parides MK, Perrault LP, Hung JW, Voisine P, Dagenais F, Gillinov AM, Thourani V, Argenziano M, Gammie JS, Mack M, Demers P, Atluri P, Rose EA, O'Sullivan K, Williams DL, Bagiella E, Michler RE, Weisel RD, Miller MA, Geller NL, Taddei-Peters WC, Smith PK, Moquete E, Overbey JR, Kron IL, O'Gara PT, Acker MA. Two-year outcomes of surgical treatment of severe ischemic mitral regurgitation. *N Engl J Med* 2016;**374**:344-353.