


Beyond appearance: An unusual manifestation of isolated oral secondary syphilis

International Journal of
Immunopathology and Pharmacology
Volume 33: 1–4
© The Author(s) 2019
Article reuse guidelines:
sagepub.com/journals-permissions
DOI: 10.1177/2058738419845566
journals.sagepub.com/home/iji


Elena Mari¹, Maurizio Nudo¹, Enzo Palese¹, Luisa Cotticelli²,
Ciro Cotticelli², Grazia Zino¹, Rosa Coppola³,
Federica Maria Di Lella⁴, Gabriele Arcari⁵,
Donatella Maria Rodio⁵, Carla Prezioso⁵, Valeria Pietropaolo⁵ ,
Valeria Devirgiliis³ and Vincenzo Panasiti³

Abstract

Syphilis is a sexually acquired chronic infection caused by *Treponema pallidum* and is characterized by a variety of clinical manifestations. The secondary stage of the disease results from the hematogenous and lymphatic dissemination of treponemes after a few weeks or months, and it is characterized by recurrent activity of the disease, with mucocutaneous as well as systemic manifestations. Mucosal lesions range from small, superficial ulcers that resemble painless aphthae to large gray plaques, and they are generally associated with systemic manifestations of the disease. The exclusive asymptomatic oral localization not associated with general manifestations is uncommon but may actually be unrecognized and under-reported. We report a case of isolated oral manifestation as the unique presentation of secondary syphilis.

Keywords

oral syphilis, secondary syphilis, unusual manifestation

Date received: 10 December 2018; accepted: 14 March 2019

Introduction

Syphilis is a sexually transmitted disease caused by *Treponema pallidum* subspecies *pallidum*, an anaerobic tightly coiled helical bacterial species member of the Spirochaetales order.

The infection course is typically divided into primary and secondary stages, also referred to as “early syphilis” which corresponds to the infectious phase and is defined as an infection more recent than 2 years by the World Health Organization (WHO) or 1 year by US and European guidelines, followed by a latent period which eventually results in tertiary syphilis.^{1–3} The disease is characterized by varied clinical manifestations, a trait which earned syphilis the name of “The great imitator.”⁴

Primary syphilis typical presentation is a single (or rarely multiple) painless, non-itchy skin ulceration called “chancre” which appears on the genitalia

¹Division of Dermatology, IDI-IRCCS-FLMM, Rome, Italy

²Department of Oral and Maxillo Facial Sciences, University of Rome “La Sapienza,” Rome, Italy

³Plastic and Reconstructive Surgery Unit, Campus Bio-Medico University of Rome, Rome, Italy

⁴Department of Experimental Medicine, University of Campania “Luigi Vanvitelli,” Naples, Italy

⁵Department of Public Health and Infectious Diseases, University of Rome “La Sapienza,” Rome, Italy

Corresponding author:

Valeria Pietropaolo, Department of Public Health and Infectious Diseases, University of Rome “La Sapienza,” Rome 00185, Italy.
Email: valeria.pietropaolo@uniroma1.it



approximately 3 weeks after the first exposure in conjunction with regional lymphadenopathy, both with spontaneous resolution.⁵ The secondary stage of the disease takes place 6–8 weeks after the clinical resolution of the primary lesions and is the result of hematogenous and lymphatic dissemination of treponemes, with the possibility of mucocutaneous and systemic manifestations. During the second stage of syphilis, the most frequent clinical presentation is a generalized non-pruritic macular or papulo-squamous eruption. Several clinical forms are described for the secondary syphilis affecting oral mucosa. Among those, the most common is called “mucous patches,” which can have two different manifestations: slightly elevated-type plaques usually oval shaped and occasionally ulcerated, covered with a gray or white pseudomembrane or multiple mucous patches that may coalesce to give rise to serpiginous lesions, described as “snail track ulcers.” However, some cases can have atypical presentations, and the diagnosis can be delayed or even missed.⁶ Syphilitic mucosal lesions are characterized by superficial ulcers like aphthae or large gray plaques, usually associated with systemic manifestations. The oral cavity involvement as the unique manifestation of secondary syphilis is rather uncommon.⁷

Case report

Ethics statement

The subject gave a written informed consent in accordance with the Declaration of Helsinki.

We present the case of a 49-year-old female patient with an isolated oral manifestation. In April 2017, she was admitted to our Division of Dermatology (IDI-IRCCS-FLMM) for a 3-month history of asymptomatic infiltrated plaques, exclusively located on the tongue. Her blood count and C-reactive protein (CRP) levels were normal, her past medical and dermatological history were unremarkable, and the oral examination revealed circular whitish and gray plaques, infiltrated and with tender consistency located on the tongue (Figure 1); physical examination did not show skin or genital lesions. Patient had no systemic involvement as fever or lymph node enlargement. Because the clinical presentation simulated an oral candidiasis (Figure 2), the patient received an antifungal treatment in the first instance, without any improvement.

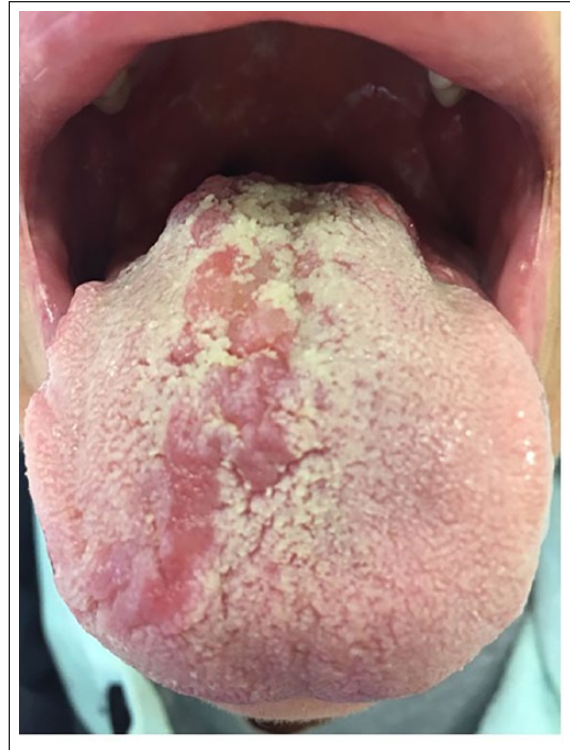

Figure 1. Circular tender and infiltrated whitish plaques on the tongue in the photography taken after the first medical examination.

Given the absence of any other symptom the hypothesis of an isolated oral secondary syphilis was first excluded.

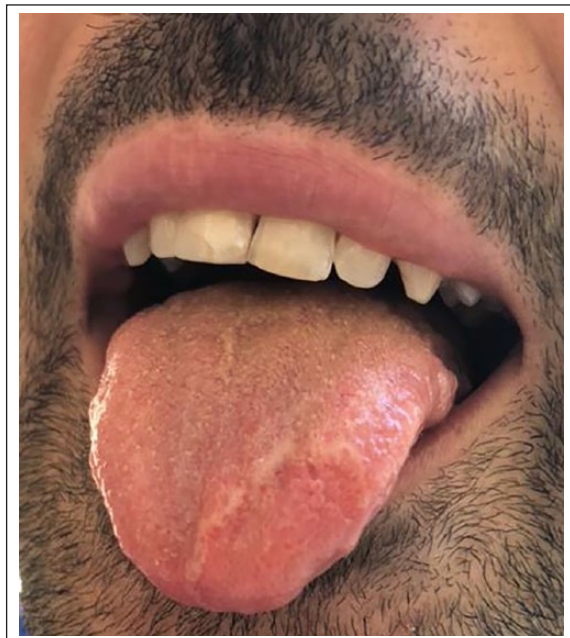


Figure 2. A typical presentation of oral thrush.

Given the similarity of our patient condition to this classic scenario a misdiagnosis can be easily done.

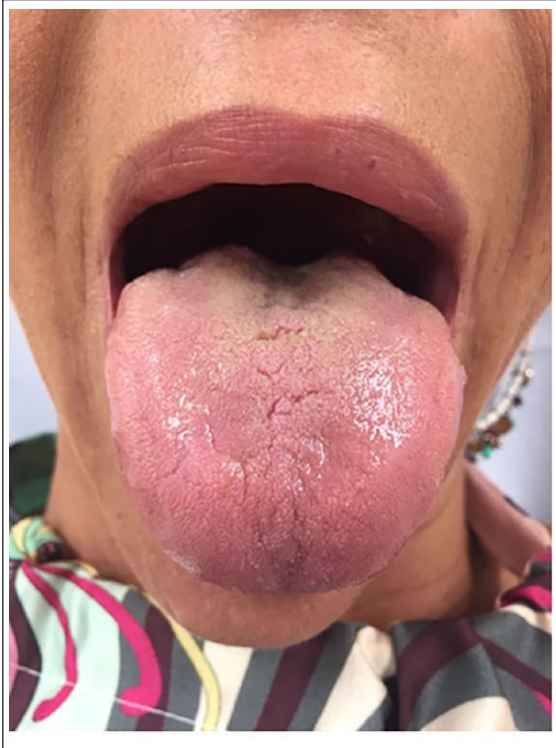


Figure 3. After an accurate diagnosis and two doses of Penicillin G 1.2 million units, a complete resolution of the lesions can be observed.

At direct microscopic smear examination, no signs of fungal infection were seen; therefore, a biopsy was performed. Histological examination revealed inflammatory infiltrate of neutrophils and plasma cells in the dermis. Routine blood tests were normal and autoimmunity, serology for HIV, HBV, and HCV tests were negative. Serologic tests for syphilis showed a positive venereal diseases research laboratory (VDRL) at a titer of 1/32 and a reactive *T. pallidum* hemagglutination test. Based on these data, a diagnosis of secondary syphilis was made.

The WHO therapy guidelines suggest the use of intramuscular benzathine penicillin G 2.4 million units once over two administrations of procaine penicillin G 1.2 million units in 10–14 days. However, this recommendation is marked as “Conditional recommendation, very low quality evidence”; hence, relying on our documented clinical experience, we decided to administer systemic therapy with penicillin G benzathine (1.2 million units, IM 2 fl). The lesions regressed completely 15 days after therapy (Figure 3).

Discussion

Primary, secondary, and tertiary stages of syphilis may imply the oral cavity, and the mouth results the main extra-genital site of primary syphilis.⁸ In particular, oral manifestations are observed at the site of penetration of the *T. pallidum* into the mucosa; in the secondary stage, oral manifestations are much more variable and may show a vast number of different features such as painless mucous patches covered by grayish pseudomembranes and surrounded by erythema, aphthous ulcers, irregularly shaped lesions with whitish edges distributed on the oral mucosa (tongue, soft palate, and lips above all) and oropharynx.^{7,9} Sometimes the lesions can appear as leukokeratosis or there is an overlying gray or silver membrane.^{10,11} Usually, the spirochetemia of secondary syphilis is associated with systemic symptoms, so a concomitant cutaneous eruption is present.¹¹ Prior descriptions suggest that these lesions usually heal from 3 to 12 weeks regardless of treatment.

Diagnostic histological features of secondary syphilis are characterized by endothelial cell swelling, perivascular infiltrates of plasma cells, and epidermal psoriasiform hyperplasia.¹² The diagnosis of secondary syphilis is of the uttermost importance; since any time it is undiagnosed and consequently untreated, it will undergo spontaneous resolution; but in future, a life-threatening tertiary syphilis may eventually ensue. That is the reason why all unexplained oral lesions should be investigated for syphilis.

We present this case report for the atypical and unusual presentation of secondary syphilis with oral lesions in the absence of skin eruption or any other sign or symptoms, remarking upon the fact that this uncommon manifestation led us to a misdiagnosis, postponing an adequate therapy. When oral manifestations are accompanied by a concomitant cutaneous eruption or other symptoms, the diagnosis of syphilis could be easily supposed, but in cases of isolated oral manifestations such as white and ulcerative lesions, or asymptomatic infiltrated plaques, the diagnosis of secondary syphilis should be considered; in these cases, a diagnostic and therapeutic algorithm can be a useful tool to guide the clinician to a correct and faster diagnosis.

Declaration of conflicting interests

The author(s) declared no potential conflicts of interest with respect to the research, authorship, and/or publication of this article.

Funding

The author(s) received no financial support for the research, authorship, and/or publication of this article.

ORCID iD

Valeria Pietropaolo  <https://orcid.org/0000-0001-5723-8886>

References

1. World Health Organization (WHO) (2016) WHO guidelines for the treatment of *Treponema pallidum* (syphilis), <https://www.who.int/reproductivehealth/publications/rtis/syphilis-treatment-guidelines/en/> (accessed 7 December 2018).
2. Workowski KA and Bolan GA; Centers for Disease Control and Prevention (2015) Sexually transmitted diseases treatment guidelines, 2015. *Morbidity and Mortality Weekly Report (MMWR) Recommendations and Reports* 64: 1–137.
3. Janier M, Hegyi V, Dupin N, et al. (2014) 2014 European guideline on the management of syphilis. *Journal of the European Academy of Dermatology and Venereology* 28: 1581–1593.
4. Carlesimo M, Palese E, Mari E, et al. (2008) Isolated oral erosions: An unusual manifestation of secondary syphilis. *Dermatology Online Journal* 14(2): 23.
5. Peeling RW, Mabey D, Kamb ML, et al. (2017) Syphilis. *Nature Reviews Disease Primers* 3: 17073.
6. De Paulo LF, Servato JP, Oliveira MT, et al. (2015) Oral manifestations of secondary syphilis. *International Journal of Infectious Diseases* 35: 40–42.
7. Liu XK and Li J (2017) Secondary syphilis-related oral mucous patches. *IDCases* 9: 34–35.
8. Eyer-Silva WA, Leite Freire MA, Horta-Araujo CA, et al. (2017) secondary syphilis presenting as glossodynia, plaques en prairie fauchée, and a split papule at the oral commissure: Case report and review. *Case Reports in Medicine* 2017: 1980798.
9. Ficarra G and Carlos R (2009) Syphilis: The renaissance of an old disease with oral implications. *Head Neck Pathology* 3(3): 195–206.
10. Junkins-Hopkins JM (1996) Multiple painful oral ulcerations. Secondary syphilis. *Archives of Family Medicine* 5(7): 379–380.
11. Mani NJ (1984) Secondary syphilis initially diagnosed from oral lesions. Report of three cases. *Oral Surgery, Oral Medicine, and Oral Pathology* 58(1): 47–50.
12. Little JW (2005) Syphilis: An update. *Oral Surgery, Oral Medicine, and Oral Pathology, Oral Radiology, and Endodontics* 100(1): 3–9.