



OPEN ACCESS

Review article

Transcatheter aortic valve implantation

Thomas M Snow, Neil Moat, Sarah Barker, Alison Duncan, Carlo Di Mario*

Cardiovascular Biomedical Research
Unit, Royal Brompton Hospital, London,
UK

*Email: C.DiMario@rbht.nhs.uk

BACKGROUND AND INTRODUCTION

Aortic valve (AV) disease is a common condition with its prevalence, particularly aortic stenosis increasing exponentially with advancing age. A decade ago conventional aortic valve replacement (AVR) was the only treatment when medical management failed and symptoms developed. More than half of the patients potentially eligible for surgery have coexistent conditions making them unsuitable or very high-risk candidates. Balloon aortic valvuloplasty had too rapid a rate of restenosis to make it a viable long-term alternative [1,2]. It was therefore occasionally used as a bridge or test to assess suitability for AVR in patients with severe but potentially reversible left ventricular (LV) dysfunction or comorbidities [3].

Transcatheter aortic valve implantation (TAVI) has grown massively over the last 8–9 years after the first-in-man implantation performed by Alain Cribier in France in 2002 [4]. Since that time two valve technologies have been developed commercially, the balloon-expandable Edwards-SAPIEN System and Medtronic's CoreValve Revalving System. At the time of writing more than 40,000 aortic valve implants have been performed worldwide and a nearly exponential increase is expected after the FDA granted approval to the first system based on the results of the PARTNER trial.

This US-based trial concluded in 2009, with a one-year follow-up for the comparison of patients judged inoperable by two surgeons because of an expected operative mortality of 50% (PARTNER Cohort B). Medical management often included palliative balloon valvuloplasty, but was still grossly inferior to TAVI at 6–12 months, despite the use in the trial of a very large introduction sheath of 24 Fr. The same device was tested via a transfemoral or transapical route against conventional surgery in high-risk surgical candidates and found to be equivalent in terms of mortality to surgical AVR (PARTNER Cohort A) [5,6]. Ongoing trials (PARTNER 2, SURTAVI) are examining its application in lower risk patient populations, in whom surgical AVR is possible, but carries moderately higher risk. Questions regarding the durability of the implanted valves and a higher incidence of aortic valve insufficiency, pacemaker implantation, vascular complications and, possibly, stroke [7] discourages the use of this technology in low-risk surgical candidates. However, these limitations can potentially be overcome if the favourable long-term results already reported at five years are maintained and improvements in the technology (embolic filters, further catheter miniaturisation, sealing mechanisms for paravalvular leaks) reduce these complications. The introduction of TAVI has already changed the surgical approach to end-stage valve disease and increased the appeal of the use of bioprostheses which offer an ideal anchoring mechanism to transcatheter valves in case of degenerative change. Whilst TAVI was developed originally for treating severe symptomatic aortic stenosis its application has been extended to patients with aortic stenosis or regurgitation (AR) and failing aortic bioprostheses [8–11].

PATIENT SELECTION AND SCREENING

Patient selection is probably the most important aspect in the application of this technology. Ideally the selection should identify patients with comorbidities making the surgical risk so high and the recovery so slow, to warrant this alternative treatment, but also offer sufficient elements to exclude patients with severe neurological degenerative diseases or other comorbidities making their life

[http://dx.doi.org/
10.5339/gcsp.2012.12](http://dx.doi.org/10.5339/gcsp.2012.12)

Published: 30 August 2012
© 2012 Snow et al., licensee
Bloomsbury Qatar Foundation
Journals. This is an open access
article distributed under the terms
of the Creative Commons
Attribution-NonCommercial license
CC BY-NC 3.0 which permits
unrestricted non-commercial use,
distribution and reproduction in
any medium, provided the original
work is properly cited.

expectancy and future quality of life so poor as to make TAVI futile. Since the decision potentially affects the patient's life expectancy, a multidisciplinary team involving geriatricians, neurologists, oncologists and other specialists with full direct knowledge of clinical history, physical examination and test results should be involved. The subsequent paragraphs will mainly cover the tests required for deciding the suitability and best access route for TAVI, but it is important to understand that this technical decision comes second, once it is clear that the valve disease is responsible for the patient's symptoms, warrants treatment and is not contraindicated by prohibitive comorbidities.

PRE-PROCEDURAL INVESTIGATIONS

Transthoracic echocardiography (TTE)

Essential to confirm the presence and severity of aortic stenosis, the TTE also determines LV systolic function (a prognostic marker for both surgical AVR and TAVI), the presence of concomitant mitral regurgitation and pulmonary hypertension. In cases of “*low flow, low gradient*” aortic stenosis there is a role for low-dose dobutamine stress echocardiography. This can distinguish a truly stenotic valve causing secondary dysfunction from one that opens poorly as a consequence of low cardiac output and does not increase its gradient when the output increases (increase in LV outflow tract velocity without increase in maximal transvalvular velocity with a consequent increase in aortic valve area measured using the continuity equation). Another piece of important information provided, but often requiring higher dobutamine doses, is the development of regional wall motion changes, preventing further increase in gradient and output pointing to the presence and location of severe coexistent coronary artery disease (CAD). This pharmacological stress does however carry a risk in patients with stenotic aortic valves.

Electrocardiogram (ECG)

An abnormal ECG with evidence of LV hypertrophy is the norm in high grade aortic stenosis. However, especially in older patients, the ECG changes can occasionally be minimal. A long PR interval and a prolonged ventricular activation with a pattern of left bundle branch block or left anterior hemiblock and right bundle branch block can identify patients at risk of high-grade atrioventricular (AV) block and QRS prolongation with valve implantation.

The observed incidence of permanent pacemaker (PPM) implantation is higher with the self-expanding prosthesis at between 25–40% vs <10% with balloon expandable prosthesis and <5% after surgical AVR [12–14]. This is likely attributable to compression of conduction tissue in the LV outflow tract due to its comparatively low implant position, leading to atrioventricular conduction abnormalities. An association has been documented between pre-procedural right bundle branch block, reduced interventricular septal thickness, depth of CoreValve prosthesis within the LV outflow tract and increased PPM implantation [13].

Pulmonary function tests

Formal spirometry, diffusion coefficients and arterial blood gases help quantify respiratory reserve, which can influence both anaesthetic and procedural risk, and the need for a prolonged respiratory wean and rehabilitation following implant. Trans-apical and trans-aortic implantation can increase the risk of pulmonary complications dependent upon the anatomical position of the aorta and its accessibility to cannulation. Concomitant parenchymal lung disease can be the deciding factor in favour of transcatheter valve intervention rather than surgical AVR.

Routine blood tests

First described in the 1950s, *Heydes Syndrome* is the uncommon association postulated between aortic stenosis and gastrointestinal bleeding. Angiodysplasia can be demonstrated in some patients on endoscopy, whilst acquired *von Willebrand Factor* deficiency and mucosal fragility has been suggested as the underlying mechanism for blood loss. Microcytic hypochromic anaemia must therefore be carefully investigated in the presence of aortic valve stenosis. Treating the anaemia alone may provide sufficient symptomatic relief from dyspnoea and angina to require a reappraisal of the appropriateness of intervention.

Chronic renal impairment, or acute deterioration as a result of forced diuresis to treat cardiac failure may complicate the use of intravenous contrast for both diagnostic angiography and multidetector computed tomography (MDCT) imaging. There is a risk of post-implant acute kidney injury from both

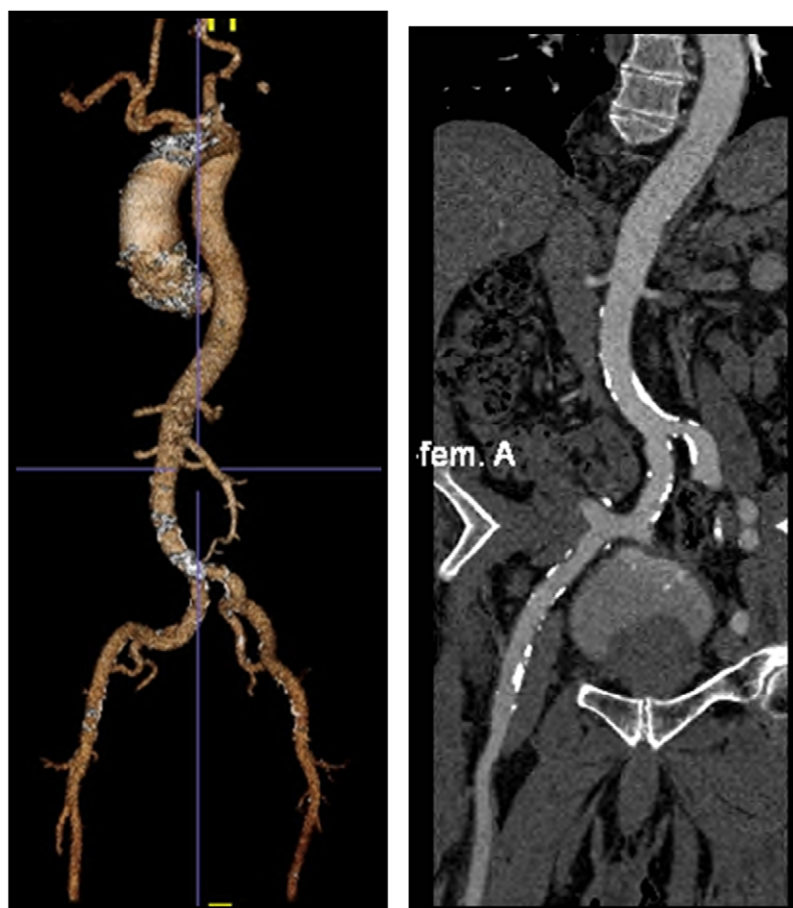


Figure 1. Contrast enhanced MDCT assessment of peripheral vasculature. Left: Volume-rendered image of the whole aorta. Mild tortuosities in both iliofemoral arteries with only mild calcification. Right: Curved multi-planar reformed image of the right femoral artery. Mild calcification with minimal size of 9 mm, which is favourable for transfemoral approach.

contrast induced nephropathy and embolic phenomena [15] and the need for renal replacement therapy is increased. This needs to be considered by the multi-disciplinary team. In general, however, the risk post-TAVI is lower than after surgical AVR.

Brain natriuretic peptide (BNP/NT Pro-BNP) increases with myocardial wall stress and supports clinical and echocardiographic measures of ventricular dysfunction. An elevated BNP or, better, elevation of BNP in serial measurements supports the presence of a cardiac cause for dyspnoea in patients with concomitant lung and cardiac insufficiency.

Multi-detector computed tomography

MDCT provides information on vascular access, aortic valve annular size, aortic root and valve calcification and angulation [16–18]. The course of patent left internal mammary arterial (LIMA) grafts in patients with previous surgical revascularization can be demonstrated, an important element to plan redo surgery because re-sternotomy can jeopardise such vessels if they are medial, or adherent to the sternum.

In some cases incidental pathology (e.g. parenchymal lung disease, malignancy) is identified. The latter can impact procedural risk and the decision making process of the multi-disciplinary team.

Vascular access: In patients with degenerative aortic valve stenosis extensive peripheral atheroma, often calcific, is extremely common and the incidence of significant luminal narrowing, aneurysmal dilatation and vessel tortuosity often complicates peripheral access. To image the vascular tree, intravenous contrast enhanced MDCT is essential and has fully replaced conventional angiography, limited by its inability to detect highly eccentric lesions and assess the amount of calcification and

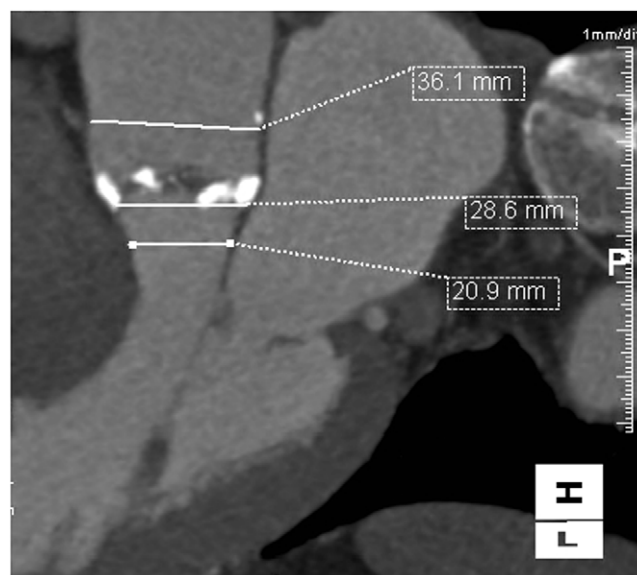


Figure 2. LVOT view of aortic annulus. Calcium nodules at the annulus with annular dimension of 28.6 mm (the other dimension not here shown is 29 mm), patient eventually had a 31 mm CoreValve® device implanted.

tortuosity. Intravascular ultrasound is likewise limited by poor intra-abdominal visualisation. MDCT allows 3D and multiplanar reconstruction of the ilio-femoral vessels [19] and aorta (Fig. 1).

Transfemoral access is the usual preferred route for TAVI with 18 French introducer sheaths (16 French expandable for Edwards SAPIEN XT) used to access the ilio-femoral vessels.

Alternative approaches have been successfully employed in patients with unsuitable peripheral vasculature. Left (or, less often, right) subclavian access (Fig. 5) can be achieved via a surgical cut-down, giving the advantages of more precise valve manipulation by eliminating the tortuosities in the descending aorta and iliac arteries, particularly in those patients with more vertical aortic valve planes. The left subclavian approach is however relatively contraindicated in patients with a patent LIMA graft, a subclavian of less than 6 mm in diameter or severe calcification. The transaortic approach (Figs. 6, 7a and 7b) via a para-sternal incision, or hemi-sternotomy allows direct visualisation of the ascending aorta and facilitates a more co-axial approach to vertical valves [20–22]. Left axillary [23] and even carotid arterial approaches have also been used in select patients. Those patients with inadequate peripheral access and “*porcelain aorta*” can be treated with a transapical approach using Edwards-SAPIEN valves [24,25]. This approach carries its own specific complications (e.g. apical infarction or aneurysm).

Aortic annular measurement: Both implant technologies have sizing limitations (Fig. 3) and patients with small or very large valves cannot be treated with transcatheter intervention. A 23 mm CoreValve is due to be released in the second quarter of 2012 and offers hope to patients with truly small valves, a small but important minority of the potential candidates for TAVI. The exact site for measurement (e.g. distal LV outflow tract/ annular ring) and the best presentation of those measurements is still unclear. Perimeter/circumferential measurements, maximal dimensions (AP and lateral: Fig. 2) on MDCT and peri-procedural transesophageal echocardiography (TEE) are all used to guide implant sizing. Implant sizing impacts upon haemodynamics in the LV outflow tract and risk of paravalvular aortic insufficiency following deployment [19].

Patient-prosthesis mismatch has proven a significant problem in the TAVI cohort with increased post-implant valve gradients, poorer symptomatic response to treatment and reduced LV mass regression [26,27]. Accurate valve sizing is therefore of paramount importance.

Aortic valve angulation: Valve angulation can present technical challenges. Horizontal aorta and a vertical valve plane can complicate transfemoral and trans-subclavian approaches due to difficulties in transmitting force through the deployment catheters for final implant positioning. The more co-axial approach provided by the trans-aortic and trans-apical approaches can overcome such limitations.

Aortic valve/aortic root and ascending aortic calcification: Calcification is highly variable. True ‘*porcelain aorta*’ has implications for aortic cross-clamping in conventional AVR and potentially can

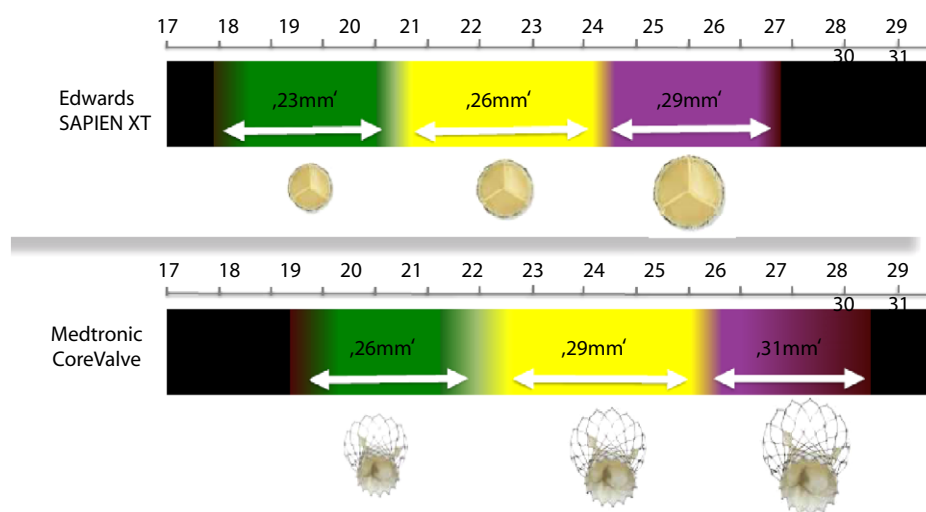


Figure 3. Commercially available TAVI devices. Above: Balloon-expandable Edwards SAPIEN/SAPIEN XT devices available in 23-mm, 26-mm and 29-mm, suitable for annulus sizes from 18–21 mm, 21–24 mm and 24–27-mm respectively. Below: Self-expanding CoreValve® devices available in 26-mm, 29-mm and 31-mm, suitable for annulus sizes from 20–23 mm, 23–27 mm and 26–29 mm.

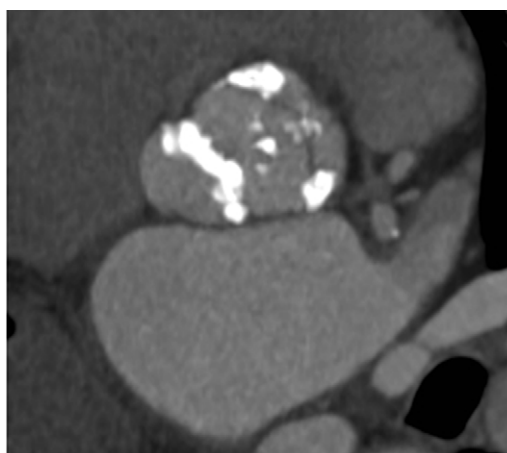

Figure 4. Aortic valve leaflet, annulus and root calcification on MDCT.

prevent a trans-aortic approach in TAVI candidates. However, the target for direct aortic approach, the upper ascending aorta below the origin of the innominate artery, is often relatively spared from calcium. The quantity, density and distribution of calcification often affects valve deployment and in some cases determines the need and aggressiveness of pre-implant balloon aortic valvuloplasty as well as post-implant balloon dilatation. Whilst some calcification in the valve leaflets can aid prosthesis positioning and stability, dense deposits can hinder implant expansion (Fig. 4). The severity of aortic annular and leaflet calcification has not been associated with increased post-procedural PPM implantation [14], but is a predictor of post-implant paravalvular aortic regurgitation [28]. Reduced aortic root calcification has conversely been demonstrated to be an independent predictor for peri-procedural prosthesis dislodgment [29].

Insufficient prosthesis expansion can result not only in dysfunctional leaflet coaptation and resultant transvalvular regurgitation, but also residual haemodynamically significant paravalvular regurgitation. Studies have shown post-procedural regurgitation to be a marker of poor outcome [30], and whilst the two technologies differ in their method of deployment all patients need to be imaged peri-procedurally to determine valve insufficiency. The self-expanding nitinol frame of the Medtronic CoreValve System continues to expand for up to 48 hours post-implantation and therefore mild para-prosthetic insufficiency may be abolished during the initial post-operative period. The

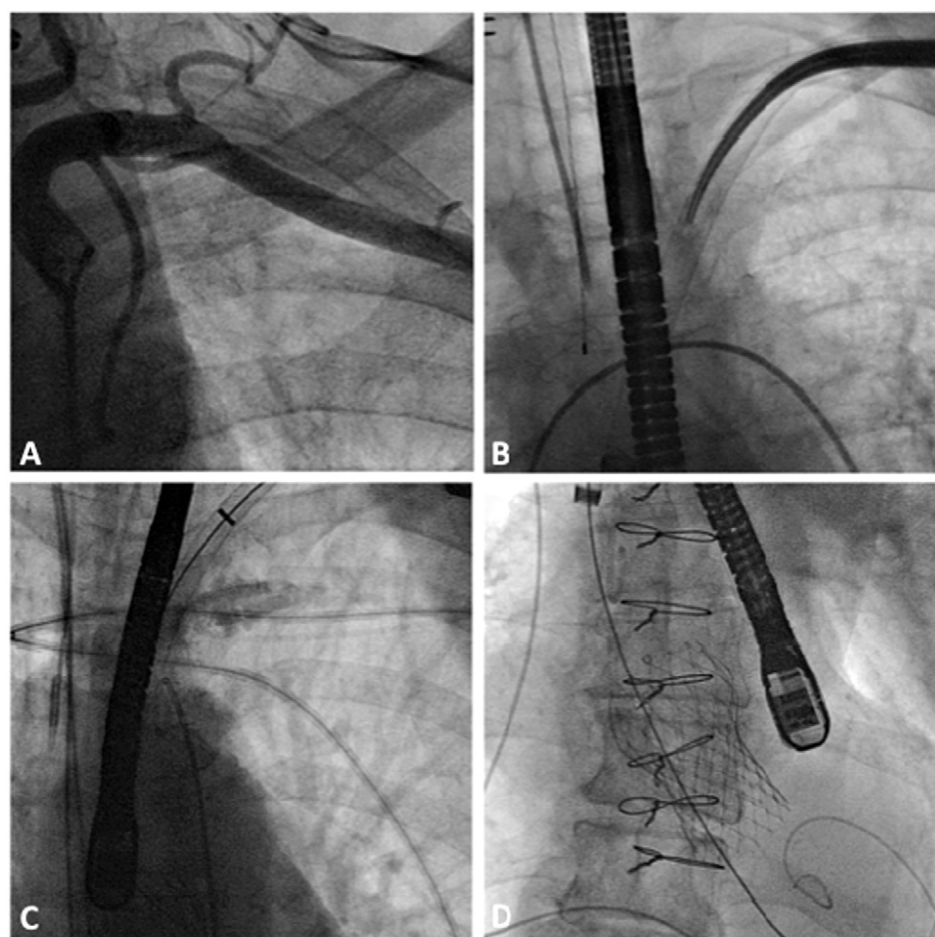


Figure 5. Fluoroscopic illustration of TAVI via. Left subclavian approach. A) Pre-operative angiogram of left subclavian artery using 5-Fr JR4 catheter inserted via right femoral artery. B) Insertion of 18-Fr introducer sheath under fluoroscopic guidance. C) Pigtail catheter inserted via right femoral artery to guide positioning of TAVI prosthesis. D) Full deployment of CoreValve[®] inserted via left subclavian arterial sheath on a stiff guidewire placed in the LV apex.

balloon-expandable system however does not exert radial force in the same manner and therefore significant aortic regurgitation (usually defined as moderate or severe) is likely to require re-intervention either immediately post-implant or soon thereafter.

Cardiac MRI (CMR)

Often confirmatory with regards to annular size, severity of valve disease and systolic function [31] it can also demonstrate the presence of LV or left atrial appendage thrombus, evidence of previous myocardial infarction and support the presence of myocardial viability (gadolinium-enhanced CMR).

Diagnostic coronary angiography

Concomitant coronary artery disease (CAD) is very common in this patient population, often due to their cardiovascular risk factor profile and age [32,33]. There is as yet little evidence to guide the management of CAD in this cohort, and whilst surgical AVR is often completed by bypass grafting at the same time, hybrid percutaneous coronary intervention (PCI)-TAVI procedures are rare. The operator or MDT often guides PCI based on the complexity of disease and the likely physiological significance of these stenoses. The use of drug-eluting stents vs bare metal stents once again is controversial with a balance of the risk of restenosis versus duration of dual anti-platelets and procedural bleeding risk. For those patients undergoing TAVI via transaortic/transapical approaches dual anti-platelet agents may increase the risk of bleeding. Evidence to support this is however anecdotal. Coronary intervention can be performed in a staged manner or during a hybrid TAVI-PCI

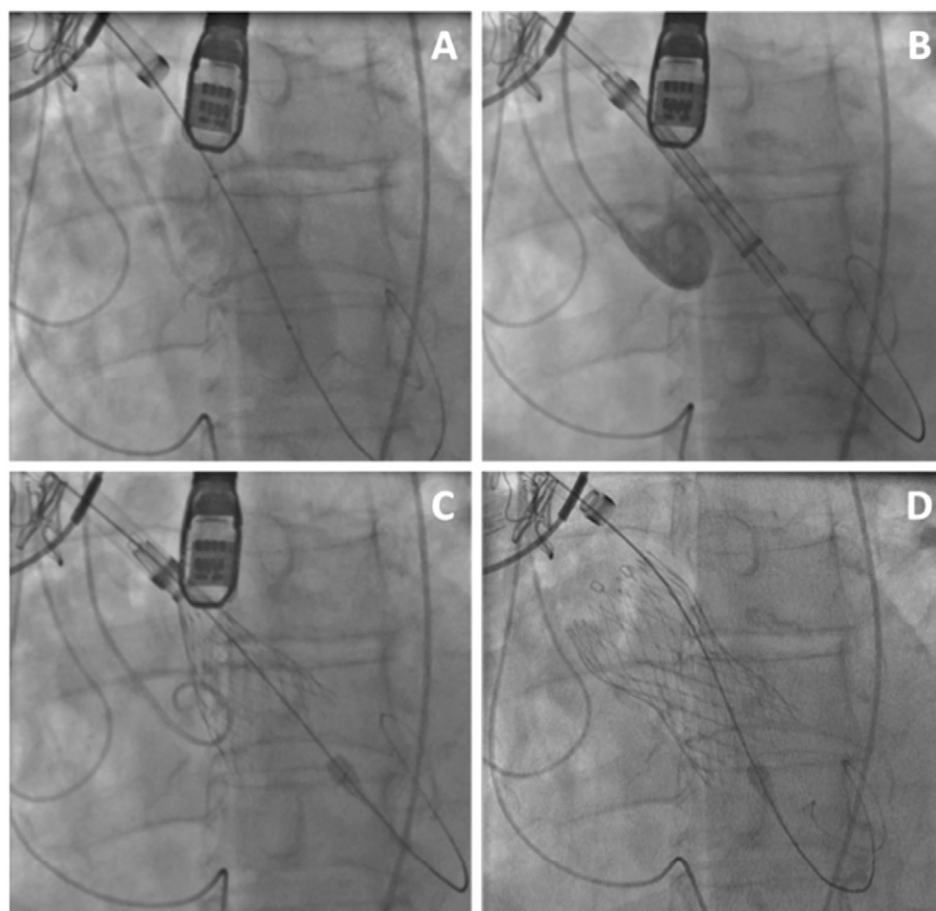


Figure 6. Fluoroscopic illustration of TAVI via direct aortic approach. A) Trans-aortic approach. Balloon aortic pre-dilatation under rapid right ventricular pacing. B) Self-expandable CoreValve[®] prosthesis aligned in pre-deployment position across aortic valve annulus into LVOT. Aortic injection demonstrates good position. C) CoreValve[®] two-thirds deployed. D) 18-Fr delivery sheath slightly withdrawn to facilitate full deployment of CoreValve[®].

procedure. The latter has proven to be technically feasible, but superior long-term outcomes have not been demonstrated. Sequential intervention to coronary stenoses and then the valve has proven feasible, but little evidence supports superior early to mid-term outcome measures.

Fluoroscopic images of the subclavian and ilio-femoral vessels can also be obtained at the time of diagnostic angiography, whilst radial diagnostic angiography spares the femoral arteries and the risk of vascular complication, if this is the proposed access route.

MDCT and diagnostic coronary angiography can provide information regarding the proximity of the coronary ostia to the aortic annulus. Low-lying ostia (≤ 14 mm) can exclude patients from implantation, due to the risk of coronary obstruction, by the valve 'skirt', or native valve leaflets on displacement with the prosthesis. This also needs to be considered in valve-in-valve implantation for failing bioprostheses. Technological advances are considering endovascular devices for native aortic valve leaflet resection, which would reduce the risk of coronary occlusion on valve deployment [34]. Such technologies are only in the early stage of development in cadaveric trials.

PROCEDURAL DETAILS

A multidisciplinary approach involving cardiac surgeons, interventional cardiologists, anaesthetists and imaging specialists are important in the hybrid cardiac catheterisation laboratory or theatre.

Outlined in the following algorithm are the procedural steps for both self-expanding and balloon expandable valve systems (shown in bold) in the deployment of a TAVI via a right transfemoral approach. Both systems share many similarities in the procedural approach, whilst the technique for valve positioning and deployment differ.

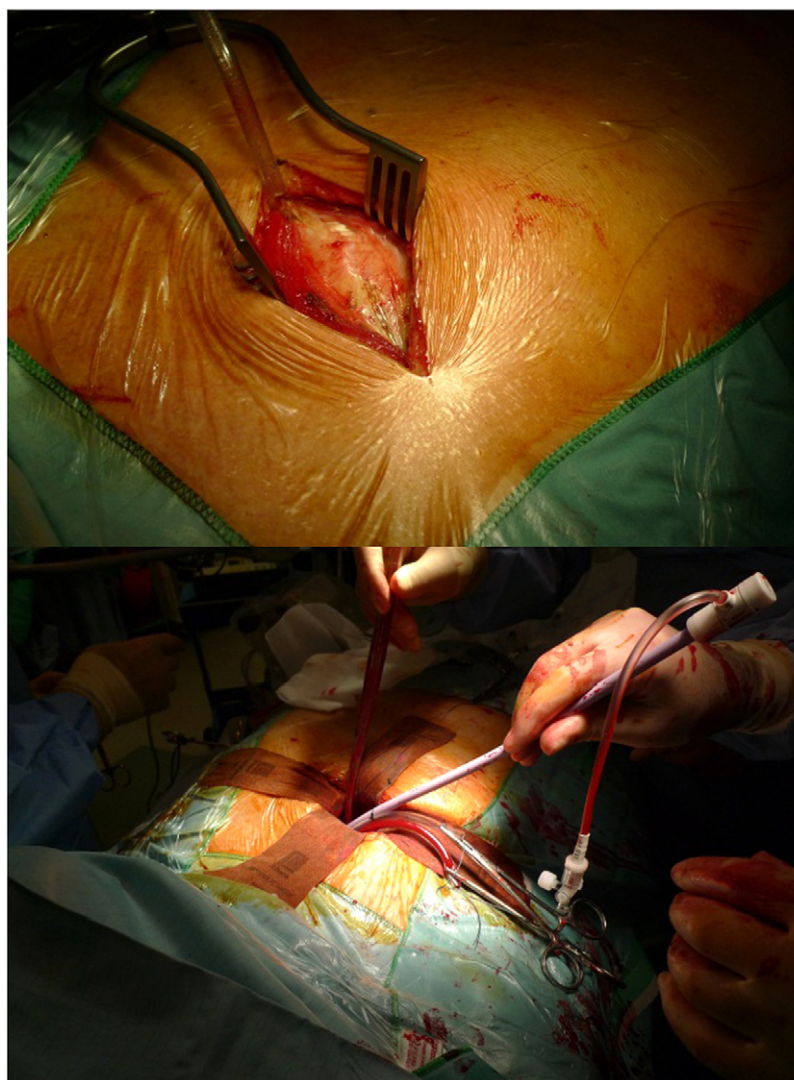


Figure 7a. Step-by-step TAVI via direct aortic approach. Top: Right upper parasternal mini-thoracotomy (second intercostal space) with excision of second intercostal cartilage. Bottom: Under direct visualisation, the ascending aorta is directly cannulated with 18-Fr Cook sheath.

Adaptations to the techniques outlined above may be made according to access route, operator preference and mode of anaesthesia. Whatever the approach, valve deployment remains the same.

Periprocedural imaging is often provided by fluoroscopy and TEE. The latter can confirm LV outflow tract and annular dimension (albeit in two dimensions) immediately pre-implantation, LV systolic function, implant positioning and can exclude cardiac perforation and cardiac tamponade [35]. It proves invaluable in the immediate assessment of post-implant aortic insufficiency and guides depth of implant, particularly important with the CoreValve prosthesis that lies within the LV outflow tract. A low-lying implant can hinder the motion of the anterior mitral valve leaflet leading to mal-coaptation and mitral regurgitation or more rarely stenosis.

Following implantation there is little evidence to support a specific anticoagulation/antiplatelet regimen. This can vary from unit to unit, mainly focused on either single or dual antiplatelet treatment, whilst coumarins tend not to be used unless for another indication. Single agent aspirin (75 mg once daily) is the most commonly used antiplatelet agent, with a period of clopidogrel (75 mg once daily) administration often used for 3–6 months following TAVI. The duration of either single or dual antiplatelet agents is highly variable and based on no clinical evidence at the present time. Obviously those patients with contemporaneous PCI would warrant the usual regime according to either bare metal or drug-eluting stent insertion.

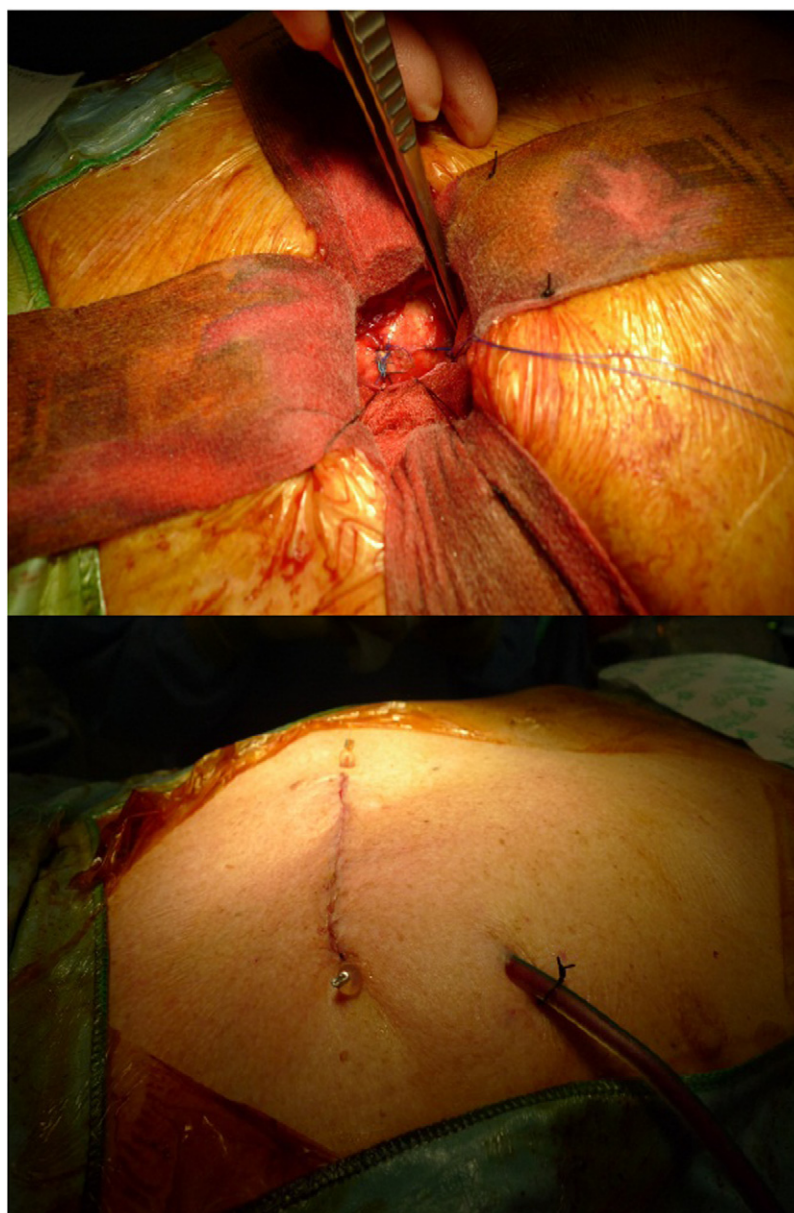


Figure 7b. Cont. Step-by-step TAVI via direct aortic approach. Top: Purse-string closure of sheath entry site with good haemostasis. Bottom: Wound closed in layers with drain left in-situ.

A steep learning curve has been seen since the advent of this technology. With increasing implant experience there has been a gradual reduction in peri-procedural complications and improved clinical outcomes [36]. At present there is a paucity of long-term outcome data and until we have this, expansion of such technology into a lower risk patient cohort is tentative. Patients demonstrating clinical equipoise between surgical intervention and transcatheter implantation now represent the forefront for TAVI [37]. Data from the PARTNER 2 and SURTAVI trials will prove central to how transcatheter technology evolves and in what patient cohort it should serve.

For those patients who are at prohibitively high surgical risk and technically/anatomically not suitable for TAVI then medical management and palliative care is the most appropriate therapeutic option.

Aortic stenosis is an inflammatory mediated process, similar to atherosclerosis, involving extra-cellular bone matrix proteins, lipids and inflammatory mediators. It is influenced by many cardiovascular risk factors, e.g. dyslipidaemia, hypertension, diabetes mellitus [38]. Initial results of retrospective, non-randomized trials of statin therapy in aortic stenosis looked promising, however

such results have not been borne out in subsequent randomized clinical trials [39]. Modifying the process of valve stenosis and calcium deposition has likewise been unaffected by studies using angiotensin receptor blockade and treatments for osteoporosis.

Vasodilators, including calcium channel blockers, nitrates, ACE inhibitors and angiotensin II receptor blockers all increase the risk of sudden cardiac death. Many are however the mainstay of medical management for CAD, LV impairment and anginal chest pain or dyspnoea (as an angina equivalent).

Anti-anginals often disturb haemodynamics with vasodilatation, unfavourable in individuals with severe aortic stenosis. The metabolic agent ranolazine has been used in such patients for relief of chest pain (in the absence of significant CAD), without haemodynamic compromise [40].

At this current time the medical management of aortic stenosis, and measures to prevent disease progression are limited. Modifying risk factors and a greater understanding of its pathophysiology may hold promise for the future in those patients who have no other therapeutic option.

The outcome for patients with aortic stenosis and conservative management is poor, even with the use of balloon aortic valvuloplasty (PARTNER B cohort). Pharmacological interventions have not improved long-term prognosis with a two-year mortality readily quoted at 50%. Recurrent hospital admissions and increasing symptom burden is often seen in the terminal stages and therefore the early involvement of the palliative care team and support in the community is essential.

References

- [1] Di Mario C, Beatt K and Serruys PW et al. Aortic balloon valvuloplasty: a treatment sine cura?. *British Heart Journal*. 1988;
- [2] Daly MJ, Monaghan M, Hamilton A, Lockhart C, Kodoth V, Pillai S, Manoharan G and Spence MS. Short-term efficacy of palliative balloon aortic valvuloplasty in selected patients with high operative risk. *Journal of Invasive Cardiol*. 2012 Feb;24:2, 58–62.
- [3] Saia F, Marrozzini C and Moretti C et al. The role of percutaneous balloon aortic valvuloplasty as a bridge for transcatheter aortic valve implantation. *EuroIntervention*. 2011;7:723–729.
- [4] Cribier A, Eltchaninoff H and Bash A et al. Percutaneous transcatheter implantation of an aortic valve prosthesis for calcific aortic stenosis: first human case description. *Circulation*. 2002;106:3006–3008.
- [5] Leon MB, Smith CR and Mack M et al. Transcatheter aortic-valve implantation for aortic stenosis in patients who cannot undergo surgery. *N Eng J Med*. 2010;363:1597–1607.
- [6] Smith CR, Leon MB and Mack MJ et al. Transcatheter versus surgical aortic-valve replacement in high-risk patients. *N Engl J Med*. 2011;364:2187–2198.
- [7] Szeto WY, Augoustides JG, Desai ND, Moeller P, McGarvey ML, Walsh E, Bannan A, Herrmann HC and Bavaria JE. Cerebral embolic exposure during transfemoral and transapical transcatheter aortic valve replacement. *J Card Surg*. 2011 Jul;26:4, 348–354.
- [8] Gurvitch R, Cheung A and Ye J et al. Transcatheter valve-in-valve implantation for failed surgical bioprosthetic valves. *J Am Coll Cardiol*. 2011;58:2196–2209.
- [9] Piazza N, Bleiziffer S and Brockmann G et al. Transcatheter aortic valve implantation for failing surgical aortic bioprosthetic valve: from concept to clinical application and evaluation. *JACC Cardiovasc Interv*. 2011;4:721–742.
- [10] Chan PH, Di Mario C and Davies SW et al. Transcatheter aortic valve implantation in degenerate failing aortic homograft root replacements. *J Am Coll Cardiol*. 2011;58:1729–1730.
- [11] Latib A, Ielasi A, Montorfano M, Maisano F, Chieffo A, Cioni M, Mussardo M, Bertoldi L, Shannon J, Sacco F, Covelto RD, Figini F, Godino C, Grimaldi A, Spagnolo P, Alfieri O and Colombo A. Transcatheter valve-in-valve implantation with the Edwards SAPIEN in patients with bioprosthetic heart valve failure: the Milan experience. *EuroIntervention*. 2012 Jan 26;pii: 20120109-00. [Epub ahead of print].
- [12] Nuis RJ, Van Mieghem NM and Schultz CJ et al. Timing and potential mechanisms of new conduction abnormalities during the implantation of the Medtronic CoreValve System in patients with aortic stenosis. *Eur Heart J*. 2011;32:2067–2074.
- [13] Saia F, Lemos PA, Bordoni B, Cervi E, Boriani G, Ciuca C, Taglieri N, Mariani Jr J, Filho RK and Marzocchi A. Transcatheter aortic valve implantation with a self-expanding nitinol bioprosthesis: Prediction of the need for permanent pacemaker using simple baseline and procedural characteristics. *Catheter Cardiovasc Interv*. 2011 Nov 22;doi:10.1002/ccd.23336 [Epub ahead of print].
- [14] Koos R, Mahnken AH, Aktug O, Dohmen G, Autschbach R, Marx N and Hoffmann R. Electrocardiographic and imaging predictors for permanent pacemaker requirement after transcatheter aortic valve implantation. *J Heart Valve Dis*. 2011 Jan;20:1, 83–90.
- [15] Madershahian N, Scherner M, Liakopoulos O, Rahmanian P, Kuhn E, Hellmich M, Mueller-Ehmsen J and Wahlers T. Renal impairment and transapical aortic valve implantation: impact of contrast medium dose on kidney function and survival. *Eur J Cardiothorac Surg*. 2011 Dec 26;[Epub ahead of print].
- [16] Leipsic J, Gurvitch R and Labounty TM et al. Multidetector computed tomography in transcatheter aortic valve implantation. *JACC Cardiovasc Imaging*. 2011;4:416–429.
- [17] Gurvitch R, Webb JG and Yuan R et al. Aortic annulus diameter determination by multidetector computed tomography: reproducibility, applicability, and implications for transcatheter aortic valve implantation. *JACC Cardiovasc Interv*. 2011;4:1235–1245.

- [18] Jabbour Am, Ismail TF and Moat N et al. Multimodality imaging in transcatheter aortic valve implantation and post-procedural aortic regurgitation: comparison among cardiovascular magnetic resonance, cardiac computed tomography, and echocardiography. *J Am Coll Cardiol*. 2011;58:2165–2173.
- [19] Schoenhagen P, Tuzcu EM, Kapadia SR, Desai MY and Svensson LG. Three-dimensional imaging of the aortic valve and aortic root with computed tomography: new standards in an era of transcatheter valve repair/implantation. *Eur Heart J*. 2009 Sep;30:17, 2079–2086.
- [20] Bruschi G, De Marco F and Fratto P et al. Alternative approaches for trans-catheter self-expanding aortic bioprosthetic valves implantation: single-center experience. *Eur J Cardiothorac Surg*. 2011;39:e151-8.
- [21] Moat N, Laborde JC and Bruschi G et al. European experience of direct aortic TAVI with a self-expanding prosthesis. *Society of Thoracic Surgeons Annual Conference*; January 30, 2012; Ft Lauderdale, FL.
- [22] Bapat V, Khawaja MZ, Attia R, Narayana A, Wilson K, Macgillivray K, Young C, Hancock J, Redwood S and Thomas M et al. Transaortic transcatheter aortic valve implantation using edwards sapien valve: A Novel Approach. *Catheter Cardiovasc Interv*. 2011 Jul 29;doi:10.1002/ccd.23276 [Epub ahead of print].
- [23] De Robertis F, Asgar A, Davies S, Delahunty N, Kelleher A, Trimlett R, Mullen M and Moat N. The left axillary artery—a new approach for transcatheter aortic valve implantation. *Eur J Cardiothorac Surg*. 2009 Nov;36:5, 807–812.
- [24] Kempfert J, Rastan A and Holzhey D et al. Transapical aortic valve implantation: analysis of risk factors and learning experience in 299 patients. *Circulation*. 2011;124:S124-9.
- [25] Unbehaun A, Pasic M and Dreyse S et al. Transapical aortic valve implantation incidence and predictors of paravalvular leakage and transvalvular regurgitation in a series of 358 patients. *J Am Coll Cardiol*. 2012;59:211–221.
- [26] Ewe SH, Muratori M, Delgado V, Pepi M, Tamborini G, Fusini L, Klautz RJ, Gripari P, Bax JJ, Fusari M, Schaliij MJ and Marsan NA. Hemodynamic and clinical impact of prosthesis-patient mismatch after transcatheter aortic valve implantation. *J Am Coll Cardiol*. 2011 Oct 25;58:18, 1910–1908.
- [27] Kukucka M, Pasic M, Dreyse S, Mladenow A, Habazettl H, Hetzer R and Unbehaun A. Patient-prosthesis mismatch after transapical aortic valve implantation: Incidence and impact on survival. *J Thorac Cardiovasc Surg*. 2012 Feb 11;[Epub ahead of print].
- [28] Haensig M, Lehmkuhl L, Rastan AJ, Kempfert J, Mukherjee C, Gutberlet M, Holzhey DM and Mohr FW. Aortic valve calcium scoring is a predictor of significant paravalvular aortic insufficiency in transapical-aortic valve implantation. *Eur J Cardiothorac Surg*. 2012 Jan 12;[Epub ahead of print].
- [29] Van Mieghem NM, Schultz CJ, van der Boon RM, Nuis RJ, Tzikas A, Geleijnse ML, van Domburg RT, Serruys PW and de Jaegere PP. Incidence, timing, and predictors of valve dislodgment during TAVI with the medtronic corevalve system. *Catheter Cardiovasc Interv*. 2011 Jul 29;doi:10.1002/ccd.23275 [Epub ahead of print].
- [30] Moat NE, Ludman P and de Belder MA et al. Long-term outcomes after transcatheter aortic valve implantation in high-risk patients with severe aortic stenosis: the U.K. TAVI (United Kingdom Transcatheter Aortic Valve Implantation) Registry. *J Am Coll Cardiol*. 2011;58:2130–2138.
- [31] Paelinck BP, Van Herck PL, Rodrigus I, Claeys MJ, Laborde JC, Parizel PM, Vrints CJ and Bosmans JM. Comparison of magnetic resonance imaging of aortic valve stenosis and aortic root to multimodality imaging for selection of transcatheter aortic valve implantation candidates. *Am J Cardiol*. 2011 Jul 1;108:1, 92–98.
- [32] Abdel-Wahab M, Mostafa AE and Geist V et al. Comparison of outcomes in patients having isolated transcatheter aortic valve implantation versus combined with preprocedural percutaneous coronary intervention. *Am J Cardiol*. 2012;109:581–586.
- [33] Wenaweser P, Pilgrim T and Guerios E et al. Impact of coronary artery disease and percutaneous coronary intervention on outcomes in patients with severe aortic stenosis undergoing transcatheter aortic valve implantation. *EuroIntervention*. 2011;7:541–548.
- [34] Astarci P, Glineur D, Elkhoury G and Raucen B. A novel device for endovascular native aortic valve resection for transapical transcatheter aortic valve implantation. *Interact Cardiovasc Thorac Surg*. 2012 Jan 9;[Epub ahead of print].
- [35] Bagur R, Rodés-Cabau J and Doyle D et al. Usefulness of TEE as the primary imaging technique to guide transcatheter transapical aortic valve implantation. *JACC Cardiovasc Imaging*. 2011;4:115–124.
- [36] Gurvitch R, Tay EL, Wijesinghe N, Ye J, Nietlispach F, Wood DA, Lichtenstein S, Cheung A and Webb JG. Transcatheter aortic valve implantation: lessons from the learning curve of the first 270 high-risk patients. *Catheter Cardiovasc Interv*. 2011 Dec 1;78:7, 977–984.
- [37] Lange R, Bleiziffer S and Mazzitelli D et al. Improvements in transcatheter aortic valve implantation outcomes in lower surgical risk patients a glimpse into the future. *J Am Coll Cardiol*. 2012;59:280–287.
- [38] Dimitrow PP, Jawien M and Rajtar-Salwa R. Pharmacotherapy of aortic stenosis - success or failure?. *Curr Pharm Biotechnol*. 2012 Jan 20;[Epub ahead of print].
- [39] Teo KK, Corsi DJ, Tam JW, Dumesnil JG and Chan KL. Lipid lowering on progression of mild to moderate aortic stenosis: meta-analysis of the randomized placebo-controlled clinical trials on 2344 patients. *Can J Cardiol*. 2011 Nov;27:6, 800–808. Epub 2011 Jul 13.
- [40] Athauda-Arachchi P and Lang C. Metabolic Antianginal Agent Ranolazine Offers Good Symptom Relief in a Patient with Inoperable Severe Aortic Stenosis. *Cardiovasc Ther*. 2011 May 25;