

# *Enterococcus faecalis* Endocarditis After Endoscopic Mucosal Resection of a Large Sessile Colonic Polyp

Antonios Wehbeh, MD<sup>1</sup>, Myron C. Gerson, MD<sup>2</sup>, and Douglas K. Rex, MD<sup>1</sup>

<sup>1</sup>Division of Gastroenterology, Department of Medicine, Indiana University School of Medicine, Indianapolis, IN

<sup>2</sup>Division of Cardiology, Department of Internal Medicine, University of Cincinnati, Cincinnati, OH

## ABSTRACT

A 71-year-old man with mitral regurgitation and apical cardiomyopathy underwent endoscopic mucosal resection of a 22-mm transverse colon tubulovillous adenoma with high-grade dysplasia. Six weeks later, he presented with fever, valvular vegetations, and positive blood cultures for *Enterococcus faecalis*. To our knowledge, this is the first reported case of endocarditis involving native heart valves after endoscopic mucosal resection.

## INTRODUCTION

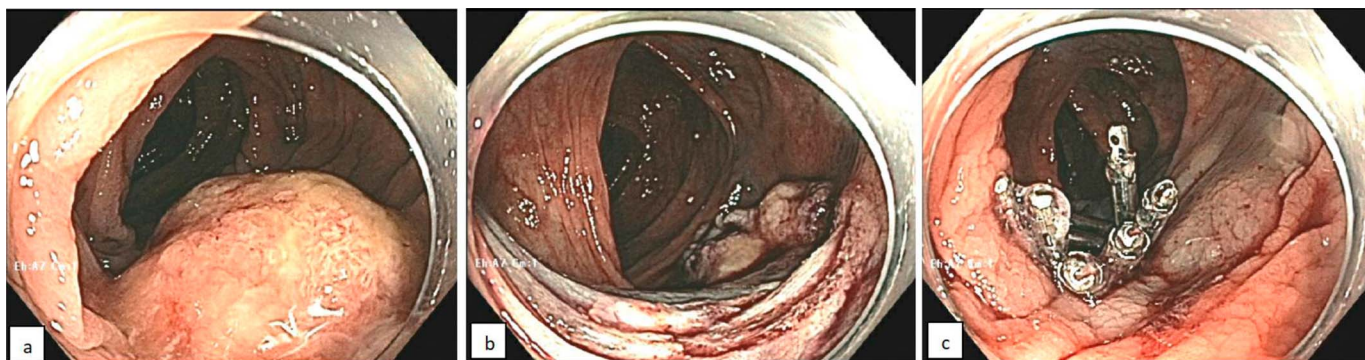Endoscopic mucosal resection (EMR) is commonly used to remove large (>20 mm) colon polyps. Common adverse events include bleeding, postpolypectomy syndrome, and perforation. We report a rare case of infective endocarditis that appears related to EMR of a large colon polyp.

## CASE REPORT

A 71-year-old man with no gastrointestinal symptoms, was referred for resection of a large sessile transverse colon polyp. He had hypertension, atrial fibrillation, apical hypertrophic cardiomyopathy, mitral regurgitation, and pulmonary hypertension. He had been advised to use prophylactic antibiotics for dental procedures. He was anticoagulated with rivaroxaban, which was discontinued 3 days before colonoscopy.

A 22-mm sessile polyp was found in the transverse colon with a tattoo on the opposite wall (Figure 1). There was exudate on the polyp surface, but after washing, the vascular and surface patterns appeared intact. Hydroxyethyl starch with indigo carmine was injected submucosally to lift the lesion. Piecemeal snare resection with electrocautery was performed, followed by snare tip soft coagulation of the normal-appearing edges of the EMR defect. Hemostatic clips were placed to prevent postpolypectomy bleeding (Figure 1). The patient restarted rivaroxaban, and there were no immediate postendoscopy complications. Pathologic examination revealed tubulovillous adenoma with high-grade dysplasia.

Six weeks after resection, he presented with back pain for 1 week, fever for 2 days reaching 38.8°C, and anorexia. He was hemodynamically stable, with an irregular rhythm and a loud systolic murmur. His white blood cell count was  $11 \times 10^3/\mu\text{L}$ , erythrocyte sedimentation rate 92 mm/hr, and C-reactive protein 113 mg/L. Urinalysis was normal. A chest radiograph showed pulmonary edema. No infection source was found on abdominal and pelvic contrast-enhanced computed tomography or on spinal magnetic resonance imaging. Multiple sets of blood cultures grew *Enterococcus faecalis*. Transthoracic echocardiogram showed possible vegetations on the mitral and tricuspid valves, and a transesophageal echocardiogram confirmed the presence of a vegetation (0.9 cm  $\times$  0.8 cm) on the anterior leaflet of the mitral valve and another (0.9  $\times$  0.5 cm) on the septal tricuspid valve leaflet (Figure 2). Left and right ventricular systolic functions were preserved. Repeat blood cultures became negative after a few days of antibiotics, and he was discharged to complete a 6-week course of intravenous ceftriaxone and ampicillin. A repeat



**Figure 1.** Colonoscopy showing (A) transverse colon polyp before resection, (B) the site after resection and snare tip soft coagulation of the edges, and (C) clips deployed at the resection site.

echocardiogram after antibiotics showed resolution of the vegetations. Six months later, repeat colonoscopy after prophylactic amoxicillin revealed clip artifact on the EMR site but no evidence of residual polyp or cancer by inspection or biopsy.

## DISCUSSION

*Enterococcus* is the third most common cause of infective endocarditis of both native and prosthetic valves; however, there is no known association between endoscopic procedures and *Enterococcus* endocarditis.<sup>1</sup> A recent guideline by the American Society of Gastrointestinal Endoscopy emphasizes that the American Heart Association does not recommend giving antibiotic prophylaxis before endoscopic procedures.<sup>2</sup> Data on bacteremia or endocarditis after EMR are very limited, and antibiotic prophylaxis is not considered necessary.<sup>3</sup>

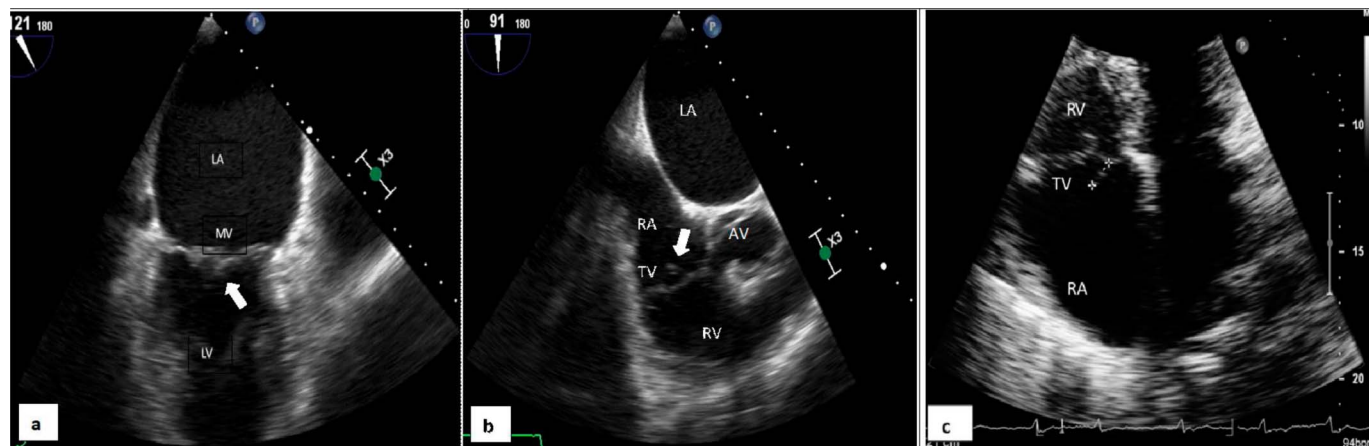
Approximately 25 cases of infective endocarditis have been reported in association with an endoscopic procedure, a few being due to *Enterococcus* species.<sup>2,4</sup> To our knowledge, this is the first reported case of native valve endocarditis occurring

after endoscopic resection of a large (>20 mm) polyp. The normal urinalysis on presentation makes a urinary source of infection unlikely. Similarly, Sekino et al reported *E. faecalis* endocarditis in a patient with prosthetic valve replacement after piecemeal resection of a 30-mm tubulovillous adenoma.<sup>5</sup> It is possible that the large area of submucosal exposure to colonic bacteria increases the risk of bacteremia and seeding of a heart valve. This complication of EMR of large colorectal polyps appears very rare. Nevertheless, we believe that the timing of the infection in relation to EMR, and *Streptococcus faecalis* as the causative organism, provides convincing evidence that the colonoscopy and EMR had a causative role in the endocarditis.

## DISCLOSURES

Author contributions: A. Wehbeh wrote the initial draft of the manuscript. MC Gerson and DK Rex critically reviewed and approved the manuscript, and is the article guarantor.

Financial disclosure: This work was supported by a gift to the Indiana University Foundation from Scott Schurz of Bloomington, Indiana, in the name of Douglas K. Rex.



**Figure 2.** Transesophageal echocardiogram showing (A) mitral valve vegetation (arrow) and (B) tricuspid valve vegetation (arrow). (C) Transthoracic echocardiogram showing tricuspid valve vegetation (asterisks). AV, aortic valve; LA, left atrium; LV, left ventricle; MV, mitral valve; RA, right atrium; RV, right ventricle; TV, tricuspid valve.

Informed consent was obtained for this case report.

Received July 26, 2018; Accepted November 7, 2018

## REFERENCES

1. Nigo M, Munita JM, Arias CA, Murray BE. What's new in the treatment of enterococcal endocarditis? *Curr Infect Dis Rep.* 2014;16:431.
2. Tang X, Gong W, Jiang B. Antibiotic prophylaxis for GI endoscopy. *Gastrointest Endosc.* 2015;81:1503–4.
3. Kaltenbach T, Soetikno R. Endoscopic mucosal resection of non-polypoid colorectal neoplasm. *Gastrointest Endosc Clin N Am.* 2010;20:503–14.
4. Allison MC, Sandoe JA, Tighe R, et al. Antibiotic prophylaxis in gastrointestinal endoscopy. *Gut.* 2009;58:869–80.
5. Sekino Y, Fujisawa N, Suzuki K, et al. A case of recurrent infective endocarditis following colonoscopy. *Endoscopy.* 2010;42(Suppl 2):E217.

---

**Copyright:** © 2019 The Author(s). Published by Wolters Kluwer Health, Inc. on behalf of The American College of Gastroenterology. This is an open-access article distributed under the terms of the Creative Commons Attribution-Non Commercial-No Derivatives License 4.0 (CCBY-NC-ND), where it is permissible to download and share the work provided it is properly cited. The work cannot be changed in any way or used commercially without permission from the journal.