

Treatment of Erythrodermic Psoriasis in Children with Secukinumab: A Case Report

Xujun Lu , Wenge Wang

Department of Pediatrics, Air Force Medical Center, Air Force Medical University, PLA, Beijing, 100142 People's Republic of China

Correspondence: Wenge Wang, Department of Pediatrics, Air Force Medical Center, Air Force Medical University, PLA, Beijing, 100142, People's Republic of China, Email 1264516006@qq.com

Abstract: Erythrodermic psoriasis (EP) is a rare and severe type of psoriasis. Common systemic therapies for children with EP include treatment with glucocorticoids, cyclosporine, acitretin, and methotrexate. Although these drugs are effective, they may cause serious side effects to children. Secukinumab has recently demonstrated efficacy in treating plaque psoriasis, but its efficacy in EP children remains unknown. We report a case of a seven-year-old patient who transitioned from generalized pustular psoriasis (GPP) to EP after routine systemic drug treatment. The patient was then treated with secukinumab. The patient's condition improved noticeably within 48 hours after the first injection. After the fifth injection, she almost completely cleared her skin lesions and achieved Psoriasis Area and Severity Index 90 (PASI 90) scores. During this period, she experienced only one respiratory infection. She completed all 11 doses of secukinumab by October 14, 2022, with no new rash (PASI 100) and no adverse drug reactions. Follow-up observation on March 15, 2023, showed no new rash (PASI 100) and no adverse reactions after medication withdrawal. This case suggests that it may also be effective in treating children with EP.

Keywords: erythrodermic psoriasis, children, generalized pustular psoriasis, secukinumab, therapy

Introduction

Psoriasis is a chronic, recurrent, inflammatory, and systemic disease. It can be hereditary or triggered by environmental factors. Psoriasis affects approximately 125 million people worldwide. However, its exact etiology and pathogenesis are not yet elucidated.¹ Erythrodermic psoriasis (EP) is a rare and severe type of psoriasis, primarily induced by factors in the acute stage of psoriasis stimulation or improper treatment.² The prevalence of EP accounts for 1–2% of psoriasis patients.³ EP is a rare type of psoriasis which, in its most severe form, can be fatal. Recent research suggests that the use of biological agents could revolutionize the treatment of EP. For example, secukinumab is proved effective for treating plaque psoriasis, and real-world studies demonstrate its effectiveness and long-term efficacy in managing this condition.^{4,5} Real-world studies can significantly inform dermatological decision-making processes. However, real-world studies on secukinumab use in treating EP are scarce. Currently, only Avallone G⁶ and his co-authors have demonstrated the effectiveness of secukinumab in treating adult EP in real-world studies. However, the therapeutic effect of secukinumab on children with EP is under-researched. There is only two reported successful EP treatment using secukinumab in children. Therefore, this paper reports a case of a child with EP treated with secukinumab, aiming to provide guidance for the treatment of psoriasis in children.

Clinical Data

A female patient of seven years and seven months was admitted to the Department of Pediatrics on April 7, 2022, with the principal complaint of “rash for more than 10 months, aggravated for more than 10 days, fever for 4 days”. More than 10 months before admission, she developed a rash on both armpits, vulva, and buttocks, with no obvious itching, fever, abdominal pain, joint pain, or other discomfort. She was treated with oral dexamethasone tablets and hormone ointment (specifics unknown) at a local hospital for 10 month. More than 10 days before admission, her rash worsened and spread

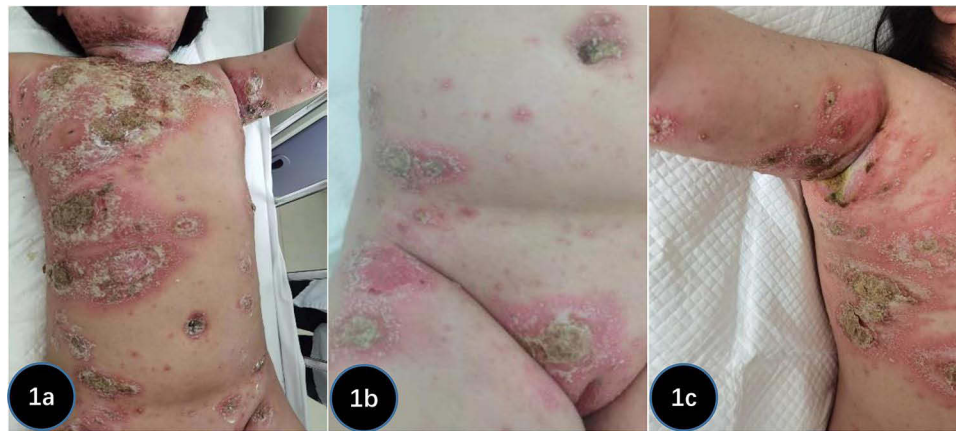

Figure 1 (a–c) Upon admission on April 7, the patient's whole body was covered with dense pustules, local congestion was evident, dandruff and dry scabs were scattered, and some abscesses coalesced into the blemish.

to the whole body, accompanied by slight itching. The local hospital diagnosed her with “generalized pustular psoriasis (GPP)”. In the four days leading up to admission, she was having a fever. After her admission, we conducted a series of examinations and carried out treatments according to her diagnosis. Detailed clinical data are reported below.

Physical examination: body temperature, 38.6°C; pulse, 98 bpm; respiration, 24 bpm; height, 130.0 cm; weight, 45.0 kg. The patient's whole body was covered with dense pustules; local congestion was evident; some pustules gathered into larger pustules, especially on the trunk, neck, armpits, and vulva (Figure 1).

Auxiliary Examination: Blood Routine Test + Rapid CRP: White blood cell count $9.39 \times 10^9/L$, neutrophil percentage 65.40%, lymphocyte percentage 24.40%, red blood cell count $3.70 \times 10^{12}/L$, hemoglobin 107.00 g/L, and C-reactive protein 52.04 mg/L. Electrolytes: Serum potassium 3.40 mmol/L, serum sodium 141.50 mmol/L, and serum chloride 105.50 mmol/L. Liver Function: Glutamic-pyruvic transaminase 13.20 U/L and glutamic-oxaloacetic transaminase 16.10 U/L. Myocardial Enzymes: Creatine kinase 57.00 U/L and creatine kinase MB isoenzyme 11.10 U/L. Erythrocyte Sedimentation Rate: 9 mm/h. D-Dimer: 380 ng/mL.

Admission Diagnosis: (1) GPP; (2) respiratory tract infection; (3) overweight; (4) mild positive cell anemia; (5) hypokalemia.

Treatment: After admission, the patient received piperacillin sodium and tazobactam sodium 1.75g twice a day, ceftriaxone (H) 1.5g once a day, and ceftizoxime 1.5g twice a day for anti-infection treatment. Topical hyaluronic acid cream, fusidic acid, mometasone furoate cream, coptis chinensis, zinc oxide, emollient cream, and silicone oil cream were also administered for anti-inflammatory, moisturizing, repair, and related symptomatic support. Upon admission, rash was present on the forechest and vulva. After initial treatment, the original rash and pustules gradually subsided. However, similar rashes appeared on the buttocks, back, and lower limbs, and the patient's body temperature remained uncontrolled. Additionally, leukocyte, platelet, and D-dimer levels gradually increased (Table 1). With informed consent from the patient's family, the patient began treatment with 10 mg of acitretin capsules twice daily on April 21. The body temperature returned to normal the next day, and the skin progressively improved. On April 25, skin flushing appeared on

Table 1 Changes in Laboratory Examination Indices

Project	When Admitted to the Hospital on April 7th	Before the Injection on April 29th	After the Injection on May 2nd	Before Discharge on May 6th
White blood cell	$9.39 \times 10^9/L$	$23.62 \times 10^9/L$	$7.54 \times 10^9/L$	$9.28 \times 10^9/L$
Hemoglobin	107 g/L	122 g/L	107 g/L	110 g/L
C-reactive protein	52.04 mg/L	18.28 mg/L	11.13 mg/L	2.29 mg/L
Erythrocyte sedimentation rate	-	22 mm	26 mm	11 mm
D-dimer	380 ng/mL	400 ng/mL	151 ng/mL	-

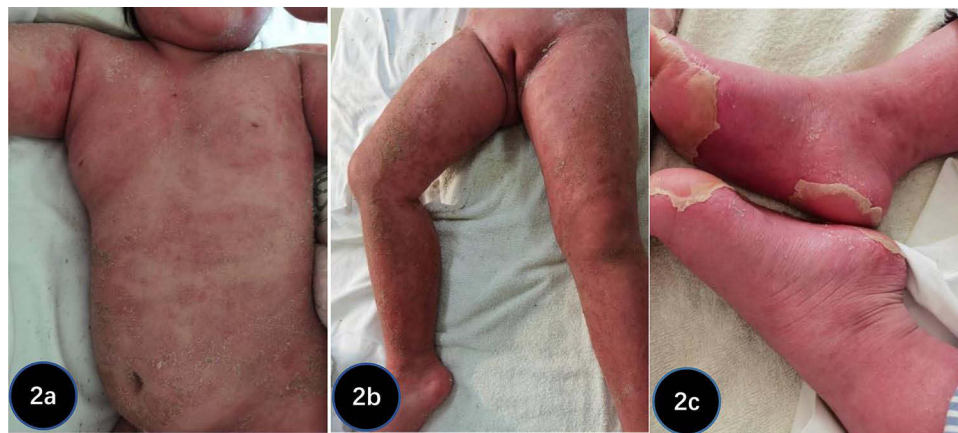

Figure 2 (a–c) Skin flushing in the forehead due to EP on April 25 gradually spread to the entire body, accompanied by dry yellow scabs and an absence of obvious pustules.

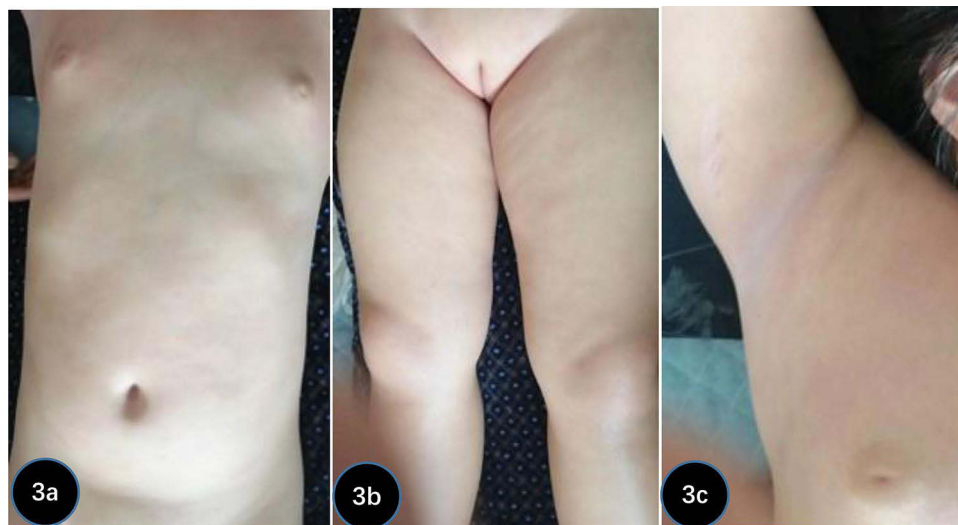


Figure 3 (a–c) By May 27, the child had nearly completely cleared the skin lesions, with the skin lesions improving to a PASI 90 score.

the forehead and spread to the entire body within 2–3 days, accompanied by a dry yellow scab and no obvious pustules (Figure 2). The diagnosis was modified to EP. On April 27, the patient experienced a fever with a peak body temperature of 40.3°C, along with noticeable skin pain and edema in both lower extremities and feet. After obtaining informed consent from the patient's family, a subcutaneous injection of Secukinumab 150mg was administered on April 29. The body temperature returned to normal on April 30, and the skin flushing subsided, with many scales falling off. By May 27, after the fifth injection of secukinumab, the patient achieved a Psoriasis Area and Severity Index (PASI) score of 90 (Figure 3). The patient completed 11 doses of secukinumab by October 14, 2022, with no new rash (PASI 100) and no adverse drug reactions. The patient was followed up until March 15, 2023. No new rash (PASI 100) or adverse drug reactions were observed after drug withdrawal.

Discussion

In this case, the child was initially diagnosed with GPP, a rare and serious type of psoriasis. GPP is characterized by multiple needle-tip to millet-sized aseptic pustules based on systemic erythema, which can fuse to form larger pustules. Accompanying symptoms include fever, fatigue, leukocytosis, and hypocalcemia. Typically, pustules dry and scabs

appear after 1 to 2 weeks, leading to natural relief, but the disease can recur periodically.^{7,8} However, as the disease progressed, the child's condition evolved into EP.

EP is marked by erythema and scales covering over 75% of the body surface area. Affected patients may experience systemic symptoms such as fever, tachycardia, lymphadenopathy, joint pain, and fatigue. Without proper treatment, EP can lead to high-output heart failure, anemia, septicemia, and even death in severe cases.^{2,9}

Most of the medicines have serious side effects, especially for children, potentially impacting their growth and development.¹⁰ Along with the use of biological agents, the treatment of EP patients has brought revolutionary progress. Recent research indicates that secukinumab can safely treat adult EP patients, but its efficacy in children remains unclear.¹¹

Secukinumab is a human monoclonal IgG antibody and a new biological agent that mainly acts on IL-17A.¹² Although not a routine drug for EP, recent studies have demonstrated its effectiveness in treating the condition. There are few reported cases of successful EP treatment with secukinumab worldwide, especially in children, with only two documented cases. The first case, reported by Dogra S,¹³ involved a 13-year-old male diagnosed with psoriasis at age 6 and erythroderma at age 9. After failing to improve with conventional treatment for 3 years, the patient received secukinumab, and his lesions resolved entirely (PASI 100) without side effects. The second case, reported by Zhao Z,¹⁴ involved a 7-year-old male with vaccine-induced EP. After 18 weeks of secukinumab combined with symptomatic treatment, the patient's lesions completely subsided (PASI 100) with no reported adverse effects.

In this case, the child's symptoms, including skin rash, body temperature, and lower limb swelling, did not improve after glucocorticoid topical treatment, moisturizing treatment, and acitretin capsule treatment. The patient's condition worsened, but with the family's informed consent, the child received secukinumab. The next day, the child's body temperature normalized, the rash disappeared, and lower extremity swelling subsided. After a 28-day treatment, the patient achieved PASI 90. On December 11, the child completed 11 doses of secukinumab, and the rash disappeared completely (PASI 100). Follow-up observation on March 15, 2023, revealed no new rashes or adverse reactions. Does this mean that secukinumab can be used as a new treatment for EP?

Nonetheless, our study is not without its limitations, such as its retrospective nature and a small patient sample. Thus, further experimental evidence is needed to ascertain the efficacy of secukinumab on children with EP. Furthermore, the collected data did not permit us to quantify the impact of prior treatments on the final outcome. However, our results align and or even outperform those reported in clinical trials. Given the limited data available on the use of secukinumab in treating pediatric EP, this case may serve as a valuable reference.

Conclusion

Currently, there is no evidence to prove that secukinumab can effectively treat EP in children. Consequently, although traditional therapeutic drugs such as methotrexate, acitretin, and cyclosporine have not been approved for use in children with EP, they remain the first-line medications recommended by international guidelines for treating pediatric EP.¹⁵ In this case, the patient did not respond to conventional drugs but experienced rapid improvement after receiving secukinumab. Furthermore, the adverse reactions of secukinumab were less severe than those of other EP Therapy Medications. Therefore, it cannot be denied that secukinumab may provide a new treatment option for children. It is anticipated that, following additional research, secukinumab will become a first-line drug for treating various types of psoriasis.

Data Sharing Statement

The authors confirm that the data supporting the findings of this study are available within the article.

Compliance with Ethical Standards

The authors declare that they have adhered to ethical standards in conducting and reporting their research.

Consent Statement

Informed consent for publication of the case details and associated images was obtained from the patient.

Institutional approval was not required to publish the case details.

Funding

This study was supported by the Beijing Science and Technology Plan Project - Research on Clinical Characteristics of the Capital. Title (Study on the Correlation Between TCM Constitution Classification of Newborns and Infant Eczema) (No: Z181100001718029).

Disclosure

The authors declare no conflicts of interest in this work.

References

1. Armstrong AW, Read C, Read C. Pathophysiology, clinical presentation, and treatment of psoriasis: a review. *JAMA*. 2020;323(19):1945–1960. doi:10.1001/jama.2020.4006
2. Singh RK, Lee KM, Ucmak D, et al. Erythrodermic psoriasis: pathophysiology and current treatment perspectives. *Psoriasis*. 2016;6:93–104. doi:10.2147/PTT.S101232
3. Lo Y, Tsai TF. Updates on the treatment of erythrodermic psoriasis. *Psoriasis*. 2021;11:59–73. doi:10.2147/PTT.S288345
4. Kacar N, Balci DD, Dogan S, et al. Real-life efficacy and drug continuation of secukinumab in treating moderate to severe plaque psoriasis in Aegean region of Turkey: a multicenter retrospective study and systematic review of the literature. *Asian Pac J Allergy Immunol*. 2022. doi:10.12932/AP-241021-1259
5. Dastoli S, Passante M, Loconsole F, et al. Long-term efficacy and safety of secukinumab in real life: a 240 weeks multicenter study from Southern Italy. *J Dermatolog Treat*. 2023;34(1):2200868. doi:10.1080/09546634.2023.2200868
6. Avallone G, Cariti C, Dapavo P, et al. Real-life comparison between secukinumab and ixekizumab in the treatment of pustular and erythrodermic psoriasis. *J Eur Acad Dermatol Venereol*. 2022;36(7):e574–e576. doi:10.1111/jdv.18069
7. Neuhauser R, Eyerich K, Boehner A. Generalized pustular psoriasis-Dawn of a new era in targeted immunotherapy. *Exp Dermatol*. 2020;29(11):1088–1096. doi:10.1111/exd.14171
8. Gooderham MJ, Van Voorhees AS, Lebwohl MG. An update on generalized pustular psoriasis. *Expert Rev Clin Immunol*. 2019;15(9):907–919. doi:10.1080/1744666X.2019.1648209
9. Carrasquillo OY, Pabon-Cartagena G, Falto-Aizpurua LA, et al. Treatment of erythrodermic psoriasis with biologics: a systematic review. *J Am Acad Dermatol*. 2020;83(1):151–158. doi:10.1016/j.jaad.2020.03.073
10. Fotiadou C, Lazaridou E, Ioannides D. Management of psoriasis in adolescence. *Adolesc Health Med Ther*. 2014;5:25–34. doi:10.2147/AHMT.S36672
11. Carriero M. Erythrodermic psoriasis and palmoplantar hyperkeratosis successfully treated with secukinumab: a case report. *Drug Target Insights*. 2022;16:1–5. doi:10.33393/dti.2022.2355
12. Langley RG, Elewski BE, Lebwohl M, et al. Secukinumab in plaque psoriasis—results of two Phase 3 trials. *N Engl J Med*. 2014;371(4):326–338. doi:10.1056/NEJMoa1314258
13. Dogra S, Bishnoi A, Narang T, et al. Long-term remission induced by secukinumab in a 13-year-old boy having recalcitrant chronic erythrodermic psoriasis. *Dermatol Ther*. 2018;31(4):e12611. doi:10.1111/dth.12611
14. Zhao Z, Zhang X, Wang R, et al. Vaccine-induced erythrodermic psoriasis in a child successfully treated with secukinumab: a case report and brief literature review. *Dermatol Ther*. 2022;35(9):e15684. doi:10.1111/dth.15684
15. Pizzatti L, Mugheddu C, Sanna S, et al. Erythrodermic psoriasis in a dialyzed patient successfully treated with Secukinumab. *Dermatol Ther*. 2020;33(3):e13348. doi:10.1111/dth.13348

Clinical, Cosmetic and Investigational Dermatology

Dovepress

Publish your work in this journal

Clinical, Cosmetic and Investigational Dermatology is an international, peer-reviewed, open access, online journal that focuses on the latest clinical and experimental research in all aspects of skin disease and cosmetic interventions. This journal is indexed on CAS. The manuscript management system is completely online and includes a very quick and fair peer-review system, which is all easy to use. Visit <http://www.dovepress.com/testimonials.php> to read real quotes from published authors.

Submit your manuscript here: <https://www.dovepress.com/clinical-cosmetic-and-investigational-dermatology-journal>