

Clinical outcomes of pars plicata anterior vitrectomy: 2-year results

Priya Narang, Amar Agarwal¹

Purpose: To demonstrate the safety and outcome of a surgical approach that uses pars plicata site for anterior vitrectomy during phacoemulsification procedure complicated by posterior capsule rupture and residual cortical matter. **Design:** Single center, retrospective, interventional, noncomparative study. **Materials and Methods:** Medical records of a consecutive series of 35 eyes of 35 patients who underwent pars plicata anterior vitrectomy (PPAV) were reviewed. The main outcome measures were corrected and uncorrected distance visual acuity (CDVA, UDVA), early and late postoperative complications and intraocular pressure (IOP). Ultrasound biomicroscopic (UBM) evaluation of sclerotomy site and spectral domain optical coherence tomography analysis for central macular thickness (CMT) was performed. The final visual outcome at 2 years was evaluated. **Results:** At 2 years follow-up, the mean postoperative UDVA (logarithm of the minimum angle of resolution [logMAR]) and CDVA (logMAR) was 0.49 ± 0.26 and 0.19 ± 0.14 , respectively. There was no significant change in the IOP ($P = 0.061$) and the mean CMT at 2 years was $192.5 \pm 5.54 \mu\text{m}$. The postoperative UBM image of the sclerotomy site at 8 weeks demonstrated a clear wound without any vitreous adhesion or incarceration. Intraoperative hyphema was seen in 1 (2.8%) case and postoperative uveitis was seen in 2 (5.7%) cases, which resolved with medications. No case of an iatrogenic retinal break or retinal detachment was reported. **Conclusions:** PPAV enables a closed chamber approach, allows thorough cleanup of vitreous in the pupillary plane and anterior chamber and affords better access to the subincisional and retropupillary cortical remnant with a significant visual outcome and an acceptable complication rate.

Key words: Anterior vitrectomy, pars plicata, posterior capsule rupture, vitreous prolapse

Vitrectomy is a crucial tool in the skill set of an anterior segment surgeon as often it is an unplanned procedure resulting from an inadvertent posterior capsule rupture (PCR) during a normal cataract procedure. The limbal route is the most common mode of vitrectomy employed by anterior segment surgeons who are often plagued by the idea of doing pars plana vitrectomy, as it is associated with a risk of damaging the vitreous base and the peripheral retina.^[1,2] A limbal vitrectomy often leads to corneal distortion and poor visualization due to the limited accessibility, fixed directionality, and hinge effect of the vitrectomy probe when passed through the limbal incision.

The objective of anterior vitrectomy is to remove vitreous from the anterior chamber, prevent its further prolapse and clear any vitreous from the corneal incision followed by the placement of an intraocular lens (IOL) in the eye. Due to nondevelopment of pars plana site, the pars plicata approach has been used successfully in children with retinopathy of prematurity.^[3]

After our elaborate experience with the employment of pars plicata site for performing anterior vitrectomy in glued intrascleral fixation of an IOL (glued IOL),^[4,5] we hereby present clinical outcomes of pars plicata anterior vitrectomy (PPAV) for managing vitreous prolapse and residual cortical matter from the perspective of an anterior segment surgeon during phacoemulsification procedure complicated by PCR.

Narang Eye Care and Laser Centre, Ahmedabad, Gujarat, ¹Dr. Agarwal's Eye Hospital and Eye Research Centre, Chennai, Tamil Nadu, India

Correspondence to: Prof. Amar Agarwal, Dr. Agarwal's Eye Hospital and Eye Research Centre, 19, Cathedral Road, Chennai - 600 086, Tamil Nadu, India. E-mail: dragarwal@vsnl.com

Manuscript received: 08.01.15; **Revision accepted:** 12.11.15

Videos Available on:
www.ijo.in

Access this article online

Website:
www.ijo.in

DOI:
10.4103/0301-4738.170976

Quick Response Code:



Materials and Methods

The procedure conformed to the Declaration of Helsinki, and a Local Institutional Review Board approval was obtained. Data of 35 consecutive patients who underwent PPAV in cases with intraoperative PCR and residual cortical and epinucleus matter during a phacoemulsification procedure were reviewed retrospectively. Patients with a minimal 2 years of follow-up were included in the study. Exclusion criteria were traumatic cataract and any history of anterior or posterior segment surgery previously undergone by the patient. Data abstracted from these consecutive case sheets included patient age, date of surgery, operative eye, a complete ophthalmologic examination including corrected and uncorrected Snellen's distance visual acuity (CDVA, UDVA), slit-lamp examination, measurement of intraocular pressure (IOP), and a dilated fundus examination. Specific intraoperative features such as hyphema, vitreous hemorrhage, iridodialysis, and cyclodialysis were monitored. Postoperatively, examinations were performed at 1, 3, and 7 days, then every week for the 1st month, at monthly intervals for 12 months and every 3 months thereafter up to the period of 2 years. Outcome variables included postoperative visual acuity, sclerotomy suture placement,

This is an open access article distributed under the terms of the Creative Commons Attribution-NonCommercial-ShareAlike 3.0 License, which allows others to remix, tweak, and build upon the work non-commercially, as long as the author is credited and the new creations are licensed under the identical terms.

For reprints contact: reprints@medknow.com

Cite this article as: Narang P, Agarwal A. Clinical outcomes of pars plicata anterior vitrectomy: 2-year results. Indian J Ophthalmol 2015;63:699-703.

leakage, hypotony, postoperative retinal tear or detachment, and the need for additional operations or procedures. In addition, each examination also included the ultrasound biomicroscopy (UBM) of the sclerotomy site, spectral domain optical coherence tomography (SD-OCT) analysis for central macular thickness (CMT) and a detailed examination of the retina with indirect ophthalmoscopy.

A disposable 23-gauge vitrectomy cutter was used in all the cases. After cortical cleanup, adequate assessment of the capsular support was done for choosing the appropriate site for the placement of an IOL. In-the-bag placement of an IOL was considered in cases with adequate capsular bag support; sulcus placement in cases with adequate capsular rim and sulcus support and glued IOL was considered in cases with inadequate sulcus and bag support. In each case, surgery was performed under monitored care, using a peribulbar anesthesia. Supplemental anesthesia was administered as necessary.

Surgical technique

After the acknowledgment of PCR in a routine phacoemulsification procedure being done with corneal incision, the surgery was temporarily halted, and anterior chamber was inflated with a dispersive ophthalmic viscosurgical device from the side port incision before the withdrawal of phacoemulsification probe. The extent, position and the stage at which a PCR had occurred were taken into consideration, and the procedure was ensued. The main corneal incision was closed with a 10-0 suture, the bottle height was reduced and an anterior chamber maintainer was introduced from limbal side port incision [Fig. 1a]. For thorough cleanup of the cortical material; a pars plicata approach was preferred.

The site of sclerotomy can be chosen depending on the primary incision for the cataract surgery and also on the location and extent of PCR and the retained cortical fragments. A small circumferential conjunctival peritomy incision 1.5 mm posterior to the limbus was fashioned and an entry with a 20-gauge micro-vitreoretinal (MVR) blade was made. The

blade was inserted through the sclera, 1.5 mm posterior to the limbus with the direction of the blade obliquely downward toward the mid-vitreous cavity [Fig. 1b].

A 23-gauge vitrectomy cutter was introduced from this site [Fig. 1c] and a cutting rate of preferably 1500 cuts/min or greater was kept so as to reduce the pulsatile vitreous traction with a moderate amount of suction and flow rate. Vitrectomy was done with better access and management of the vitreous and cortical fragments [Supplemental digital content; Video Clips 1-6] and it was performed under direct visualization to debulk the vitreous in the pupillary plane. The anteriorly prolapsed vitreous was addressed through the posterior capsular tear. Residual cortical matter and epinucleus, if present, was removed simultaneously. Precautions were taken to avoid extending the capsule tear and protecting the anterior capsulorhexis margin.

Triamcinolone acetonide can be used to visualize vitreous in the anterior chamber. Following the completion of vitrectomy, the cutter was removed, and the pressure was applied for wound closure. If a leak was suspected then the wound was apposed with 7-0 vicryl suture. The capsular bag and residual capsular support were assessed to determine the final placement of an IOL. Following the removal of corneal suture, sulcus implantation [Fig. 1d] with an appropriate IOL was considered in eyes with adequate sulcus support and glued IOL was performed in eyes with inadequate sulcus support. A 3-piece, 6.0-mm optic, and acrylic foldable IOL with a modified C-loop haptic configuration was implanted in all eyes. In-the-bag IOL implantation was not possible in any case. The corneal wound was secured with a 10-0 nylon suture. The postoperative drug regime comprised of topical antibiotics and steroids.

Results

Data were entered in a Microsoft Excel Sheet (Microsoft Corp., Redmond, Washington, US), and were analyzed using SPSS version 16.1 (SPSS Inc., Chicago, Illinois, USA). Differences were considered statistically significant at $P < 0.05$.

Database of 35 eyes was evaluated and the mean age of patients was 59 years (range 45–73 years). All the patients had a minimum follow-up of 24 months. The mean postoperative UDVA (logarithm of the minimum angle of resolution) was 0.49 ± 0.26 . There was a significant improvement in the UDVA ($P = 0.001$, Wilcoxon signed rank test) and CDVA ($P = 0.000$). The mean postoperative CDVA was 0.09 ± 0.14 . The mean postoperative IOP was 13.1 ± 2 mmHg. There was no significant change in the IOP ($P = 0.061$). Intraoperative complications included hyphema in 1 (2.8%) eye and no incidence of vitreous hemorrhage, iridodialysis, or cyclodialysis was reported. Early (<1 month) and late (>1 month) postoperative complications are depicted in Table 1. None of the eyes developed sclerotomy port-related complications such as a retinal break, retinal detachment, or vitreous incarceration in the wound. The postoperative UBM image of the sclerotomy site at 8 weeks shows the wound clear of any vitreous adhesion or prolapse [Fig. 2].

Resistance during sclerotomy was encountered in 1 (2.8%) case. The needle was withdrawn, and a fresh entry was attempted slightly posterior to the site of previous entry. This case developed mild hyphema, which resolved

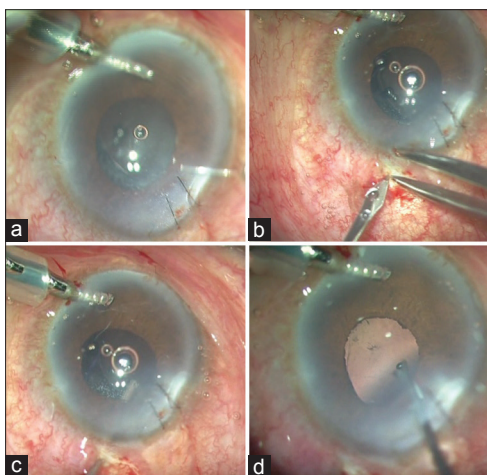


Figure 1: (a) The corneal wound is sutured and an anterior chamber maintainer is introduced. (b) Sclerotomy is made at the level of pars plicata with a micro-vitreoretinal blade 1.5 mm behind the limbus as measured with a Vernier caliper. (c) 23-gauge vitrectomy cutter introduced from the sclerotomy site (d) Sulcus placement with a well centered intraocular lens

postoperatively with medications. No case of endophthalmitis, uveitis-glaucoma-hyphema syndrome or chronic uveitis was reported. Postoperative uveitis was seen in 2 (5.7%) cases,

Table 1: Complication profile in eyes with PPAV

	n (%)
Intra operative	
Hyphema	1 (2.8)
Vitreous hemorrhage	0
Iridodialysis	0
Cyclodialysis	0
Early postoperative (<1 month)	
Wound leak	0
Hypotony	0
Vitreous in wound	0
Postoperative uveitis	2 (5.7)
Retinal traction	0
Hyphema	0
Vitreous hemorrhage	0
Ocular hypertension	0
Late postoperative (>1 month)	
Glaucoma	0
Chronic uveitis	0
Vitreous hemorrhage	0
UGH syndrome	0
Endophthalmitis	0
Retinal breaks	0
Retinal detachment	0
Vitreous incarceration	0
Pigment dispersion	1 (2.8)
Optic capture	1 (2.8)
Cystoid macular edema	0
Total number of cases that underwent PPAV	35

UGH: Uveitis, glaucoma, hyphema, n: Number of eyes, PPAV: Pars plicata anterior vitrectomy

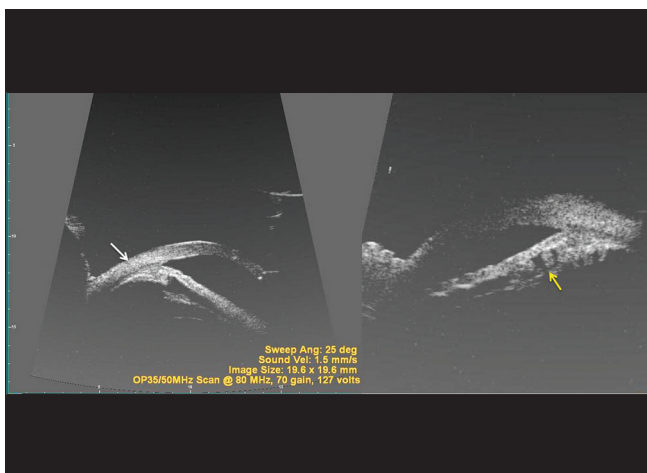


Figure 2: Ultrasound biomicroscopy demonstrates the site of pars plicata anterior vitrectomy (white arrow: External entry in relation to limbus; yellow arrow: Internal position across pars plicata process)

which resolved eventually with medications and no long-term repercussions. SD-OCT at regular intervals did not demonstrate cystoid macular edema in any case and the mean CMT at 2 years was $192.5 \pm 5.54 \mu\text{m}$.

Sulcus placement of the IOL was performed in 29 cases and glued IOL^[4] was performed in 6 cases due to inadequate sulcus support. The IOL was well centered [Fig. 3] in all the cases and there was no significant postoperative IOL decentration seen. Optic capture in the pupillary margin was noticed in 1 (2.8%) case, which had undergone a glued IOL fixation. The pigment dispersion was observed in 1 (2.8%) case. Re-surgery and suture placement for sclerotomy wound closure was not needed for any case. Loss of nuclear or cortical fragments into the vitreous cavity was not reported in any of the cases.

Discussion

This study represents and illustrates the surgical approach of PPAV for phacoemulsification cases complicated by a PCR and residual cortical matter. Following a PCR, the limbal route is more commonly employed for vitrectomy by anterior segment surgeons who often tend to use the preexisting corneal incision, which is too large for the vitrectomy probe and this eventually results in a less-stable anterior chamber as fluid, and possibly more vitreous, leak through the wound. Closure of the main corneal incision and creation of an additional side port incision is often done for a bi-manual approach that allows greater access to the anterior chamber, as the irrigation cannula and the vitrectomy probe can be placed through either port. However, this method is eventually limited by the fulcrum effect and also by its inability to debulk the vitreous in the pupillary and retro-pupillary plane, thereby enhancing the chances of the vitreous bulge. Inadequate and inappropriate debulking of the vitreous may eventually lead to other complications like IOL displacement and dislocation due to the pushing effect, along with the traction caused by pulling and entrapment of the vitreous strands which may eventually lead to cystoid macular edema.

Placing a vitrectomy probe through the pars plicata site using an MVR blade offers increased access to the anterior vitreous and draws vitreous posteriorly during aspiration and cutting, away from the anterior chamber and the entry incisions.

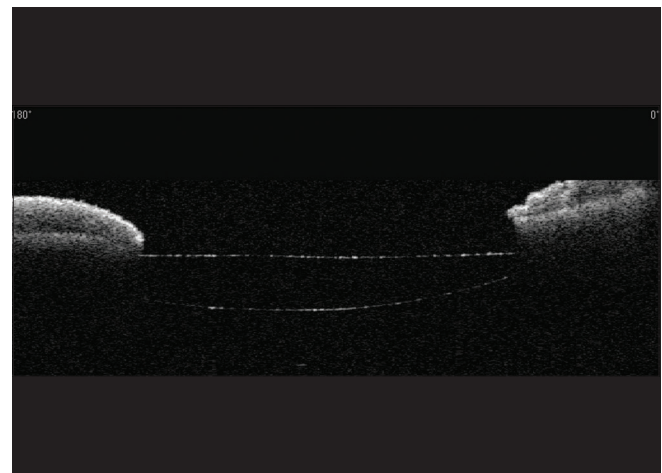


Figure 3: Optical coherence tomography analysis shows a well centered intraocular lens

Placement of an anterior chamber maintainer with the flow of fluid directed towards the anterior chamber followed by vitrectomy through a separate incision prevents the cortical fragments from being pushed away during the chewing up process and it also prevents enlargement of capsular tear and hydration of vitreous which normally occurs with vitrectomy probes where irrigation port is placed adjacent to the cutter port.

There are various anatomical considerations to be taken into account for vitrectomy through the pars plicata site. First, a major arterial vascular circle is located at the root of iris, and a forceful entry at pars plicata should be avoided during sclerotomy as it can lead to iridodialysis and also hyphema. In such a scenario, the MVR blade should be withdrawn, and a fresh entry should be attempted slightly below the site of previous entry.

Second, pars plicata lies in the direct axis of the lens and allows a better access to the residual cortical matter. In cases of small PCR, a limbal vitrectomy can suffice well as limited cleanup of vitreous is required. However in cases of moderate to large PCR's, adequate cleanup is necessary and it can be achieved through PPAV, as the fear of further damaging the residual capsular bag does not exist [Fig. 4]. A continuous monitoring of the sulcus support can be achieved during

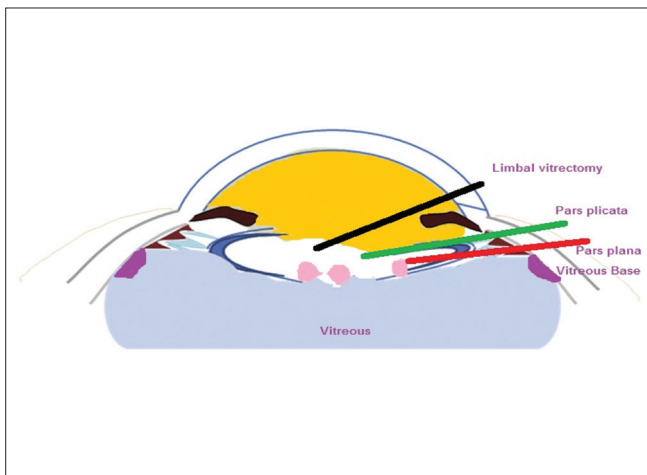


Figure 4: The picture demonstrates the anatomical sites of limbal, pars plicata and pars plana site

vitrectomy procedure, and an entire clean up beneath the sulcus support can be achieved for an effective placement of an IOL. In cases of pupil constriction, iris hooks can be deployed to enhance the visualization of the retro-pupillary area for adequate vitrectomy.

Third, researchers state that the ciliary zonular fibers originate in the pars plana as fine fiber bundles on the nonpigment epithelial basement membrane from 0.5 to 1 mm anterior to the ora serrata^[6] but they differ in estimating the number that may originate or terminate on the pars plicata and the degree of zonular adherence to this tissue. In such a scenario, the extent of damage caused to the zonules by utilization of the pars plicata site is not clear and is difficult to comment upon.

In as early as 1990, pars plicata sclerotomy has been successfully reported to be helpful for repositioning a posteriorly dislocated IOL.^[7] In our series of glued IOL surgery,^[4,5] sclerotomy was made at the level of pars plicata. In the review of complications profile of 486 eyes with rigid IOL, and 191 eyes with foldable IOL; posterior segment complications included macular edema (1.4%), retinal detachment (1%), and chronic vitritis (0.4%).^[5]

Pars plana vitrectomy requires an entry approximately 3–4 mm behind the limbus to avoid trauma to the lens or to the retina. However, in cases of PCR, the manipulation is at the level of the lens and posterior capsule. A slightly anterior approach at the level of pars plicata is a suitable option as it offers protection and a safe margin against damaging the strong vitreal adhesions at the level of pars plana and vitreous base. Pars plana approach is not a reasonable idea for anterior vitrectomy because the pars plana entry has a risk of iatrogenic tears in the peripheral retina.^[8] An overview of all the three modes of vitrectomy has been mentioned in the Table 2.

Surgical complications related to the insertion and removal of instruments through the pars plana incisions during vitrectomy have been well described.^[1,2,9] A peripheral retinal examination particularly at sclerotomy entry sites before completion of surgery is advocated. Ideally, single-use vitrectomy cutters should not be reused^[10] and it is for this reason that a disposable vitrectomy cutter was used in all the cases in our case series of PPAV.

Table 2: Overview of various modes of vitrectomy

Modes of vitrectomy	Advantages	Disadvantages
Limbal	Easy Most commonly employed by anterior segment surgeons Utilizes existing corneal incision	Not very effective Does not provide retro-pupillary access Limited accessibility and fixed directionality of vitrectomy probe Inappropriate debulking of the vitreous may eventually lead to other complications like IOL displacement and dislocation due to the pushing effect
Pars plana	Commonly employed by posterior segment surgeons Provides retro-pupillary access Allows handling of dropped nucleus and other associated complications	Technically difficult Needs proper training Chances of damage to peripheral retina
Pars plicata	Commonly employed by surgeons performing intrascleral fixation of IOL Provides retro-pupillary access Easy to learn	Needs a separate incision to be made Chances of damage to iris root Needs a separate incision to be made

The MVR blade was used to create the sclerotomy incision; alternatively a trocar-cannula system can also be used. The implantation of an acrylic hydrophobic 3-piece foldable IOL with modified C-loop haptics in the sulcus and in glued IOL preserves the advantages of a small-incision cataract surgery. In 6 eyes that underwent glued IOL, two separate sclerotomy sites were created below the scleral flaps for haptic externalization.^[4,5] The previously created sclerotomy site for PPAV could not be used for haptic externalization due to the fact that it was fashioned without the initial creation of a scleral flap. Moreover, the presence of inadequate sulcus support was realized at a later stage following the clearance of the vitreous and the lenticular matter. In cases with dislodgement of nuclear fragments in the anterior vitreous, posterior assisted levitation^[11] can be done and the nuclear fragments can be brought into the anterior chamber. IOL scaffold technique^[12,13] can then be employed to emulsify the remaining fragments although we did not come across the need to perform IOL scaffold in any of our cases reported in this paper. In our series of PPAV, we did not come across any major complication and had a very gratifying and a favorable outcome.

Limitations

The limitation of this technique is that it is not evaluated for proper posterior segment approach requiring full-fledged posterior segment surgery and secondly the surgeon may still need to perform additional cleanup with vitrectomy through an anterior side-port incision to completely remove vitreous from the anterior chamber.

Though pars plicata approach is justified in young children as pars plana are not well developed, PPAV offers an advantage in adults too as even anterior segment surgeons can perform this procedure and it provides a retro pupillary access for removal of cortical material and vitreous. To prevent unwanted complications, the surgeon should exert caution while introducing instruments through the densely vascularized area of pars plicata as it may further complicate the surgery by hyphema, iridodialysis, zonular damage, or a vitreous hemorrhage occasionally. Although cannulated vitrectomies are the standard approach for intraoperative capsular dehiscence management, PPAV can be adopted as an option if cannulated vitrectomy instruments are not available. In conclusion, although 2 years postoperative results are promising; larger case series with consistent selection criteria,

standardized outcome measure, and long-term follow-up are necessary.

Financial support and sponsorship

Nil.

Conflicts of interest

There are no conflicts of interest.

References

1. Faulborn J, Conway BP, Machemer R. Surgical complications of pars plana vitreous surgery. *Ophthalmology* 1978;85:116-25.
2. Machemer R. A new concept for vitreous surgery 2. Surgical technique and complications. *Am J Ophthalmol* 1972;74:1022-33.
3. Gonzales CR, Boshra J, Schwartz SD. 25-gauge pars plicata vitrectomy for stage 4 and 5 retinopathy of prematurity. *Retina* 2006;26 7 Suppl: S42-6.
4. Agarwal A, Kumar DA, Jacob S, Baid C, Agarwal A, Srinivasan S. Fibrin glue-assisted sutureless posterior chamber intraocular lens implantation in eyes with deficient posterior capsules. *J Cataract Refract Surg* 2008;34:1433-8.
5. Kumar DA, Agarwal A. Glued intraocular lens: A major review on surgical technique and results. *Curr Opin Ophthalmol* 2013;24:21-9.
6. Streeten BW. Anatomy of the zonular apparatus. In: Duane's Foundations of Clinical Ophthalmology. Vol. 1, Ch. 14. Philadelphia, PA: Lippincott Williams and Wilkins; 2006.
7. Lyons CJ, Steele AD. Report of a repositioned posteriorly dislocated intraocular lens via pars plicata sclerotomy. *J Cataract Refract Surg* 1990;16:509-11.
8. Er H. Small-gauge, sutureless pars plana vitrectomy to manage vitreous loss during phacoemulsification. *J Cataract Refract Surg* 2004;30:2252-3.
9. Aaberg TM. Pars plana vitrectomy for diabetic traction retinal detachment. *Ophthalmology* 1981;88:639-42.
10. Ramkissoon YD, Aslam SA, Shah SP, Wong SC, Sullivan PM. Risk of iatrogenic peripheral retinal breaks in 20-G pars plana vitrectomy. *Ophthalmology* 2010;117:1825-30.
11. Chang DF, Packard RB. Posterior assisted levitation for nucleus retrieval using Viscoat after posterior capsule rupture. *J Cataract Refract Surg* 2003;29:1860-5.
12. Kumar DA, Agarwal A, Prakash G, Jacob S, Agarwal A, Sivagnanam S. IOL scaffold technique for posterior capsule rupture. *J Refract Surg* 2012;28:314-5.
13. Narang P, Agarwal A, Kumar DA, Jacob S, Agarwal A, Agarwal A. Clinical outcomes of intraocular lens scaffold surgery: A one-year study. *Ophthalmology* 2013;120:2442-8.