



# Immune reconstitution inflammatory syndrome following *Cryptococcus neoformans* infection in an immunocompetent host: A case report and review of the literature

Raguharan Kathiresu<sup>a,\*</sup>, Syeda Nabila Zinat<sup>a,1</sup>, Malindu Fernando<sup>a,b,2</sup>

<sup>a</sup> Department of Internal Medicine, The Townsville Hospital, Townsville, Queensland, Australia

<sup>b</sup> College of Medicine and Dentistry, James Cook University, Townsville, Queensland, Australia

## ARTICLE INFO

### Article history:

Received 10 July 2019

Received in revised form 30 December 2019

Accepted 1 January 2020

### Keywords:

Cryptococcus

*C. neoformans*

Atypical presentations

## ABSTRACT

We present a case of *Cryptococcus neoformans* in an immunocompetent middle-aged woman with a disseminated manifestation of pulmonary cryptococcoma and cryptococcal meningitis resulting in bilateral blindness. The presentation was complicated by delayed diagnosis resulting in optic neuritis and an infected percutaneous lumbar drainage with methicillin resistant staphylococcus aureus (MRSA) and a paradoxical reaction of suspected immune reconstitution inflammatory syndrome (IRIS). We discuss the pathogen, the clinical manifestations and diagnostic approach (through laboratory and radiology findings), differential diagnosis, treatment, and proposed pathogenesis of IRIS and *C. neoformans* in an immunocompetent patient.

© 2020 The Authors. Published by Elsevier Ltd. This is an open access article under the CC BY-NC-ND license (<http://creativecommons.org/licenses/by-nc-nd/4.0/>).

## Introduction

Immunocompromised patients are particularly susceptible to *Cryptococcus* infections with *Cryptococcus gattii* being the predominant type in immunocompetent hosts. [1] The incidence of AIDS-associated cases in Australia have declined annually and *Cryptococcus* infection is more common in Aboriginal and Torres Strait Islander people in rural or semirural locations and in immunocompetent males [2,3]. Therefore clinical manifestations of the disease is influenced more strongly by host immune status than by *Cryptococcus* variety [1]. *Cryptococcus neoformans* is less commonly encountered and 10–30% of cryptococcal meningitis presentations occur in non-human immunodeficiency virus (HIV) patients [4]. Common treatment of Cryptococcal meningitis comprises of antifungal therapy and management of increased intracranial pressure [5]. Success rates are high with this combination therapy within the time frame of six weeks. Although

subtle, there is a vast differentiation between immunosuppressed and immunocompetent individuals infected with *Cryptococcus*. Immunocompetent patients generally present with pulmonary cryptococcoma [6–9] or meningoencephalitis, whilst immunocompromised patients more commonly present with meningoencephalitis [10,11]. Diagnosis is often delayed in immunocompetent patients given the condition is rare, resulting in a poorer prognosis [12,13].

Atypical presentations of *C. neoformans* is rare, nevertheless requires careful consideration in the clinical setting [14–16]. Regardless of a patient's immune status, a thorough and systematic clinical evaluation and prompt management is crucial in order to prevent the occurrence of sinister complications such as optic neuritis [17,18]. In the context of symptom relapse, consideration of paradoxical immune reconstitution inflammatory syndrome (IRIS) reactions and initiation of early steroid treatment is an important consideration [19–22]. Here we present the clinical journey of an immunocompetent patient who presented with disseminated *C. neoformans* infection resulting in IRIS and permanent bilateral vision loss.

## Case description

A 41-year-old Caucasian woman presented to a regional tertiary hospital in August 2018 with an eight week history of intermittent headaches, dizziness, and visual disturbance. She had initially presented to her general practitioner that morning who promptly

\* Corresponding author at: Department of Internal Medicine, The Townsville Hospital, 100 Angus Smith Drive, Douglas, Townsville 4811, Queensland, Australia.

E-mail addresses: [Raguharan.Kathiresu@health.qld.gov.au](mailto:Raguharan.Kathiresu@health.qld.gov.au) (R. Kathiresu), [syeda.zinat@health.qld.gov.au](mailto:syeda.zinat@health.qld.gov.au) (S.N. Zinat), [malindu.fernando@myjcu.edu.au](mailto:malindu.fernando@myjcu.edu.au) (M. Fernando).

<sup>1</sup> Department of Internal Medicine, The Townsville Hospital, 100 Angus Smith Drive, Douglas, Townsville 4811, Queensland, Australia.

<sup>2</sup> College of Medicine and Dentistry, James Cook University, 1 James Cook Drive, Douglas, Townsville 4811, Queensland, Australia, Townsville, Queensland, Australia.

transferred her to the emergency department. The patient's headaches were localized around the occipital cortex with a gradual onset and had been worsening over two weeks and were associated with dizziness, visual blurriness, and morning emesis. She reported associated unintentional weight loss of 10 kg over a month. The patient was previously well and her only prescribed medication was Carbamazepine 400 mg twice a day for epilepsy diagnosed at the age of 30 with no recent history of seizure relapse.

She had no history of HIV, Tuberculosis, exposure to pigeons, or any immunosuppressive treatments. She was investigated with blood and biochemical tests and a brain computed tomography (CT) scan, which were unremarkable. A provisional diagnosis of occipital neuralgia was made and 50 mg of oral Pregabalin twice daily was prescribed and the patient was discharged with a referral for an outpatient Magnetic Resonance Imaging (MRI) scan of her brain, and an outpatient neurologist review appointment in a month.

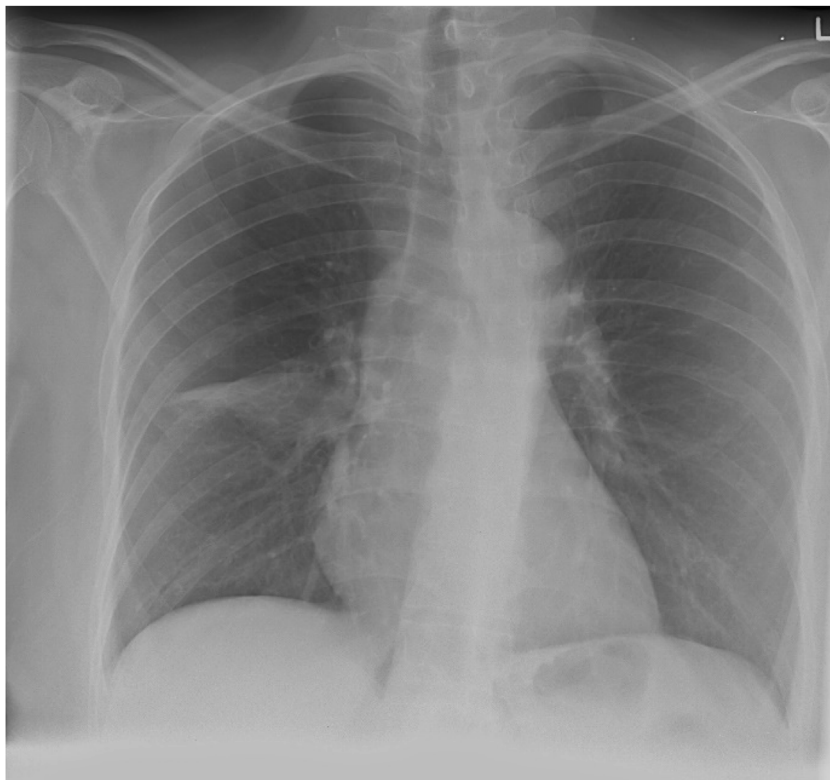
Three weeks later she re-presented to our center and was re-admitted with worsening headache and associated nausea and vomiting, bilateral double vision on lateral gaze, dry cough, and shortness of breath; along with a diagnosis of bilateral abducens nerve (CN VI) palsy. An initial chest radiograph showed a right middle lobe consolidation (Fig. 1) and the patient was treated for community acquired pneumonia with intravenous (IV) ceftriaxone 1 g and doxycycline 100 mg orally. The patient had an initial C-reactive protein (CRP) of 46 mg/L. An inpatient MRI scan was organized to investigate a cause of her persistent headache and her cranial nerve palsy and a neurological opinion was requested.

The MRI brain scan showed a small meningioma in her right frontal cortex, with evidence of meningitis and the patient underwent a lumbar puncture which showed high opening pressure ( $> 34$  cm H<sub>2</sub>O), high protein (1100 mg/L), low glucose (14 mmol/L), high white cell count ( $220 \times 10^6$ /L) with 83 %

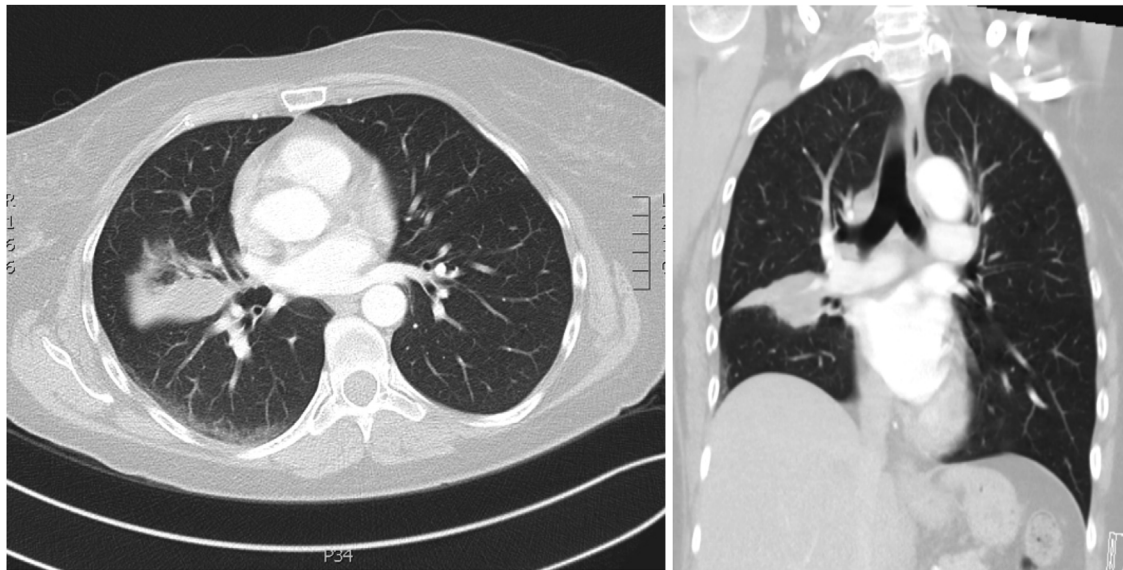
mononuclear cells and a positive cryptococcal titer of 1:1024. Cerebrospinal fluid (CSF) culture showed growth of *C. neoformans*. She was commenced on daily IV amphotericin B (AmBisome liposomal 50 mg), 5 mg/kg and oral 5-fluorocytosine 1500 mg 6-hly for a duration of six weeks as induction therapy followed by fluconazole 600 mg daily for eradication. A chest CT scan was taken which showed possible large cryptococcoma (Fig. 2). This was confirmed with bronchoscopy and bronchial lavage.

During the admission, the patient required lumbar percutaneous drainage due to persistently high intracranial pressure. The percutaneous drainage site became infected by Methicillin-resistant *Staphylococcus aureus* (MRSA) infection although she was negative for MRSA colonization previously. This was treated as a hospital acquired infection and required the removal of the drain for source control and IV vancomycin 1 g twice a day and rifampicin 300 mg daily, orally for two weeks. The initial presenting symptoms began to improve and the CSF had evident cryptococcal clearance by week three following treatment and she was transferred to the rehabilitation ward on oral Fluconazole 400 mg daily. An external ventricular drain (EVD) was inserted by the neurosurgical team to control raised intracranial pressure. However the patient continued to deteriorate clinically with persistent headaches, nausea and vomiting, and visual impairment along with ongoing high output EVD; resulting in eventual insertion of a ventriculoperitoneal (VP) shunt by the neurosurgical team during the fifth week of admission.

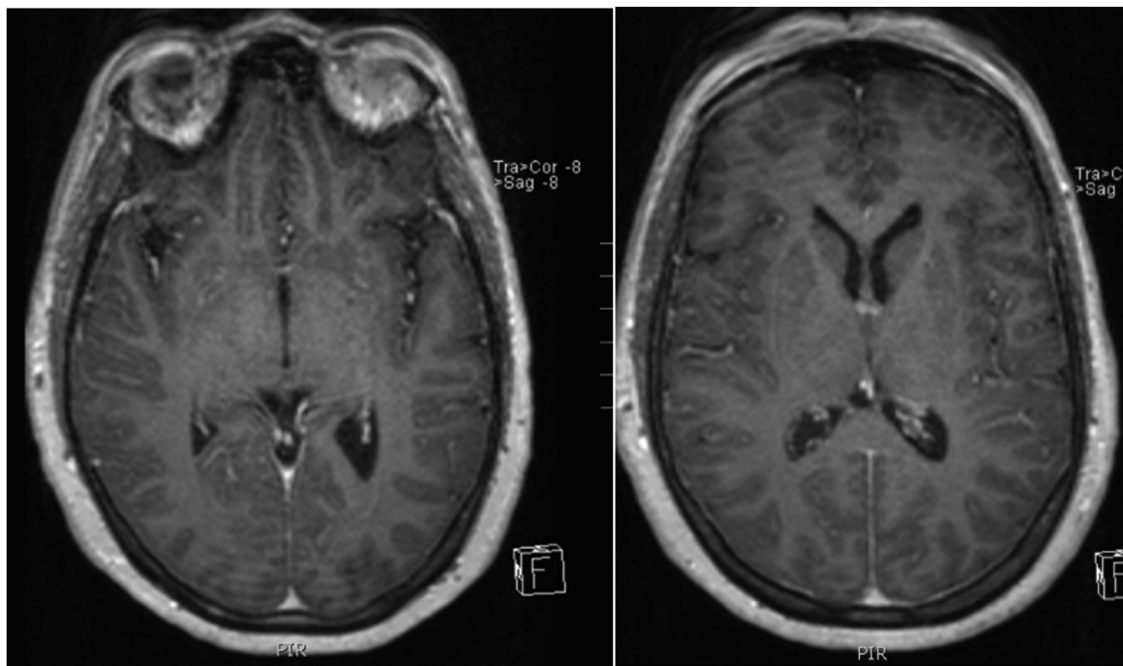
At week seven, she developed a fever (38.2°C), worsening vision, confusion, and a non-localized headache. Her septic screen was unremarkable and a repeated CSF analysis showed normal open pressure, with markedly increased protein (4300 mg/L), and raised white cell count ( $191 \times 10^6$ /L). A repeated MRI brain revealed gyro hyper-intensity on the fluid-attenuated inversion recovery (FLAIR) study which was a novel finding (Fig. 3). Despite intensive



**Fig. 1.** Chest Radiograph shows an opacity in the right midzone with an ovoid, well-defined fluid density structure in the superior aspect of the right middle lobe measuring  $3.4 \times 2$  cm in maximal axial dimensions.



**Fig. 2.** CT tomography of chest in axial and coronal view shows middle lobe consolidation of the Right lung, suggestive of cryptococcoma.



**Fig. 3.** MRI-FLAIR (Fluid-attenuated inversion recovery) study depicting gyro hyper-intensity on the FLAIR study pre-contrast and post-contrast. The post contrast MRI image depicts meningeal enhancement through gyro hyper-intensity on the FLAIR study.

treatment with IV cefepime 2 g eight hourly, and IV vancomycin 1 g every 12 h, her level of consciousness deteriorated. She was admitted to the intensive care unit (ICU) and required endotracheal intubation and monitoring for 48 h. Her CSF culture remained negative. IRIS was strongly suspected at this point, and a high dose of IV steroids was administered along with oral prednisolone. The patient remarkably improved within the next week and returned to the ward for continuation of rehabilitation. However, her vision remained severely impaired.

The patient had two visual evoked potential tests with no abnormal results and normal baseline visual examination. During Ophthalmology review during week ten of admission, bilateral optic neuropathy was confirmed, and she was declared legally blind. During her admission the patient tested negative for

Hepatitis B and HIV repeatedly (eight weeks apart) but had positive hepatitis C antibodies with evidence of past infection (IgG), normal immunoglobulin levels (IgG, IgA, IgM) and normal complement levels.

### Search strategy

References for this review were identified through searches of Ovid MEDLINE (1946 to 7 May 2019); Elsevier SCOPUS (1960 to 13 May 2019; by use of the terms “Cryptococcus”, “Immunocompetence”, “Cryptococcoma” and “Cryptococcal meningitis”. Articles resulting from these searches and relevant references cited in those articles were reviewed. Articles published in English were included in the review where the article contained a study

reporting on a case study of *Cryptococcus neoformans* in an immunocompetent host. Articles in other languages were excluded unless an English translation existed.

## Discussion

A case of *Cryptococcus neoformans* infection in an immunocompetent woman with a disseminated manifestation, including spread cryptococcoma in her lungs, and Cryptococcal meningitis is presented. The patient initially presented with the symptom constellation of headache, nausea, fatigue and altered mental status which mimics many other conditions. The treatment was complicated by optic neuritis, an infected percutaneous lumbar drainage with methicillin resistant staphylococcus aureus (MRSA), and a suspected paradoxical reaction of IRIS. Whilst cranial nerve palsies and ophthalmoplegia are well documented complications of this disease, bilateral complete ophthalmoplegia is a rare presentation [23]. Our patient relapsed whilst on antifungal treatment despite an undetectable cryptococcal antigen on CSF analysis and continued to deteriorate despite antifungal therapy [24].

Subsequently, administration of corticosteroid treatment for suspected IRIS resulted in significant improvement in overall symptoms, but the optic neuritis symptoms persisted with poor visual acuity ending in permanent vision loss. This was a devastating outcome for the patient and may have been avoided with early diagnosis. The outcome was considered likely as a result of chronic raised intracranial pressure and the end result of cryptococcal meningitis. Reduced visual acuity is likely secondary to bilateral optic neuropathy or ischemia secondary to inflammation and cortical atrophy as a result of meningitis. However, this case report supports adjunctive corticosteroid therapy in the management of suspected cases of IRIS following *C. neoformans* meningitis treated with first-line antifungal treatment leading to initial overall improvement.

*Cryptococcus* are basidiomycetes that are encapsulated yeasts. *C. neoformans* and *C. gattii* are the chief pathogens in humans, and inhalation is the usual route of primary infection [25].

*C. neoformans* was originally discovered by Sanfelice in 1894 [4], and is a ubiquitous pathogen found in most temperate regions of the world commonly found in decaying organic matter and in many soil types, particularly that which has been enriched by animal and bird droppings [26]. In a retrospective study, 29 cases of cryptococcal infections were diagnosed in our local hospital region between 1997 and 2015 [3]. The reported overall mortality rate was 10.3 %, with an attributable mortality rate of 6.9 %. Forty-five per cent of patients with central nervous system (CNS) involvement developed long-term neurological deficits and this was attributed to delayed diagnosis as both time from onset of symptoms to diagnosis (median of 45.5 days versus 18.5 days, respectively) and time from presentation to diagnosis (median 14.5 days versus 7 days, respectively) differed compared to cases without CNS involvement [3]. Our patient was diagnosed well outside both median timeframes hence delayed diagnosis of *C. neoformans* continues to be a major problem not only in our region but worldwide [10,15].

Interestingly, raised intracranial pressure and female gender are significantly associated with poor neurological outcomes (both relevant to our patient) [3]. A more recent retrospective multi-centre analysis of immunocompetent patients diagnosed and treated for cryptococcal meningitis in Australia indicated 67 of the 143 cases (46.8 %) of cryptococcosis occurred in immunocompetent patients [2]. The relative risk of meningitis with a serum cryptococcal antigen >1:64 was 1.8 (95 % CI 1.15–2.82) [3]. This suggests that *C. neoformans* infections are relatively common in immunocompetent individuals and therefore needs to be considered as a differential diagnosis in the setting of non-specific neurological symptoms. A unique aspect of the case presented was disseminated disease in an immunocompetent patient [13]. We did not find any evidence of an immunodeficiency despite extensive investigation for acquired immunodeficiency, but an underlying sub-clinical immunodeficiency was possible. This is contradictory to the typical presentations of *C. neoformans* in immunocompetent patients [6–11].

Consideration of a wide range of differential diagnoses in clinical practice is always advised with thorough history taking and

**Table 1**

A summary of previous case studies on *Cryptococcus neoformans* infection in immunocompetent hosts.

| Author, year [reference]       | Country                   | Sex of participant | Age of participant (years) | Presenting complaint                                  | Time to diagnosis | Initial Cryptococcal titre in CSF | Management  |
|--------------------------------|---------------------------|--------------------|----------------------------|---|-------------------|-----------------------------------|---|
| (Mada et.al, 2017) [14]        | Shreveport, Louisiana USA | Male               | 56                         | Right Knee pain                                       | 4 weeks           | 1:1024                            | Liposomal amphotericin B 180 mg intravenous once daily for 2 weeks; Flucytosine 1500 mg every 6 hours orally for 2 weeks and Fluconazole orally for 1 year after induction therapy  |
| (Portelinha et al, 2014) [17]  | Lisbon, Portugal          | Female             | 57                         | Headache vomiting, photophobia and fatigue.           | 6 weeks           | 1:100                             | Amphotericin B at a dose of 300 mg/day for 70 days, flucytosine 1500 mg four times a day for 40 days and at day 40 she started fluconazole with maintenance (400 mg/day). Intravenous liposomal amphotericin (I-AMB) 3 mg/kg daily and 5-FC 25 mg/kg 6-hourly |
| (Somerville et. al, 2015) [28] | Westmead, Australia       | Female             | 36                         | Headache, blurred vision and ataxia                   | 2 months          | 1:4096                            | Intravenous liposomal amphotericin (I-AMB) 3 mg/kg daily and 5-FC 25 mg/kg 6-hourly   |
| (Chan et.al, 2017) [10]        | Boston, USA               | Female             | 75                         | Headache and confusion                                | 2 weeks           | –                                 | –   |
| (Kessler et.al, 2013) [15]     | Bern, Switzerland         | Female             | 41                         | Severe headache, fever and ophthalmoplegia            | 1–2 weeks         | Negative                          | Intravenous liposomal amphotericin B (5 mg/kg per day) and flucytosine (25 mg/kg four times a month).   |
| (Nakajima et. al, 2015) [24]   | Takatsuki, Japan          | Female             | 69                         | Loss of appetite, nausea, headache and fever          | 6 weeks           | 1:2,04                            | Liposomal amphotericin B (L-AMB; 5 mg/kg per day) and flucytosine (25 mg/kg four times a day)   |
| (Newsome et. al, 2014) [38]    | North Carolina, USA       | Male               | 23                         | Headache, weight loss, and multiple syncopal episodes | 8 weeks           | 1:1024                            | Amphotericin B, flucytosine and fluconazole; unreported doses.  |

Legend: The table contains data from previous case-reports reporting on *Cryptococcus neoformans* infection in immunocompetent individuals.

clinical examinations in atypical presentation with common symptoms [14]. The differential diagnosis for cryptococcal infection includes; Granulomatous diseases, cavernous sinus thrombosis, internuclear ophthalmoplegia or demyelinating lesions and Hepatitis B virus related vasculitis [15]. If suspecting a Cryptococcus presentation, screening for pulmonary, skin and neurological manifestations is essential [26,27]. An in-depth ocular examination is of importance to detect early signs of intracranial hypertension and ophthalmoplegia [17,18]. A brain CT-scan is not reliable in the case of *C. neoformans* encephalitis, nor raised intracranial hypertension; however, MRI and lumbar puncture are imperative as was seen in the case study. Upon suspicion of meningoencephalitis, investigation of Cryptococcus antigen in lumbar puncture is advised, regardless of the immune status of the patient [28].

A summary of previously reported case reports from a search of the literature on *C. neoformans* is provided below (Table 1). In immunocompetent patients, presentations predominate with isolated pulmonary Cryptococcus. A third of the patients were diagnosed incidentally on chest x-ray. Initial presenting symptoms included dyspnoea, dry cough and haemoptysis. Guidelines stipulate that confirmed pulmonary cryptococcoma should be treated with fluconazole 200 mg for 6–12 months regardless of the patients' immune status [29,30]. In asymptomatic pulmonary infection or post-surgical excision, treatment is still recommended.<sup>22</sup> This is however under the condition that they are to be strictly monitored clinically and be within stipulated laboratory guidelines [21,24]. The Updated Clinical Practice Guidelines for the Management of Cryptococcal Disease by the Infectious Diseases Society of America [31] stipulates that induction therapy for meningoencephalitis using fungicidal regimens, such as a polyene and flucytosine, followed by suppressive regimens using fluconazole, early recognition and treatment of increased intracranial pressure and IRIS; and the use of lipid formulations of amphotericin B regimens in patients with renal impairment are important considerations [5,32,33]. There is however much controversy on duration and type of treatment [21].

Our patient had persistent raised intracranial pressure despite the initial EVD shunt, complicated with optic neuritis [18,34]. This is known to lead to neurological sequelae or death within a period of 12 months in *C. gattii* meningoencephalitis but is not reported in *C. neoformans* [21]. High CSF pressure is conventionally controlled with serial lumbar punctures, or otherwise by neurosurgical intervention via EVD or VP shunts [34]. Our patient required neurosurgical intervention, and as an early neurological opinion was sought regarding recommendation for early intervention, neurosurgical intervention (within 1–2 weeks) was in order as frequent lumbar punctures did not adequately control CSF pressure [34]. The patient suffered neurological sequelae in the form of visual loss likely secondary to persistently high CSF pressures and an inflammatory optic neuritis leading to optic atrophy [18].

As mentioned the patient was managed with a 6-week IV induction treatment of liposomal amphotericin B and flucytosine and was diagnosed with IRIS at 7 weeks post commencement of anti-fungal treatment [5,24,35]. During antifungal therapy of cryptococcal meningitis, clinical deterioration may occur despite evidence of mycological response. This paradoxical heightened immune response is increasingly recognized in immunocompetent hosts [33,36]. IRIS is a recognised complication of *C. neoformans* treatment in immunocompromised patients and not very common in immune competent patients, typically manifesting as neurological symptoms of headache, fevers and meningism [21]. Brain imaging may identify new lesions or increased leptomeningeal enhancement, and lumbar puncture typically demonstrates a culture-negative pleocytosis as was the case in our patient. The

pathogenesis of IRIS has not been definitively defined. IRIS is characterized by an increase in immune regulatory natural killer (NK) cells and IFN- $\gamma$ -dependent factors such as monocyte attractant CXC motif chemokine (MCP-1) [37]. Such an inflammatory state is particularly problematic in cryptococcal meningitis, as the closed compartment of the brain within the skull allows little expansion with inflammation or cerebral oedema [33,34]. There is much controversy regarding the management of severe cases of cryptococcal meningitis as response to steroids are unexpected and host-specific immune characterizations are poorly understood.

Specific risk factors for the development of cryptococcal IRIS in immunocompromised people include a shorter duration between cryptococcal diagnosis and antiretroviral drug initiation, low CD4 counts (<100 cells/ $\mu$ l), higher baseline plasma HIV RNA levels; and higher CSF cryptococcal antigen titres or CSF opening pressures, WBC count, and glucose levels. Unlike many other forms of IRIS, which produce less dramatic consequences, Cryptococcus associated IRIS is exceptional for its substantial morbidity and mortality and cases are seldom reported in immunocompetent individuals [37].

For major manifestations such as raised ICP, treatment guidelines recommend corticosteroid therapy [31]. The early initiation of steroids is proposed in order to minimise the neurological complications and permanent sequelae.<sup>31</sup> Manifestations of IRIS include worsening, or relapse, of clinical symptoms with or without radiological findings as described earlier [22]. The duration of time from CSF culture clearance and onset of IRIS can be up to three months due to often negative antigen titres and evidence of bacterial meningitis, despite lumbar percutaneous drainage of infection [21]. Here we demonstrate how IRIS was successfully managed with high-dose intravenous corticosteroids, followed by an oral course that was tapered over 6 months [31].

## Conclusion

This case study highlights the importance of early diagnosis and the need to limit raised intracranial pressure to minimize long-term neurological deficits in immunocompetent patients with *C. neoformans* [10,21,33]. The literature related to management has been reviewed and there appears to be limited case reports on the manifestation of IRIS in immunocompetent individuals with *C. neoformans* [31]. Atypical presentations of *C. neoformans* are rare, nevertheless require careful consideration in the clinical setting. Regardless of immune status, a thorough clinical examination followed by early diagnosis and management is crucial in order to prevent the occurrence of sinister complications such as optic neuritis from raised intracranial pressure.

## Contributions

RK was the lead clinician and senior registrar responsible for the management of the patient, provided overall guidance on clinical care, guideline review, and chart-review, sought consent for publication, carried out literature searches and formatted and edited the manuscript for publication. SNZ was the senior consultant physician responsible for the management of the patient, provided overall guidance on clinical care, the structure and write-up of the case report and editing the report for publication. MF was the lead academic on the paper, was responsible for the overall governance, guidance and structure of the case report, helped with literature searches, analysis of literature, formatting of the tables and figures and text and drafted and edited the manuscript for publication.

## Role of the funding source

This study was not funded.

## Declaration of Competing Interest

None of the authors have any conflicts of interest to disclose with regards to this paper.

## Acknowledgements

We wish to thank the patient and her next of kin for providing their support and consent to publish this article with the aim that others can learn from their experience.

## References

- Martinez LR, Garcia-Rivera J, Casadevall A. Cryptococcus neoformans var. neoformans (serotype D) strains are more susceptible to heat than C. neoformans var. grubii (serotype A) strains. *J Clin Microbiol* 2001;39:3365–7.
- Aye C, Henderson A, Yu H, Norton R. Cryptococcosis—the impact of delay to diagnosis. *Clin Microbiol Infect* 2016;22(7):632–5.
- Gassiep I, Aye C, Armstrong M, Emoto TI, Heather CS, Norton RE. Correlation between serum cryptococcal antigen titre and meningitis in immunocompetent patients. *J Med Microbiol* 2018;67(10):1515–8.
- Park BJ, Wannemuehler KA, Marston BJ, Govender N, Pappas PG, Chiller TA. Estimation of the current global burden of cryptococcal meningitis among persons living with HIV/AIDS. *AIDS* 2009;23(4):525–30.
- Graybill JR, Sobel J, Saag M, et al. Diagnosis and management of increased intracranial pressure in patients with AIDS and cryptococcal meningitis. The NIAID Mycoses Study Group and AIDS Cooperative Treatment Groups. *Clin Infect Dis* 2000;30(1):47–54.
- Haddad N, Cavallaro MC, Lopes MP, et al. Pulmonary cryptococcoma: a rare and challenging diagnosis in immunocompetent patients. *Autops Case Rep* 2015;5(2):35–40.
- Hemant RG, Ayaz MA, Balaram RY, Samkit M. Pulmonary cryptococcoma presenting as endobronchial mass mimicking malignancy in immunocompetent host. *Lung India* 2015;(5):537.
- Ho CL, Chang BC, Hsu GC, Wu CP. Pulmonary cryptococcoma with CD4 lymphocytopenia and meningitis in an HIV-negative patient. *Respir Med* 1998;92(1):120–2.
- Nadrous HF, Antonios VS, Terrell CL, Ryu JH. Pulmonary cryptococcosis in nonimmunocompromised patients. *Chest* 2003;124(6):2143–7.
- Chan IS, Chudasama R, Burrows AB. Delayed diagnosis of disseminated cryptococcosis with associated meningoencephalitis in an immunocompetent septuagenarian host. *Am J Med* 2017;130(1):e31–2.
- Patel C, Rabindra R, Hashemi N, Ward M, Mannan JM. Chronic meningitis: a diagnostic challenge highlighted in a case of cryptococcal meningoencephalitis in an apparently immunocompetent older woman. *BMJ Case Rep* 2011;11: 2011.
- Mitchell DH, Sorrell TC, Allworth AM, et al. Cryptococcal disease of the CNS in immunocompetent hosts: influence of cryptococcal variety on clinical manifestations and outcome. *Clin Infect Dis* 1995;20(3):611–6.
- Lu CH, Chang WN, Chang HW, Chuang YC. The prognostic factors of cryptococcal meningitis in HIV-negative patients. *J Hosp Infect* 1999;42(4):313–20.
- Mada P, Nowack B, Cady B, Joel Chandranesan AS. Disseminated cryptococcosis in an immunocompetent patient. *BMJ Case Rep* 2017;2017:.
- Kessler B, Bally F, Hewer E, Sendi P. Delayed diagnosis of cryptococcal meningoencephalitis due to negative cryptococcal antigen test. *BMJ Case Rep* 2013;2013:.
- Broom J, Woods 2nd M, Allworth A. Immune reconstitution inflammatory syndrome producing atypical presentations of cryptococcal meningitis: case report and a review of immune reconstitution-associated cryptococcal infections. *Scand J Infect Dis* 2006;38(3):219–21.
- Portelinha J, Passarinho MP, Almeida AC, Costa JM. Bilateral optic neuropathy associated with cryptococcal meningitis in an immunocompetent patient. *BMJ Case Rep* 2014;2014:.
- Seaton RA, Verma N, Naraqi S, Wembri JP, Warrell DA. The effect of corticosteroids on visual loss in *Cryptococcus neoformans* var. *gattii* meningitis. *Trans R Soc Trop Med Hyg* 1997;91(1):50–2.
- Anil AP, Simone CW, Yen-Chih L, et al. Paradoxical immune responses in non-HIV cryptococcal meningitis. *PLoS Pathog* 2015(5)e1004884.
- Einsiedel L, Gordon DL, Dyer JR. Paradoxical inflammatory reaction during treatment of *Cryptococcus neoformans* var. *gattii* meningitis in an HIV-seronegative woman. *Clin Infect Dis* 2004;39(8):e78–82.
- O'Brien MP, Ford TJ, Currie BJ, Francis JR. *Cryptococcus gattii* infection complicated by immune reconstitution inflammatory syndrome in three apparently immunocompetent children. *J Paediatr Child Health* 2018.
- Wiesner DL, Boulware DR. Cryptococcus-related immune reconstitution inflammatory syndrome(IRIS): pathogenesis and its clinical implications. *Curr Fungal Infect Rep* 2011;5(4):252–61.
- Liyanage DS, Pathberiya LPS, Gooneratne IK, Caldera MHPC, Perera PWS, Gamage R. Cryptococcal meningitis presenting with bilateral complete ophthalmoplegia: a case report. *BMC Res Notes* 2014;7:328.
- Nakajima H, Takayama A, Fujiki Y, Ito T, Kitaoka H. Refractory *Cryptococcus neoformans* meningoencephalitis in an immunocompetent patient: paradoxical antifungal therapy-induced clinical deterioration related to an immune response to cryptococcal organisms. *Case Rep Neurol* 2015;7(3):204–8.
- Sloan DJ, Parris V. Cryptococcal meningitis: epidemiology and therapeutic options. *Clin Epidemiol* 2014;13(May (6)):169–82.
- Franzot SP, Salkin IF, Casadevall A. *Cryptococcus neoformans* var. *grubii*: separate varietal status for *Cryptococcus neoformans* serotype A isolates. *J Clin Microbiol* 1999;37(3):838–40.
- Thompson HJ. Not your 'typical patient': cryptococcal meningitis in an immunocompetent patient. *J Neurosci Nurs* 2005;37(3):144–8.
- Somerville LK, Henderson AP, Chen SC, Kok J. Successful treatment of *Cryptococcus neoformans* immune reconstitution inflammatory syndrome in an immunocompetent host using thalidomide. *Med Mycol Case Rep* 2014;7:12–4.
- Pappas P. Therapy of cryptococcal meningitis in non-HIV-infected patients. *Curr Infect Dis Rep* 2001;3(4):365.
- Pappas PG, Perfect JR, Cloud GA, et al. Cryptococcosis in human immunodeficiency virus-negative patients in the era of effective azole therapy. *Clin Infect Dis* 2001;33(5):690–9.
- Perfect JR, Dismukes WE, Dromer F, et al. Clinical practice guidelines for the management of cryptococcal disease: 2010 update by the infectious diseases society of America. *Clin Infect Dis* 2010;50(3):291–322.
- Abassi M, Boulware DR, Rhein J. Cryptococcal meningitis: diagnosis and management update. *Curr Trop Med Rep* 2015;2(2):90–9.
- Jarvis JN, Harrison TS. Understanding causal pathways in cryptococcal meningitis immune reconstitution inflammatory syndrome. *J Infect Dis* 2019;219(3):344–6.
- Foong KS, Lee A, Vasquez G. Cryptococcal infection of the ventriculoperitoneal shunt in an immunocompetent patient. *Am J Case Rep* 2016;17:31–4.
- Chen SCA, Korman TM, Slavin MA, et al. Antifungal therapy and management of complications of cryptococcosis due to *Cryptococcus gattii*. *Clin Infect Dis* 2013;57(4):543–51.
- Haddow LJ, Colebunders R, Meintjes G, et al. Cryptococcal immune reconstitution inflammatory syndrome in HIV-1-infected individuals: proposed clinical case definitions. *Lancet Infect Dis* 2010;10(11):791–802.
- Sharma SK, Soneja M. HIV & immune reconstitution inflammatory syndrome (IRIS). *Indian J Med Res* 2011;134(6):866–77.
- Newsome J, Nguyen D. Cryptococcal meningitis caused by *Cryptococcus neoformans* in an immunocompetent soldier. *Mil Med* 2014;179(9):e1059–61.