

# A comparative study of knotless versus knotted transscleral suture-fixed intraocular lens implantation

Sami Yilmaz, Aysegul Mavi Yildiz, Remzi Avci

**Purpose:** To compare functional outcomes and complication rates of two scleral fixated intraocular lens implantation (SFIOL) techniques. **Methods:** In this retrospective study, there were 30 eyes of 30 patients who underwent SFIOL implantation for dislocation of the IOL or crystalline lens. Group 1 (n = 17) comprised patients who received scleral-fixated polymethylmethacrylate (PMMA) IOL implantation through a self-sealing sclerocorneal tunnel with the suture burial technique, and group 2 (n = 13) comprised patients who received scleral-fixated foldable acrylic IOL implantation with a cartridge using a self-sealing clear corneal incision (CCI) with knotless Z-suture technique between 2014 and 2019. Surgical outcomes concerning safety, efficiency, visual function, induced astigmatism with vector analysis, and complications were compared. **Results:** The indications were dislocated crystalline lens (n = 5/30), dislocated IOL (n = 17/30), and dropped nucleus (n = 8/30). The mean follow-up time was 50.65 ± 14.02 months in group 1 and 15.69 ± 3.71 months in group 2 (P < 0.001). The postoperative visual acuity improvement was statistically significant in both groups (P < 0.001). Surgically induced astigmatism was significantly higher in group 1 (2.68 ± 1.04 D) compared with group 2 (1.6 ± 1.0 D) at month 12 (P = 0.001). Postoperative complications included suture exposure (n = 1 in group 1) and cystoid macular edema (n = 1 in group 1; n = 1 in group 2). **Conclusion:** Both SFIOL techniques are safe and effective in the absence of adequate capsular support. However, the knotless Z-suture technique appears to be superior to the suture burial technique with regard to suture exposure-related complications. In addition, self-sealing CCI appears to be superior to self-sealing sclerocorneal tunnel with regard to surgically induced astigmatism.

**Key words:** Myopic shift, refraction, scleral-fixated intraocular lens

The primary indication for scleral fixated intraocular lens implantation (SFIOL) is the lack of adequate capsular/zonular support. Complicated cataract surgery and blunt or penetrating ocular trauma are the leading causes of capsular/zonular damage.<sup>[1,2]</sup> In such cases, SFIOL may be a good alternative to provide adequate optical rehabilitation.

Malbran *et al.*<sup>[3]</sup> first published the technique of sutured scleral-fixated IOLs for the management of aphakia in the 1980s. Later, various methods of IOL placement via scleral fixation were defined in the early 1990s.<sup>[4,5]</sup> All these techniques included the use of nonabsorbable sutures tied over the sclera to stabilize the IOL. However, leaving a suture knot often results in suture exposure, irritation, and increased risk of endophthalmitis. Scleral flaps, autologous cornea, and dura mater or fascia lata patches have been discussed in the literature to prevent conjunctival erosion.<sup>[6-8]</sup> Baykara<sup>[9]</sup> first described the scleral suture burial technique in 2004. Later in 2010, Szurman *et al.*<sup>[10]</sup> introduced the knotless Z-suture technique to avoid suture exposure-related complications.<sup>[9,10]</sup>

Since the SFIOL technique was first introduced, various modifications of the surgical steps and materials have been tried to achieve a simpler, safer, and more effective surgery. Options for IOL include polymethylmethacrylate (PMMA) or

acrylic IOL with suture eyelets. A 10.0 or 9.0 double-armed polypropylene suture and straight or curved needle are commonly used for scleral fixation of the IOL.<sup>[11]</sup>

The aim of this study was to compare the visual, refractive outcomes, and complication rates of two SFIOL techniques: scleral-fixated PMMA IOL implantation through a self-sealing 6.5-mm scleral tunnel incision using the suture burial technique, and an acrylic foldable scleral-fixated IOL implantation through a self-sealing 2.4-mm clear corneal incision (CCI) using the knotless Z-suture technique in patients with a history of ocular blunt trauma or complicated cataract surgery.

## Methods

This was a retrospective, comparative case series including patients who underwent SFIOL implantation. Group 1 comprised patients who received scleral-fixated PMMA IOL implantation through a self-sealing sclerocorneal tunnel using the suture burial technique between July 2014 and February 2018, and group 2 comprised patients who received an acrylic foldable scleral-fixated IOL implantation through a self-sealing

This is an open access journal, and articles are distributed under the terms of the Creative Commons Attribution-NonCommercial-ShareAlike 4.0 License, which allows others to remix, tweak, and build upon the work non-commercially, as long as appropriate credit is given and the new creations are licensed under the identical terms.

For reprints contact: WKHLRPMedknow\_reprints@wolterskluwer.com

Cite this article as: Yilmaz S, Mavi Yildiz A, Avci R. A comparative study of knotless versus knotted transscleral suture-fixed intraocular lens implantation. *Indian J Ophthalmol* 2022;70:131-7.

Videos Available on:  
www.ijo.in

Access this article online

Website:  
www.ijo.in

DOI:  
10.4103/ijo.IJO\_551\_21

Quick Response Code:



Department of Ophthalmology, Bursa Retina Eye Hospital, Bursa, Turkey

Correspondence to: Dr. Aysegul Mavi Yildiz, Bursa Retina Eye Hospital, Bursa, Turkey. E-mail: dramavi85@hotmail.com

Received: 09-Mar-2021

Revision: 07-Jun-2021

Accepted: 24-Aug-2021

Published: 23-Dec-2021

CCI using the knotless Z-suture technique between February 2018 and March 2019 at Bursa Retina Eye Hospital. Informed consent was obtained from all the participants. All participants provided written consent for the use of clinical findings and relevant figures in this publication. The study was conducted in line with the ethical standards of the Helsinki Declaration.

### Patient eligibility

**Inclusion criteria.** Patients who underwent SFIOL implantation due to subluxation (6 or more o'clock hours involved) and luxation of the lens with a minimum follow-up of 12 months were included.

**Exclusion criteria.** Patients aged <18 years, patients with glaucoma history, high myopia, corneal disorders (scar, haze), penetrating ocular trauma history, and hereditary eye disorders (Marfan syndrome, Stargardt disease, and retinitis pigmentosa) were excluded.

### Ocular parameters

All patients underwent complete ophthalmic examinations, including best-corrected visual acuity (BCVA) in the logMAR scale, slit-lamp examination, intraocular pressure (IOP) assessment, fundus examination and autokeratorefractometry (auto kerato-refractometer KR-8800 from Topcon, Tokyo, Japan), at baseline and postoperative month 12. IOL spherical power calculations (SRK/T formula from Nidek Optical Biometer-AL Scan, Nidek Co. Ltd., Japan) were also performed preoperatively. The IOL power calculations were obtained from the fellow eye of the same patient in the event of opaque media in the affected eye. Post-surgical astigmatism values were calculated using a vector analysis software and vector graphs were generated using AstigMATIC [Figs. 1 and 2].<sup>[12,13]</sup>

### Surgical procedures

All surgeries were performed by the same surgeon (S.Y.). Retrobulbar block anesthesia (a mixture of 2 ml of lidocaine hydrochloride 2% and 2 ml of bupivacaine hydrochloride 0.5%) was used. 23-G transconjunctival pars plana vitrectomy (PPV) was performed using the vitrectomy system DORC (Dutch Ophthalmic Research Center, Zuidland, Netherlands) and Zeiss microscope with EIBOS 2 (Haag Streit, Mason, OH, USA) attachment for noncontact fundus viewing.

For patients who underwent PPV, initially, standard core vitrectomy was performed and the vitreous surrounding the luxated IOL or crystalline lens was shaved to free the lens. The

vitrectomy probe or an intravitreal fragmatome was used to remove the luxated crystalline lens depending on the hardness of the nucleus. The luxated IOL was grasped using intraocular forceps and brought into the anterior chamber (AC). Then, in group 1, the IOL was explanted through the sclerocorneal tunnel (described below). In group 2, the IOL was cut into two pieces using lens-cutting scissors and explanted via a 2.4-mm CCI. After IOL or crystalline lens removal, a near-complete vitrectomy and vitreous base shaving was performed. Additionally, laser endo-photocoagulation, and a nonexpansile mixture of C3F8 gas tamponade was used in cases of coexisting retinal detachment or retinal tear and lens implantation was deferred to a second session.

For patients who underwent anterior vitrectomy, initially, an anterior chamber maintainer was inserted through the inferotemporal corneal side port. Subsequently, a fornix-based conjunctival flap was created in the superior quadrant, and episcleral vessels were cauterized in group 1. A 6.5-mm half-thickness, scleral tunnel incision was made approximately 2 mm behind the limbus. A sclerocorneal tunnel was created from the initial scleral incision to 1 mm inside the cornea about 50% scleral and corneal thickness by using a crescent knife. Then, subluxated IOL was grasped using forceps and brought into the AC and removed through the sclerocorneal tunnel. In group 2, a 2.4-mm CCI was performed. Subsequently, the subluxated IOL was grasped using microforceps and brought into the AC. The IOL was cut into two pieces by using lens-cutting scissors and the pieces were removed from the CCI. Then, anterior vitrectomy was performed using a 23-G vitrectomy system.

**IOL implantation:** Two conjunctival flaps were prepared 180° apart, following cauterization of the episcleral vessels. The locations of needle entrances were marked 2 mm apart from the limbus at the 3 and 9 o'clock positions. A 10-0 double-armed polypropylene (Prolene, Ethicon) suture and a straight needle and a bent 27-G needle were inserted from opposing sides through the marked sclera. The straight needle was pushed as far as possible into the lumen of the 27-G needle. The 27-G needle was then slowly taken out of the sclera. Then 10-0 polypropylene was pulled outside the eye through the sclerocorneal tunnel or CCI with a hook or forceps. The suture was cut into two parts.

In group 1, the preferred IOL type was a single-piece scleral-fixated PMMA with haptic suture eyelets (OSF 651, Optima Lens, Excellent Hicare Pvt Ltd, India). The free ends of

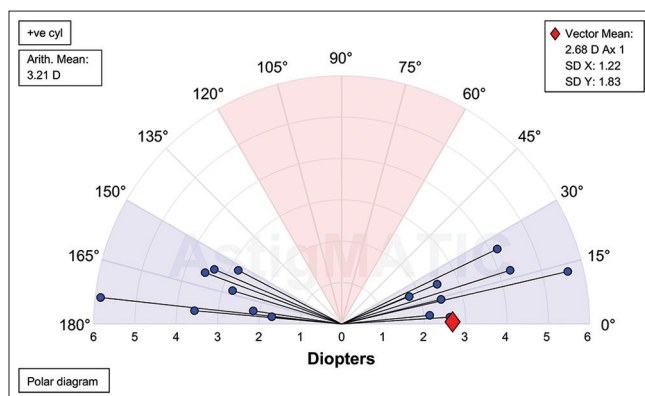


Figure 1: Surgically induced astigmatism vector graph of group 1

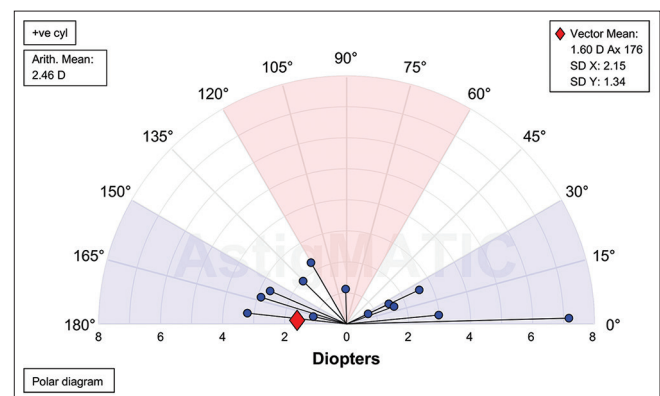


Figure 2: Surgically induced astigmatism vector graph of group 2



the sutures were tied to eyelets of the haptic of the PMMA IOL. The PMMA IOL was inserted into the ciliary sulcus through the sclerocorneal tunnel. Subsequently, the free ends of the sutures were buried into the sclera as described by Baykara.<sup>[9]</sup> There was no leakage from the sclerocorneal tunnel in any patients [Video 1].

In group 2, the preferred IOL type was a scleral fixation-acrylic foldable IOL with a two-plate loop design (Optima Fold Lens, Excellent Hicare Pvt Ltd, India) (optic size: 6.5 mm, overall size: 13.75 mm). The reason we chose this IOL was that it could be implanted via a disposable injector and 2.4-mm cartridge. The free end of the suture was passed through the 2.4-mm opening of the cartridge and it was pulled through the cartridge using microforceps. Then, the cartridge was fixed with a sterile band on the superior part of the surgical drape for stabilization. One of the free ends of the suture that passed through the cartridge was tied to the central hole of the haptic, which would first enter into the AC. Viscoelastic was injected into the AC and the cartridge. The IOL was inserted into the cartridge. Then, the sterile band was removed from the cartridge, which was then inserted into the disposable injector. Subsequently, the tied haptic part and optic part of the IOL were injected into the AC, but the sutureless haptic of the IOL was left out of the cornea. The disposable injector and the cartridge were removed from the surgical area. The other free end of the suture was tied to the central hole of the haptic of the IOL, and the entire IOL was inserted into the AC. The IOL was gently pushed behind the iris using an IOL manipulator. The sutures were slowly pulled and the IOL was secured in a central position behind the iris. Next, a knotless Z-suture was performed to stabilize the IOL as described by Szurman *et al.*<sup>[10]</sup> Then, the suture was cut without knotting. The CCI was self-sealing, and mild edema was induced around the incision site through hydration. The conjunctival flaps were closed using an 8-0 polyglactin suture (Vicryl) [Figs. 3 and 4; Video 2].

### Statistical analysis

The normality of data distribution was evaluated using the Shapiro–Wilk test. Numerical variables were compared

between the two groups using the Mann–Whitney U test, and the Wilcoxon signed-rank test was used to compare dependent variables in the same group. The association between categorical variables was assessed using the Chi-square test and Fisher's exact test.  $P < 0.05$  were considered statistically significant for all analyses. All statistical analyses were performed using the IBM SPSS Statistics for Windows, version 21.0 software (IBM, Corp, Armonk, NY).

## Results

A total of 30 patients were recruited, 17 of whom were included in group 1 and 13 were in group 2. No statistically significant difference was detected between the groups concerning age, sex, and baseline ocular features, including eye laterality, indications for surgery, BCVA, IOP, cylindrical error, dioptric power of IOL, and target spheric equivalent.

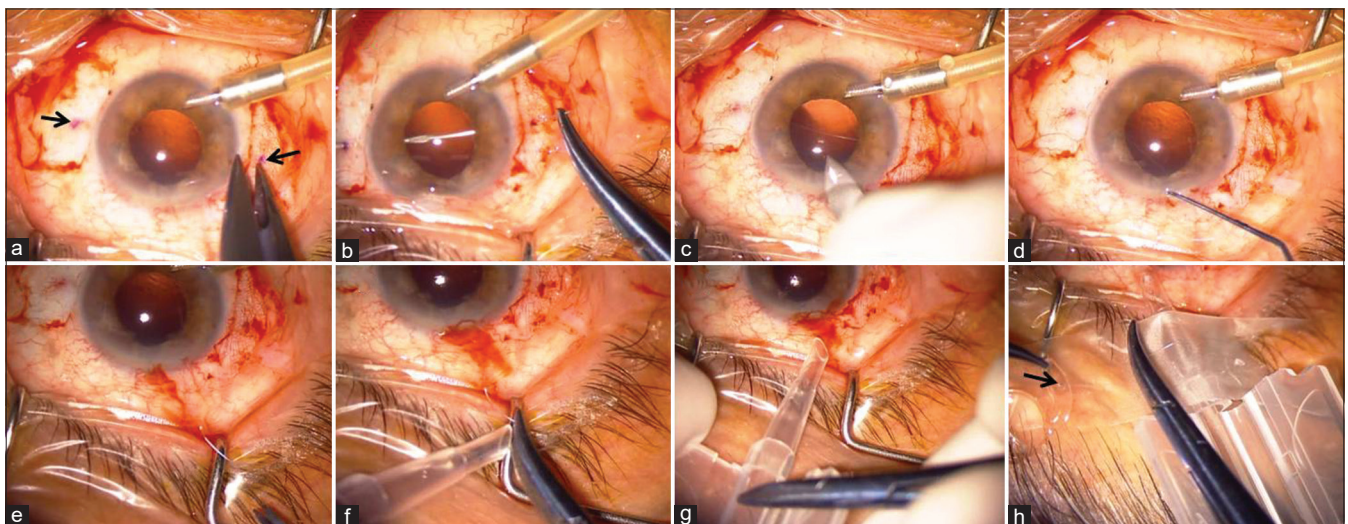
### Preoperative data

In group 1, we detected ocular hypertension (IOP over 25 mm Hg) in six (35.3%) eyes, retinal tear in one (5.9%) eye, traumatic iridodialysis ( $\leq 3$  hours involved) in two (11.8%) eyes, and intraocular hemorrhage in three (17.7%) eyes.

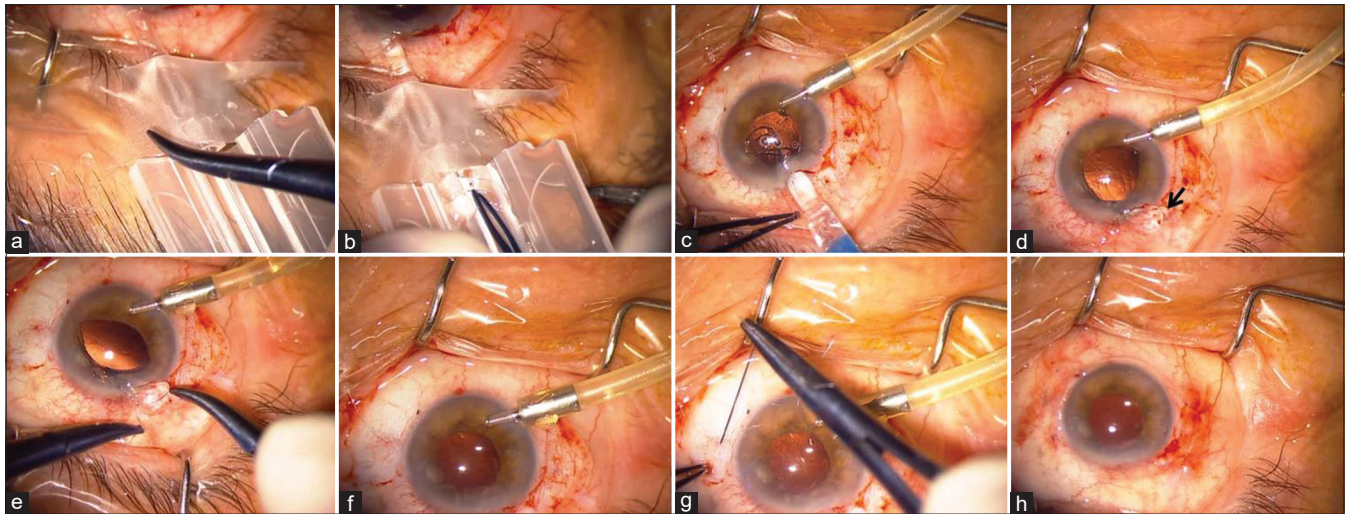
In group 2, we detected ocular hypertension (IOP over 25 mm Hg) in four (30.8%) eyes; retinal tear in three (23.1%) eyes; traumatic iridodialysis ( $\leq 3$  hours involved) in one (7.6%) eye; intraocular hemorrhage in four (30.8%) eyes; and superior temporal, macula-on rhegmatogenous retinal detachment in one (7.6%) eye. The baseline characteristics and preoperative data of the groups are presented in Table 1.

### Operative data

In group 1, 12 (70.6%) patients underwent simultaneous PPV and SFIOL implantation and four (23.5%) underwent simultaneous anterior vitrectomy and SFIOL implantation. However, one (5.9%) patient with retinal tear underwent PPV and 4% perfluoropropane (C3F8) gas tamponade in the first session and subsequent SFIOL implantation at month 3.



**Figure 3:** The needle entrances were marked 2 mm from the limbus (black arrows) (a). A 10-0 double-armed polypropylene suture, a straight needle, and a bent 27-G needle were inserted from opposed sides (b). A 2.4-mm CCI was made (c). 10-0 polypropylene was pulled out through the CCI (d) and the suture was cut into two parts (e). The free end of the suture was passed through the cartridge (f) and pulled with microforceps (g). The cartridge was fixed with a sterile tape and a free end of the suture was passed through the central hole of the haptic (black arrow) (h)



**Figure 4:** The free end of the suture was tied to the central hole of the haptic (a). The IOL was inserted into the cartridge (b). The tied haptic and optic were injected into AC (c). The second haptic was left outside the corneal incision (black arrow) (d). The other free end of the suture was tied (e). The entire IOL was inserted into AC and gently pushed behind the iris (f). A knotless Z-suture was performed (g). Conjunctiva is closed with 8-0 polyglactin suture and CCI is hydrated to prevent wound leakage (h)

**Table 1: The baseline characteristics and preoperative data of the two groups**

	Group 1 Suture burial method	Group 2 Knotless Z-suture method	<i>P</i>
Number	17	13	
Eyes, <i>n</i> (%)			0.269*
Right	7 (41.2)	8 (61.5)	
Left	10 (58.8)	5 (38.5)	
Sex, <i>n</i> (%)			0.515**
Female	5 (29.4)	3 (23.1)	
Male	12 (70.6)	10 (76.9)	
Age (years)			0.773***
Mean±SD	67.29±10.34	68.54±11.14	
Reason for surgery, <i>n</i> (%)			0.638*
Ocular blunt trauma	9 (52.9)	8 (61.5)	
Complicated cataract surgery	8 (47.1)	5 (38.5)	
Lens status, <i>n</i> (%)			0.314 <sup>†</sup>
Subluxated crystalline lens	0	1 (7.6)	
Luxated crystalline lens	1 (5.9)	3 (23.1)	
Subluxated IOL	4 (23.5)	3 (23.1)	
Luxated IOL	7 (41.2)	3 (23.1)	
Retained crystalline lens	5 (29.4)	3 (23.1)	
IOP (mm Hg)			0.398***
Mean±SD	22.9±9.6	19.54±7.17	
BCVA (logMAR)			0.475***
Mean±SD	2.04±1.04	1.74±1.12	
IOL power (D)			0.589***
Mean±SD	21.59±2.19	21.08±2.27	
Cylindrical error (D)			0.121***
Mean±SD	0.91±0.61	1.35±0.88	
Predicted SE (D)			0.592***
Mean±SD	-0.65±0.36	-0.53±0.42	
Follow-up (months)			<0.001***
Mean±SD	50.65±14.02	15.69±3.71	

IOL, Intraocular lens. IOP, Intraocular pressure. BCVA, Best-corrected visual acuity. *P* is the statistical level between group 1 and group 2. *P*<0.05 was considered significant. logMAR, logarithm of minimal angle of resolution. SD, Standard deviation. D, Dioptre. SE, Spheric error. \*Chi-square Test. \*\*Fisher's exact test. \*\*\*Mann-Whitney U test. <sup>†</sup>Fisher's exact test was used with combined subgroups according to the subluxation or luxation of the lens (retained crystalline lens material was accepted in the dislocated group due to retained material was located into vitreous.)



In group 2, six (46.2%) patients underwent simultaneous PPV and SFIOL implantation and three (23.1%) underwent anterior vitrectomy with SFIOL implantation. The remaining four (30.7%) patients underwent PPV with 4% or 8% C3F8 gas tamponade due to concomitant retinal tear and/or rhegmatogenous retinal detachment, respectively. SFIOL implantation was performed 3 months following the first surgery.

### Postoperative data

The postoperative visual acuity improvement was statistically significant in both groups ( $P < 0.001$ ).

The surgically induced astigmatism was significantly higher in group 1 compared to group 2 ( $P = 0.001$ ) [Table 2]. In terms of complications, cystoid macular edema was observed in one (5.9%) eye in group 1 and one (7.7%) eye in group 2 ( $P = 0.687$ ), both of which were treated with sub-Tenon corticosteroid injections and topical nonsteroidal medication. An IOP (over 25 mm Hg) increase on day 1 was observed in two (11.8%) eyes in group 1 and one (7.7%) eye in group 2 ( $P = 0.580$ ) and was successfully treated with topical anti-glaucomatous eye drops. Exposure of the Prolene suture was observed only in one (5.9%) eye in group 1 ( $P = 0.567$ ) that was treated with conjunctival flap coverage. Post-traumatic mydriasis was noted due to a tear in the iris sphincter in two (11.8%) eyes in group 1 and two (14.4%) eyes in group 2 ( $P = 0.591$ ). No other severe postoperative complications in terms of suture breakage, lens dislocation, hemorrhage, retinal tear, retinal detachment, corneal compromise, or endophthalmitis, was detected in any patients in either group. Operative and postoperative data of the groups are presented in Table 2.

## Discussion

Ocular trauma, complicated cataract surgery, pseudoexfoliation syndrome, and certain systemic diseases accompanied by zonular weakness may result in dislocation of the IOL or crystalline lens. In such cases, there is no consensus among ophthalmologists regarding the ideal IOL type and implantation technique including AC IOL, iris-fixated IOL, and SFIOL. It is shown in the literature that all three techniques may improve visual function with their respective advantages and disadvantages.<sup>[14-16]</sup>

The type of the dislocated IOL is also important in surgical planning. A dislocated 3-piece foldable IOL can be fixated to the sclera by using sutures or by inserting the haptics into the sclera without explanting the IOL. However, a dislocated PMMA or single-piece foldable IOL generally requires exchange surgery.<sup>[17]</sup> In the current study, as all the dislocated IOLs were PMMA or single-piece foldable IOLs, the surgeon preferred to exchange the dislocated IOL with an SFIOL. In the literature, it is stated that both primary and secondary IOL implantation can provide favorable visual outcomes.<sup>[18,19]</sup> Therefore, the decision of a primary or secondary IOL implantation generally depends on coexisting corneal and retinal pathologies and the surgeon's preference. In the current study, the timing of the IOL implantation mainly depended on whether a concomitant retinal pathology existed. We preferred secondary implantation if there was a retinal tear or detachment requiring gas tamponade to avoid forward shift of the IOL.

By contrast, SFIOL can be performed with or without using sutures. Malbran *et al.*<sup>[9]</sup> first introduced the SFIOL

**Table 2: The operative and postoperative data of the two groups**

	Group 1 Suture burial method	Group 2 Knotless Z-suture method	P
Surgery, n (%)			0.660*
PPV with SFIOL	12 (70.6)	6 (46.2)	
Anterior vitrectomy with SFIOL	4 (23.5)	3 (23.1)	
First PPV and secondary SFIOL	1 (5.9)	4 (30.7)	
IOP at day 1 (mm Hg)			
Mean±SD	15.5±6.28	15.2±5.7	0.983**
IOP at month 12 (mm Hg)			
Mean±SD	12.94±4.09	13.92±6.8	0.948**
BCVA at month 12 (logMAR)			
Mean±SD	0.35±0.25	0.38±0.23	0.714**
Spheric error at month 12 (D)			
Mean±SD	0.58±1.46	0.88±1.21	0.467**
Cylindrical error at month 12 (D)			
Mean±SD	-2.53±0.89	-1.83±1.55	0.013**
SE at month 12 (D)			
Mean±SD	-0.69±1.32	-0.01±1.06	0.130**
Induced astigmatism with vector analysis at month 12 (D)			
Mean±SD	2.68±1.04	1.6±1.0	0.001**
Complication, n (%)			
Suture exposure	1 (5.9)	∅	0.567***
CME	1 (5.9)	1 (7.7)	0.687***

SFIOL, Scleral fixated intraocular lens. PPV, Pars plana vitrectomy. BCVA, Best-corrected visual acuity. P is the statistical level between group 1 and group 2.  $P < 0.05$  was considered significant. logMAR, logarithm of minimal angle of resolution. SD, Standard deviation. D, Dioptre. SE, Spheric error. CME, Cystoid macular edema. \*Fisher's exact test was used with combined subgroups according to PPV or anterior vitrectomy. \*\* Mann-Whitney U test. \*\*\*Fisher exact test

technique using sutures. Since then, various modifications of this technique have been described in the literature.<sup>[2,20,21]</sup> However, leaving a suture knot directly under the conjunctiva often leads to suture exposure, resulting in an elevated risk of endophthalmitis.<sup>[22]</sup> Therefore, numerous techniques to cover the free suture ends have been proposed, including scleral flaps, scleral pockets, and grafting with fascia lata.<sup>[17,23-25]</sup> Solomon *et al.*<sup>[26]</sup> reported a 73% rate of suture exposure and 17% of conjunctival erosion despite burying the knot under the scleral flap. To avoid suture-related complications, Baykara described a suture burial technique for SFIOL in 2004. Subsequently, Szurman *et al.*<sup>[10]</sup> reported a knotless Z-suture technique in 2010.<sup>[9]</sup> Baykara and Timucin reported no intraoperative or postoperative complications with the suture burial method during 24 months of follow-up.<sup>[27]</sup> However, we detected conjunctival suture erosion in one (5.9%) patient in group 1 at postoperative month 30. This case was a 71-year-old male with thin conjunctiva and Tenon's layer, which may have facilitated the suture exposure.

In the literature, failure of IOL implantation due to suture breakage rate varies between 1.2% and 40%; however, only a few studies have reported long-term outcomes of Z-sutured scleral fixation.<sup>[28,29]</sup> Kandemir *et al.*<sup>[30]</sup> reported a 2.2% rate of suture loosening with the Z-suture method. In the current study, none of the patients presented with suture breakage and suture loosening during follow-up. No suture exposure was observed in group 2. Due to the knotless structure of the Z-suture technique, it may be more advantageous than the suture burial method regarding suture knot exposure, especially for older patients with thin conjunctiva and Tenon's layer. Both sclerocorneal tunnel and corneal incisions may cause induced astigmatism, depending on the length, shape, and location of the incision.<sup>[31-33]</sup> In the current study, surgically induced astigmatism was more common in group 1 than in group 2. Although there is no consensus on the target spherical equivalent value for SFIOL, Abbey *et al.*<sup>[34]</sup> reported relative success using -1.00 D target refraction for the in-the-bag IOL calculation. Regarding variable refractive results of SFIOL, a goal of mild residual myopia can be helpful to avoid a hyperopic surprise. In this study, the mean target SE was -0.65 D in group 1 and -0.53 D in group 2. At month 12, a hyperopic shift was detected in group 2, providing emmetropia with a SE value of -0.01 D. No significant hyperopic shift was observed in group 1. Regarding the flexible structure of the IOL and knotless Z-suture technique used, the most possible explanation for delayed hyperopic shift might be a slight posterior migration of hydrophilic acrylic lens.

By contrast, the two-point fixation technique may cause lens tilt, which may cause high-order aberrations that cannot be corrected with spectacles. Holladay *et al.*<sup>[35]</sup> reported that a lens tilt of >15° might cause such aberrations, and Tsai *et al.*<sup>[36]</sup> found that a tilt of just 5° can induce additional refractive error. Continuity of the pupil margin plays a crucial role in preventing IOL tilt. No iris capture of the IOL was detected postoperatively. However, post-traumatic mydriasis was noted in four patients. No serious complications were detected except for macular edema in two (6.7%) patients. In both groups, BCVA improvement was significant at month 12.

Comparing the two SFIOL techniques; foldable IOL has the advantage of a small corneal incision with a lower risk

of induced astigmatism. Moreover, the knotless nature of the Z-suture seems superior to the suture burial technique concerning reducing suture exposure risk in long-term follow-up. The potential limitations of our study were the retrospective design, a relatively short follow-up in group 2, and the limited number of patients in the groups. Another potential limitation was the lack of ultrasound biomicroscopy, which is considered the standard method for accessing the IOL position. However, to the best of our knowledge, this is the first study to compare the suture burial SFIOL technique with the knotless Z-suture method.

## Conclusion

In conclusion, both SFIOL techniques seem safe and effective in the management of dislocated IOLs or crystalline lenses. However, knotless Z-suture SFIOL implantation offers a lower risk of suture-related complications. In addition, scleral-fixated foldable IOL implantation with self-sealing CCI appears to be superior to scleral-fixated PMMA IOL implantation with a self-sealing sclerocorneal tunnel concerning surgically induced astigmatism.

## Informed consent

Informed consent was obtained from all individual participants included in the study.

## Ethical approval

All procedures performed in studies involving human participants were in accordance with the ethical standards of the institutional and/or national research committee and with the 1964 Helsinki Declaration and its later amendments or comparable ethical standards.

## Financial support and sponsorship

Nil.

## Conflicts of interest

All authors certify that they have no affiliations with any organization or entity with any financial interest (such as honoraria; educational grants; participation in speakers' bureaus; membership, employment, consultancies, stock ownership, or other equity interest; expert testimony or patent-licensing arrangements), or non-financial interest (such as personal or professional relationships, affiliations, knowledge or beliefs) in the subject matter or materials discussed in this manuscript.

## References

1. Agarwal A, Kumar DA, Nair V. Cataract surgery in the setting of trauma. *Curr Opin Ophthalmol* 2010;21:65-70.
2. Por YM, Lavin MJ. Techniques of intraocular lens suspension in the absence of capsular/zonular support. *Surv Ophthalmol* 2005;50:429-62.
3. Malbran ES, Malbran E Jr, Negri I. Lens guide suture for transport and fixation in secondary IOL implantation after intracapsular extraction. *Int Ophthalmol* 1986;9:151-60.
4. Lewis JS. Ab externo sulcus fixation. *Ophthalmic Surg* 1991;22:692-5.
5. Smiddy WE, Sawusch MR, O'Brien TP, Scott DR, Huang SS. Implantation of scleral-fixated posterior chamber intraocular lenses. *J Cataract Refract Surg* 1990;16:691-6.
6. Bucci FA Jr, Holland EJ, Lindstrom RL. Corneal autografts for

- external knots in transsclerally sutured posterior chamber lenses. *Am J Ophthalmol* 1991;112:353-4.
7. Bashshur Z, Ma'luf R, Najjar D, Nouredin B. Scleral fixation of posterior chamber intraocular lenses using fascia lata to cover the knots. *Ophthalmic Surg Lasers* 2002;33:445-9.
  8. Chakrabarti A, Gandhi RK, Chakrabarti M. Ab externo 4-point scleral fixation of posterior chamber intraocular lenses. *J Cataract Refract Surg* 1999;25:420-6.
  9. Baykara M. Suture burial technique in scleral fixation. *J Cataract Refract Surg* 2004;30:957-9.
  10. Szurman P, Petermeier K, Aisenbrey S, Spitzer MS, Jaissle GB. Z-suture: A new knotless technique for transscleral suture fixation of intraocular implants. *Br J Ophthalmol* 2010;94:167-9.
  11. Stem MS, Todorich B, Woodward MA, Hsu J, Wolfe JD. Scleral-fixed intraocular lenses: Past and present. *J Vitreoretin Dis* 2017;1:144-52.
  12. Eğrilmez S, Dalkılıç G, Yağcı A. Astigmatizma analizinde vektöryel analiz programı. *T Oft Gaz* 2003;33:404-16.
  13. Gauvin M, Wallerstein A. AstigMATIC: An automatic tool for standard astigmatism vector analysis. *BMC Ophthalmol* 2018;18:255.
  14. Chan TC, Lam JK, Jhanji V, Li EY. Comparison of outcomes of primary anterior chamber versus secondary scleral-fixed intraocular lens implantation in complicated cataract surgeries. *Am J Ophthalmol* 2015;159:221-6.e2.
  15. Hazar L, Kara N, Bozkurt E, Ozgurhan EB, Demirok A. Intraocular lens implantation procedures in aphakic eyes with insufficient capsular support associated with previous cataract surgery. *J Refract Surg* 2013;29:685-91.
  16. Kim KH, Kim WS. Comparison of clinical outcomes of iris fixation and scleral fixation as treatment for intraocular lens dislocation. *Am J Ophthalmol* 2015;160:463-9.e1.
  17. Kim M, Lee DH, Koh HJ, Lee SC, Kim SS. Surgical outcome of simultaneous intraocular lens rescue and sutureless intrascleral tunnel fixation of dislocated intraocular lenses. *Retina* 2015;35:1450-7.
  18. Lee VY, Yuen HK, Kwok AK. Comparison of outcomes of primary and secondary implantation of scleral fixed posterior chamber intraocular lens. *Br J Ophthalmol* 2003;87:1459-62.
  19. Yalniz-Akkaya Z, Burcu A, Uney GO, Abay I, Eksioğlu U, Acar MA, *et al.* Primary and secondary implantation of scleral-fixed posterior chamber intraocular lenses in adult patients. *Middle East Afr J Ophthalmol* 2014;21:44-9.
  20. Buckley EG. Safety of transscleral-sutured intraocular lenses in children. *J AAPOS* 2008;12:431-9.
  21. Fass ON, Herman WK. Four-point suture scleral fixation of a hydrophilic acrylic IOL in aphakic eyes with insufficient capsule support. *J Cataract Refract Surg* 2010;36:991-6.
  22. Heilskov T, Joondeph BC, Olsen KR, Blankenship GW. Late endophthalmitis after transscleral fixation of a posterior chamber intraocular lens. *Arch Ophthalmol* 1989;107:1427.
  23. Lewis JS. Sulcus fixation without flaps. *Ophthalmology* 1993;100:1346-50.
  24. Baykara M, Avci R. Prevention of suture knot exposure in posterior chamber intraocular lens implantation by 4-point scleral fixation technique. *Ophthalmic Surg Lasers Imaging* 2004;35:379-82.
  25. Hoffman RS, Fine IH, Packer M. Scleral fixation without conjunctival dissection. *J Cataract Refract Surg* 2006;32:1907-12.
  26. Solomon K, Gussler JR, Gussler C, Van Meter WS. Incidence and management of complications of transsclerally sutured posterior chamber lenses. *J Cataract Refract Surg* 1993;19:488-93.
  27. Baykara M, Timucin OB. Long-term results of a suture burial technique. *Eur J Ophthalmol* 2008;18:368-70.
  28. Dimopoulos S, Dimopoulos V, Blumenstock G, Trevino-Rodriguez H, Bartz-Schmidt KU, Spitzer MS, *et al.* Long-term outcome of scleral-fixed posterior chamber intraocular lens implantation with the knotless Z-suture technique. *J Cataract Refract Surg* 2018;44:182-5.
  29. Luk AS, Young AL, Cheng LL. Long-term outcome of scleral-fixed intraocular lens implantation. *Br J Ophthalmol* 2013;97:1308-11.
  30. Kandemir Beşek N, Alagoz N, Gumus G, Kepez Yildiz B, Kirgiz A, Yildirim Y, *et al.* Long-term results of aphakia management by scleral fixation intraocular lens placement with knotless transscleral Z-suture method. *Int Ophthalmol* 2020;40:1449-54.
  31. Mallik VK, Kumar S, Kamboj R, Jain C, Jain K, Kumar S. Comparison of astigmatism following manual small incision cataract surgery: Superior versus temporal approach. *Nepal J Ophthalmol* 2012;4:54-8.
  32. Jauhari N, Chopra D, Chaurasia RK, Agarwal A. Comparison of surgically induced astigmatism in various incisions in manual small incision cataract surgery. *Int J Ophthalmol* 2014;7:1001-4.
  33. Tetikoğlu M, Yeter C, Helvacioğlu F, Aktaş S, Sağdıç HM, Özcürü F. Effect of corneal incision enlargement on surgically induced astigmatism in biaxial microincision cataract surgery. *Turk J Ophthalmol* 2016;46:99-103.
  34. Abbey AM, Hussain RM, Shah AR, Faia LJ, Wolfe JD, Williams GA. Sutureless scleral fixation of intraocular lenses: Outcomes of two approaches. The 2014 Yasuo Tano Memorial Lecture. *Graefes Arch Clin Exp Ophthalmol* 2015;253:1-5.
  35. Holladay JT. Evaluating the intraocular lens optic. *Surv Ophthalmol* 1986;30:385-90.
  36. Tsai YY, Tseng SH. Transscleral fixation of a foldable intraocular lens after pars plana lensectomy in eyes with a subluxated lens. *J Cataract Refract Surg* 1999;25:722-4.