

Choroidal thickness changes in non-treated acute and ranibizumab-treated chronic central serous chorioretinopathy

Erhan Yumusak, MD^a, Nesrin Buyuktortop Gokcinar, MD^{a,*}, Kemal Ornek, MD^b

Abstract

To evaluate the changes in subfoveal retinal, and choroidal thicknesses (CT) in the non-treated acute and the ranibizumab-treated chronic central serous chorioretinopathy (CSCR) patients.

This retrospective study included 32 eyes of 32 consecutive patients with CSCR. There were 12 patients who presented with a spontaneous resolution of CSCR (Group 1) and 20 patients who were treated with ranibizumab for persistent subretinal fluid (SRF) (Group 2). Optical coherence tomography (OCT) imaging of subfoveal retinal thickness and enhanced depth imaging OCT of CT at subfoveal; at nasal and temporal 500 μm (T500); at nasal and temporal 1500 μm (T1500) were analyzed. The Student *t* test and multivariate analysis were used to compare variables within and between groups, respectively and correlations were analyzed using Pearson correlation coefficient. A *P* value of *P* < .05 was accepted as significant.

The mean patient age was 38.94 ± 8.41 years (range, 20–53 years). Female/male ratio was 4/28. The mean duration of follow-up was 21.6 ± 8.2 months in the chronic CSCR group. Visual acuity improved and central foveal thickness (FT) decreased significantly in both groups. CT decreased significantly only at nasal 1500 μm (N1500) in the acute group and at all measured points in the chronic group compared with baseline, except at T500 (*P* = .07). No significant difference in central FT was detected between the 2 groups. Compared with the acute group, baseline subfoveal CT was significantly higher in chronic patients. There was a significant difference between the groups in baseline and final CT at T500. No significant difference was found at T1500. At nasal 500 μm and N1500, the difference between the groups was significant only for final CT values.

Chronic CSCR was associated with higher baseline CT values in the subfoveal region and at T500. CT significantly decreased at most of the measured points in ranibizumab-treated chronic CSCR patients, whereas it significantly decreased only at 1 point in spontaneously resolved acute CSCR patients.

Abbreviations: BCVA = best-corrected visual acuity, CSCR = central serous chorioretinopathy, CT = choroidal thickness, EDI-OCT = enhanced depth imaging optical coherence tomography, FT = foveal thickness, N1500 = nasal 1500 μm , PDS = pachychoroid disease spectrum, SFCT = subfoveal choroidal thickness, SRF = subretinal fluid, T1500 = temporal 1500 μm , T500 = temporal 500 μm .

Keywords: central serous chorioretinopathy, choroidal thickness, optical coherence tomography, ranibizumab, retinal thickness

1. Introduction

Central serous chorioretinopathy (CSCR) is characterized by idiopathic serous retinal detachment in the posterior pole associated with 1 or more leaks from the retinal pigment epithelium.^[1] Although there have been many theories concerning the pathogenesis of CSCR, Gass^[2] proposed that CSCR was the consequence of choroidal vascular hyperpermeability. This

hypothesis was confirmed by recent studies, which found evidence of hyperpermeability from the choriocapillaris on Indocyanine green (ICG) angiography.^[1,3–5] If there is sufficient hydrostatic pressure from the choroidal vasculature causing leakage from RPE and serous retinal detachment, 1 may expect that the choroid would be thickened as well.^[6,7]

Choroidal thickening can result from focal or diffuse dilatation of large choroidal vessels.^[8] However, there are reports of dilated choroidal vessels with normal subfoveal choroidal thickness (SFCT) in resolved CSCR.^[9] CSCR can occur in an acute or chronic form. Although acute episodes resolve spontaneously, 20% to 50% of the affected eyes may later present with either 1 or more recurrences.^[10,11] Yet, little is known about the underlying mechanisms triggering the recurrences and leading to chronic forms of the disease. Many authors accept that the disease is chronic if symptoms last longer than 3 months, whereas this period is more than 6 months for others.^[12]

In this study, we compared changes in subfoveal retinal, and choroidal thickness (CT), using Enhanced depth imaging optical coherence tomography (EDI-OCT) between non-treated acute and ranibizumab-treated chronic CSCR patients. Our aim was to reveal the anatomical and functional differences in the CT at the beginning and after the resolution of subretinal fluid (SRF) in both of the acute and chronic forms of the disease.

Editor: Suleyman Demircan.

The authors declare no conflict of interest.

^a Kırıkkale University, School of Medicine, Department of Ophthalmology, Kırıkkale, ^b Kudret Eye Hospital, Ankara, Turkey.

* Correspondence: Nesrin Buyuktortop Gokcinar, Kırıkkale University Hospital, Department of Ophthalmology, Yahşihan, Kırıkkale, Turkey (e-mail: tortopn@kku.edu.tr).

Copyright © 2018 the Author(s). Published by Wolters Kluwer Health, Inc. This is an open access article distributed under the terms of the Creative Commons Attribution-Non Commercial-No Derivatives License 4.0 (CCBY-NC-ND), where it is permissible to download and share the work provided it is properly cited. The work cannot be changed in any way or used commercially without permission from the journal.

Medicine (2018) 97:43(e12885)

Received: 9 April 2018 / Accepted: 26 September 2018

<http://dx.doi.org/10.1097/MD.0000000000012885>

Table 1**The comparison of the baseline and final clinical characteristics of the acute CSCR group.**

n=12	Baseline	Final	P value
FT	411.5±120.5	278.7±93.6	.02*
VA	0.7±0.26	0.83±0.27	.04*
SFCT	211.9±76.8	181.1±35.1	.16
T500	212.6±65.7	194.1±21.8	.39
T1500	222.9±51.9	202.4±31.1	.19
N500	209.1±78.2	170.9±43.1	.11
N1500	212.1±67.9	168.1±32.3	.01*

CSCR = central serous chorioretinopathy, FT = foveal thickness, N1500 = choroidal thickness at nasal 1500 μm , N500 = choroidal thickness at nasal 500 μm , SFCT = subfoveal choroidal thickness, T1500 = choroidal thickness at temporal 1500 μm , T500 = choroidal thickness at temporal 500 μm , VA = best corrected visual acuity.

* The *p* value was significant.

2. Methods

In this study, the medical records of patients with acute or chronic CSCR from March 2011 to December 2015 were reviewed. A total of 32 eyes of 32 consecutive patients with CSCR were included. There were 12 patients who presented with a spontaneous resolution of CSCR (Group-1) and 20 patients who were treated with ranibizumab for persistent SRF of >3 months' duration (Group-2). The research was approved by the Institutional Review Board. All participants gave written informed consent before their participation. The study was conducted in adherence to the tenets of the Declaration of Helsinki.

Patients with a history of any retino-choroidal diseases and vitreoretinal interventions, such as laser photocoagulation, intravitreal injection, or vitreoretinal surgery, previous systemic or chronic disease or conditions (such as diabetes mellitus or systemic hypertension) in 1 or both eyes, an axial length $>24 \pm 1.0$ mm, a refractive measurement exceeding 2.0 diopters, and medications altering the choroidal vasculature, including corticosteroid and sildenafil, were excluded.

At the initial visit, all patients were examined using slit lamp biomicroscopy, fluorescein angiography, and OCT. Best-corrected visual acuity (BCVA) measurement with Snellen chart and EDI-OCT (OCT Advance Nidek RS-3000; Nidek Co. Ltd., Gamagori, Japan) were performed at each visit. BCVA was converted into log MAR (logarithm of minimal angle of resolution) scale for the analysis.

In the first 2 months, patients were followed up monthly for 2 months. Then, patients with an evident decrease in SRF were followed up monthly until complete recovery. In patients with persistent or increasing SRF after 3 months of observation, ranibizumab was administered to facilitate SRF resolution.

Intravitreal ranibizumab injection was performed in an operating room under sterile conditions. CT was measured

using EDI-OCT (OCT Advance Nidek RS-3000; Nidek Co. Ltd). All patients underwent EDI-OCT scanning. A single physician (EY) manually drew choroidal and scleral boundaries with the assistance of software program. These boundaries limited the Bruch membrane between the subfoveal points (SFCT) to 500 and 1500 μm in the nasal (N500, N1500) and 500 and 1500 μm in the temporal regions (T500, T1500) for measurement. Follow-up examinations were conducted on day 1, week 1, and monthly thereafter. Data related to baseline (SFCT₀, N500₀, N1500₀, T500₀, T1500₀) and final visits (SFCT₁, N500₁, N1500₁, T500₁, T1500₁), besides foveal retinal thickness (FT₀ and FT₁), were recorded in each group.

SPSS statistical software (SPSS for Windows, version 21.0; SPSS, Inc., Chicago, IL) was used for the statistical analysis. The results of the descriptive analysis are presented as mean, and standard deviations. The Student's *t*-test and multivariate analysis were used to compare variables within and between groups, respectively and correlations were performed using Pearson's correlation coefficient. A *P* value below .05 was taken to indicate a statistically significant result.

3. Results

The study included 32 eyes of 32 patients. There were 4 female and 28 male patients. The mean patient age was 38.94 ± 8.41 years. Twelve patients (12 eyes) had acute CSCR, with a mean age of 39.90 ± 9.4 years (range, 20–53) and 20 patients (20 eyes) had chronic CSCR with a mean age of 37.33 ± 9.7 years (range, 29–46). The groups did not differ significantly with respect to age (*P* = .40).

The mean duration of follow-up was 21.6 ± 8.2 months in the chronic CSCR group. The number of ranibizumab injections in the chronic group was 3.2 ± 1.8 (range, 1–6). The mean baseline decimal visual acuity was 0.70 (0.17 logMAR) for eyes with acute CSCR and 0.48 (0.31 logMAR) for those with chronic CSCR. Descriptive clinical values of the chronic CSCR patients are shown in Table 1.

In Group-1, visual acuity improved and central foveal thickness (FT) decreased significantly after spontaneous resolution (Table 2). Choroidal thinning was observed at all measured points, but a significant difference was found only at N1500 (Table 2 and Fig. 1).

In Group-2, there was also a significant increase in visual acuity and a significant decrease in central FT (Table 3). CT was decreased at all measured areas compared to baseline values, following treatment. The decrease in CT was statistically significant at all points except T500 (Table 3 and Fig. 2).

When we compared the baseline and the final values of the 2 groups, no significant difference was found in central FT between the groups, either at baseline or final examination (*P* = .13 and *P* = .50, respectively). The mean baseline BCVA was significantly better in Group-1 (*P* = .02), whereas there was no significant

Table 2**Descriptive clinical values of the chronic CSCR patients.**

n=20	Age	Duration of CSCR, weeks	Follow-up period, month	Number of attacks	Number of injection
Mean	39.90	37	21.6	2.90	3.30
Median	43.00	24	21.0	2.50	3.00
Std. Deviation	9.46	34	8.28	1.80	1.65
Minimum	20	12	12	1	1
Maximum	53	132	42	6	6

CSCR = central serous chorioretinopathy.

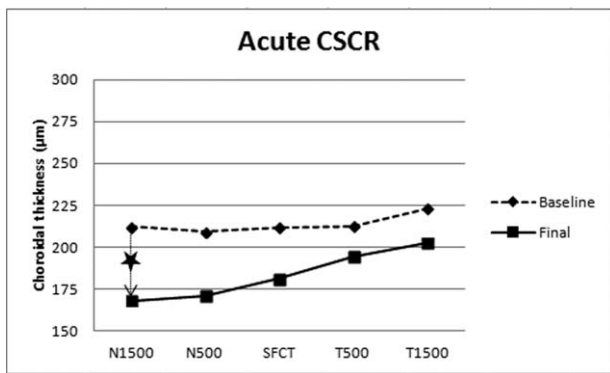


Figure 1. The baseline and final choroidal thickness values at nasal 1500 µm, nasal 500 µm, subfoveal, temporal 500 µm, and temporal 1500 µm in Group-1 (Acute central serous chorioretinopathy group). Significant changes were marked with a star.

Table 3
The comparison of the baseline and final clinical characteristics of the ranibizumab-treated chronic CSCR group.

n=20	Baseline	Final	P value
FT	361.9 ± 63.2	263.1 ± 38.4	<.01*
VA	0.48 ± 0.26	0.83 ± 0.27	<.01*
SFCT	281.2 ± 77.1	221.9 ± 66.9	<.01*
T500	291.1 ± 68.3	246.2 ± 85.2	.07
T1500	251.1 ± 64.1	211.9 ± 49.9	.03*
N500	252.1 ± 84.2	203.1 ± 29.3	.01*
N1500	260.6 ± 71.5	222.9 ± 47.3	.02*

CSCR = central serous chorioretinopathy, FT = foveal thickness, N1500 = choroidal thickness at nasal 1500 µm, N500 = choroidal thickness at nasal 500 µm, SFCT = subfoveal choroidal thickness, T1500 = choroidal thickness at temporal 1500 µm, T500 = choroidal thickness at temporal 500 µm, VA = best corrected visual acuity. The data are given as mean ± standard deviation.
*The P value was significant.

difference between the groups in the final BCVA ($P=.96$). Compared with Group-1, baseline SFCT was significantly higher in Group-2 ($P=.01$). After the ranibizumab treatment, baseline SFCT was decreased and no significant difference was detected in final SFCT values ($P=-.06$). There was a significant difference in baseline and final CT at T500 between the groups ($P<.05$). At

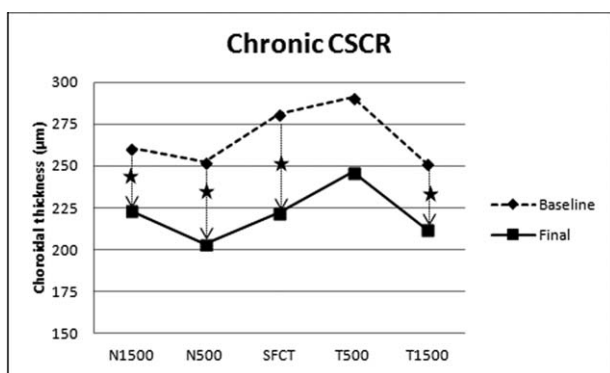


Figure 2. The baseline and final choroidal thickness values at nasal 1500 µm, nasal 500 µm, subfoveal, temporal 500 µm, and temporal 1500 µm in Group-2 (Chronic central serous chorioretinopathy). Significant changes were marked with a star.

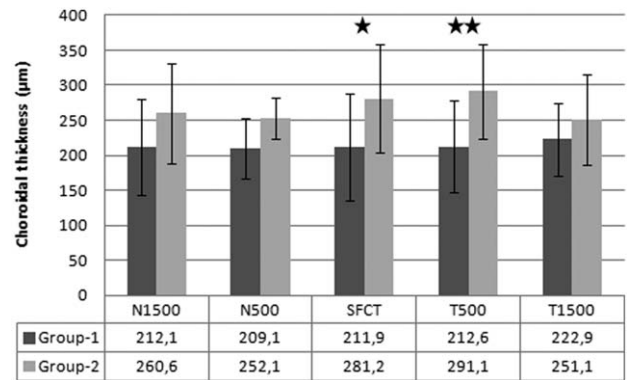


Figure 3. The comparison of the baseline choroidal thickness between the groups at different measurement points. Group-1: Spontaneously resolved acute central serous chorioretinopathy group, Group-2: Ranibizumab-treated chronic central serous chorioretinopathy group. Significant changes were marked with a star; 1 star denotes $P<.05$; 2 stars denote $P<.01$.

N500 and N1500, the difference was significant only for the final CT values ($P<.05$). No significant differences were found at T1500 either at baseline or final (all $P>.05$) (Figs. 3 and 4).

We did not observe any serious injection/drug-related complications in the ranibizumab-treated chronic CSCR group during the follow-up period.

4. Discussion

The pathogenesis of CSCR is related to abnormal choroidal circulation. Gass suggested that increased permeability of the choriocapillaris may result in subretinal serous detachment.^[2] The condition is usually self-limiting with spontaneous resolution within 3 to 4 months and overall good visual outcome.^[1,13,14] However, recurrences could be seen in up to 50% of patients within the first year.^[15,23] Several treatments, including laser photocoagulation, photodynamic therapy (PDT), intravitreal anti-vascular endothelial growth factor (VEGF) drugs, systemic carbonic anhydrase inhibitors (CAIs), aspirin, and so on have been used to treat chronic CSCR.^[1]

In our study, we evaluated non-treated acute and ranibizumab-treated chronic CSCR patients and compared the results of both groups. Intravitreal ranibizumab was found to be effective in

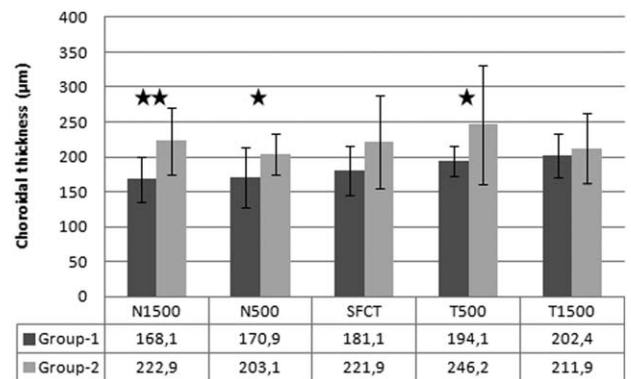


Figure 4. The comparison of the final choroidal thickness between the groups at different measurement points. Group-1: Spontaneously resolved acute central serous chorioretinopathy group, Group-2: Ranibizumab-treated chronic central serous chorioretinopathy group. Significant changes were marked with a star; 1 star denotes $P<.05$; 2 stars denote $P<.01$.

chronic cases and showed similar results to those in patients with spontaneously resolved acute CSCR. Finally, the foveal retinal thickness significantly decreased, and BCVA significantly increased in both of the groups.

CSCR is located in the pachychoroid disease spectrum (PDS) including pachychoroid pigment epitheliopathy, focal choroidal excavation, pachychoroid neovascularopathy, and polypoidal choroidal vasculopathy. PDS is characterized by focal or generalized thickening in different parts of the choroid (in Haller layer).^[16] Recently, a new entity named “Peripapillary pachychoroid syndrome,” was described as a distinct variant of PDS which is characterized by peripapillary choroidal thickening with nasal macular intraretinal and/or SRF.^[16] On the other hand, CSCR itself has different presentations including acute, chronic, recurrent, and rarely bullous phenotypes.^[17,18]

On the basis of the literature about the variations in CSCR, we measured the CT at 5 separate points on the macula (SFCT, T500, T1500, N500, and N1500) in order to evaluate the relationship between the anatomical localization of the “pachy = thick choroid” and the phenotype of CSCR. The baseline and final CTs were compared between the spontaneously resolved acute CSCR group and the ranibizumab-treated chronic CSCR group. The baseline and final CT values were also compared within each group.

In the acute CSCR group, CT decreased at all measured points, but the difference was significant only at N1500. In a retrospective study by Unlu et al including 37 patients with acute CSCR, SFCT changes were assessed after the bevacizumab therapy. SFCT decreased in both of the treatment and the control groups with remission of the disease. However, the decrease was significantly greater in the control group. In acute CSCR, intravitreal bevacizumab injection was not superior to observation.^[19] In our study, acute CSCR cases were observed without any treatment. Although not statistically significant, a decrease in SFCT was observed, similar to the literature by Unlu et al Besides, in our study, changes in CT at neighboring points were analyzed and a significant reduction was found at N1500.

In another study, evaluating the efficacy of oral spironolactone in patients with acute CSCR, central macular thickness and SRF significantly decreased in both of the treatment and the control groups. SRF resorption was reported to be faster in the spironolactone group. There was no significant difference between the 2 groups in SFCT at baseline or final visit. During the follow-up, SFCT decreased in both of the groups, but the decrease was not significant in the control group as it was in the non-treated acute CSCR group in our study.^[20]

In a recent study by Kim et al, 76 CSCR patients who had decreased vision lasting for more than 3 months were evaluated.^[21] Forty-two received bevacizumab treatment, and 34 had photodynamic therapy. SFCT was measured in the study groups and was compared with baseline values. The authors concluded more than 1 interesting data:

- (1) SFCT decreased after complete resolution,
- (2) decrease in CT was not significant between the groups,
- (3) recurrence was more in bevacizumab group, and
- (4) there was a negative correlation between the amount of reduction in CT and recurrences.

Both treatments were found to be effective in patients with chronic CSCR.^[21] In our study, we found a significant decrease in SFCT after ranibizumab treatment for chronic CSCR, similar to the results of Kim et al. Moreover, in patients with chronic CSCR, CT decreased significantly after ranibizumab treatment at all

selected points, except at T500, in our study. Similar to our results with ranibizumab, a significant reduction was reported in SFCT of patients with chronic CSCR after photodynamic therapy.^[22]

When we compared the baseline data between the 2 groups, CT at T500 was significantly higher in the chronic group. Moreover, the baseline subfoveal choroid was significantly thicker in chronic CSCR (281.2 μm vs 211.9 μm , $P = .01$), in accordance with the Kim et al.^[21] The difference in SFCT decreased after the resolution of SRF (221.9 μm vs 181.1 μm , $P = .06$). But, although not statistically significant, the final SFCT was still higher in the chronic CSCR group than the acute group. The final CT was also significantly thicker at T500, N500, and N1500 in the chronic CSCR group than the acute group. We may suggest that higher baseline SFCT levels may indicate a worse prognosis about chronicity and recurrences. Supporting our findings SFCT was reported as the most important risk factor for chronic CSCR.^[23] In a retrospective study by Ambiya et al, 38 eyes of 33 patients with CSCR were followed-up for 12 months.^[24] It was reported that the eyes with SFCT of more than 356 μm were more likely to be chronic and require treatment rather than observation. SFCT was also suggested to be a predictive value for the treatment of chronic CSCR.^[24] Similarly, Hamzah et al studied both chronic and acute CSCR cases and reported that baseline SFCT were thicker in the patients with chronic CSCR.^[7]

Additionally, we may say that although the SRF resolves and CT significantly decreases with the ranibizumab treatment, chronic CSCR patients may have a higher CT level than the acute group, significantly at the nasal macula, and at T500. Chronic CSCR was suggested to be associated with a more extensive RPE damage than the acute CSCR causing choroidal thickening through the accumulation of fluid. This may be 1 of the reasons for a thicker choroid in chronic CSCR.^[7]

In the ranibizumab-treated chronic group, reduction in the CT was more prominent than in the acute group. Although it is not possible to explain the precise reason in our study design, we may suggest that ranibizumab might have been beneficial for the recovery of the thickened choroid, when we consider that baseline CT values were significantly higher in the chronic group than in the acute group, especially in the subfoveal region. We think that further prospective studies with larger sample size are required to draw a definitive conclusion.

The limitations of our study were its retrospective nature, small sample size and manual measurement of the CTs. On the other hand, we could not include ICG angiography in our study. ICG angiography demonstrated multiple areas of choroidal vascular hyperpermeability, vascular congestion, and venous dilation in CSCR patients. These findings suggested a generalized choroidal vascular disturbance in the pathophysiology.^[6,25,26] Along with the abnormal findings of ICG angiography, recently developed enhanced depth-OCT showed that the SFCT of eyes with CSCR was higher than that of age-matched normal subjects.^[6] We believe that to measure the CT regarding the ICG angiography findings may provide more valuable results, in further studies.

5. Conclusions

The findings of this present study revealed that the foveal retinal thickness significantly decreased, and BCVA significantly increased in both of the acute CSCR and ranibizumab-treated chronic CSCR groups. Chronic CSCR was associated with higher baseline CT values in the subfoveal region and at T500. Although

the CT significantly decreased with the ranibizumab treatment, the final CT may be still higher than the acute group at some points. The baseline subfoveal and temporal CT may have a predictive value for chronicity.

We hope that future studies will help us to understand the role of the choroid in the pathogenesis and follow-up of patients with acute and chronic CSCR and take these data a step further.

Author contributions

Conceptualization: Erhan Yumusak.

Data curation: Erhan Yumusak, Kemal Ornek.

Formal analysis: Erhan Yumusak, Nesrin Buyuktortop Gokcinar.

Investigation: Erhan Yumusak, Nesrin Buyuktortop Gokcinar, Kemal Ornek.

Methodology: Erhan Yumusak, Nesrin Buyuktortop Gokcinar, Kemal Ornek.

Project administration: Erhan Yumusak.

Resources: Erhan Yumusak.

Software: Nesrin Buyuktortop Gokcinar.

Supervision: Kemal Ornek.

Validation: Nesrin Buyuktortop Gokcinar.

Writing – original draft: Erhan Yumusak.

Writing – review & editing: Nesrin Buyuktortop Gokcinar.

Nesrin Buyuktortop Gokcinar ORCID: 0000-0001-7795-5188.

References

- [1] Klais CM, Ober MD, Ciardella AP, Ryan SJ, Hinton DR, Schachat AP, Wilkinson P, et al. Central serous chorioretinopathy. Retina 4th ed. Elsevier Mosby, Philadelphia:2006;1135–61.
- [2] Gass JD. Pathogenesis of disciform detachment of the neuroepithelium. II. Idiopathic central serous choroidopathy. Am J Ophthalmol 1967;63:587–615.
- [3] Scheider A, Nasemann JE, Lund OE. Fluorescein and indocyanine green angiographies of central serous choroidopathy by scanning laser ophthalmoscopy. Am J Ophthalmol 1993;115:50–6.
- [4] Iida T, Kishi S, Hagimura N, et al. Persistent and bilateral choroidal vascular abnormalities in central serous chorioretinopathy. Retina 1999;19:508–12.
- [5] Spaide RF, Goldbaum M, Wong DW, et al. Serous detachment of the retina. Retina 2003;23:820–46.
- [6] Imamura Y, Fujiwara F, Margolis R, et al. Enhanced depth imaging optical coherence tomography of the choroid in central serous chorioretinopathy. Retina 2009;29:1469–73.
- [7] Hamzah F, Shinjima A, Mori R, et al. Choroidal thickness measurement by enhanced depth imaging and swept-source optical coherence tomography in central serous chorioretinopathy. BMC Ophthalmol 2014;14:145.
- [8] Yang L, Jonas JB, Wei W. Choroidal vessel diameter in central serous chorioretinopathy. Acta Ophthalmol 2013;91:e358–62.
- [9] Daruich A, Matet A, Dirani A, et al. Central serous chorioretinopathy: recent findings and new physiopathology hypothesis. Prog Retin Eye Res 2015;48:82–118.
- [10] Ozkaya A, Alkin Z, Ozveren M, et al. The time of resolution and the rate of recurrence in acute central serous chorioretinopathy following spontaneous resolution and low-fluence photodynamic therapy: a case-control study. Eye (Lond) 2016;30:1005–10.
- [11] Kitzmann AS, Pulido JS, Diehl NN, et al. The incidence of central serous chorioretinopathy in Olmsted County, Minnesota, 1980–2002. Ophthalmology 2008;115:169–73.
- [12] Lim SH, Chang W, Sagong M. Efficacy of half-fluence photodynamic therapy depending on the degree of choroidal hyperpermeability in chronic central serous chorioretinopathy. Eye (Lond) 2013;27:353–62.
- [13] Ross A, Ross AH, Mohamed Q. Review and update of central serous chorioretinopathy. Curr Opin Ophthalmol 2011;22:166–73.
- [14] Mudvari SS, Goff MJ, Fu AD, et al. The natural history of pigment epithelial detachment associated with central serous chorioretinopathy. Retina 2007;27:1168–73.
- [15] Aggio FB, Roisman L, Melo GB, et al. Clinical factors related to visual outcome in central serous chorioretinopathy. Retina 2010;30:1128–34.
- [16] Gallego-Pinazo R, Dolz-Marco R, Gómez-Ulla F, et al. Pachychoroid diseases of the macula. Med Hypothesis Discov Innov Ophthalmol 2014;3:111–5.
- [17] Mazzuca DE, Benson WE. Central serous retinopathy: variants. Surv Ophthalmol 1986;31:170–4.
- [18] Balaratnasingam C, Freund KB, Tan AM, et al. Bullous variant of central serous chorioretinopathy: expansion of phenotypic features using multimethod imaging. Ophthalmology 2016;123:1541–52.
- [19] Ünlü C, Erdogan G, Gezginaslan TA, et al. Subfoveal choroidal thickness changes after intravitreal bevacizumab therapy for central serous chorioretinopathy. Arq Bras Oftalmol 2016;79:308–11.
- [20] Sun X, Shuai Y, Fang W, et al. Spironolactone versus observation in the treatment of acute central serous chorioretinopathy. Br J Ophthalmol 2018;102:1060–5.
- [21] Kim DY, Joe SG, Yang HS, et al. Subfoveal choroidal thickness changes in treated idiopathic central serous chorioretinopathy and their association with recurrence. Retina 2015;35:1867–74.
- [22] Iacono P, Tedeschi M, Boccassini B, et al. Chronic central serous chorioretinopathy: early and late morphological and functional changes after verteporfin photodynamic therapy. Retina 2018;[Epub ahead of print].
- [23] Matet A, Daruich A, Zola M, et al. Risk factors for recurrences of central serous chorioretinopathy. Retina 2018;38:1403–14.
- [24] Ambiya V, Yogi R, Li A, et al. Subfoveal choroidal thickness as a predictor of central serous chorioretinopathy. Eye (Lond) 2016;30:1623–9.
- [25] Spaide RF, Hall L, Haas A, et al. Indocyanine green videoangiography of older patients with central serous chorioretinopathy. Retina 1996;16:203–13.
- [26] Hayashi K, Hasegawa Y, Tokoro T. Indocyanine green angiography of central serous chorioretinopathy. Int Ophthalmol 1986;9:37–41.