

# Traditional transcutaneous approaches in head and neck surgery

## Abstract

The treatment of laryngeal and hypopharyngeal malignancies remains a challenging task for the head and neck surgeon as the chosen treatment modality often has to bridge the gap between oncologically sound radicality and preservation of function. Due to the increase in transoral laser surgery in early tumor stages and chemoradiation in advanced stages, the usage of traditional transcutaneous approaches has decreased over the recent past. In addition, the need for a function-sparing surgical approach as well as highest possible quality of life has become evident. In view of these facts, rationale and importance of traditional transcutaneous approaches to the treatment of laryngeal and hypopharyngeal malignancies are discussed in a contemporary background. The transcutaneous open partial laryngectomies remain a valuable tool in the surgeon's armamentarium for the treatment of early and advanced laryngeal carcinomas, especially in cases of impossible laryngeal overview using the rigid laryngoscope. Open partial laryngectomies offer superior overview and oncologic safety at the anterior commissure, especially in recurrences. In select advanced cases and salvage settings, the supracricoid laryngectomy offers a valuable tool for function-preserving but oncologically safe surgical therapy at the cost of high postoperative morbidity and a very demanding rehabilitation of swallowing. In hypopharyngeal malignancies, the increasing use of transoral laser surgery has led to a decline in transcutaneous resections via partial pharyngectomy with partial laryngectomy in early tumor stages. In advanced stages of tumors of the piriform sinus and the postcricoid area with involvement of the larynx, total laryngectomy with partial pharyngectomy is an oncologically safe approach. The radical surgical approach using circumferent laryngopharyngectomy with/without esophagectomy is indicated in salvage cases with advanced recurrences or as a primary surgical approach in patients where chemoradiation does not offer sufficient oncologic control or preservation of function.

In cases with impending reconstruction, fasciocutaneous free flaps (anterolateral thigh flap, radial forearm flap) seem to offer superior results to enteric flaps in cases where the cervical esophagus is not involved leading to better voice rehabilitation with fewer complications and postoperative morbidity. In salvage situations, the Gastrointestinal Free Flap has proven to be a valuable tool.

In conclusion, the choice of a surgical treatment modality is influenced by the patient's anatomy, tumor size and location as well as the surgeon's personal expertise.

## 1 Introduction

Over the recent years, the specialty of Head and Neck Surgery lived through significant changes concerning the choice of treatment modalities for head and neck malignancies, especially in the treatment of laryngeal and hypopharyngeal carcinomas. Multiple factors were responsible.

On the one hand, especially Europe faced a drastic incline in transoral laser surgery. Studies could prove that this approach produced excellent oncologic and functional

results provided that indications were carefully chosen and good surgical expertise was available. The results were comparable to classic transcervical surgery or radiotherapy but were afflicted with significantly lower perioperative morbidity [1]. Especially in early carcinomas (T1/T2), transoral laser surgery has replaced open approaches to larynx and pharynx. As a result, open transcervical approaches are nowadays rarely performed even in centers specializing in Head and Neck surgery. On the other hand, the treatment modalities of advanced tumor stages have changed over time. Two clinical studies

Ulrich R. Goessler<sup>1</sup>

1 Universitaets-HNO-Klinik,  
Universitaetsmedizin  
Mannheim, Germany

in particular have led to significant changes: First, the study of the Veterans Affairs Study Group [2] revealed that in certain patients survival rates after induction chemotherapy and radiation are comparable to the established approaches of surgical therapy using laryngectomy and postoperative radiotherapy. Furthermore, the study of the Radiation Therapy Oncology Group (RTOG) 91-11 established that in advanced laryngeal carcinomas, chemoradiation offered superior results to radiotherapy alone [3]. This resulted in a change of paradigms in the treatment of advanced laryngeal carcinomas toward laryngeal preservation and chemoradiation.

However, over the years the complications due to late toxicity of chemoradiation and the established downsides of salvage surgery keep the discussion of a primarily surgical approach in the treatment of advanced head and neck carcinomas alive.

In view of these facts, this paper shall review remaining indications of open organ-preserving approaches to larynx and pharynx.

## 2 Larynx

About 25% of head and neck malignancies are carcinomas of the larynx [4], 97.1% being squamous cell carcinomas. The rise in mass-produced cigarettes led to a rise in the incidence of laryngeal carcinomas and as a result the need for effective treatment modalities arose. The first total laryngectomy was performed by Billroth 1873 and this technique rapidly became a standard treatment modality in the first half of the twentieth century [4]. Nowadays, total laryngectomy remains the traditional gold standard in surgical therapy of advanced laryngeal carcinomas by which all other treatment modalities are measured. However, the loss of the larynx has significant impact on the patient's quality of life. One study revealed that the loss of the larynx leads to such a subjective loss in quality of life that 20% of healthy individuals would accept a shortening of survival time just to keep their larynx [5]. As a result, a variety of organ-sparing surgical procedures has been developed – open and endoscopic – to effectively treat laryngeal malignancies.

The question whether traditional transcervical approaches still offer valuable tools in modern head and neck oncology laid the ground for this paper, especially in face of the rise in transoral laser surgery.

An extensive review of the literature was performed with special regard to oncologic results, quality of life and remaining function of the larynx in a primary treatment setting. Traditional transcervical approaches were emphasized to analyse their indications and relevance in modern head and neck oncology.

The basis for effective treatment of laryngeal and hypopharyngeal malignancies by the head and neck surgeon is a detailed understanding of relevant anatomy and potential routes for tumor spread. The cartilagenous framework and the fibroelastic ligaments and muscles form the borders of distinct threedimensional spaces and

either assist or inhibit tumor spread in different directions. The understanding of these structures is key to understanding the inner structure of the larynx and the subsequent correct choice of treatment: The conus elasticus and the membrana quadrangularis span the height of the larynx and inhibit tumor spread. In the supraglottis, the preepiglottic space of Boyer is a key structure in tumor spread [6], the borders are the hyoepiglottic ligament superiorly, the thyrohyoid membrane and thyroid cartilage anteriorly, the epiglottis and the thyroepiglottic ligament posteriorly. The preepiglottic space is filled with fat and abundant lymphatics and possesses bilateral lymphatic drainage.

On the glottic level, the vocal ligaments meet at the anterior commissure and Broyle's ligament [7]. The latter inserts into the thyroid cartilage and this insertion is devoid of perichondrium. This tendinous insertion at first provides a barrier to tumor invasion anteriorly [8], but if the tendon is invaded by tumor, it provides a route for tumor extension anteriorly [8]. Below the anterior commissure, Guerrier's "plane zero" is devoid of perichondrium and allows direct tumor infiltration of the cartilage [9]. Hence, the anterior commissure is a key structure for tumor spread, it enables tumor spread to different spaces: preepiglottic, paraglottic and subglottic spaces or externally via the vascularized ossification centers of the thyroid cartilage. The paraglottic space as described by Berman is bordered by the thyroid cartilage, the membrana quadrangularis, the conus elasticus and the ventricle [10]. This threedimensional space is continuous with the preepiglottic space cranially and provides a route for tumor spread.

The cricoarytenoid unit is another key structure of laryngeal function and treatment and consists of the cricoid cartilage, the arytenoids, associated muscles and the superior laryngeal and the recurrent nerves. The preservation of all these structures is one basic principle in preserving the functionality of the remaining larynx.

Although the knowledge on routes of tumor spread and the understanding of pathogenesis and treatment in head and neck cancer has improved radically over the past 50 years, the 5-year-survival rate remained largely unchanged over the past 25 years: 1975 the 5-year-survival rate was 66%, 1986 66% and 2002 65% [5]. In addition, there was reported a decline in survival rates using the state of the art treatment modalities in the United States, which coined a new discussion about the choice of the correct treatment modality [11].

The treatment of laryngeal and carcinomas may be performed using either one of the following modalities: transoral endoscopic laser resection, transcervical open partial laryngectomies, total laryngectomy, primary radiation therapy or primary combined chemoradiation. Every treatment modality has an impact on phonation, swallowing and breathing by influencing the anatomic structure of the larynx and thus imposing consequences on the patient's quality of life, social interactions, socioeconomic status and psychologic makeup. Distinct factors may influence the choice of the optimal therapeutic concept,

**Table 1: Influencing factors in choice of treatment modality (modified according to [98])**

<b>Tumor factors</b>	Location Volume Extension Regional metastases Distant metastases
<b>Patient factors</b>	Pulmonal reserve Medical comorbidities Alcohol dependence Synchronous tumors Occupational voice usage
<b>Other factors</b>	Social support Distance from hospital Availability of facilities for treatment (surgery, radiation, speech therapy)

these may be grouped into patient factors, tumor factors and other factors (Table 1). Detailed analysis of these factors should guide the physician to a treatment modality best suited for the patient.

This paper will review the principles and treatment results for transcervical approaches to the treatment of laryngeal and hypopharyngeal malignancies. The results will be described for the distinct surgical techniques as well as subdivided for “early” and “advanced” carcinomas. There are no generally accepted precise definitions for the terms “early” and “advanced”, so the definitions commonly used in the literature were used: “Early” carcinoma was referred to carcinomas in the T-stages T1/T2 without metastases. “Advanced” carcinoma was applied to carcinomas in the T-stages T3/T4 without metastases. Generally, for laryngeal carcinomas, emphasis was put on carcinomas amenable to open partial resection (T1/T2), for hypopharyngeal carcinomas, the discussion was structured to anatomic subdivisions and as early carcinomas are rather rare, the emphasis naturally was put on the treatment of advanced carcinomas.

The evidence-based discussion of transcervical surgery is difficult as prospective, randomized studies are non-existent and the comparison of the different treatment modalities with differing patient populations offers only limited information.

## 2.1 Treatment strategies

In 1972, Strong and Jako established transoral laser surgery as a treatment option for small glottic carcinomas [12]. Since then, transoral laser surgery quickly gained great popularity in the treatment of glottic carcinomas at first, but the indications quickly broadened toward the treatment of supraglottic and hypopharyngeal carcinomas [13], [14], [15], [16]. The oncologic results are excellent [17], [18] and are comparable to open partial laryngectomies and radiation [19] with respect to local control rates [20] and survival rates [20]. Laser surgery offers the advantage of minimal disturbance of laryngeal function by avoiding the opening of the laryngeal framework and cutting of the prelaryngeal muscles [14]. Further-

more, the sensoric innervation of the larynx remains untouched by preserving the superior laryngeal nerve. Especially with small carcinomas, tracheostomy can be avoided and the usage of feeding tubes can be reduced to a minimum. Transoral laser surgery offers the possible usage of other treatment modalities in patients with local recurrences or metachronous tumors as there is still the possibility of transoral laser re-excision, open partial laryngectomy and radiation therapy. Other advantages include the single-stage surgery and significantly reduced cost because of the quicker rehabilitation and shorter hospital stay [14].

Transcervical open laryngectomies offer a traditional method of treatment with good results in the case of precise analysis and patient selection [21], [22], a prerequisite being exclusion of medical contraindications and disturbances in wound healing (Diabetes, Immunosuppression) as the patient needs a good pulmonary reserve for a prolonged period of postoperative aspiration. A high measure of personal motivation on the patient's side is mandatory in order for the patient to play an active role in postoperative swallowing rehabilitation. It is a prerequisite for any open partial laryngectomy to get the patient's informed consent for the planned surgical procedure as well as a total laryngectomy in order to be able to convert to such a procedure at any time during surgery. Patients that are not able to consent to that are no good candidates for open partial resections [23]. Preoperative analysis of tumor extent and localization is essential as the intraoperative conversion to a total laryngectomy can be reduced significantly. This includes a preoperative workup including laryngoscopy, stroboscopy and a panendoscopy under general anesthesia (Microlaryngoscopy, Bronchoscopy, Esophagoscopy) as well as imaging for advanced cases (usually CT and/or MRI). A whole variety of open partial laryngectomies has been described dependent on extent and localization of the primary [24], [25], [26].

Open partial laryngectomies can be classified into the ones with vertical incisions of the larynx (vertical partial laryngectomies) and the ones with horizontal incisions (horizontal partial laryngectomies). The smallest possible

procedure is an open chordectomy with laryngofissure, these are indicated for small T1 lesions of the middle third of the vocal chord. The vertical or frontolateral laryngectomy is indicated for carcinomas of the vocal chord with mild subglottic extension (T1/T2). Carcinomas infiltrating the inferior ventricle but not the paraglottic space can be amenable to this procedure. In the case of extension to the paraglottic place, the supracricoid laryngectomy may offer a curative approach.

The horizontal or supraglottic laryngectomy is amenable for tumors of the supraglottis infiltrating the ventricle, the aryepiglottic folds and the medial wall of the piriform sinus, mostly T2 and T3-lesions, rarely T4 [23].

The surgical options for transcervical partial laryngectomies for glottic carcinomas include:

1. chordectomy and vertical partial laryngectomy
2. supracricoid partial laryngectomy with cricothyroidopexy (CHEP)

The surgical options for transcervical partial laryngectomies for supraglottic carcinomas include:

1. horizontal supraglottic partial laryngectomy
2. supracricoid partial laryngectomy with cricothyroidopexy (CHP)

The following description of surgical procedures shall not replace a surgical atlas, but rather give an overview of the anatomic basis and basic steps of the procedures.

## 2.2 Techniques of transcervical larynx-preserving surgery

### 2.2.1 Chordectomy and vertical partial laryngectomy

Open chordectomy with or without reconstruction is indicated in T1 glottic lesions that are not amenable to transoral endoscopic laser excision. This includes mostly patients with anatomic contraindications such as stiffened cervical spine, M. Bechterew, retrognathia or trismus that render transoral visualization of the larynx impossible. Contraindications include carcinomas infiltrating the contralateral vocal chord, subglottic extension or infiltration of the ipsilateral false vocal chord [23], in these cases resection needs to be extended.

The first surgical step is tracheostomy. The horizontal skin incision is placed in a skin crease at half the height of the thyroid cartilage. Myocutaneous skin flaps are raised reaching from the cricoid to the hyoid. The vertical laryngofissure is placed in the midline with an oscillating saw. Care is taken not to damage the inner perichondrium. The cricothyroid membrane is horizontally incised on the tumor side at the upper border of the cricoid in a lateral direction. This enables the surgeon to inspect the subglottic area to rule out subglottic extension that has gone unnoticed so far. This would lead to a changed surgical strategy. With absence of subglottic tumor extension, the inner perichondrium is vertically incised in the

midline in a sagittal plane at the anterior commissure. The incision is extended laterally on the tumor side toward the superior laryngeal nerve. The larynx can now be opened and the vocal chord can be inspected. To resect the tumor, horizontal incisions are placed cranially and inferiorly onto the vocal fold. The vocal chord can now be retracted medially and be resected. Posteriorly, the vocal chord is resected from the vocal process, the thyroid cartilage pieces are flipped back together and sutured. A penrose drain is inserted for emphysema prophylaxis and the wound is closed in layers.

The main advantage of the open chordectomy is the excellent overview of the surgical field, the main disadvantage is the necessity of tracheostomy and the destabilization of the laryngeal framework. For a simple open chordectomy, healing by secondary intention might be sufficient but usually leads to a breathy voice, so mostly reconstructive strategies are included in the surgical plan. These include medialization procedures with alloplastic or autologous materials and flaps of the prelaryngeal muscles [27].

The oncologic results are excellent in the carefully selected patient, the largest study was performed by Neel et al. [28] with 182 patients – but in the pre-laser era. Early complications are rare and include postoperative atelectasis, pneumonia and emphysema, perichondritis and infection – cumulated 18% [28]. Late complications include breathy voice, formation of granulations, laryngeal stenosis and -webbing – cumulated 19% [28].

A vertical partial laryngectomy usually entails the resection of a vocal chord from the anterior commissure to the vocal process including the false vocal chord, ventricle, paraglottic space and attached thyroid cartilage (Figure 1). It is indicated in T1 and select T2 glottic carcinomas. T3-lesions may only be treated with this surgical technique in the case of minimal subglottic extension or minimal infiltration of the undersurface of the false vocal chord. The local recurrence rates after vertical partial laryngectomy range from 0%–11% for T1-carcinomas, 4%–26% for T2-carcinomas and up to 46% for T3-carcinomas [23]. This surgical procedure offers excellent local control rates for T1 glottic lesions infiltrating the vocal chord only. Oncologic control decreases significantly with infiltration of the anterior commissure and tumor extension beyond the glottic level with impaired vocal chord mobility. The latter in T2-lesions is usually due to infiltration of the thyroarytaenoid muscle [23], this equals tumor extension to the paraglottic space. The same is true for subglottic tumor extension as this equals infiltration of the cricoid. Supraglottic tumor extension usually leads to infiltration of the thyroid cartilage with decreased local control [23]. The above mentioned factors point out the importance of preoperative imaging especially in T2-carcinomas harboring T3 as faulty planning leads to reduced local control and increased recurrence rates if treated by vertical partial laryngectomy [29]. In conclusion, T3-carcinomas with infiltration of the cricoarytenoid joint are not amenable to vertical partial laryngectomy, they should be treated with supracricoid laryngectomy [29].

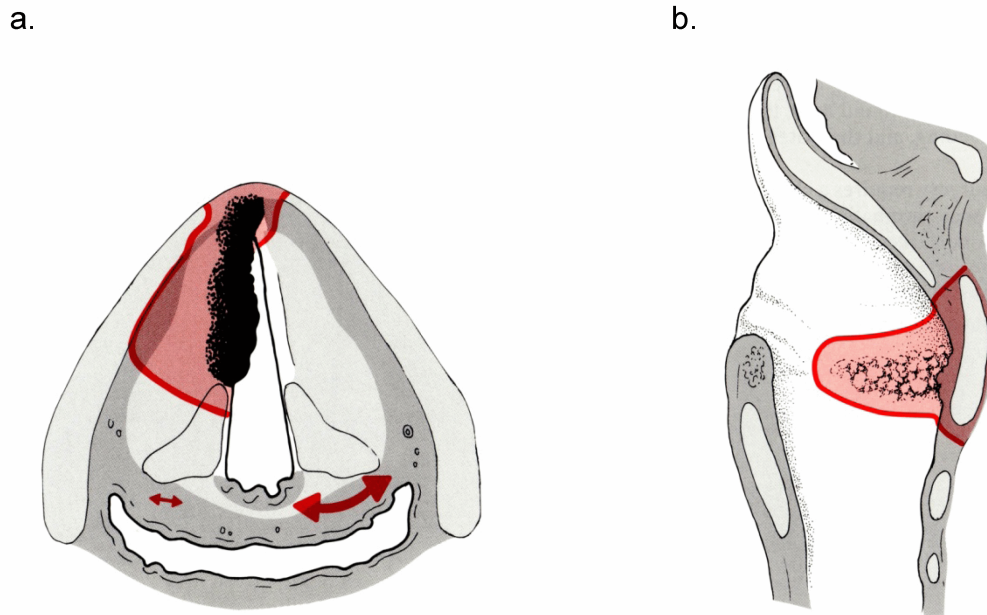


Figure 1(a. and b.): Indications and surgical margins of frontolateral partial laryngectomy (from [154], with permission)

Many modifications of the surgical technique have been published describing varying degrees of resection ranging from resection of the ipsilateral arytenoid, the anterior commissure or the anterior third of the contralateral vocal chord. In addition the upper half of the cricoid can be resected. The extended hemilaryngectomy is described as the standard surgical procedure plus resection of the ipsilateral arytenoid [23].

A frontolateral hemilaryngectomy includes the resection of the anterior commissure and varying extents of the contralateral vocal chord with attached thyroid cartilage [23].

The standard technique enables the patient of glottic phonation and preservation of swallowing. If the extent of surgery is increased, complications increase and there is increased need for reconstructive techniques.

The first surgical step usually is tracheostomy. A horizontal skin incision is followed by raising of subplatysmal flaps from the inferior border of the thyroid cartilage to the hyoid bone (Figure 2). The prelaryngeal muscles are lateralized and the neurovascular pedicles of the superior laryngeal nerves are preserved.

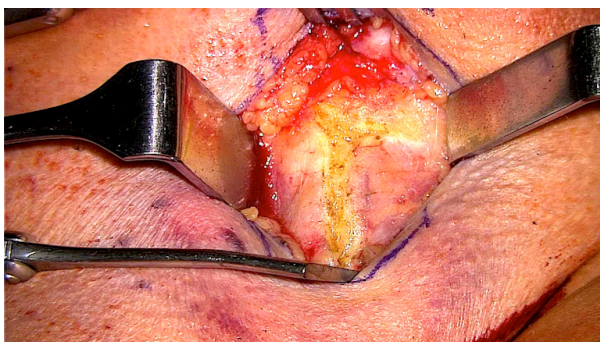


Figure 2: Transcervical approach to vertical partial laryngectomy

The outer perichondrium of the thyroid cartilage is incised in the midline in a sagittal plane with additional extensions of the incision at the cranial and inferior borders of the thyroid cartilage in a lateral direction (Figure 3). The so created perichondrial flaps are mobilized to the oblique line. The thyroid cartilage is incised vertically in the midline using an oscillating saw, in case of infiltration of the anterior commissure, the cartilage incision is placed in a paramedian plane on the non-tumor side (Figure 4). The cricothyroid membrane is incised and an incision is created following the superior border of the cricoid cartilage on the tumor-side. The subglottic space is inspected, if the caudal margin can be kept, the thyrohyoid membrane is incised following the cranial border of the thyroid cartilage on the tumor side to release the epiglottis. The larynx is opened and the extent of the tumor is inspected. A second thyrotomy is placed about 1 cm anterior to the posterior border of the thyroid cartilage to preserve the insertion of the inferior constrictor pharyngis muscle. The corresponding soft tissue cut is placed at the or through the vocal process to keep a posterior margin of at least 2–3 mm. The superior and inferior margins should reach from the false vocal chord to 5 mm below the glottis [30]. In the case of resection of the anterior commissure (Figure 5), the remaining contralateral vocal chord is sutured to the inner perichondrium of the thyroid cartilage using a resorbable mattress suture [23]. The epiglottic petiolus is refixated in the primordial anatomic position to prevent prolapse of the epiglottis. The glottis can be reconstructed using Bailey's omohyoid flaps or a bipediced sternohyoid flap [31]. A wait-and-see strategy may be employed as the prolapsing cervical soft tissues may create sufficient contact for the contralateral vocal chord.

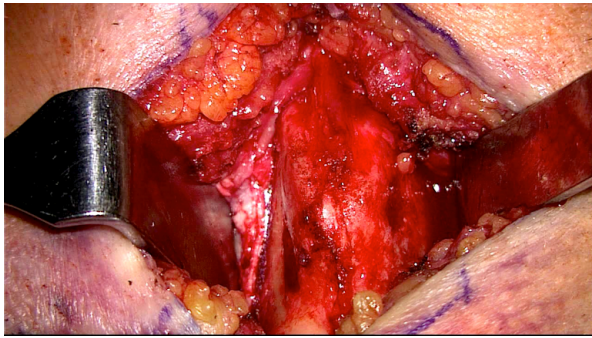


Figure 3: Transcervical dissection of thyroid cartilage

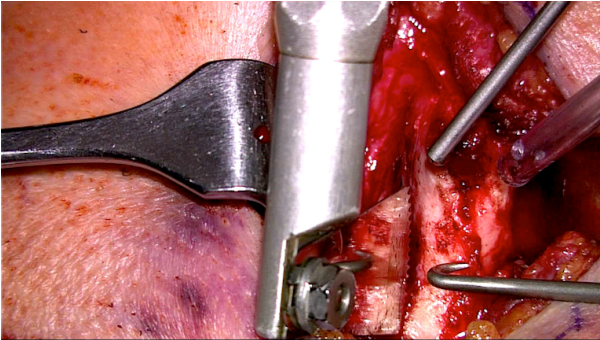


Figure 4: Oscillating saw for cutting the thyroid cartilage

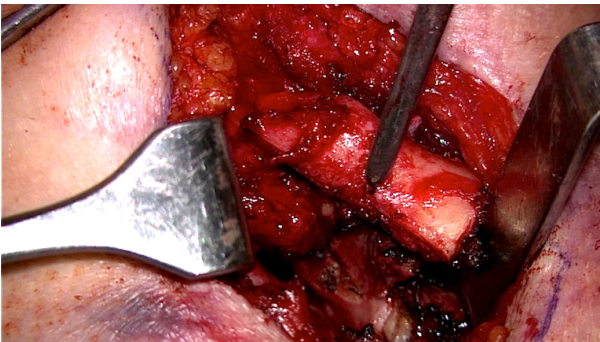


Figure 5: Resection of the anterior commissure

There are no evidence-based studies comparing the different reconstructive strategies. Finally, the remaining outer perichondrium is sutured to the remaining thyroid cartilage. A penrose drain for 5 days is essential, a feeding tube improves wound healing. The tracheostomy can usually be abandoned after 5–8 days and confirmed absence of aspiration as well as an adequately documented patent airway.

Complications are rare, the decannulation is rarely problematic, rehabilitation of adequate swallowing fast if the ipsilateral arytenoid has been preserved. Resection of the anterior commissure and parts of the contralateral vocal chord shortens the anterior-posterior diameter of the larynx leading to impairment of air passage. Resection of the ipsilateral arytenoid – and thus the medial wall of the piriform sinus – impairs swallowing. The more the resection is extended the more airway and swallowing rehabilitation are impaired and the morbidity of the patient is increased.

## 2.2.2 Supracricoid partial laryngectomy with cricohyoidoepiglottopexy (CHEP) or cricohyoidopexy (CHP)

The supracricoid partial laryngectomy was described in 1959 by Majer and Rieder [32] as a transcervical surgical procedure aiming at avoiding the stigmata of total laryngectomy, mainly the permanent tracheostomy. After initial difficulties and refinement of the surgical technique by Labayle and Bismuth [33], the supracricoid partial laryngectomy was established as a standard tool in head and neck oncology. Indications include glottic carcinomas staged T1b, T2, T3 and select T4 in the case of reduced vocal chord mobility or vocal chord fixation, infiltration of the preepiglottic space or the anterior commissure, infiltration of the ventricle or the thyroid cartilage with extralaryngeal spread [23]. Local control for early carcinomas reaches excellent 97.3%, 5-year survival 85% [34]. These numbers decrease with advanced disease, supracricoid laryngectomy provides decreased success rates with invasion of the cricoarytenoid joint and a fixed arytenoid cartilage as well as with infiltration of the extrinsic laryngeal muscles or the recurrent laryngeal nerve. Contraindications include subglottic extension for more than 1 cm, invasion of the cricoid cartilage, infiltration of the posterior commissure and transgression of the outer perichondrium of the thyroid cartilage [23] (Table 2) as well as infiltration of the hyoid bone. Large T4-lesions extending into the prelaryngeal muscles are also not amenable to resection with a supracricoid laryngectomy [23].

Table 2: Contraindications to open supracricoid laryngectomy [155]

Arytenoid fixation
Subglottic extension >10 mm anteriorly, >5 mm laterally
Cricoid infiltration
Infiltration of the preepiglottic space
Infiltration of the hyoid bone
Infiltration of the outer perichondrium of the thyroid cartilage
Extralaryngeal tumor spread

Piquet and Chevalier present their data on 104 patients with T2 glottic carcinomas with infiltration of the anterior commissure, the ventricle, both vocal chords or reduced vocal chord mobility. They propagate conservation of the epiglottis for splinting of the airway and as a contact surface for the remaining arytenoid, they thus established closure of the pharynx using a cricohyoidoepiglottopexy (CHEP [35]). Laccourreye went another way and described his approach in 68 patients with resection of epiglottis and preepiglottic space preserving at least one arytenoid hence closing the pharynx using cricohyoidopexy (CHP [25]).

The surgical procedure of supracricoid laryngectomy contains tumor resection with subsequent reconstruction. The open transcervical approach allows for en bloc resection of vocal chords, paraglottic space bilaterally, epiglottis, thyroid cartilage as well as resection of one or both arytenoids. Disarticulation of the cricothyroid joint is a crucial surgical step and is afflicted with a high incidence of recurrent laryngeal nerve damage. At least one arytenoid as well as the posterior mucosa should be preserved at any cost. The reconstruction relocates the tongue base anteriorly, epiglottis and hyoid bone caudally and anteriorly, these structures are reanchored to the cricoid using mucosal sutures.

The supracricoid laryngectomy aims at enabling the patient to use glottic phonation without permanent tracheostomy. The reconstruction of a neoglottis and the transient destruction of laryngeal anatomy entails a mandatory phase of aspiration. One prerequisite to this procedure is a high level of patient motivation and a good pulmonary reserve in order to overcome the pulmonary sequelae of aspiration.

The surgical procedure starts with the creation of an apron flap similar to a total laryngectomy, the tracheostomy is included in the incision (Figure 6). Subplatysmal flaps are raised from the clavicle up to 1 cm cranially to the hyoid bone (Figure 7). The prelaryngeal muscles are cut at the inferior edge of the hyoid, the perichondrium of the thyroid cartilage is incised at the cranial and lateral edge and the pharyngeal constrictor muscles are dissected from the thyroid cartilage. The piriform sinuses are mobilised posteriorly (Figure 8) followed by disarticulation of the cricothyroid joints. Access to the pharynx is gained in the vallecula caudal to the hyoid, care is taken to preserve as much epiglottis as possible. The epiglottis is retracted anteriorly and the mucosa is incised along the aryepiglottic folds, the incision then cuts the vocal process as well as false vocal chords and true vocal chords posteriorly. On the non-tumor side, the incision is joined with the cricothyrotomy by cutting the cricothyroid muscle. The larynx may now be cracked open [32]. The above depicted incisions are mirrored on the tumor side taking great care to preserve the posterior and interarytenoid mucosa.

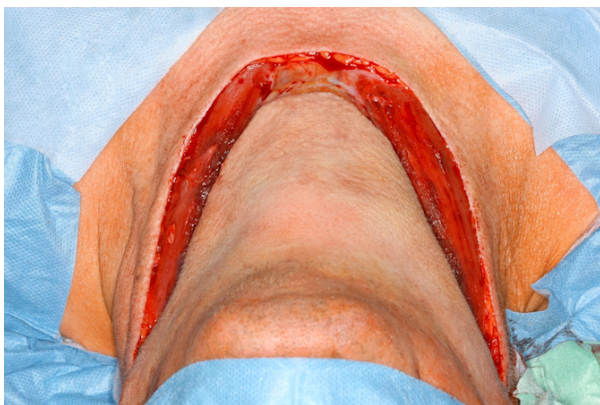


Figure 6: Dissection of an apron flap

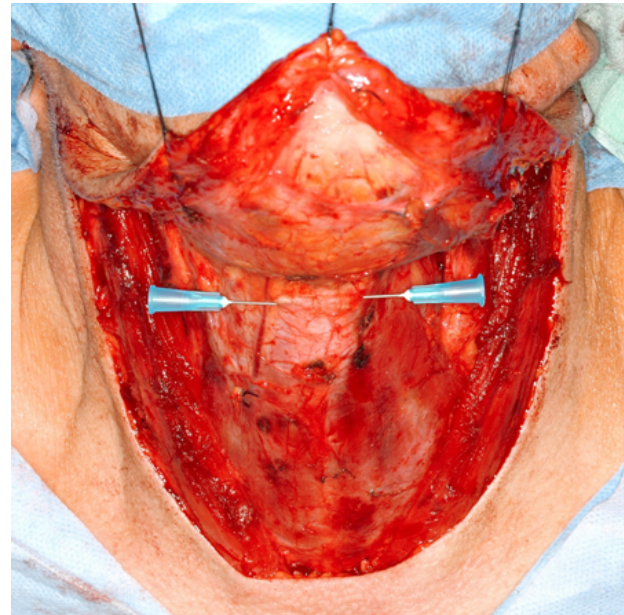


Figure 7: Dissection of an apron flap from hyoid to clavicle, needles mark the hyoid bone

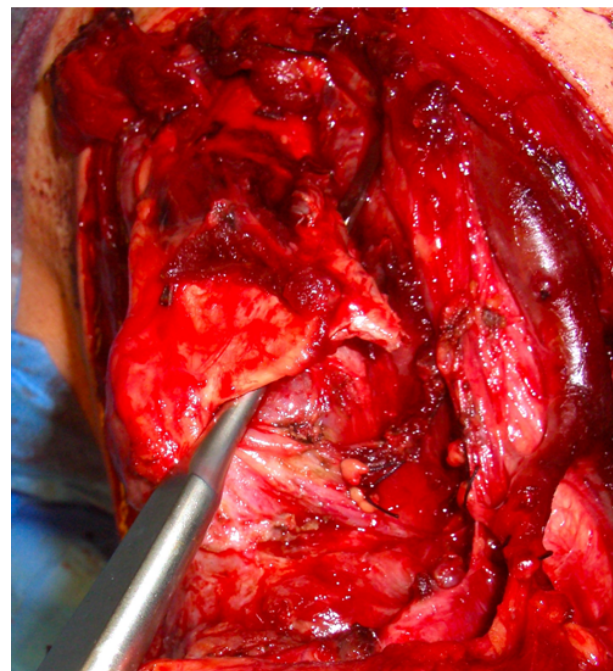


Figure 8: Mobilization of piriform sinus

A neoglottis is reconstructed by anterior rotation of the arytenoids and fixation to the cricoid by sutures. The following sutures approach and fixate cricoid, epiglottis and hyoid bone in the midline as well as 2 symmetric sutures 1 cm lateral in a paramedian plane. The pharynx is thus closed by a CHEP.

Postoperative dysphagia and aspiration are common and must be tackled with immediate aggressive swallowing rehabilitation. Feeding tubes are usually discontinued within 1 to 3 weeks, decannulation of the tracheostomy is usually achieved within 6 to 8 weeks [23].

The most-feared complication of the supracricoid laryngectomy is chronic aspiration. The period of aspiration and dependence on feeding tube/gastrostomy and

tracheostomy is prolonged by adjuvant chemoradiation [23]. Necrosis of the hyoid bone and esophageal/laryngeal stenosis have been described as sequelae to supracricoid laryngectomy and chemoradiation [23]. Local control rates for select T3 and T4-lesions have been reported to be as high as 90% [23].

Tumors extending into the supraglottis are treated best with supracricoid laryngectomy and cricothyroidopexy (CHP) which entails additional resection of the epiglottis and preepiglottic space. Supraglottic lesions that are not amenable to supraglottic laryngectomy due to glottic extension, reduced vocal chord mobility and infiltration of the thyroid cartilage may be treated with a supracricoid laryngectomy and cricothyroidopexy (CHP) as well. The reconstruction is performed with the 3 sutures described above. Persistent dysphagia and aspiration are a problem as with the missing epiglottis the tongue base provides the only protection of the neoglottis. The risk for chronic aspiration after supracricoid laryngectomy and cricothyroidopexy spans 0–11%. Laccourreye described sound oncologic results with this technique in 19 patients with a local control rate 94% [25].

### 2.2.3 Supraglottic laryngectomy

The supraglottic laryngectomy encompasses resection of all laryngeal structures cranial to the glottis, including epiglottis, aryepiglottic folds, false vocal chords, preepiglottic space and the cranial half of the thyroid cartilage (Figure 9). The hyoid bone may be preserved, in case of extensive disease with invasion of the hyoid bone it may be resected. Some studies point out a positive effect of hyoid bone preservation for postoperative swallowing rehabilitation [23]. Standard indications include T1 and T2 supraglottic carcinomas. Treatment of advanced disease using this surgical procedure is afflicted with a recurrence rate up to 45% [36] pointing to a contraindication for this approach in advanced disease. Caudal extension with infiltration of the false vocal chords and impaired vocal chord mobility complete the contraindications (Table 3) [23], [37]. Preoperative evaluation with microlaryngoscopy and panendoscopy is an essential tool in planning the surgical procedure, especially the point of entry into the pharynx. The surgical steps include tracheostomy and mobilization of an apron flap. Bilateral selective neck dissections are standard, they facilitate skeletonization of the larynx. The outer perichondrium of the thyroid cartilage is incised and mobilized caudally following the cranial and posterior borders to about half the vertical height of the cartilage. The cartilage incision is performed cranially of the anterior commissure which lies at about half the vertical height of the thyroid cartilage in men and slightly lower in women. The cranial half of the thyroid cartilage is resected on the tumor side, the incision is beveled obliquely on the non-tumor side to ensure preservation of the superior laryngeal nerve (Figure 10) thus

preserving sensory innervation of the piriform sinus and facilitating swallowing rehabilitation. The incision is performed using an oscillating saw with protection of the inner perichondrium (Figure 11). In case of a tumor that is not invading the vallecula that is the proper entry point using a horizontal incision of the thyrohyoid membrane either caudally or superiorly of the hyoid depending on preservation or resection of the hyoid bone. If the tongue base needs to be resected, at least 1 cm of tongue base posterior to the circumvalate papillae must be preserved in order to guarantee minimal function postoperatively. The epiglottis is retracted exteriorly. With T1 and T2 as well as some T3-lesions there will be definite laterality, so the mucosa is dissected on the non-tumor side following the aryepiglottic folds and the access is widened. The piriform sinuses and the constrictor muscles are mobilized laterally and the larynx rotates anteriorly and inferiorly and the tumor extent is inspected with this panoramic view. Once the arytenoids are reached, dissection continues anteriorly in a horizontal plane cranially to the vocal chord (in the ventricle, caudally to the false vocal chord) to join incisions of cartilage and soft tissue. Identical dissection is performed on the tumor side and the specimen is retrieved en bloc. The pharyngeal mucosa is sutured, the caudally-pediced perichondrial flaps are reflected back cranially and are sutured to the tongue base. The goal of reconstruction is mucosal closure with repositioning of the tongue base above the laryngeal inlet to provide minimal protection of the glottis. This repositioning is achieved by submucosal sutures to approximate tongue base and hyoid bone. Finally, the prelaryngeal muscles and the suprahyoid muscles are sutured [23]. Alimentation of the patient is achieved by feeding tubes for 7 days, after sufficient swallowing rehabilitation the patient is decannulated.

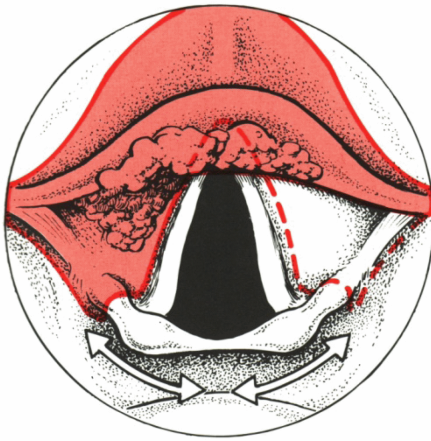
Aspiration occurs postoperatively in nearly all patients, this problem resolves within 3–4 weeks for most of the patients [37]. An aggressive approach toward swallowing rehabilitation is mandatory in extensive resections, satisfactory function is usually achieved after 3–4 months [37]. Long-term complications after transcervical supraglottic laryngectomy include pharyngocutaneous fistulas, permanent tracheostomy, tracheocutaneous fistulas and persistent dysphagia with aspiration-induced pneumonia. The incidence of pharyngocutaneous fistulas may be as high as 12% [23].

In most of the cases watchful waiting and parenteral feeding are sufficient, in rare cases resection and reconstruction using free tissue transfer may be necessary. Up to 6% may need a permanent tracheostomy after open supraglottic laryngectomy, adjuvant chemoradiation further increases the risk [23].

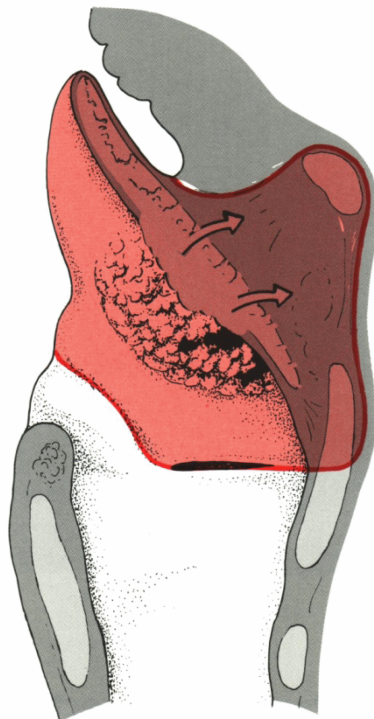


**Table 3: Contraindications to open supraglottic laryngectomy [37]**

Infiltration of glottis or ventricle
Infiltration of the epiglottic petiolus or anterior commissure
Extension to paraglottic space
Infiltration of interarytenoid space
Vocal chord fixation
Infiltration of the apex of the piriform sinus
Bilateral neck nodes with indication to bilateral radical neck dissection
Decreased tongue base mobility
Insufficient pulmonal reserve

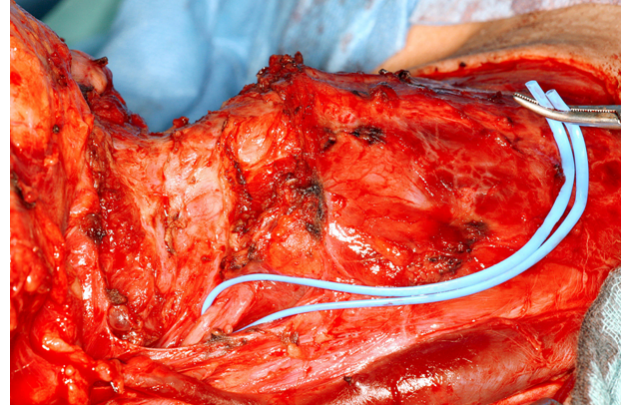


a.

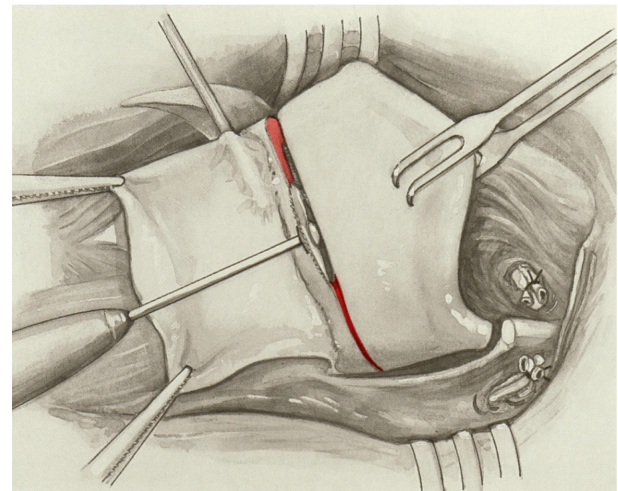


b.

**Figure 9: a. Indications and surgical margins of supraglottic laryngectomy; b. Note potential danger zone: preepiglottic space (both from [154], with permission)**



**Figure 10: Dissection of superior laryngeal nerve**



**Figure 11: Resection of the supraglottis (from [154], with permission)**

### 2.2.4 Total laryngectomy

Total laryngectomy implies the complete removal of the larynx and hence includes resection of cricoid, thyroid cartilage, both arytenoids, false vocal chords, true vocal chords, epiglottis, preepiglottic space, paraglottic space and hyoid bone. Total laryngectomy entails separation of airway and digestive pathway, the patients rely on a permanent tracheostomy. Total laryngectomy is indicated in advanced carcinomas of the larynx (T3/T4) with invasion of the thyroid or cricoid cartilage, subglottic extension greater 1 cm and dyspnea caused by tumor bulk [38]. Additional indications include infiltration of pharyngeal

structures, recurrences after larynx-preserving surgery or chemoradiation.

Surgery starts with an apron flap and bilateral selective neck dissection. The larynx is skeletonized and the perichondrium is incised at the cranial and posterior border. The perichondrium is elevated and the pharyngeal constrictors are dissected posteriorly. The superior cornu of the thyroid cartilage is cut and the neurovascular pedicles of the superior laryngeal nerves are identified and ligated. The thyroid isthmus is ligated and the gland is lateralized. The piriform sinus is mobilized posteriorly, the hyoid bone is skeletonized and resected. The pharynx is entered in the midline, the epiglottis retracted and the mucosa is incised along the aryepiglottic folds. The incisions join at the upper border of the cricoid and dissection is carried inferiorly between trachea and esophagus toward the tracheostomy. The larynx is resected and the mucosa is closed in layers with inverting sutures.

Total laryngectomy provides oncologically sound and good functional results. Phonation is achieved usually by tracheoesophageal puncture (e.g. Provox) and alimentation may be achieved with feeding tubes. Total laryngectomy with adjuvant chemoradiation provides local control rates up to 93% [39]. The Veterans Affairs Trial reported the average survival rate after total laryngectomy to be 86% [39]. The European Cooperative Trial documented an improvement of the survival rate after surgical tumor removal and postoperative radiation from 40% to 53% [40].

## 2.3 Relevance of transcervical laryngeal approaches

There has been an ongoing worldwide debate on the best choice of treatment modality for laryngeal malignancies. Studies support either radiation therapy or transcervical surgery or transoral laser surgery as appropriate. Accepted parameters in judging the effectiveness of the particular treatment modality include: local control rate, laryngeal preservation, complications and side effects of treatment, quality of life and remaining treatment options in the salvage scenario.

### 2.3.1 Early glottic carcinomas (T1/T2)

Treatment choices include transoral endoscopic laser resection, transcervical open resections and/or chemoradiation – each method offering specific advantages and disadvantages.

The work of Steiner provided impressive evidence of excellent local control rates (85–100%) for transoral endoscopic laser resections in the case of early glottic carcinomas with good visualization offering a better functional result and lesser perioperative morbidity [14]. Excluded are carcinomas staged T1b as laser resection can compromise the functional result (voice) due to prevalently forming synechias and webs. In this scenario open resection might be advantageous due to the reconstructive

options, e.g. a posteriorly pedicled flap of the false vocal chords [41].

Retrospective studies comparing local control rates of endoscopic laser resection and open resection in T1a early glottic carcinomas could not show any significant differences. In some studies, advanced stages were associated with a slight advantage for open resections (Table 4) which might be due to better control of the paraglottic space especially by supracricoid laryngectomy. Infiltration of the anterior commissure in early glottic carcinomas is Achilles' tendon of every surgical attempt of treatment. The anterior commissure might act as a distribution board enabling infiltration of the petiolus of the epiglottis, infiltration of the thyroid cartilage and the cricothyroid membrane as well as the anterior subglottis. These features may be missed on endoscopic evaluation and the infiltration of the anterior commissure thus leads to a decrease in local control rates and survival rates after transoral laser resection [18], [42]. Infiltration of the anterior commissure may lead to an increased rate of recurrences after radiation therapy [43], [44], [45]. The situation is complicated by narrow space and difficulty in evaluation of clear margins for surgeon and pathologist. The consequential increased rate of unnoticed R1-resections may explain the heightened rate of recurrences [46]. In this scenario, an open vertical laryngectomy might be useful. Sachse et al. compared local control rates for glottic carcinomas in 119 patients after transoral laser resection and open partial laryngectomy with special regard to infiltration of the anterior commissure and could not find significant differences depending on the treatment chosen (Table 5) [47].

Nevertheless open partial laryngectomy and open supracricoid laryngectomy may offer an alternative to laser surgery in the scenario of anterior commissure infiltration as they offer local control rates of 95 to 98% and about 100% of laryngeal preservation in the case of a supracricoid laryngectomy [48], [49]. However a supracricoid laryngectomy involves extensive dissection and resection and is associated with grave disturbances of laryngeal function, especially compared to laser surgery and radiotherapy.

T2-carcinomas are associated with a greater degree of fluctuation in local control rate, impaired vocal fold movement (T2b) is the key parameter and the prognostic value could be highlighted by Ambrosch: After laser resection, local control rate was 74% [1]. Laccourreye compared open partial laryngectomy and supracricoid laryngectomy for T2N0M0 glottic carcinomas [48], he found significantly higher local control rates and rates of laryngeal preservation for supracricoid laryngectomy, but this was associated with a significantly higher radicality and functional impairment postoperatively.

Bron and co-workers compared surgical approaches (open vs. Laser) to radiotherapy and found similar initial control rates for all treatment modalities. The rate of laryngeal preservation was higher after surgery [43].

The 5-year survival rate averaged 93% for all treatment modalities, the local control rate bordered 84% for

**Table 4: Retrospective studies with initial local control rates for T1/T2 glottic carcinomas (modified according to [38])**

T-Stage	Open chordectomy [28, 156, 157]	Frontolateral laryngectomy [22, 156, 158]	Hemilaryngectomy [31, 48, 159-164]	Supracricoid laryngectomy [35, 67, 155, 165-168]	Laser [15, 18, 42, 159, 169-176]	Radiation [177]
T1a	90–100%	93–96%	91–100%	98–100%	85–100%	84–95%
T1a-b + T2 With infiltration of ant. commissure	–	–	86–98% [76, 178]	–	70–95%	T1: 43–91%, T1T2: 58–74%
T2	–	92%	69–78%	88–96%	66–100%	50–85%

**Table 5: Results of retrospective studies for therapy of T1/T2 glottic carcinomas (modified according to [38])**

Study	No. of patients	Study design	Compared treatment modality	Result
Sachse [47]	119	Retrospective, non-randomized	Open surgery vs. laser	Local control: no significant difference
Bron [43]	156	Retrospective, non-randomized	Surgery (laser or open) vs radiation	Initial local control / laryngeal preservation surgery superior to radiation
Zohar [53]	67	Retrospective, non-randomized	Open surgery vs radiation	Initial local control: open surgery superior to radiation
Rucci [54]	182	Retrospective, non-randomized	Open surgery vs radiation	Initial local control: radiation superior to surgery Local control after salvage surgery: initial surgery superior to radiation

surgical approaches and 77% for radiotherapy. After salvage, the local control rate averaged 96% after initial surgery and 94% after radiotherapy.

A direct comparison of laser surgery and traditional open approaches is documented in 3 studies for tumor stages T1 and T2 [50], [51], [52]. There were no significant differences concerning survival rates, local control rates and the occurrence of regional metastases postoperatively. However, there was a trend toward shorter hospital stays after laser surgery.

The comparison of radiation therapy with open partial laryngectomies in two other studies revealed no significant differences concerning initial local control rates [53], however Rucci and co-workers concluded that if salvage surgery was included in the analysis, initial open partial laryngectomies offer better local control rates than radiation therapy [54].

In conclusion, the minimal data available renders an evidence-based decision for the treating physician hardly possible. The above mentioned studies reveal transcervical open partial laryngectomies to be a valuable treatment modality in early laryngeal carcinomas concerning local control rates and survival rates.

However, in the recent years studies have proved open partial laryngectomies, endoscopic laser surgery and radiation therapy to be effective treatment options, most notably that laser surgery provides similar results compared to transcervical approaches.

Nowadays, if it is decided to choose a surgical approach for early glottic carcinomas, laser surgery should be the

preferred method as it offers equally good results and less perioperative morbidity. However, transcervical approaches should be available as an optional approach and offer significant advantages under difficult anatomical circumstances, additionally in patients with tumors of the anterior commissure.

### 2.3.2 Early supraglottic carcinomas (T1/T2)

The supraglottis is characterized by excellent overview and visualization with the rigid laryngoscope which renders early-staged supraglottic carcinomas (T1/T2) excellent candidates for transoral laser surgery with regard to oncologic and functional results. Local control rates for laser surgery average between 82 and 100% for T1-carcinomas and 63 and 91% for T2-lesions [13], [55], [56], [57] (Table 6). Open supraglottic laryngectomy provides local control rates from 90 to 100% for T1-lesions and from 85 to 100% in T2-carcinomas. In comparison to radiotherapy, local control rates are slightly better with open supraglottic laryngectomy especially for T2-lesions [58], [59].

Lately, studies compared local control rates and 5-year survival rates in supraglottic carcinomas treated with laser surgery and open surgical approaches (supraglottic laryngectomy for T1, supraglottic laryngectomy or total laryngectomy for T2 [60]).

No significant differences could be detected between laser surgery and open surgical treatment with respect to local control and 5-year survival. Laryngeal preservation

Table 6: Results for the treatment of supraglottic laryngeal carcinomas with open partial laryngectomy

Author	N	Location	T-Stage	Treatment with	Adjuvant radiation	Local control	Larynx preservation	5-year survival rate
Bron [57]	75	Supraglottis	T1–3	Supraglottic laryngectomy	25	92.5%	98.5%	75%
Sevilla [179]	267	Supraglottis	T1–4	Supraglottic laryngectomy	125	71%	85%	–
Maurizi [180]	163	Supraglottis	T1–4	Supraglottic laryngectomy	25	–	–	86%
Dufour [67]	118	Glottis + supraglottis	T3	Supracricoid laryngectomy	24	91%	90%	-
Gallo [159]	253	Glottis + supraglottis	T1–4	Supracricoid laryngectomy	10	92.5%	–	79%
Laudadio [181]	206	Glottis + supraglottis	T1–4	Supracricoid laryngectomy	36	93%	97%	81%

after laser surgery was possible in 94% of the patients and 90% after open supraglottic laryngectomy 90%, the complication rate was 8.1% with laser surgery, 24.1% with supraglottic laryngectomy and 17.1% after total laryngectomy. The high incidence of tracheotomies is one negative implication of open supraglottic laryngectomy, however most authors observe that tracheotomy was performed for the sake of patient's safety. There were no significant differences between the surgical approaches concerning swallowing rehabilitation or necessity for percutaneous gastrostomies [60].

So far, 2 studies compared the functional outcomes after open supraglottic laryngectomy and endoscopic lasersurgical supraglottic laryngectomy. Both studies revealed a significantly lower number of tracheostomies with a lasersurgical endoscopic approach. Their postoperative period with need for a feeding tube averaged shorter after lasersurgery. The results for longterm swallowing rehabilitation however did not reveal any significant differences proving that satisfactory swallowing rehabilitation is possible after transcervical supraglottic laryngectomy [61], [62]. All studies detected a significantly higher percentage of silent aspiration after open supraglottic laryngectomy which was documented by videofluoroscopy [61].

Due to the high perioperative morbidity after open supraglottic laryngectomy, this treatment modality nowadays is only a second-line choice in the treatment of early supraglottic carcinomas. Only in cases not amenable to lasersurgical resection open supraglottic laryngectomy should be performed.

### 2.3.3 Advanced glottic carcinomas (T3/T4)

Higher T-stage in glottic carcinomas is correlated with higher divergence in the choice of the therapeutic modality. This is especially true for T3 glottic carcinomas. This may be due to the internationally and regionally differing expertise in laser surgery and open partial resections. Surgical expertise is and individual skill and as such not amenable to standardization. This renders a randomized

comparison between open and lasersurgical approaches impossible [63], hence no evidence-based guidelines exist. Generally, in advanced tumors detailed information should be gathered, especially imaging is important in identifying infiltration of the thyroid cartilage.

Due to the differing expertise, identification of generally accepted constraints in lasersurgical or open approaches remains difficult. Schröder defines hazardous situations that render lasersurgical resection in advanced carcinomas obsolete [64]: 1. A carcinoma of the anterior commissure with deep anterior infiltration, 2. Infiltration of the preepiglottic, paraglottic or subglottic space, 3. Local recurrence after radiation therapy [64].

In addition, with a certain tumor extent and size sufficient formation of scar tissue cannot be summed increasing the risk of chronic aspiration [64]. Supracricoid laryngectomy offers the advantage of cranializing the residual sphincter due to the CHP. This maneuver makes swallowing rehabilitation possible even with one cricoarytenoid unit [64].

Subglottic tumor extension is an early contraindication to laryngeal preservation: A subglottic extension of more than 15 mm is often associated with cricoid infiltration and is a contraindication for open partial resections [64], [65].

Assessment of vocal chord mobility with differentiation between vocal chord fixation due to infiltration of the thyroarytenoid muscle or infiltration of the cricoarytenoid joint is important for surgical planning. Infiltration of the thyroarytenoid muscle may be approached with a curative intent using a supracricoid laryngectomy, studies have proven the oncologic control of the paraglottic space by means of this surgical technique [34]. However, fixation of the cricoarytenoid joint by direct infiltration is a contraindication for a supracricoid laryngectomy. Studies by Sparano et al. could show that infiltration of a cricoarytenoid joint is usually associated with gross cricoid infiltration [65]. Katilmis could show that advanced carcinomas with vocal chord fixation showed infiltration of the cricoarytenoid joint in 50% of the cases [66], this certainty renders infiltration of the cricoarytenoid joint a reliable sign for

cricoid infiltration, hence the contraindication for open partial resection.

Tumor extension into the preepiglottic and paraglottic space may be reliably treated with a supracricoid laryngectomy, with good results with respect to oncologic control and functional outcomes. However, there are certain contraindications in advanced tumor stages. The postoperative integrity of the larynx may not be maintained if the laryngeal framework has been weakened significantly. The structural integrity of the upper respiratory tract is usually guaranteed by the integrity of the cricoid. If resection of the cricoid is necessary, larynx-preserving surgery is not possible, invasion of the cricoid or the mucosa covering the cricoid is a contraindication to larynx-preserving surgery. Likewise the hyoid stabilizes the pharynx. Supracricoid laryngectomy is impossible with infiltration of the hyoid or the tongue base as the hyoid needs to be resected in this scenario. Hence, extralaryngeal tumor spread in carcinomas at stage T4a is regarded a contraindication to supracricoid laryngectomy by some authors [67], [68], but future studies will need to compare the results of supracricoid laryngectomy and total laryngectomy in that respect.

The anterior commissure is a key structure in advanced carcinomas as the clinical signs of cartilage invasion may be missed. Likewise, tumor extension to the thyroarytenoid muscle may be missed as well as such infiltration may not result in diminished vocal chord mobility [69]. Due to these pitfalls, carcinomas of the anterior commissure may be understaged with a resulting higher recurrence rate [70].

In conclusion, even the treatment of advanced carcinomas has been changed toward lasersurgical management with comparable oncologic and functional results. The vertical partial laryngectomy is contraindicated in advanced T-stages, but the last years have proven the supracricoid laryngectomy to be a valuable tool in the surgical armamentarium with special regard to quality of life. The indications compared to total laryngectomy will need to be acuminated by future studies.

### 2.3.4 Advanced supraglottic carcinomas (T3/T4)

Local control becomes more inconsistent in advanced supraglottic carcinomas, T3-carcinomas show a local control ranging from 0% to 75%, T4-carcinomas 0% to 67% [36], [71]. This broad range may be due to tumor extension to the paraglottic space and a wide spectrum of regions with possible tumor spread: A T3-carcinoma may infiltrate differing anatomic regions, ranging from postcricoid to preepiglottic or paraglottic space, additionally, the thyroid cartilage may be involved. Tumor extension into the postcricoid region is a contraindication to supraglottic laryngectomy and can be surgically treated only by total laryngectomy. In addition, open supraglottic laryngectomy is contraindicated in patients with glottic involvement, invasion of cricoid or thyroid cartilage, infiltration of tongue base with the distance to the circumval-

late papillae being less than 1 cm or involvement of the intrinsic tongue muscles. Tumor extension to the preepiglottic space in advanced carcinomas (T3) lasersurgical excision is possible with adequate expertise of the treating surgeon. The key element in resection is complete removal of the preepiglottic space alongside the thyrohyoid membrane and the inner perichondrium of the thyroid cartilage. If this is accomplished, local control rates up to 86% are possible [1]. Alternatively, a transcervical supraglottic laryngectomy poses an oncologically sound approach but is afflicted with a significant morbidity. A key detail during surgery is preservation of the hyoid bone as this serves as an important anchor point for the pexy sutures and accelerates swallowing rehabilitation [64]. Further indications for open supraglottic laryngectomy result from difficult anatomic conditions and better control of lingual and superior thyroid arteries. Bleeding complications from these vessels are a rare but dangerous postoperative complication of transoral lasersurgical excision [64]. Open supraglottic laryngectomy offers a local control rate up to 92% in T3-carcinomas [57]. With tumor extension into the paraglottic space, there may rarely be an indication for a supracricoid laryngectomy in advanced supraglottic carcinomas. Two studies substantiate this for T3N0 supraglottic carcinomas after induction chemotherapy with local control rates being 94.6% [34] and 91.4% [67], ultimate local control was 97.3% [34] and 98.3% [67]. The percentage of patients receiving adjuvant chemoradiation was very low, making the supracricoid laryngectomy a sound approach in recurrence settings.

In conclusion, transoral laser surgery offers an oncologically and functionally sound approach in advanced supraglottic carcinomas with adequate surgical expertise. Transcervical open supraglottic laryngectomy has become a second-line treatment reserved for difficult anatomical situations. Additionally, tumor extension into the paraglottic space may open a possible indication for supracricoid laryngectomy in supraglottic carcinomas.

## 2.4 Salvage surgery after radiotherapy

Laryngectomy has set the gold standard in salvage surgery after radiation failure in glottic carcinomas for decades. The recent years have witnessed an increasing acceptance of lasersurgical approaches in salvage settings as well as transcervical open approaches for recurrences in selected patients. Improved radiation protocols have enabled open partial laryngectomies to be performed as salvage procedures with acceptable oncologic safety and morbidity [72], [73], [74].

Key element is R0-resection [75], this is rendered difficult by postradiogenic edema. It is a well accepted fact that radiation therapy does not lead to concentric shrinking of the tumor but that islands of cancer cells may remain spread over the area of the original tumor extend or even beyond [76]. Hence Shah et al. recommend open partial surgery only for recurrences of T1- and T2-carcinomas that do not extend beyond the original primary [75].

Steiner et al. propagate transoral lasersurgical resection as a possible surgical approach for salvage in patients with recurrences after radiation, he could show a cure rate of 71% in recurrences of early and advanced carcinomas [76]. Open partial larynx-preserving procedures were also performed successfully as a salvage. Holsinger et al. were able to establish that in the salvage setting open larynx-preserving surgery does not show significant differences in locoregional control and survival compared to total laryngectomy [72]. Spriano et al. were able to achieve excellent longterm local control rates with a salvage supracricoid laryngectomy [73]. Laccourreye et al. could establish 75% laryngeal preservation and 100% local control using supracricoid laryngectomy as salvage after radiation failure [77].

Motamed et al. performed a metaanalysis of the available literature on salvage surgery comparing open transcervical approaches and lasersurgical approaches [78] resulting in a slight advantage for larynx-preserving open approaches in the salvage setting for local control. The average reported local control rate for recurrent early glottic cancer after radiotherapy salvaged by using the external or the endolaryngeal laser approach was 77% and 65%. The average reported overall local control rate, including cases that subsequently required total laryngectomy, was 90% and 83%. The endolaryngeal approach when compared with the extralaryngeal approach had the advantage of reduced complications, lesser requirement for tracheostomy and nasogastric feeding, and shortened hospitalization time [78].

Postoperative complications are more frequent in patients having received radiation. A supracricoid laryngectomy as first-line treatment has a mortality of 1% and local complications in 12% of cases. After radiation therapy, the complication rate borders 42% including longterm dysphagia, laryngeal edema and aspiration with aspiration pneumonia [79], the incidence of aspiration pneumonia was 17.5% [80]. All studies documented satisfactory local control rates of 80–85% after salvage surgery, however proper patient selection remains key as the patients need a high level of motivation and a good pulmonary reserve [72]. Holsinger emphasizes that supracricoid laryngectomy might be an option for about 30% of patients in need for salvage surgery, all other patients should be treated with total laryngectomy [72].

Total laryngectomy has been the gold standard in surgical salvage so far. Up to 30% will be complicated by mucocutaneous fistulas after radiation therapy. Salvage laryngectomy is also performed in non-functioning larynges after organ preservation protocols. Christiansen et al. could show total laryngectomy and radiation to be efficient in advanced recurrences with local control bordering 48% and 5-year survival 21%.

In conclusion, the recent years have revealed surgical alternatives to total laryngectomy in the salvage setting, especially transoral laser surgery and transcervical supracricoid laryngectomy. In future, these salvage approaches will have to prove their efficiency in controlled studies.

## 3 Hypopharynx

Carcinomas of the hypopharynx are associated with the worst survival rates in the Head and Neck area and are associated with a significant morbidity. Early symptoms are vague, most patients are diagnosed late with a large tumor extension and regional metastases. The larynx often is involved while hoarseness rarely is a symptom in early tumor stages. Total laryngectomy with partial or total pharyngectomy as first-line treatment is associated with significant morbidity and reduced quality of life. Advances in reconstructive surgery and voice rehabilitation led to more extensive surgical approaches and reduced morbidity with better functional results. However, many patients need to be subjected to adjuvant chemoradiation.

The anatomic structure of the hypopharynx provides the basis for diagnosis and treatment. The clinical course for carcinomas of the piriform sinus is similar to transglottic carcinomas [81]. Lateral and apical extension usually leads to early cartilage infiltration [82] and submucosal spread for more than 10 mm [83]. Tumors of the lateral pharyngeal wall are associated with cartilage invasion in up to 55% of the cases, especially at the posterior wall of the cricoid [82]. Kirchner was able to establish that reduced vocal chord mobility is often caused by invasion of the posterior cricoarytenoid muscle as well as the interarytenoid muscles [84]. Additionally, 42% of the patients showed an infiltration of the intrinsic laryngeal muscles and 16% infiltration of the cricoarytenoid joint [81]. Kirchner described the problem of understaging hypopharyngeal carcinomas in up to 47% of T3-carcinomas as they often show unnoticed cartilage invasion [82]. Carcinomas of the hypopharynx are associated with the worst survival rate of all squamous cell carcinomas of the upper aerodigestive tract, average 5-year survival is 35% and is independent of the chosen treatment [82], [85], [86].

The treatment of hypopharyngeal carcinomas is demanding and remains controversial as the survival rates remain low and possible complications for swallowing and speech may be devastating. Additional difficulty is added by the dilemma between organ-(larynx-)preservation and highest possible quality of life and survival rate. Carcinomas with larger extent and infiltration of adjacent structures show worse control rates with radiation because of large tumor volume and are hence afflicted with a higher amount of radiation-resistant tumor cells. The same is true for carcinomas with extensive cartilage infiltration. Hypopharyngeal carcinomas burden the patients with longstanding dysphagia, weight loss and associated diminished quality of life. These factors often render these patients poor candidates for aggressive surgical or non-surgical therapy.

### 3.1 Surgical approaches for treatment

Traditionally, patients with hypopharyngeal carcinomas were treated with total laryngectomy and partial or circumferent (total) pharyngectomy with postoperative chemoradiation. However, in the recent years preservation of voice

and swallowing became a goal in planning treatment, this led to reduced rates of laryngopharyngectomy and implementation of reconstructive measures, especially free tissue transfer.

Similar to laryngeal carcinomas, studies of perioperative morbidity and mortality led to an increase in radiation therapy. However, the results showed worse outcomes for radiation as a single modality and better results for combination of radiation and chemotherapy [87], [88], [89]. Primary chemoradiation offers similar results as surgical treatment with postoperative radiation with the advantage of laryngeal preservation [90]. In hypopharyngeal cancer, laryngeal preservation has not been in the focus of studies as it has been in advanced laryngeal cancer. Parameters include voice quality, swallowing and quality of life. These parameters may be better after resection of the larynx and absence of aspiration and with phonation using tracheoesophageal puncture compared to preservation of a non-functioning larynx.

Surgical options include: 1. Radical open resection of larynx and pharynx (total laryngectomy with partial or total laryngectomy), 2. Partial open resection (partial laryngectomy with partial pharyngectomy), 3. Transoral laser surgery.

The transcervical surgical approaches often include the laryngectomy, isolated lesions in the hypopharynx may be accessible via lateral pharyngotomy. In this very versatile latter approach, the larynx is mobilised and a vertical incision is placed in the lateral wall of the piriform sinus posterior to the thyroid cartilage. This approach offers access to all subareas of the hypopharynx and is especially useful for tumors of the lateral wall of the piriform sinus and posterior pharyngeal wall. Nowadays this approach is used in tumors with unsatisfactory visualisation and accessibility via the transoral route for laser surgery, another indication is surgical salvage of small tumors due to the excellent overview.

The transcervical approaches may be classified into partial pharyngectomy with partial laryngectomy, total laryngectomy with partial pharyngectomy or circumferent laryngopharyngectomy with or without esophagectomy [91]. A review of the literature offers a vast variety of combinations of partial pharyngectomy and partial transcervical laryngectomy [24], [92], [93]. Partial pharyngectomy may be combined with vertical partial laryngectomy, supraglottic laryngectomy or supracricoid laryngectomy [94], [95]. However, in summary the indication for open partial resections usually was the early stage tumor (T1/T2), nowadays with lasersurgical approaches widely accepted the usage of these techniques has significantly diminished.

Total laryngectomy with partial pharyngectomy is indicated in advanced carcinomas of the piriform sinus and post-cricoid region with laryngeal involvement [91]. This approach offers a traditional and reliable technique with sound oncological results. The extent of the safety margin remains controversial, studies have proved submucosal spread greater 1 cm, the average recommended safety margin is 1–1.5 cm [91].

Circumferent laryngopharyngectomy with or without esophagectomy is indicated if R0-resection is not accomplished with the above mentioned approaches [96] as well as in patients with extensive recurrences after radiation therapy or as primary surgical approach in patients with extensive tumors when chemoradiation might not guarantee sufficient oncologic control and functional results [97].

Overall, mostly patients with early T-stages (T1/T2) are amenable to surgical treatment other than total laryngectomy, most of them will need an adjuvant radiation or chemoradiation. Partial open resection of a hypopharyngeal tumor may be accomplished via transcervical or transoral lasersurgical approaches. Both routes with laryngeal preservation are valuable treatments for T1- or T2-tumors of the hypopharynx, especially the piriform sinus and the posterior pharyngeal wall. The advantages of laser surgery have been highlighted above: lesser amount of fistula formation, absence of the need of reconstruction, shorter hospitalization of patients. However there are no evidence-based studies comparing open transcervical approaches to transoral lasersurgical excisions. Additionally, most hypopharyngeal tumors have reached an advanced stage at primary diagnosis. Thus, the function of larynx and hypopharynx are usually gravely impaired and a total laryngectomy with partial or circumferent pharyngectomy usually is necessary for a curative surgical approach. Total laryngectomy with partial pharyngectomy is indicated if the larynx is grossly infiltrated by the tumor located in the piriform sinus. A total laryngectomy with circumferent pharyngectomy is usually performed if the tumor may not be resected by partial pharyngectomy.

The surgical approach with sacrifice of the larynx as first-line treatment is indicated in the following scenarios: 1. Advanced tumor stage with extensive thyroid cartilage destruction and extralaryngeal tumor extension, 2. Patients with extensive recurrence after radiation failure, 3. Advanced tumor stages that are not amenable to primary radiation or chemoradiation [98].

Total laryngectomy has been traditionally used with a tumor extent of more than two thirds of the hypopharyngeal circumference [99], [100], [101]. The 5-year-survival rates were 40–50%, postoperative chemoradiation further ameliorated tumor control [102]. However, such radical surgical approaches warrant a high rate of postoperative complications: Fistula formation (33%), disturbances in wound healing (25%), stricture formation (15%), permanent dependency on parenteral feeding (PEG, 16%) [103]. Only 44% of the patients were able to regain a voice using tracheoesophageal puncture [103].

Preservation of the larynx is only indicated under the following circumstances: 1. Vocal chords and arytenoid cartilages are fully mobile and not infiltrated by tumor, 2. No infiltration of the apex of the piriform sinus, 3. No invasion of the thyroid cartilage [104], [105].

Open partial resections usually are only amenable in select cases, mostly early stage carcinomas (T1/T2), and include lateral pharyngectomy and hemilaryngopharynx-

Table 7: Local control rates and survival rates with laryngeal preservation in hypopharyngeal carcinomas

Author	No. of patients	T-Stage	Surgical procedure	Local control rate	5-year survival rate
Ogura [95]	160	T1–T4	Open partial laryngopharyngectomy	74%	59%
Laccourreye [94]	34	T2	Supracricoid hemilaryngopharyngectomy	95%	55.8%
Chevalier [24]	48	T1/T2 (piriform sinus)	Supraglottic hemilaryngopharyngectomy + radiation	T1: 78% T2: 38%	47%
Makeieff [106]	87	T1/T2 (piriform sinus)	Supraglottic hemilaryngopharyngectomy + radiation	T1: 83.3% T2: 49.9%	T1: 92.1% T2: 49.2%
Plouin-Gaudon [107]	34	T1–T4 (piriform sinus)	Open partial laryngopharyngectomy + radiation	86%	65%
Vandenbrouck [182]	18	T1/T2 (piriform sinus)	Open partial laryngopharyngectomy + radiation	89%	56%
Martin [108]	33	T1–T4	Transoral laser resection ± radiation	T1: 84% T2: 70% T3: 75% T4: 57%	Stage I/II: 68% Stage III: 64% Stage IV: 41%

gectomy, transoral laser resections are also possible. However, these larynx-preserving strategies will have to be weighed against the possible submucosal spread. Supraglottic hemilaryngopharyngectomy may be used for carcinomas of the upper piriform sinus or aryepiglottic fold. Ogura treated patients with partial laryngopharyngectomy and found a 3-year-survival rate of 67%, for total laryngopharyngectomy the 3-year-survival rate was 43%. The better results for open partial surgery however must be viewed against the background of selection of early-stage tumors for this treatment (Table 7) [95].

Laccourreye treated patients with a T2 hypopharyngeal carcinoma with supracricoid hemilaryngopharyngectomy [94], patients were excluded with invasion of the apex of the piriform sinus, infiltration of the postcricoid or the posterior pharyngeal wall. The goal of their study was to achieve comparable local control with better functional outcomes. Local control was 95%, the 5-year survival rate was 56% [94]. Laccourreye concluded that supracricoid hemilaryngopharyngectomy is a safe strategy in preserving voice production in patients with hypopharyngeal carcinoma.

Another study protocol treated patients with T1/T2-hypopharyngeal carcinomas of the piriform sinus or aryepiglottic fold with induction chemotherapy and supraglottic laryngectomy [24], 5-year survival was 47% and local control for T1/T2-carcinomas was 78%/38%. All patients were able to achieve satisfactory swallowing rehabilitation without aspiration 4 weeks after surgery, all patients received radiation therapy postoperatively. Other studies found similar results [106], [107], and hence the following selection criteria were established for open surgery: 1. Early T-stage, 2. Tumor localization in the piriform sinus,

3. Exclusion of tumor infiltration of the apex of the piriform sinus or the postcricoid area or the parapharyngeal space, 4. Exclusion of thyroid cartilage infiltration.

However, Martin et al. could prove that transoral laser surgery produces similar oncologic and functional results in hypopharyngeal carcinomas with less perioperative morbidity [108].

### 3.2 Significance of surgical approaches depending on tumor location

Total laryngectomy with partial or circumferent pharyngectomy and reconstruction with voice rehabilitation has been the traditional gold standard in treating carcinomas of this location. The recent years have established transoral endoscopic laser surgery or open partial surgical resection as valuable surgical tools in the treatment of early stage carcinomas (T1/T2) in young healthy individuals with good pulmonary reserve [108]. Prerequisites for larynx-preserving surgery are mobility of both vocal chords and no infiltration of the apex of the piriform sinus, contraindications include infiltration of the postcricoid and the thyroid cartilage. These criteria lead to selection of early stage tumors of the cranial lateral wall of the piriform sinus. So in summary, laryngeal preservation seems possible only in patients with early stage (T1/T2) carcinomas. The 5-year survival rate after open partial laryngopharyngectomy was 55% [109], the recurrence rate was as high as 44% [110], [111] and was attributed to submucosal tumor spread [110]. In patients with early stage carcinomas of the piriform sinus, local control rate after 5 years was 80% with a functioning larynx, survival was



50% [112]. The analysis of open partial surgery in advanced carcinomas (T3/T4) [113] showed the 2-year survival rate to be 55% and the 5-year survival rate to be 40% after surgery and postoperative radiation.

Steiner pioneered transoral laser surgery in the treatment of piriform sinus carcinomas [114], [115], [116], 5-year survival in advanced tumor stages (T3/T4) was 64%. The Steiner group presented extensive data in 2001 dealing with the management of all T-stages with transoral laser surgery: In early T-stages (T1/T2) local control was 87% and 5-year survival was 71%, in advanced T-stages (T3/T4) local control was 46% [117].

In conclusion, early stages of piriform sinus carcinoma may be amenable to transoral laser surgery or open partial larynx-preserving approaches. In advanced T-stages however, a more radical approach including total laryngectomy is mandatory to achieve the necessary oncologic safety.

There are no randomized, placebo-controlled trials comparing radiation therapy and surgical treatment. No treatment leads to a rapid deterioration with 50% mortality after 6 weeks, 90% mortality after 4 months and 100% mortality after 9 months [118]. The established safety margins are 3 cm inferiorly and 1–1.5 cm laterally, this mostly leads to a total laryngo-pharyngectomy. Usually, transoral laser surgery is not possible because of difficult visualization and proximity to laryngeal muscles, arytenoid cartilages and recurrent nerves [81].

In carcinomas of the posterior pharyngeal wall the surgical approach is mostly dictated by the tumor extension. The prognosis for this anatomical location usually is poor on the grounds of submucosal spread and infiltration of the prevertebral fascia. Again, no randomized, placebo-controlled studies exist, the literature reveals sparse publications on the topic. Most publications report the results of treatment of carcinomas of the posterior pharyngeal wall in hypopharyngeal as well as oropharyngeal carcinomas, so no isolated results for the hypopharynx exist. Spiro treated 78 patients surgically via a lateral/anterior pharyngotomy and/or laryngectomy [119] and found a 2-year survival rate of 49% and a 5-year survival rate of 32%. In carcinomas originating from the posterior pharyngeal wall, the 2- and 5-year survival rates were 58% and 34% respectively [119]. The survival rates of early stages (T1/T2) were significantly higher than in advanced stages (T3/T4) [119]. Local recurrences occurred in 41%, regional metastases in 21% and distant metastases in 9% [119]. Another study found a 5-year-survival rate of 30% after primary surgery and postoperative radiation in T1/T2-carcinomas [120], additionally, in advanced tumors, primary surgery showed better results than radiation alone [120].

In conclusion, tumor extension and volume dictate the treatment in early and advanced hypopharyngeal carcinomas originating from the posterior pharyngeal wall, in early carcinomas laryngeal preservation may be possible by the usage of laser surgery, alternatively via the transcervical route. With increasing tumor extent, laryngeal preservation is more difficult to achieve and tumor resec-

tion with a radical surgical approach and reconstruction becomes necessary.

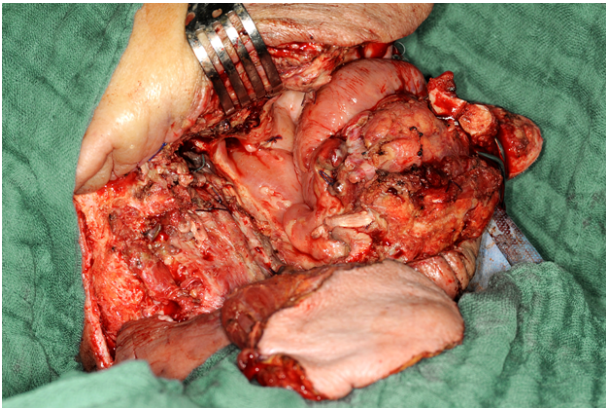
### 3.3 Reconstructive options

Reconstruction of a hypopharyngeal defect remains a challenging task, starting from the Wookey-Flap [121], developing from usage of a deltopectoral flap [122], pectoralis-major-flap [123], gastric transposition [124] and jejunal transfer [125], gastro-omental free flap [126] toward the anterolateral thigh-flap [127] and radial forearm flap [128], the latter two offering a good combination of ready accessibility, good reliability and acceptable [129].

The goal of any reconstruction in the pharyngeal area is the reestablishment of form (pharyngeal tube) and function (speech, swallowing) with minimal postoperative complications (pharyngocutaneous fistula, pharyngeal stenosis) [130], [131]. The choice of the reconstructive approach is dictated by defect size and position as well as factors like previous radiation or chemoradiation and concomitant medical diseases [130]. However, the 5-year-survival-rates remain rather disappointing in spite of advances in reconstructive techniques and have to be taken into account for the choice of treatment modality [130], [131]. Disa et al. classify hypopharyngeal defects into 4 categories and developed an algorithm for reconstruction [132]. Type 1-defects were partial and comprise less than 50% of the pharyngeal circumference, the choice for reconstruction was the radial forearm flap. Type 2-defects were circumferent or comprised more than 50% of the pharyngeal circumference, the choice for reconstruction was free jejunum. Type 3-defects were long non-circumferent defects including several levels (e.g. additional parts of nasopharynx, oropharynx, floor of the mouth or mandible) and were reconstructed with a rectus abdominis flap. Type 4-defects included the cervical esophagus and were reconstructed with a gastric transposition. Urken et al. modified classification and algorithm: Type 0-defects were treated with primary closure, type 1-defects were described as non-circumferent defects with at least a 2 cm mucosal bridge remaining to bridge the gap. Type 2-defects were circumferent, did not infiltrate the esophagus and cranially did not reach past the vallecula. Type 3-defects were partial or circumferent and reached past the vallecula cranially. Type 4-defects caudally stretched past the clavícula [133]. Overall, the reconstructive strategies were similar to the ones suggested by Disa. Clark et al. presented a practically oriented algorithm for hypopharyngeal reconstruction [103].

Defects of the lateral piriform sinus after partial hypopharyngectomy or partial pharyngectomy without laryngectomy usually can be closed primarily. In larger defects after partial pharyngectomy with laryngectomy, reconstruction usually is mandatory. Numerous regional or free flaps have been described, generally a flexible and thin flap is desirable for the sake of ease in forming the pharyngeal tube [103], [134], [135], [136]. This is why the radial forearm and anterolateral thigh flaps have become

workhorses in pharyngeal reconstruction. The pectoralis major flap for years remained the mainstay in pharyngeal reconstruction providing safe and abundant vascularity and safe usage after chemoradiation. Disadvantages are the relatively high rate of distal necrosis (10%) with possible formation of fistulas and the less appealing appearance of the donor site (Figure 12) [137].



**Figure 12: Partial pharyngolaryngectomy with pectoralis major-flap for reconstruction**

Microvascular free tissue transfer (Radial Forearm Flap, Anterolateral Thigh Flap) minimizes donor site morbidity and is afflicted with a lower rate of partial flap necroses [135]. Compared to reconstructions of circumferent defects, the reconstructions after partial pharyngectomies present with better functional results (swallowing, stenosis) [103]. Tracheoesophageal puncture is used for voice rehabilitation and offers acceptable results [103]. In circumferent defects free tissue transfer demands more complex reconstructions, the perioperative morbidity however is significantly reduced [103]. The key element for flap choice is involvement of the cervical esophagus. With esophageal infiltration, gastric pullup is the reconstruction of choice [96]. Usage of pectoralis major flaps has diminished in circumferent defects as the muscle bulk leads to difficulties in forming the pharyngeal tube, partial necrosis is up to 10%, the rate of fistula 13 to 63%. Postoperative swallowing rehabilitation after a pectoralis major flap is difficult and the rate of stenosis remains high [137].

Over the years circumferent reconstruction has been established using enteric free flaps, especially jejunal free flaps and the Gastro-Omental Free Flap. The usage of a jejunal free flap has declined over the years due to the high perioperative morbidity [138]. The latter could be lowered with laparoscopic flap harvest [139], however patients complain postoperatively about dysphagia due to uncontrolled peristalsis, mucus production and a high rate of stenosis (7–15%), the rate of fistula formation is 7–31% [140]. Theile et al. report a success rate of 97%, a postoperative mortality of 4.5%, local complications in the neck of 17% and in the abdomen of 2.5%. Achievement of sufficient swallowing rehabilitation was reported after an average of 11 days [141]. The expedient functionality of the transferred jejunal segment remains in

the focus of debate. Electrophysiologic studies prove the existence of peristaltic movements, however no coordinated contractions could be seen [142]. These movements diminish with time, so the jejunum transforms to a passive tubular conduit. This transformation explains the longterm amelioration of swallowing in these patients [143].

If a laparotomy is indicated, nowadays the tendency is to choose the Gastro-Omental Free Flap over the Jejunal Free Flap, especially in the salvage setting as the abundant omentum can be used to cover exposed cervical vessels and to protect the reconstructed pharyngeal wall [91], [144], [145]. The fistula rate in high-risk patients was reported to be 0–16% [91], [144]. Swallowing rehabilitation is easier as no peristalsis needs to subside [145]. Donor site morbidity is minimal, only the antrum should be avoided as a donor site [145].

Studies have shown in the previous years, that fasciocutaneous flaps are superior to enteric free flaps with respect to voice rehabilitation, complication rate and postoperative morbidity. The latter is largely due to the avoidance of laparotomy [128], [146], [147], [148], [149]. The radial forearm flap and the anterolateral thigh flap are the workhorses due to their pliability. The anterolateral thigh flap has replaced the radial forearm in most centers due to the minimized donor site morbidity, however, in patients with a huge thigh circumference, problems may arise in molding the pharyngeal tube. This can be ameliorated by the usage of a salivary bypass [150]. The rate of pharyngocutaneous fistulas showed significant differences: The radial forearm had a 53% rate, the anterolateral thigh flap 9% [103]. The lower fistula rate of the anterolateral thigh flap is attributed to the presence of the firm fascia which can be used as a second layer in pharyngeal reconstruction [103]. In contrast, the radial forearm flap is afflicted with a lower rate of stenosis compared to up to 27% in the anterolateral thigh flap [103].

In conclusion, patients that are treated surgically with a laryngopharyngectomy represent a high risk group for postoperative complications, in the primary setting as well as in the salvage setting. Older studies argue against reconstruction due to the poor survival rates [137]. Current studies report sound locoregional control rates and acceptable 5-year survival-rates (37% [103]). Clark et al. present reconstructive algorithms for the reconstruction of partial and circumferent pharyngeal defects with the best possible safety and least postoperative morbidity (Figure 13, Figure 14) [103].

### 3.4 Salvage surgery

The role of salvage surgery after radiation failure in hypopharyngeal carcinomas remains controversial. Salvage surgery is indicated in case of recurrence that is resectable. The patient needs to be free of distant metastases and must be capable of tolerating the surgical procedure [130]. These selection criteria extract about 40% of the patients with recurrences for salvage surgery, the 5-year survival rates after salvage surgery average at about 20%

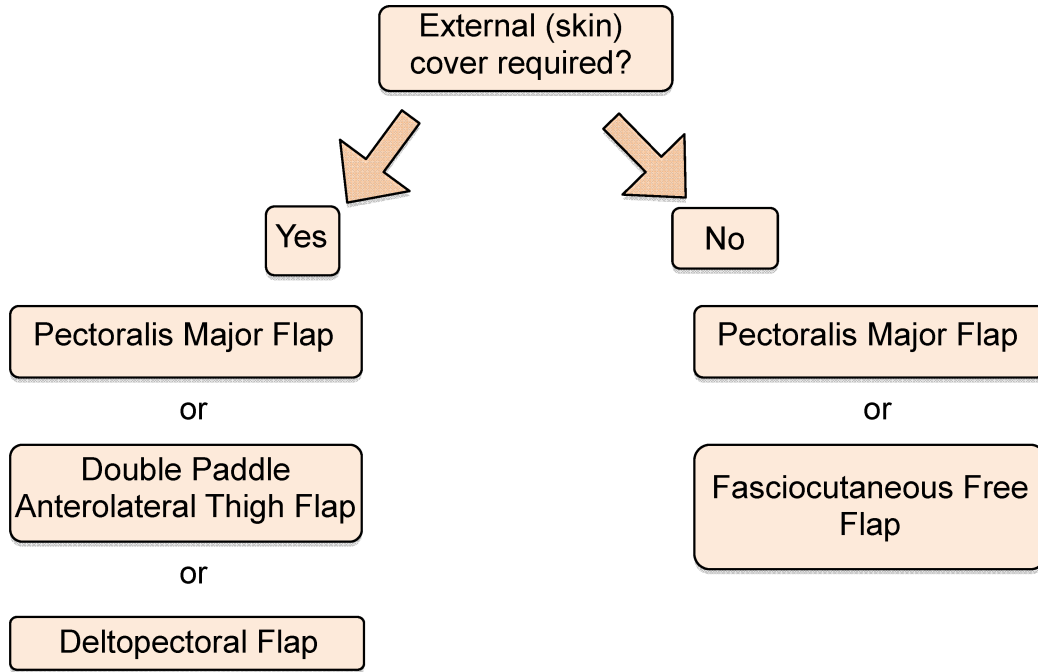


Figure 13: Reconstruction of partial laryngopharyngeal defects (modified from [103], with permission)

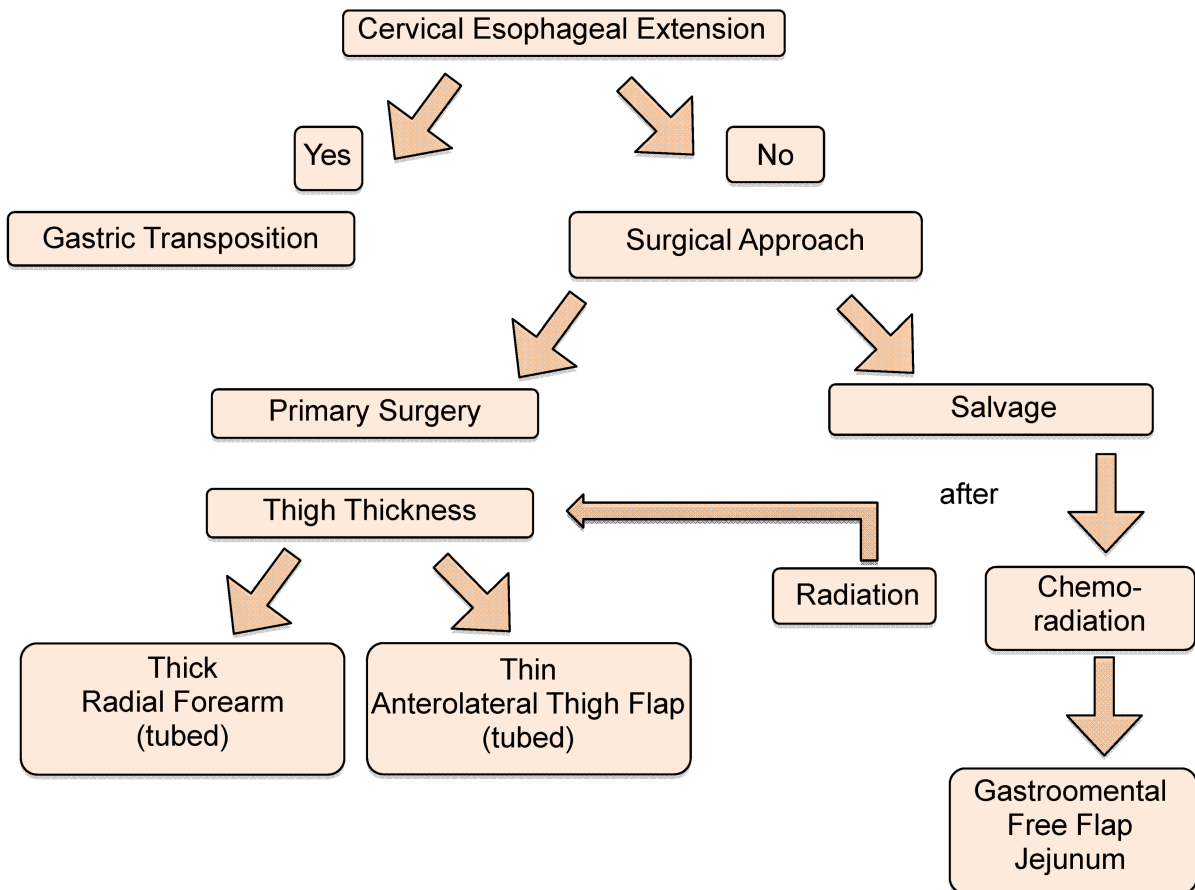


Figure 14: Reconstruction of circumferential laryngopharyngeal defects (modified from [103], with permission)

[151], the approach of choice is total laryngectomy with or without total pharyngectomy with the above mentioned reconstructive procedures. As discussed above for laryngeal carcinomas, submucosal spread and difficult

assessment after radiation render diagnosis difficult, hence most authors recommend radical surgical resections in spite of the high morbidity [152], [153]. Interest-

ingly, prognosis in patients with neck recurrences is the same as in patients with pharyngeal recurrences [151].

## 4 Conclusion

Open transcervical approaches remain a valuable tool in selected patients, especially in patients with difficult anatomical composition and poor laryngeal visualization with the rigid endoscope. Open transcervical approaches can be used in early as well as in advanced tumor stages. The possibility of performing an en bloc resection as well as excellent visualization and safe R0-resection especially in locations otherwise difficult to reach, e.g. anterior commissure or in the salvage setting, nourish the need for these traditional techniques.

Supracricoid laryngectomy is a valuable tool if the paraglottic space is infiltrated or in the salvage situation as it offers oncologically sound and safe therapy at the cost of high postoperative morbidity and difficult swallowing rehabilitation. The indications for supracricoid laryngectomy must be carved out in future studies, especially with respect to the indications for total laryngectomy. Especially in the salvage setting, the previous years have shown a paradigm shift towards transoral lasersurgical approaches and the transcervical supracricoid laryngectomy. These treatment options will have to prove their value in future studies with respect to oncologic safety and preservation of function.

Due to the increase in transoral laser resections, the indications for open transcervical approaches to partial pharyngectomy with partial laryngectomy in early hypopharyngeal carcinomas have significantly decreased. Transcervical larynx-preserving approaches are only indicated in hypopharyngeal tumors without infiltration of the apex of the piriform sinus or thyroid cartilage as well as no restricted movement of the arytenoids and vocal chords. Total laryngectomy with partial pharyngectomy offers reliable oncologic results in advanced tumor stages of piriform sinus and postcricoid with laryngeal involvement. More radical approaches as circumferent laryngopharyngectomy with or without esophagectomy are indicated in the salvage situation in patients with extensive recurrences after radiation and as a primary surgical approach in huge tumors that are likely to not be oncologically controllable by primary chemoradiation and might result in frustrating functional outcomes. If reconstruction is needed, partial and circumferent defects without involvement of the cervical esophagus are best reconstructed with a fasciocutaneous free flap (anterolateral thigh, radial forearm), studies suggest them to offer superior results compared to enteric free flaps (jejunum, gastroomental free flap), they seem to produce better results in voice rehabilitation with less morbidity by avoidance of laparotomy. The Gastro-Omental Free Flap has proven to be a valuable tool in the salvage setting. In conclusion, the rise in transoral lasersurgical approaches and primary chemoradiation has led to a significant decrease in transcervical approaches to laryngeal

and pharyngeal carcinomas. In consideration of late toxicity of chemoradiation, the above mentioned open approaches will have to prove their value in new, organ-preservation algorithms – as primary approaches as well as in salvage approaches.

## Notes

### Competing interests

The author declares that he has no competing interests.

## References

- Ambrosch P, Rödel R, Kron M, Steiner W. Die transorale Lasermikrochirurgie des Larynxkarzinoms. *Der Onkologe*. 2001;7:505-12. DOI: 10.1007/s007610170103
- Induction chemotherapy plus radiation compared with surgery plus radiation in patients with advanced laryngeal cancer. The Department of Veterans Affairs Laryngeal Cancer Study Group. *N Engl J Med*. 1991 Jun;324(24):1685-90. DOI: 10.1056/NEJM199106133242402
- Forastiere AA, Goepfert H, Maor M, Pajak TF, Weber R, Morrison W, Glisson B, Trotti A, Ridge JA, Chao C, Peters G, Lee DJ, Leaf A, Ensley J, Cooper J. Concurrent chemotherapy and radiotherapy for organ preservation in advanced laryngeal cancer. *N Engl J Med*. 2003 Nov;349(22):2091-8. DOI: 10.1056/NEJMoa031317
- Davies L, Welch HG. Epidemiology of head and neck cancer in the United States. *Otolaryngol Head Neck Surg*. 2006 Sep;135(3):451-7. DOI: 10.1016/j.otohns.2006.01.029
- Jemal A, Siegel R, Ward E, Murray T, Xu J, Thun MJ. Cancer statistics, 2007. *CA Cancer J Clin*. 2007 Jan-Feb;57(1):43-66. DOI: 10.3322/canjclin.57.1.43
- Gregor RT. The preepiglottic space revisited: is it significant? *Am J Otolaryngol*. 1990 May-Jun;11(3):161-4. DOI: 10.1016/0196-0709(90)90031-P
- Rucci L, Gammarota L, Borghi Cirri MB. Carcinoma of the anterior commissure of the larynx: I. Embryological and anatomic considerations. *Ann Otol Rhinol Laryngol*. 1996 Apr;105(4):303-8.
- Kirchner JA. One hundred laryngeal cancers studies by serial section. *Ann Otol Rhinol Laryngol*. 1969 Aug;78(4):689-709.
- Andrea M, Guerrier Y. The anterior commissure of the larynx. *Clin Otolaryngol Allied Sci*. 1981 Aug;6(4):259-64. DOI: 10.1111/j.1365-2273.1981.tb01545.x
- Brzóška M, Pietrysiak A, Kruk-Zagajewska A. Znaczenie przestrzeni okologicznej dla rozprzestrzeniania się raka krtani [The impact of paraglottic space for laryngeal cancer spread]. *Otolaryngol Pol*. 2005;59(4):527-32.
- Olsen KD. Reexamining the treatment of advanced laryngeal cancer. *Head Neck*. 2010 Jan;32(1):1-7. DOI: 10.1002/hed.21294
- Strong MS, Jako GJ. Laser surgery in the larynx. Early clinical experience with continuous CO<sub>2</sub> laser. *Ann Otol Rhinol Laryngol*. 1972 Dec;81(6):791-8.
- Rudert HH, Werner JA, Höft S. Transoral carbon dioxide laser resection of supraglottic carcinoma. *Ann Otol Rhinol Laryngol*. 1999 Sep;108(9):819-27.

14. Steiner W, Ambrosch P. Endoscopic Laser Surgery of the Upper Aerodigestive Tract: With Special Emphasis on Cancer Surgery. Stuttgart/NewYork: Thieme Medical Publishers; 2010.
15. Eckel HE, Thumfart WF. Laser surgery for the treatment of larynx carcinomas: indications, techniques, and preliminary results. *Ann Otol Rhinol Laryngol.* 1992 Feb;101(2 Pt 1):113-8.
16. Iro H, Waldfahrer F, Altendorf-Hofmann A, Weidenbecher M, Sauer R, Steiner W. Transoral laser surgery of supraglottic cancer: follow-up of 141 patients. *Arch Otolaryngol Head Neck Surg.* 1998 Nov;124(11):1245-50.
17. Ambrosch P. The role of laser microsurgery in the treatment of laryngeal cancer. *Curr Opin Otolaryngol Head Neck Surg.* 2007 Apr;15(2):82-8. DOI: 10.1097/MOO.0b013e3280147336
18. Steiner W, Ambrosch P, Rödel RM, Kron M. Impact of anterior commissure involvement on local control of early glottic carcinoma treated by laser microresection. *Laryngoscope.* 2004 Aug;114(8):1485-91. DOI: 10.1097/00005537-200408000-00031
19. Abdurehim Y, Hua Z, Yasin Y, Xukurhan A, Imam I, Yuqin F. Transoral laser surgery versus radiotherapy: systematic review and meta-analysis for treatment options of T1a glottic cancer. *Head Neck.* 2012 Jan;34(1):23-33. DOI: 10.1002/hed.21686
20. Strojan P, Ferlito A, Langendijk JA, Corry J, Woolgar JA, Rinaldo A, Silver CE, Paleri V, Fagan JJ, Pellitteri PK, Haigentz M Jr, Suárez C, Robbins KT, Rodrigo JP, Olsen KD, Hinni ML, Werner JA, Mondin V, Kowalski LP, Devaney KO, de Bree R, Takes RP, Wolf GT, Shaha AR, Genden EM, Barnes L. Contemporary management of lymph node metastases from an unknown primary to the neck: II. A review of therapeutic options. *Head Neck.* 2011 Oct;.: DOI: 10.1002/hed.21899
21. Alonso JM. La chirurgie conservatrice pour le cancer du larynx et de l'hypopharynx [Conservative surgery of cancer of the larynx and hypopharynx]. *Ann Otolaryngol.* 1951;68(8-9):689-96.
22. Brumund KT, Gutierrez-Fonseca R, Garcia D, Babin E, Hans S, Laccourreye O. Frontolateral vertical partial laryngectomy without tracheotomy for invasive squamous cell carcinoma of the true vocal cord: a 25-year experience. *Ann Otol Rhinol Laryngol.* 2005 Apr;114(4):314-22.
23. Tufano RP, Stafford EM. Organ preservation surgery for laryngeal cancer. *Otolaryngol Clin North Am.* 2008 Aug;41(4):741-55, vi. DOI: 10.1016/j.otc.2008.01.020
24. Chevalier D, Watelet JB, Darras JA, Piquet JJ. Supraglottic hemilaryngopharyngectomy plus radiation for the treatment of early lateral margin and pyriform sinus carcinoma. *Head Neck.* 1997 Jan;19(1):1-5. DOI: 10.1002/(SICI)1097-0347(199701)19:1<1::AID-HED1>3.0.CO;2-A
25. Laccourreye H, Laccourreye O, Weinstein G, Menard M, Brasnu D. Supracricoid laryngectomy with cricohyoidopexy: a partial laryngeal procedure for selected supraglottic and transglottic carcinomas. *Laryngoscope.* 1990 Jul;100(7):735-41. DOI: 10.1288/00005537-199007000-00009
26. Laccourreye H, Laccourreye O, Weinstein G, Menard M, Brasnu D. Supracricoid laryngectomy with cricohyoidoepiglottopexy: a partial laryngeal procedure for glottic carcinoma. *Ann Otol Rhinol Laryngol.* 1990 Jun;99(6 Pt 1):421-6.
27. Su CY, Chuang HC, Tsai SS, Chiu JF. Bipedicled strap muscle transposition for vocal fold deficit after laser cordectomy in early glottic cancer patients. *Laryngoscope.* 2005 Mar;115(3):528-33. DOI: 10.1097/01.MLG.0000150091.55295.56
28. Neel HB 3rd, Devine KD, Desanto LW. Laryngofissure and cordectomy for early cordal carcinoma: outcome in 182 patients. *Otolaryngol Head Neck Surg.* 1980 Jan-Feb;88(1):79-84.
29. Mohr RM, Quenelle DJ, Shumrick DA. Vertico-frontolateral laryngectomy (hemilaryngectomy). Indications, technique, and results. *Arch Otolaryngol.* 1983 Jun;109(6):384-95. DOI: 10.1001/archotol.1983.00800200030010
30. Shaw HJ. A view of partial laryngectomy in the treatment of laryngeal cancer. *J Laryngol Otol.* 1987 Feb;101(2):143-54. DOI: 10.1017/S0022215100101410
31. Bailey BJ, Calcaterra TC. Vertical, subtotal laryngectomy and laryngoplasty. Review of experience. *Arch Otolaryngol.* 1971 Mar;93(3):232-7. DOI: 10.1001/archotol.1971.00770060370002
32. Majer EH, Rieder W. [Technic of laryngectomy permitting the conservation of respiratory permeability (cricohyoidopexy)]. *Ann Otolaryngol.* 1959 Jul-Aug;76:677-81.
33. Labayle J. Laryngectomie totale reconstitutive [Reconstructive total laryngectomy]. *Otorinolaringologie.* 1972 Mar-Apr;17(2):115-24.
34. Chevalier D, Laccourreye O, Brasnu D, Laccourreye H, Piquet JJ. Cricohyoidoepiglottopexy for glottic carcinoma with fixation or impaired motion of the true vocal cord: 5-year oncologic results with 112 patients. *Ann Otol Rhinol Laryngol.* 1997 May;106(5):364-9.
35. Piquet JJ, Chevalier D. Subtotal laryngectomy with crico-hyoido-epiglottopexy for the treatment of extended glottic carcinomas. *Am J Surg.* 1991 Oct;162(4):357-61. DOI: 10.1016/0002-9610(91)90148-7
36. Burstein FD, Calcaterra TC. Supraglottic laryngectomy: series report and analysis of results. *Laryngoscope.* 1985 Jul;95(7 Pt 1):833-6.
37. Rinaldo A, Ferlito A. Open supraglottic laryngectomy. *Acta Otolaryngol.* 2004 Sep;124(7):768-71. DOI: 10.1080/00016480310000737
38. Hartl DM, Landry G, Hans S, Marandas P, Casiraghi O, Janot F, Brasnu DF. Thyroid cartilage invasion in early-stage squamous cell carcinoma involving the anterior commissure. *Head Neck.* 2012 Oct;34(10):1476-9. DOI: 10.1002/hed.21950
39. Induction chemotherapy plus radiation compared with surgery plus radiation in patients with advanced laryngeal cancer. The Department of Veterans Affairs Laryngeal Cancer Study Group. *N Engl J Med.* 1991 Jun;324(24):1685-90. DOI: 10.1056/NEJM199106133242402
40. Bernier J, Domenge C, Ozsahin M, Matuszewska K, Lefebvre JL, Greiner RH, Giral J, Maingon P, Rolland F, Bolla M, Cognetti F, Bourhis J, Kirkpatrick A, van Glabbeke M. Postoperative irradiation with or without concomitant chemotherapy for locally advanced head and neck cancer. *N Engl J Med.* 2004 May;350(19):1945-52. DOI: 10.1056/NEJMoa032641
41. Biacabe B, Crevier-Buchman L, Hans S, Laccourreye O, Brasnu D. Phonatory mechanisms after vertical partial laryngectomy with glottic reconstruction by false vocal fold flap. *Ann Otol Rhinol Laryngol.* 2001 Oct;110(10):935-40.
42. Chone CT, Yonehara E, Martins JE, Altemani A, Crespo AN. Importance of anterior commissure in recurrence of early glottic cancer after laser endoscopic resection. *Arch Otolaryngol Head Neck Surg.* 2007 Sep;133(9):882-7. DOI: 10.1001/archotol.133.9.882
43. Bron LP, Soldati D, Monod ML, Mégevand C, Brossard E, Monnier P, Pasche P. Horizontal partial laryngectomy for supraglottic squamous cell carcinoma. *Eur Arch Otorhinolaryngol.* 2005 Apr;262(4):302-6. DOI: 10.1007/s00405-004-0824-y
44. Reddy SP, Hong RL, Nagda S, Emami B. Effect of tumor bulk on local control and survival of patients with T1 glottic cancer: a 30-year experience. *Int J Radiat Oncol Biol Phys.* 2007 Dec;69(5):1389-94. DOI: 10.1016/j.ijrobp.2007.05.077

45. Marshak G, Brenner B, Shvero J, Shapira J, Ophir D, Hochman I, Marshak G, Sulkes A, Rakowsky E. Prognostic factors for local control of early glottic cancer: the Rabin Medical Center retrospective study on 207 patients. *Int J Radiat Oncol Biol Phys*. 1999 Mar;43(5):1009-13. DOI: 10.1016/S0360-3016(98)00547-1
46. Laccourreye O, Gutierrez-Fonseca R, Garcia D, Hans S, Hacquart N, Ménard M, Brasnu D. Local recurrence after vertical partial laryngectomy, a conservative modality of treatment for patients with Stage I-II squamous cell carcinoma of the glottis. *Cancer*. 1999 Jun;85(12):2549-56. DOI: 10.1002/(SICI)1097-0142(19990615)85:12<2549::AID-CNCR9>3.0.CO;2-M
47. Roedel RM, Matthias C, Wolff HA, Christiansen H. Repeated transoral laser microsurgery for early and advanced recurrence of early glottic cancer after primary laser resection. *Auris Nasus Larynx*. 2010 Jun;37(3):340-6. DOI: 10.1016/j.anl.2009.07.004
48. Laccourreye O, Laccourreye L, Garcia D, Gutierrez-Fonseca R, Brasnu D, Weinstein G. Vertical partial laryngectomy versus supracricoid partial laryngectomy for selected carcinomas of the true vocal cord classified as T2N0. *Ann Otol Rhinol Laryngol*. 2000 Oct;109(10 Pt 1):965-71.
49. Laccourreye O, Muscatello L, Laccourreye L, Naudo P, Brasnu D, Weinstein G. Supracricoid partial laryngectomy with cricothyroidoepiglottopexy for "early" glottic carcinoma classified as T1-T2N0 invading the anterior commissure. *Am J Otolaryngol*. 1997 Nov-Dec;18(6):385-90. DOI: 10.1016/S0196-0709(97)90058-2
50. de Campora E, Radici M, de Campora L. External versus endoscopic approach in the surgical treatment of glottic cancer. *Eur Arch Otorhinolaryngol*. 2001 Dec;258(10):533-6. DOI: 10.1007/s004050100402
51. Maurizi M, Almadori G, Plaudetti G, De Corso E, Galli J. Laser carbon dioxide cordectomy versus open surgery in the treatment of glottic carcinoma: our results. *Otolaryngol Head Neck Surg*. 2005 Jun;132(6):857-61. DOI: 10.1016/j.otohns.2005.01.038
52. Puxeddu R, Argiolas F, Bielamowicz S, Satta M, Ledda GP, Puxeddu P. Surgical therapy of T1 and selected cases of T2 glottic carcinoma: cordectomy, horizontal glottectomy and CO2 laser endoscopic resection. *Tumori*. 2000 Jul-Aug;86(4):277-82.
53. Zohar Y, Rahima M, Shvili Y, Talmi YP, Lurie H. The controversial treatment of anterior commissure carcinoma of the larynx. *Laryngoscope*. 1992 Jan;102(1):69-72. DOI: 10.1288/00005537-199201000-00014
54. Rucci L, Gallo O, Fini-Storchi O. Glottic cancer involving anterior commissure: surgery vs radiotherapy. *Head Neck*. 1991 Sep-Oct;13(5):403-10. DOI: 10.1002/hed.2880130505
55. Eckel HE. Endoscopic laser resection of supraglottic carcinoma. *Otolaryngol Head Neck Surg*. 1997 Dec;117(6):681-7. DOI: 10.1016/S0194-5998(97)70052-4
56. Ambrosch P, Kron M, Steiner W. Carbon dioxide laser microsurgery for early supraglottic carcinoma. *Ann Otol Rhinol Laryngol*. 1998 Aug;107(8):680-8.
57. Bron LP, Soldati D, Monod ML, Mégevand C, Brossard E, Monnier P, Pasche P. Horizontal partial laryngectomy for supraglottic squamous cell carcinoma. *Eur Arch Otorhinolaryngol*. 2005 Apr;262(4):302-6. DOI: 10.1007/s00405-004-0824-y
58. Robbins KT, Davidson W, Peters LJ, Goepfert H. Conservation surgery for T2 and T3 carcinomas of the supraglottic larynx. *Arch Otolaryngol Head Neck Surg*. 1988 Apr;114(4):421-6. DOI: 10.1001/archotol.1988.01860160065023
59. Orús C, León X, Vega M, Quer M. Initial treatment of the early stages (I, II) of supraglottic squamous cell carcinoma: partial laryngectomy versus radiotherapy. *Eur Arch Otorhinolaryngol*. 2000 Nov;257(9):512-6. DOI: 10.1007/s004050000276
60. Karatzanis AD, Psychogios G, Zenk J, Waldfahrer F, Hornung J, Velegrakis GA, Iro H. Evaluation of available surgical management options for early supraglottic cancer. *Head Neck*. 2010 Aug;32(8):1048-55. DOI: 10.1002/hed.21289
61. Peretti G, Piazza C, Cattaneo A, De Benedetto L, Martin E, Nicolai P. Comparison of functional outcomes after endoscopic versus open-neck supraglottic laryngectomies. *Ann Otol Rhinol Laryngol*. 2006 Nov;115(11):827-32.
62. Cabanillas R, Rodrigo JP, Llorente JL, Suárez V, Ortega P, Suárez C. Functional outcomes of transoral laser surgery of supraglottic carcinoma compared with a transcervical approach. *Head Neck*. 2004 Aug;26(8):653-9. DOI: 10.1002/hed.20063
63. Werner JA. Zur Wertigkeit retrospektiver Vergleichsanalysen laserchirurgischer und konventionell-chirurgischer Behandlungen von Larynxkarzinomen [Value of retrospective comparative analyses of laser surgery and conventional surgical treatment of laryngeal cancers]. *Laryngorhinootologie*. 2003 Mar;82(3):194-6; discussion 196. DOI: 10.1055/s-2003-38409-2
64. Schröder U. Aktueller Stellenwert der offenen Larynxteilresektion unter besonderer Berücksichtigung der suprakrikoidalen Teilresektionen [Current value of open-preservation surgery with special emphasis given to the supracricoid laryngectomy]. *Laryngorhinootologie*. 2007 Jul;86(7):490-9. DOI: 10.1055/s-2007-966535
65. Sparano A, Chernock R, Feldman M, Laccourreye O, Brasnu D, Weinstein G. Extending the inferior limits of supracricoid partial laryngectomy: a clinicopathological correlation. *Laryngoscope*. 2005 Feb;115(2):297-300. DOI: 10.1097/01.mlg.0000154737.46528.82
66. Katilmiş H, Oztürkcan S, Ozdemir I, Adadan I, Tunç A, Akder A, Başoğlu S. A clinico-pathological study of laryngeal and hypopharyngeal carcinoma: correlation of cord-arytenoid mobility with histopathologic involvement. *Otolaryngol Head Neck Surg*. 2007 Feb;136(2):291-5. DOI: 10.1016/j.otohns.2006.08.022
67. Dufour X, Hans S, De Mones E, Brasnu D, Ménard M, Laccourreye O. Local control after supracricoid partial laryngectomy for "advanced" endolaryngeal squamous cell carcinoma classified as T3. *Arch Otolaryngol Head Neck Surg*. 2004 Sep;130(9):1092-9. DOI: 10.1001/archotol.130.9.1092
68. Holsinger FC, Weinstein GS, Laccourreye O. Supracricoid partial laryngectomy: an organ-preservation surgery for laryngeal malignancy. *Curr Probl Cancer*. 2005 Jul-Aug;29(4):190-200. DOI: 10.1016/j.currproblcancer.2005.07.001
69. Kocatürk S, Han U, Yilmazer D, Onal B, Erkam U. A histopathological study of thyroarytenoid muscle invasion in early (T1) glottic carcinoma. *Otolaryngol Head Neck Surg*. 2005 Apr;132(4):581-3. DOI: 10.1016/j.otohns.2004.09.133
70. Eckel HE. Topographische und klinisch-onkologische Analyse lokoregionärer Rezidive nach transoraler Laserchirurgie zur Behandlung von Kehlkopfkarcinomen [Topographical and clinic-oncologic analysis of locoregional recurrence after transoral laser surgery for laryngeal cancer]. *Laryngorhinootologie*. 1993 Aug;72(8):406-11. DOI: 10.1055/s-2007-997926
71. Lee NK, Goepfert H, Wendt CD. Supraglottic laryngectomy for intermediate-stage cancer: U.T. M.D. Anderson Cancer Center experience with combined therapy. *Laryngoscope*. 1990 Aug;100(8):831-6. DOI: 10.1288/00005537-199008000-00007
72. Holsinger FC, Funk E, Roberts DB, Diaz EM Jr. Conservation laryngeal surgery versus total laryngectomy for radiation failure in laryngeal cancer. *Head Neck*. 2006 Sep;28(9):779-84. DOI: 10.1002/hed.20415
73. Spriano G, Pellini R, Romano G, Muscatello L, Roselli R. Supracricoid partial laryngectomy as salvage surgery after radiation failure. *Head Neck*. 2002 Aug;24(8):759-65. DOI: 10.1002/hed.10117

74. Rodríguez-Cuevas S, Labastida S, Gonzalez D, Briseño N, Cortes H. Partial laryngectomy as salvage surgery for radiation failures in T1-T2 laryngeal cancer. *Head Neck*. 1998 Oct;20(7):630-3. DOI: 10.1002/(SICI)1097-0347(199810)20:7<630::AID-HED9>3.0.CO;2-K
75. Shah JP, Loree TR, Kowalski L. Conservation surgery for radiation-failure carcinoma of the glottic larynx. *Head Neck*. 1990 Jul-Aug;12(4):326-31. DOI: 10.1002/hed.2880120409
76. Steiner W, Vogt P, Ambrosch P, Kron M. Transoral carbon dioxide laser microsurgery for recurrent glottic carcinoma after radiotherapy. *Head Neck*. 2004 Jun;26(6):477-84. DOI: 10.1002/hed.20009
77. Laccourreye O, Salzer SJ, Brasnu D, Shen W, Laccourreye H, Weinstein GS. Glottic carcinoma with a fixed true vocal cord: outcomes after neoadjuvant chemotherapy and supracricoid partial laryngectomy with cricothyroidopexy. *Otolaryngol Head Neck Surg*. 1996 Mar;114(3):400-6. DOI: 10.1016/S0194-5998(96)70209-7
78. Motamed M, Laccourreye O, Bradley PJ. Salvage conservation laryngeal surgery after irradiation failure for early laryngeal cancer. *Laryngoscope*. 2006 Mar;116(3):451-5. DOI: 10.1097/01.MLG.0000199591.92336.06
79. Naudo P, Laccourreye O, Weinstein G, Hans S, Laccourreye H, Brasnu D. Functional outcome and prognosis factors after supracricoid partial laryngectomy with cricothyroidopexy. *Ann Otol Rhinol Laryngol*. 1997 Apr;106(4):291-6.
80. Marioni G, Marchese-Ragona R, Pastore A, Staffieri A. The role of supracricoid laryngectomy for glottic carcinoma recurrence after radiotherapy failure: a critical review. *Acta Otolaryngol*. 2006 Dec;126(12):1245-51. DOI: 10.1080/00016480600818062
81. Olofsson J, van Nostrand AW. Growth and spread of laryngeal and hypopharyngeal carcinoma with reflections on the effect of preoperative irradiation. 139 cases studied by whole organ serial sectioning. *Acta Otolaryngol Suppl*. 1973;308:1-84.
82. Kirchner JA. Pyriform sinus cancer: a clinical and laboratory study. *Ann Otol Rhinol Laryngol*. 1975 Nov-Dec;84(6):793-803.
83. Harrison DF. Pathology of hypopharyngeal cancer in relation to surgical management. *J Laryngol Otol*. 1970 Apr;84(4):349-67. DOI: 10.1017/S0022215100071991
84. Stell PM. Cancer of the hypopharynx. *J R Coll Surg Edinb*. 1973 Jan;18(1):20-30.
85. Parkin DM, Muir CS. Cancer Incidence in Five Continents. Comparability and quality of data. *IARC Sci Publ*. 1992;(120):45-173.
86. Carpenter RJ 3rd, DeSanto LW. Cancer of the hypopharynx. *Surg Clin North Am*. 1977 Aug;57(4):723-35.
87. Pingree TF, Davis RK, Reichman O, Derrick L. Treatment of hypopharyngeal carcinoma: a 10-year review of 1,362 cases. *Laryngoscope*. 1987 Aug;97(8 Pt 1):901-4.
88. Sewnaik A, Hoorweg JJ, Knegt PP, Wieringa MH, van der Beek JM, Kerrebijn JD. Treatment of hypopharyngeal carcinoma: analysis of nationwide study in the Netherlands over a 10-year period. *Clin Otolaryngol*. 2005 Feb;30(1):52-7. DOI: 10.1111/j.1365-2273.2004.00913.x
89. Kim S, Wu HG, Heo DS, Kim KH, Sung MW, Park CI. Advanced hypopharyngeal carcinoma treatment results according to treatment modalities. *Head Neck*. 2001 Sep;23(9):713-7. DOI: 10.1002/hed.1101
90. Lefebvre JL, Chevalier D, Lubinski B, Kirkpatrick A, Collette L, Sahnoud T. Larynx preservation in pyriform sinus cancer: preliminary results of a European Organization for Research and Treatment of Cancer phase III trial. EORTC Head and Neck Cancer Cooperative Group. *J Natl Cancer Inst*. 1996 Jul;88(13):890-9. DOI: 10.1093/jnci/88.13.890
91. Clark JR, de Almeida J, Gilbert R, Irish J, Brown D, Neligan P, Gullane PJ. Primary and salvage (hypo)pharyngectomy: Analysis and outcome. *Head Neck*. 2006 Aug;28(8):671-7. DOI: 10.1002/hed.20428
92. Florant A, Berreby S, Gilain L, Denoyelle F, Geoffroy B, Morisseau MP, Trotoux J. La chirurgie fonctionnelle des cancers de l'hypopharynx. Hémi-laryngo-pharyngectomies, pharyngectomies postérieures par abord cervical bilatéral [Functional surgery of cancer of the hypopharynx. Hemilaryngopharyngectomy, posterior pharyngectomy by bilateral cervical approach]. *Ann Otolaryngol Chir Cervicofac*. 1986;103(7):443-53.
93. Lecanu JB, Monceaux G, Périé S, Angelard B, St Guily JL. Conservative surgery in T3-T4 pharyngolaryngeal squamous cell carcinoma: an alternative to radiation therapy and to total laryngectomy for good responders to induction chemotherapy. *Laryngoscope*. 2000 Mar;110(3 Pt 1):412-6. DOI: 10.1097/00005537-200003000-00015
94. Laccourreye O, Mérite-Drancy A, Brasnu D, Chabardes E, Cauchois R, Ménard M, Laccourreye H. Supracricoid hemilaryngopharyngectomy in selected pyriform sinus carcinoma staged as T2. *Laryngoscope*. 1993 Dec;103(12):1373-9. DOI: 10.1288/00005537-199312000-00010
95. Ogura JH, Marks JE, Freeman RB. Results of conservation surgery for cancers of the supraglottis and pyriform sinus. *Laryngoscope*. 1980 Apr;90(4):591-600. DOI: 10.1288/00005537-198004000-00005
96. Harrison DF. Surgical repair in hypopharyngeal and cervical esophageal cancer. Analysis of 162 patients. *Ann Otol Rhinol Laryngol*. 1981 Jul-Aug;90(4 Pt 1):372-5.
97. Peracchia A, Bonavina L, Botturi M, Pagani M, Via A, Saino G. Current status of surgery for carcinoma of the hypopharynx and cervical esophagus. *Dis Esophagus*. 2001;14(2):95-7. DOI: 10.1046/j.1442-2050.2001.00163.x
98. Montgomery PQ, Rhys Evans PH, Gullane PJ, eds. Principles and Practice of Head and Neck Surgery and Oncology. 2. ed. Boca Raton, Fla.: Informa Healthcare; 2009.
99. Kraus DH, Zelefsky MJ, Brock HA, Huo J, Harrison LB, Shah JP. Combined surgery and radiation therapy for squamous cell carcinoma of the hypopharynx. *Otolaryngol Head Neck Surg*. 1997 Jun;116(6 Pt 1):637-41. DOI: 10.1016/S0194-5998(97)70240-7
100. Frank JL, Garb JL, Kay S, McClish DK, Bethke KP, Lind DS, Mellis M, Slomka W, Sismanis A, Neifeld JP. Postoperative radiotherapy improves survival in squamous cell carcinoma of the hypopharynx. *Am J Surg*. 1994 Nov;168(5):476-80. DOI: 10.1016/S0002-9610(05)80105-9
101. Bova R, Goh R, Poulson M, Coman WB. Total pharyngolaryngectomy for squamous cell carcinoma of the hypopharynx: a review. *Laryngoscope*. 2005 May;115(5):864-9. DOI: 10.1097/01.MLG.0000158348.38763.5D
102. Bernier J, Cooper JS, Pajak TF, van Glabbeke M, Bourhis J, Forastiere A, Ozsahin EM, Jacobs JR, Jasse J, Ang KK, Lefebvre JL. Defining risk levels in locally advanced head and neck cancers: a comparative analysis of concurrent postoperative radiation plus chemotherapy trials of the EORTC (#22931) and RTOG (# 9501). *Head Neck*. 2005 Oct;27(10):843-50. DOI: 10.1002/hed.20279

103. Clark JR, Gilbert R, Irish J, Brown D, Neligan P, Gullane PJ. Morbidity after flap reconstruction of hypopharyngeal defects. *Laryngoscope*. 2006 Feb;116(2):173-81. DOI: 10.1097/01.mlg.0000191459.40059.fcd
104. Million RR, Cassisi NJ, Mancuso AA. Hypopharynx: Pharyngeal walls, pyriform sinus, postcricoid pharynx. In: Million RR, Cassisi NJ, eds. *Management of Head and Neck Cancer*. Philadelphia: Lippincott; 1994.
105. Wenig BL, Ziffra KL, Mafee MF, Schild JA. MR imaging of squamous cell carcinoma of the larynx and hypopharynx. *Otolaryngol Clin North Am*. 1995 Jun;28(3):609-19.
106. Makeieff M, Mercante G, Jouzdani E, Garrel R, Crampette L, Guerrier B. Supraglottic hemipharyngolaryngectomy for the treatment of T1 and T2 carcinomas of laryngeal margin and pyriform sinus. *Head Neck*. 2004 Aug;26(8):701-5. DOI: 10.1002/hed.20051
107. Plouin-Gaudon I, Lengelé B, Desuter G, Rombaux P, Ledeghen S, Grégoire V, Hamoir M. Conservation laryngeal surgery for selected pyriform sinus cancer. *Eur J Surg Oncol*. 2004 Dec;30(10):1123-30. DOI: 10.1016/j.ejso.2004.08.011
108. Martin A, Jäckel MC, Christiansen H, Mahmoodzada M, Kron M, Steiner W. Organ preserving transoral laser microsurgery for cancer of the hypopharynx. *Laryngoscope*. 2008 Mar;118(3):398-402. DOI: 10.1097/MLG.0b013e31815aada3
109. Barton RT. Surgical treatment of carcinoma of the pyriform sinus. *Arch Otolaryngol*. 1973 Apr;97(4):337-9. DOI: 10.1001/archotol.1973.00780010347012
110. Czaja JM, Gluckman JL. Surgical management of early-stage hypopharyngeal carcinoma. *Ann Otol Rhinol Laryngol*. 1997 Nov;106(11):909-13.
111. Czaja JM, McCaffrey TV. The surgical management of laryngotracheal invasion by well-differentiated papillary thyroid carcinoma. *Arch Otolaryngol Head Neck Surg*. 1997 May;123(5):484-90. DOI: 10.1001/archotol.1997.01900050030003
112. Holsinger FC, Motamed M, Garcia D, Brasnu D, Ménard M, Laccourreye O. Resection of selected invasive squamous cell carcinoma of the pyriform sinus by means of the lateral pharyngotomy approach: the partial lateral pharyngectomy. *Head Neck*. 2006 Aug;28(8):705-11. DOI: 10.1002/hed.20375
113. El Badawi SA, Goepfert H, Fletcher GH, Herson J, Oswald MJ. Squamous cell carcinoma of the pyriform sinus. *Laryngoscope*. 1982 Apr;92(4):357-64.
114. Steiner W, Stenglein C, Fietkau R, Sauerbrei W. Therapie des Hypopharynxkarzinoms. Teil IV: Langzeitergebnisse der transoralen Lasermikrochirurgie von Hypopharynxkarzinomen [Therapy of hypopharyngeal cancer. Part IV: Long-term results of transoral laser microsurgery of hypopharyngeal cancer]. *HNO*. 1994 Mar;42(3):147-56.
115. Steiner W. Therapie des Hypopharynxkarzinoms. Teil III: Das Konzept der minimal invasiven Therapie von Karzinomen des oberen Aerodigestivtrakts unter besonderer Berücksichtigung des Hypopharynxkarzinoms und der transoralen Lasermikrochirurgie [Therapy of hypopharyngeal cancer. Part III: The concept of minimally invasive therapy of cancers of the upper aerodigestive tract with special reference to hypopharyngeal cancer and trans-oral laser microsurgery]. *HNO*. 1994 Feb;42(2):104-12.
116. Ambrosch P, Brinck U, Fischer G, Steiner W. Spezielle Aspekte der histopathologischen Diagnostik bei der Lasermikrochirurgie von Karzinomen des oberen Aerodigestivtraktes [Special aspects of histopathologic diagnosis in laser microsurgery of cancers of the upper aerodigestive tract]. *Laryngorhinootologie*. 1994 Feb;73(2):78-83. DOI: 10.1055/s-2007-997084
117. Steiner W, Ambrosch P, Hess CF, Kron M. Organ preservation by transoral laser microsurgery in pyriform sinus carcinoma. *Otolaryngol Head Neck Surg*. 2001 Jan;124(1):58-67. DOI: 10.1067/mhn.2001.111597
118. Farrington WT, Weighill JS, Jones PH. Post-cricoid carcinoma (a ten-year retrospective study). *J Laryngol Otol*. 1986 Jan;100(1):79-84. DOI: 10.1017/S0022215100098777
119. Spiro RH, Kelly J, Vega AL, Harrison LB, Strong EW. Squamous carcinoma of the posterior pharyngeal wall. *Am J Surg*. 1990 Oct;160(4):420-3. DOI: 10.1016/S0002-9610(05)80557-4
120. Pene F, Avedian V, Eschwege F, Barrett A, Schwaab G, Marandas P, Vandenbrouck C. A retrospective study of 131 cases of carcinoma of the posterior pharyngeal wall. *Cancer*. 1978 Nov;42(5):2490-3. DOI: 10.1002/1097-0142(197811)42:5<2490::AID-CNCR2820420553>3.0.CO;2-5
121. Wookey H. The surgical treatment of carcinoma of the hypopharynx and the oesophagus. *Br J Surg*. 1948 Jan;35(139):249-66. DOI: 10.1002/bjs.18003513903
122. Bakamjian VY. A two-stage method for pharyngoesophageal reconstruction with a primary pectoral skin flap. *Plast Reconstr Surg*. 1965 Aug;36:173-84. DOI: 10.1097/00006534-196508000-00004
123. Ariyan S. The pectoralis major myocutaneous flap. A versatile flap for reconstruction in the head and neck. *Plast Reconstr Surg*. 1979 Jan;63(1):73-81. DOI: 10.1097/00006534-197901000-00012
124. Ong GB, Lee TC. Pharyngogastric anastomosis after oesophago-pharyngectomy for carcinoma of the hypopharynx and cervical oesophagus. *Br J Surg*. 1960 Sep;48:193-200. DOI: 10.1002/bjs.18004820823
125. Seidenberg B, Rosenak SS, Hurwitt ES, Som ML. Immediate reconstruction of the cervical esophagus by a revascularized isolated jejunal segment. *Ann Surg*. 1959 Feb;149(2):162-71. DOI: 10.1097/00006558-195902000-00002
126. Baudet J. Reconstruction of the pharyngeal wall by free transfer of the greater omentum and stomach. *Int J Microsurg*. 1979;53-9.
127. Genden EM, Jacobson AS. The role of the anterolateral thigh flap for pharyngoesophageal reconstruction. *Arch Otolaryngol Head Neck Surg*. 2005 Sep;131(9):796-9. DOI: 10.1001/archotol.131.9.796
128. Anthony JP, Singer MI, Deschler DG, Dougherty ET, Reed CG, Kaplan MJ. Long-term functional results after pharyngoesophageal reconstruction with the radial forearm free flap. *Am J Surg*. 1994 Nov;168(5):441-5. DOI: 10.1016/S0002-9610(05)80095-9
129. Richmon JD, Brumund KT. Reconstruction of the hypopharynx: current trends. *Curr Opin Otolaryngol Head Neck Surg*. 2007 Aug;15(4):208-12. DOI: 10.1097/MOO.0b013e3182825b0852
130. Genden EM, Varvares MA, eds. *Head and Neck Cancer, An Evidence-Based Team Approach*. New York: Thieme; 2008.
131. Patel RS, Goldstein DP, Brown D, Irish J, Gullane PJ, Gilbert RW. Circumferential pharyngeal reconstruction: history, critical analysis of techniques, and current therapeutic recommendations. *Head Neck*. 2010 Jan;32(1):109-20. DOI: 10.1002/hed.21169
132. Disa JJ, Pusic AL, Hidalgo DA, Cordeiro PG. Microvascular reconstruction of the hypopharynx: defect classification, treatment algorithm, and functional outcome based on 165 consecutive cases. *Plast Reconstr Surg*. 2003 Feb;111(2):652-60; discussion 661-3. DOI: 10.1097/01.PRS.0000041987.53831.23



133. Urken ML, ed. Multidisciplinary head and neck reconstruction: a defect-oriented approach. Philadelphia: Wolters Kluwer, Lippincott Williams & Wilkins; 2010.
134. Takato T, Harii K, Ebihara S, Ono I, Yoshizumi T, Nakatsuka T. Oral and pharyngeal reconstruction using the free forearm flap. *Arch Otolaryngol Head Neck Surg.* 1987 Aug;113(8):873-9. DOI: 10.1001/archotol.1987.01860080079022
135. Mäkitie AA, Beasley NJ, Neligan PC, Lipa J, Gullane PJ, Gilbert RW. Head and neck reconstruction with anterolateral thigh flap. *Otolaryngol Head Neck Surg.* 2003 Nov;129(5):547-55. DOI: 10.1016/S0194-5998(03)01393-7
136. Nakatsuka T, Harii K, Asato H, Ebihara S, Yoshizumi T, Saikawa M. Comparative evaluation in pharyngo-oesophageal reconstruction: radial forearm flap compared with jejunal flap. A 10-year experience. *Scand J Plast Reconstr Surg Hand Surg.* 1998 Sep;32(3):307-10. DOI: 10.1080/02844319850158651
137. Spriano G, Pellini R, Roselli R. Pectoralis major myocutaneous flap for hypopharyngeal reconstruction. *Plast Reconstr Surg.* 2002 Nov;110(6):1408-13; discussion 1414-6. DOI: 10.1097/01.PRS.0000029350.61515.39
138. Shangold LM, Urken ML, Lawson W. Jejunal transplantation for pharyngoesophageal reconstruction. *Otolaryngol Clin North Am.* 1991 Dec;24(6):1321-42.
139. Wadsworth JT, Futran N, Eubanks TR. Laparoscopic harvest of the jejunal free flap for reconstruction of hypopharyngeal and cervical esophageal defects. *Arch Otolaryngol Head Neck Surg.* 2002 Dec;128(12):1384-7.
140. Reece GP, Bengtson BP, Schusterman MA. Reconstruction of the pharynx and cervical esophagus using free jejunal transfer. *Clin Plast Surg.* 1994 Jan;21(1):125-36.
141. Theille DR, Robinson DW, Theille DE, Coman WB. Free jejunal interposition reconstruction after pharyngolaryngectomy: 201 consecutive cases. *Head Neck.* 1995 Mar-Apr;17(2):83-8. DOI: 10.1002/hed.2880170202
142. Kerlin P, McCafferty GJ, Robinson DW, Theille D. Function of a free jejunal "conduit" graft in the cervical esophagus. *Gastroenterology.* 1986 Jun;90(6):1956-63.
143. Nakamura T, Inokuchi K, Sugimachi K. Use of revascularized jejunum as a free graft for cervical esophagus. *Jpn J Surg.* 1975 Jun;5(2):92-102. DOI: 10.1007/BF02469613
144. Genden EM, Kaufman MR, Katz B, Vine A, Urken ML. Tubed gastro-omental free flap for pharyngoesophageal reconstruction. *Arch Otolaryngol Head Neck Surg.* 2001 Jul;127(7):847-53.
145. Righini CA, Bettega G, Lequeux T, Chaffanjon P, Lebeau J, Reyt E. Use of tubed gastro-omental free flap for hypopharynx and cervical esophagus reconstruction after total laryngo-pharyngectomy. *Eur Arch Otorhinolaryngol.* 2005 May;262(5):362-7. DOI: 10.1007/s00405-004-0828-7
146. Yu P. Characteristics of the anterolateral thigh flap in a Western population and its application in head and neck reconstruction. *Head Neck.* 2004 Sep;26(9):759-69. DOI: 10.1002/hed.20050
147. Azizzadeh B, Yafai S, Rawnsley JD, Abemayor E, Sercarz JA, Calcaterra TC, Berke GS, Blackwell KE. Radial forearm free flap pharyngoesophageal reconstruction. *Laryngoscope.* 2001 May;111(5):807-10. DOI: 10.1097/00005537-200105000-00010
148. Scharpf J, Esclamado RM. Reconstruction with radial forearm flaps after ablative surgery for hypopharyngeal cancer. *Head Neck.* 2003 Apr;25(4):261-6. DOI: 10.1002/hed.10197
149. Deschler DG, Doherty ET, Reed CG, Anthony JP, Singer MI. Tracheoesophageal voice following tubed free radial forearm flap reconstruction of the neopharynx. *Ann Otol Rhinol Laryngol.* 1994 Dec;103(12):929-36.
150. Anthony JP, Singer MI, Mathes SJ. Pharyngoesophageal reconstruction using the tubed free radial forearm flap. *Clin Plast Surg.* 1994 Jan;21(1):137-47.
151. Stoeckli SJ, Pawlik AB, Lipp M, Huber A, Schmid S. Salvage surgery after failure of nonsurgical therapy for carcinoma of the larynx and hypopharynx. *Arch Otolaryngol Head Neck Surg.* 2000 Dec;126(12):1473-7.
152. Sassler AM, Esclamado RM, Wolf GT. Surgery after organ preservation therapy. Analysis of wound complications. *Arch Otolaryngol Head Neck Surg.* 1995 Feb;121(2):162-5. DOI: 10.1001/archotol.1995.01890020024006
153. Weber RS, Berkey BA, Forastiere A, Cooper J, Maor M, Goepfert H, Morrison W, Glisson B, Trotti A, Ridge JA, Chao KS, Peters G, Lee DJ, Leaf A, Ensley J. Outcome of salvage total laryngectomy following organ preservation therapy: the Radiation Therapy Oncology Group trial 91-11. *Arch Otolaryngol Head Neck Surg.* 2003 Jan;129(1):44-9. DOI: 10.1001/archotol.129.1.44
154. Naumann HH, Herberhold J, Jahrdoerfer RA, Kastenbauer ER, Panje WR, Tardy ME. *Head and Neck Surgery. Volume 3.* Stuttgart/NewYork: Thieme; 1998.
155. Brasnu DF. Supracricoid partial laryngectomy with cricothyroidopexy in the management of laryngeal carcinoma. *World J Surg.* 2003 Jul;27(7):817-23. DOI: 10.1007/s00268-003-7116-3
156. Laccourreye O, Weinstein G, Brasnu D, Trotoux J, Laccourreye H. Vertical partial laryngectomy: a critical analysis of local recurrence. *Ann Otol Rhinol Laryngol.* 1991 Jan;100(1):68-71.
157. Thomas JV, Olsen KD, Neel HB 3rd, DeSanto LW, Suman VJ. Early glottic carcinoma treated with open laryngeal procedures. *Arch Otolaryngol Head Neck Surg.* 1994 Mar;120(3):264-8. DOI: 10.1001/archotol.1994.01880270012003
158. Giovanni A, Guelfucci B, Gras R, Yu P, Zanaret M. Partial frontolateral laryngectomy with epiglottic reconstruction for management of early-stage glottic carcinoma. *Laryngoscope.* 2001 Apr;111(4 Pt 1):663-8. DOI: 10.1097/00005537-200104000-00020
159. Gallo A, Manciooco V, Simonelli M, Pagliuca G, D'Arcangelo E, de Vincentiis M. Supracricoid partial laryngectomy in the treatment of laryngeal cancer: univariate and multivariate analysis of prognostic factors. *Arch Otolaryngol Head Neck Surg.* 2005 Jul;131(7):620-5. DOI: 10.1001/archotol.131.7.620
160. Soo KC, Shah JP, Gopinath KS, Gerold FP, Jaques DP, Strong EW. Analysis of prognostic variables and results after supraglottic partial laryngectomy. *Am J Surg.* 1988 Oct;156(4):301-5. DOI: 10.1016/S0002-9610(88)80298-8
161. Leroux-Robert J. A statistical study of 620 laryngeal carcinomas of the glottic region personally operated upon more than five years ago. *Laryngoscope.* 1975 Sep;85(9):1440-52. DOI: 10.1288/00005537-197509000-00005
162. Biller HF, Lawson W. Partial laryngectomy for vocal cord cancer with marked limitation or fixation of the vocal cord. *Laryngoscope.* 1986 Jan;96(1):61-4. DOI: 10.1288/00005537-198601000-00011
163. Daniilidis J, Nikolaou A, Fountzilias G, Sombolos K. Vertical partial laryngectomy: our results after treating 81 cases of T2 and T3 laryngeal carcinomas. *J Laryngol Otol.* 1992 Apr;106(4):349-52. DOI: 10.1017/S0022215100119462
164. Ogura JH, Sessions DG, Spector GJ. Analysis of surgical therapy for epidermoid carcinoma of the laryngeal glottis. *Laryngoscope.* 1975 Sep;85(9):1522-30. DOI: 10.1288/00005537-197509000-00015

165. Laccourreye O, Brasnu D, Merite-Drancy A, Cauchois R, Chabardes E, Ménard M, Laccourreye H. Cricohyoidopexy in selected infrahyoid epiglottic carcinomas presenting with pathological preepiglottic space invasion. *Arch Otolaryngol Head Neck Surg.* 1993 Aug;119(8):881-6. DOI: 10.1001/archotol.1993.01880200087012
166. Alajmo E, Fini-Storchi O, Agostini V, Polli G. Conservation surgery for cancer of the larynx in the elderly. *Laryngoscope.* 1985 Feb;95(2):203-5. DOI: 10.1288/00005537-198502000-00016
167. Laccourreye O, Weinstein G, Brasnu D, Bassot V, Cauchois R, Jouffre V, Garcia D, Laccourreye H. A clinical trial of continuous cisplatin-fluorouracil induction chemotherapy and supracricoid partial laryngectomy for glottic carcinoma classified as T2. *Cancer.* 1994 Nov;74(10):2781-90. DOI: 10.1002/1097-0142(19941115)74:10<2781::AID-CNCR2820741007>3.0.CO;2-U
168. Maurice N, Crampette L, Mondain M, Guerrier B. Laryngectomie sub-totale reconstructive avec cricohyoidopexie résultats carcinologiques et suites fonctionnelles précoces. A propos de 43 cas [Subtotal laryngectomy with cricohyoidopexy. Carcinologic results and early functional follow-up. Apropos of 49 cases]. *Ann Otolaryngol Chir Cervicofac.* 1994;111(8):435-42.
169. Peretti G, Nicolai P, Piazza C, Redaelli de Zinis LO, Valentini S, Antonelli AR. Oncological results of endoscopic resections of Tis and T1 glottic carcinomas by carbon dioxide laser. *Ann Otol Rhinol Laryngol.* 2001 Sep;110(9):820-6.
170. Hartl DM, de Monès E, Hans S, Janot F, Brasnu D. Treatment of early-stage glottic cancer by transoral laser resection. *Ann Otol Rhinol Laryngol.* 2007 Nov;116(11):832-6.
171. Pearson BW, Salassa JR. Transoral laser microresection for cancer of the larynx involving the anterior commissure. *Laryngoscope.* 2003 Jul;113(7):1104-12. DOI: 10.1097/00005537-200307000-00002
172. Davis RK, Hadley K, Smith ME. Endoscopic vertical partial laryngectomy. *Laryngoscope.* 2004 Feb;114(2):236-40. DOI: 10.1097/00005537-200402000-00012
173. Peretti G, Piazza C, Mensi MC, Magnoni L, Bolzoni A. Endoscopic treatment of cT2 glottic carcinoma: prognostic impact of different pT subcategories. *Ann Otol Rhinol Laryngol.* 2005 Aug;114(8):579-86.
174. Peretti G, Piazza C, Bolzoni A, Mensi MC, Rossini M, Parrinello G, Shapshay SM, Antonelli AR. Analysis of recurrences in 322 Tis, T1, or T2 glottic carcinomas treated by carbon dioxide laser. *Ann Otol Rhinol Laryngol.* 2004 Nov;113(11):853-8.
175. Sigston E, de Mones E, Babin E, Hans S, Hartl DM, Clement P, Brasnu DF. Early-stage glottic cancer: oncological results and margins in laser cordectomy. *Arch Otolaryngol Head Neck Surg.* 2006 Feb;132(2):147-52. DOI: 10.1001/archotol.132.2.147
176. Davis RK. Endoscopic surgical management of glottic laryngeal cancer. *Otolaryngol Clin North Am.* 1997 Feb;30(1):79-86.
177. Mendenhall WM, Amdur RJ, Morris CG, Hinerman RW. T1-T2N0 squamous cell carcinoma of the glottic larynx treated with radiation therapy. *J Clin Oncol.* 2001 Oct;19(20):4029-36.
178. Stoeckli SJ, Schnieper I, Huguenin P, Schmid S. Early glottic carcinoma: treatment according patient's preference? *Head Neck.* 2003 Dec;25(12):1051-6. DOI: 10.1002/hed.10323
179. Sevilla MA, Rodrigo JP, Llorente JL, Cabanillas R, López F, Suárez C. Supraglottic laryngectomy: analysis of 267 cases. *Eur Arch Otorhinolaryngol.* 2008 Jan;265(1):11-6. DOI: 10.1007/s00405-007-0415-9
180. Maurizi M, Paludetti G, Galli J, Ottaviani F, D'Abramo G, Almadori G. Oncological and functional outcome of conservative surgery for primary supraglottic cancer. *Eur Arch Otorhinolaryngol.* 1999;256(6):283-90. DOI: 10.1007/s004050050247
181. Laudadio P, Presutti L, Dall'olio D, Cunsolo E, Consalici R, Amorosa L, Cancellieri A, Bocciolini C. Supracricoid laryngectomies: long-term oncological and functional results. *Acta Otolaryngol.* 2006 Jun;126(6):640-9. DOI: 10.1080/00016480500469024
182. Vandenbrouck C, Sancho H, Le Fur R, Richard JM, Cachin Y. Results of a randomized clinical trial of preoperative irradiation versus postoperative in treatment of tumors of the hypopharynx. *Cancer.* 1977 Apr;39(4):1445-9. DOI: 10.1002/1097-0142(197704)39:4<1445::AID-CNCR2820390415>3.0.CO;2-6

**Corresponding author:**

Prof. Dr. Ulrich R. Goessler  
 Universitaets-HNO-Klinik, Universitätsmedizin Mannheim,  
 Theodor-Kutzer-Ufer 1-3, 68167 Mannheim, Germany,  
 Phone: +49(0)621-3831600, Fax: +49(0)621-3833827  
 ulrich.goessler@umm.de

**Please cite as**

Goessler UR. *Traditional transcutaneous approaches in head and neck surgery.* *GMS Curr Top Otorhinolaryngol Head Neck Surg.* 2012;11:Doc06.  
 DOI: 10.3205/cto000088, URN: urn:nbn:de:0183-cto0000887

**This article is freely available from**

<http://www.egms.de/en/journals/cto/2012-11/cto000088.shtml>

**Published:** 2012-12-20

**Copyright**

©2012 Goessler. This is an Open Access article distributed under the terms of the Creative Commons Attribution License (<http://creativecommons.org/licenses/by-nc-nd/3.0/deed.en>). You are free: to Share — to copy, distribute and transmit the work, provided the original author and source are credited.